

Unusual presentation of a large tension bronchogenic cyst in an adult

Stephen P Tarpy, Hardy Kornfeld, Krzysztof Moroz, Harold L Lazar

Abstract

A routine chest radiograph in a 20 year old man revealed a giant air filled cavity of the left hemithorax under tension. At thoracotomy a large left lower lobe intraparenchymal cyst required lobectomy and the pathological findings were consistent with a bronchogenic cyst. Although tension bronchogenic cysts are common in infants, this case demonstrates their unusual presentation in an adult.

(Thorax 1993;48:951-952)

Large air filled cysts displacing the mediastinum and causing respiratory distress have been reported frequently in infants.¹⁻³ In contrast, giant bronchogenic cysts containing air under pressure have rarely been described in older children and adults.³⁻⁶ We present an adult with this unusual complication who underwent successful surgical resection.

Case report

A 20 year old Haitian man who had been living in the USA for one year came to the tuberculosis clinic for evaluation of a positive tuberculin test. A chest radiograph showed a large cystic lesion occupying most of the left

hemithorax, displacing the trachea and the mediastinum to the right (fig 1). He gave a history of dyspnoea on heavy exertion but denied fever, chills, night sweats, cough, weight loss, pleuritic chest pain, or haemoptysis. He also denied any serious respiratory illness in the past or family history of lung disease. He had no history of smoking or intravenous drug abuse and was HIV negative when tested one year before presentation.

Physical examination showed a young man in no distress. He had no lymphadenopathy and a normal jugular venous pulse. Chest examination revealed hyperresonance to percussion and decreased breath sounds over the left hemithorax. The cardiac examination was normal.

Arterial blood gas tensions measured on air showed a pH of 7.30, PCO₂ of 37 mm Hg, and PO₂ of 103 mm Hg. The α_1 antitrypsin level was normal. The results of spirometric tests were as follows: forced vital capacity (FVC) 2.81 l (54% predicted), forced expiratory volume in one second (FEV₁) 2.20 l (53% predicted), and FEV₁/FVC 78%. Lung volumes measured by plethysmography revealed a total lung capacity of 6.37 l (93% predicted), functional residual capacity of 4.61 l (125% predicted), and residual volume of 3.58 l (221% predicted). A chest computed tomographic scan showed a giant air filled cyst of the left lower lobe displacing the left upper lobe anteriorly and medially to the right.

The patient underwent a left thoracotomy which revealed a large cystic lesion occupying almost the entire left lower lobe. A left lower lobectomy was performed and histological examination showed a 15.0 × 10.0 × 2.5 cm intraparenchymal cyst lined by pseudostratified ciliated columnar epithelium and fibrous tissue (fig 2). There was no communication between the cyst and the bronchial tree. No cartilage or smooth muscle was found in the cyst wall. The patient made an uneventful recovery and was discharged home after nine days.

Discussion

Pulmonary bronchogenic cysts present radiographically in three different patterns depending on the extent of bronchial or parenchymal communication and the secretory capacity of the lining epithelium.⁷ If no communication is present the cyst will appear as a homogeneous mass with a density of water or a nodule, while communicating cysts will be air filled or contain an air-fluid level. Lesions do not generally communicate with the tracheo-bronchial tree until they become infected.⁷

The development of a large air filled cyst may be due to a one way ball valve which allows air to enter but not to leave the cyst.^{2,4} The present case is unusual since most reports of giant air filled cysts compressing adjacent lung parenchyma and the mediastinum occur in infants.^{1,2} To our knowledge there are only a few pathologically confirmed reports of such cysts occurring in older

Pulmonary Center
S P Tarpy
H Kornfeld
Department of Anatomical Pathology, Mallory Institute of Pathology
K Moroz
Department of Cardiothoracic Surgery, University Hospital
H L Lazar
Boston University School of Medicine, Boston, Massachusetts, USA

Reprint requests to:
Dr S P Tarpy, Pulmonary Department (111 PI), Boston VA Medical Center, 150 South Huntington Avenue, Boston, Massachusetts 02130, USA
Received 13 August 1992
Returned to authors 22 October 1992
Revised version received 24 November 1992
Accepted 26 November 1992

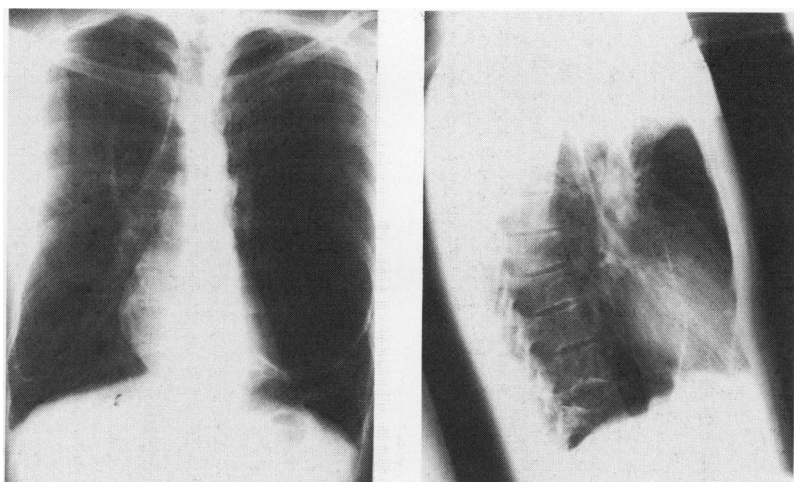

Figure 1 Chest radiograph showing a large cystic lesion occupying almost the entire left hemithorax displacing the trachea and mediastinum to the right.

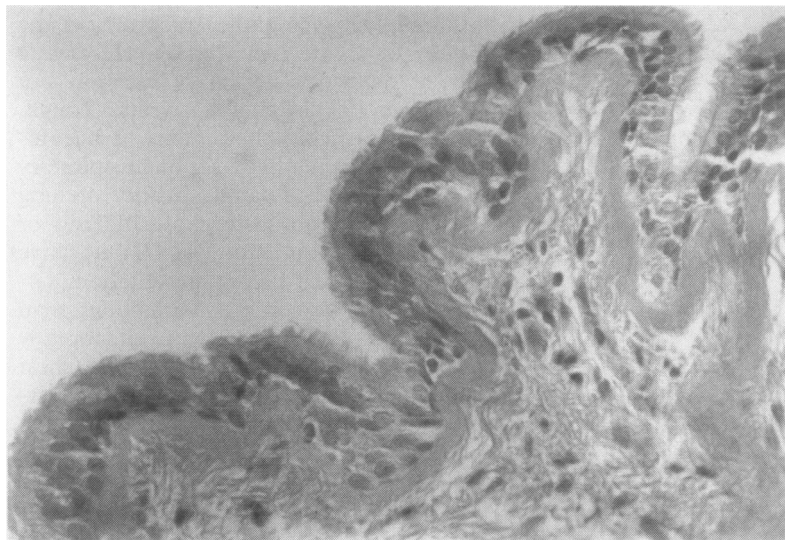


Figure 2 Photomicrograph of the cyst wall showing pseudostratified ciliated respiratory mucosa. Stain: haematoxylin and eosin.

children and adults.³⁻⁶ The more frequent occurrence of these cysts in infants has never been adequately explained, but it has been attributed to the narrower bronchial lumen and the greater compressibility of the bronchial wall allowing obstruction to occur more easily in this age group.⁴ Identifying the bronchial connection is difficult⁵ and it was not located in our case.

In the adult the differential diagnosis of a giant thin walled air filled cavity includes a bronchogenic cyst, an infected lesion, a bulla, a tension pneumothorax, a pneumatocele, and a diaphragmatic hernia with air filled loops of bowel.²⁷ An emphysematous bulla was the preoperative diagnosis, but thoracotomy revealed an air filled structure grossly resembling a cyst rather than a bulla. A lobectomy was therefore performed as the procedure of choice.⁸ Histopathological

examination revealed pseudostratified ciliated columnar epithelium consistent with a bronchogenic cyst.⁷ Although a healed abscess may occasionally epithelialise with pseudostratified ciliated epithelium,⁹ we believe this is unlikely in our case since there was no history of prior respiratory illness.

Bronchogenic cysts were thought to present incidentally on chest radiographs or at necropsy in adults.² More recent reports, however, have shown that most cysts present with symptoms or become symptomatic.^{4,8} In a large series by St-George *et al* 82% of bronchogenic cysts produced symptoms, complications, or both. In their series most patients with parenchymal cysts had cough, fever, and purulent sputum due to infection within or surrounding the cyst.⁸ Infection of the cyst, with formation of a fistula into a bronchus or the adjacent lung parenchyma, was present in 13 of 20 patients. Because of the frequency of complications and the poor operative outcome, resection is recommended for all presumed bronchogenic cysts in the adult.

- 1 Anspach WE, Wolman IJ. Large pulmonary air cysts of infancy: with special reference to the pathogenesis and diagnosis. *Surg Gynecol Obstet* 1933;56:635-45.
- 2 Maier HC. Pulmonary cysts. *Am J Surg* 1941;54:68-81.
- 3 Berg RA. Giant congenital bronchogenic cyst, "pseudopneumothorax". *Postgrad Med* 1970;48:121-6.
- 4 Gourin A, Garzon AA, Rosen Y, Lyons HA. Bronchogenic cysts. Broad spectrum of presentation. *NY State J Med* 1976;76:714-9.
- 5 Ofoegbu RO. Intraparenchymal bronchogenic cysts in adults. *Thorac Cardiovasc Surg* 1982;30:298-301.
- 6 Dahmash NS, Chen JT, Ravin CE, Reed JC, Pratt PC. Unusual radiologic manifestations of bronchogenic cyst. *South Med J* 1984;77:762-4.
- 7 Rogers LF, Osmer JC. Bronchogenic cyst. A review of 46 cases. *AJR* 1964;91:273-93.
- 8 St-George R, Deslauriers J, Duranceau A, Vaillancourt R, Deschamps C, Beauchamp G, *et al*. Clinical spectrum of bronchogenic cysts of the mediastinum and the lung in the adult. *Ann Thorac Surg* 1991;52:6-13.
- 9 Pryce DM. The lining of healed but persistent abscess cavities in the lung with epithelium of the ciliated columnar type. *J Pathol Bacteriol* 1948;60:259-64.