

Diverticulosis of the main bronchi: a rare cause of recurrent bronchopneumonia in a child

A Barbato, A Novello Jr, D Zanolin, P Corner, E Talenti

Abstract

Diverticulosis of the main bronchi, not associated with other organ abnormalities, developed in a 12 year old child. This abnormality caused recurrent bronchopneumonia in the lung with the main bronchi diverticulosis. Fibreoptic bronchoscopy helped to locate the lesion and selective bronchography, with injection of contrast medium through the suction channel of the fibreoptic bronchoscope, showed the morphology of this rare malformation.

(Thorax 1993;48:187-188)

Congenital anomalies of the large bronchi are rare in childhood. They include bronchomalacia,¹ congenital bronchial stenosis,² bronchobiliary fistulas, bronchogenic cysts, oesophageal cysts associated with broncho-oesophageal fistulas,² and bronchial atresia.³ We report a clinical case of diverticulosis of the large bronchi, diagnosed from bronchographic and bronchoscopic data; no other such case to our knowledge has been published.

Case report

A 12 year old white boy was admitted to a peripheral hospital with bronchopneumonia of the left lung, which had recurred frequently since the age of 4. Because of these recurrent infections he was transferred to our department for further investigation. He had no family history of lung disease. His birth weight was within the normal range and he was normal in the perinatal period. The infectious diseases he contracted were chickenpox and measles; whooping cough was excluded.

On admission he was of normal height and weight. He had no finger clubbing, nor was he dyspnoeic at rest or with mild exertion. His chest shape and expansion were normal and inspiratory crepitations were heard on auscultation of the left lower lobe. Physical examination otherwise showed no abnormality, and routine blood counts, biochemical investigations, and chest radiography gave normal results. Echocardiography and ab-

dominal ultrasound showed normal appearances. Spirometry showed a mildly obstructive pattern. His sweat test gave a normal result, and serum immunoglobulins and lymphocyte subtype counts were normal.

Bronchoscopy, performed with an Olympus BF-P-10 bronchoscope, showed many small invaginations on the bronchial wall around the main carina, and fewer invaginations in the right and left main bronchi. A large orifice was located on the medial wall of the left main bronchus (fig 1). At their orifices the basal segmental bronchi in the left and right lower lobes were reduced in calibre by 10% as a result of medially located translucent, falciform pseudomembranes.

Bronchography of the left lower lobe bronchus, performed with 10 ml of Hytrast (diiodopiridone) injected via a catheter, showed no abnormalities except for small rugosities of the wall. The patient was discharged and given cyclic antibiotic treatment and physiotherapy. After six months of recurrent respiratory symptoms we decided to readmit him for biopsy of the bronchial wall and to obtain a more proximal bronchogram showing the area with the large abnormal orifice. The bronchogram performed with Hytrast injected via the suction channel of the Olympus BF-P-10 bronchoscope, with its end located in the left main bronchus, showed a large diverticulum of the left main bronchus and a small diverticulum of the right main bronchus (fig 2).

Histological examination of biopsy specimens taken within the diverticula showed normal bronchial mucosa and electron microscopy showed normal morphology of the cilia.

Discussion

Diverticulosis of the tracheobronchial tree is extremely rare in paediatrics. The only previously reported case was in a child who died at the age of 25 days, who had a right sided tracheal diverticulum as well as many other malformations.⁴

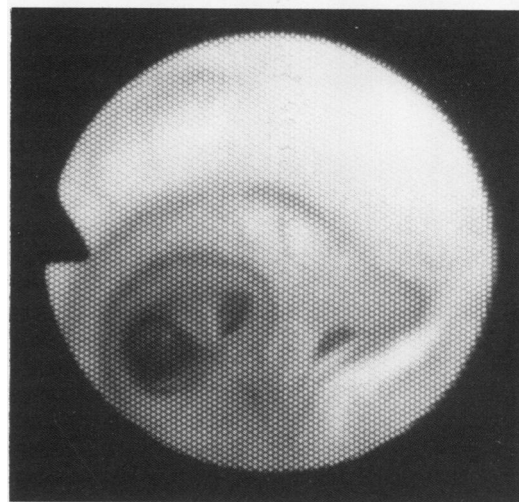


Figure 1 Cribiform membrane shown by bronchoscopy on the medial wall of the main bronchus, which separates the diverticular cavity from the bronchial lumen.

Department of Paediatrics

A Barbato
A Novello Jr
D Zanolin
P Corner

Institute of Radiology

E Talenti

University Hospital, Padua, Italy

Reprint requests to:
Professor A Barbato,
Department of Paediatrics,
via Giustiniani 3,
35128 Padua, Italy.

Received 19 December 1991

Returned to authors

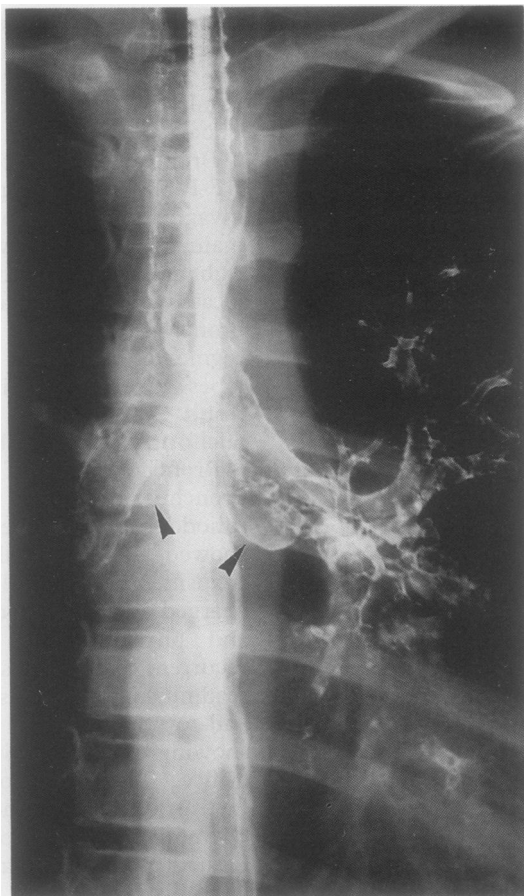
30 January 1992

Revised version received

24 February 1992

Accepted 27 February 1992

Figure 2 Main bronchial diverticulum seen by bronchography to be communicating with the medial wall of the left main bronchus (arrow). A small diverticulum is communicating with the medial wall of the right main bronchus (arrow).



In our young patient these bronchial anomalies were associated with recurrent infections of the lower airways, which were more severe in the left lung, the site of the larger diverticulum. During the investigation of this case endoscopy was a great diagnostic aid, even though the exact pathological picture and the morphology of the major lesions could be understood only with bronchography. The use

of bronchography in childhood is controversial^{5,6}; this is one case in which it was necessary for the definitive diagnosis. Another important finding was the value of selective bronchography with a fiberoptic bronchoscope in showing diverticula arising from the main bronchi.

Bronchial diverticulosis may be due to "abnormal budding" of the bronchial tree, possibly stimulated by an infectious agent acting during the embryogenic phase.⁷⁻⁹ The same cause could have spread in patchy fashion from the major site of action to the rest of the bronchial mucosa. This also explains the small invaginations evident only from fiberoptic bronchoscopy.

The paediatric surgeons did not wish to attempt surgical repair of the major malformations. We are treating the frequent recurrence of pulmonary infections in this child with cycles of antibiotics and physiotherapy.

- 1 Wood R. Localized tracheomalacia or bronchomalacia in children with intractable cough. *J Pediatr* 1990;116:404-6.
- 2 Kendig EL, Chernick V. *Disorders of the respiratory tract in children*. Philadelphia: Saunders, 1980:244-7.
- 3 Asada M, Yano S, Okavasu K, Tanabe T, Hiraga T, Kawakami Y. A case report of congenital bronchial atresia—review of 43 cases in Japan. *Nippon Kyobu Geka Gakkai Zasshi* 1991;39:463-8.
- 4 Rosenberg HS, Bolande RP. *Perspectives in pediatric pathology*. Vol 1. Chicago: Year Book Medical Publishers, 1973:1-32.
- 5 Avery ME. Bronchography: outmoded procedure? *Pediatrics* 1970;46:333-4.
- 6 Levy M, Glick B, Springer C, Mogle P, Vatahsy E, Drexler H, et al. Bronchoscopy and bronchography in children. *Am J Dis Child* 1983;137:14-6.
- 7 Lallemand D. Les malformations tracheobronchiques rares ou asymptomatiques. *Traité de Radiodiagnose* 1977;19:287-90.
- 8 Jaubert F, de Blic J. Malformations de l'appareil respiratoire. *Encycl Med Chir (Paris, France) Poumon* 1989;9:1-10.
- 9 Gaultier Cl. Développement post-natal du poumon et exploration fonctionnelle respiratoire chez le nourrisson et l'enfant. *Encycl Med Chir (Paris, France) Pédiatrie* 1987;7:1-9.