

# Congenital bronchial atresia with regional emphysema associated with pectus excavatum

R J van Klaveren, W J Morshuis,  
L K Lacquet, A L Cox, J Festen,  
F M J Heystraten

## Abstract

**Two cases of congenital bronchial atresia with pectus excavatum are reported. Costosternal retraction during the efforts to overcome the airway obstruction due to encroachment on normal lung tissue by the hyperinflated segments may play a part in causing pectus excavatum.**

(Thorax 1992;47:1082-1083)

Congenital bronchial atresia, representing one cause of congenital regional emphysema, is a rare anomaly. Since the first description by Ramsay and Byron in 1953<sup>1</sup> 87 cases have been reported.<sup>2</sup> To our knowledge this is the first report of congenital bronchial atresia associated with pectus excavatum. We discuss the possible cause and effect relationship and the indications for surgical treatment.

## Case reports

### PATIENT 1

A 23 year old woman was admitted for correction of pectus excavatum in 1980. She had had recurrent bronchopulmonary infections, dyspnoea, chest pain, and psychological problems associated with her pectus excavatum. Physical examination showed an asymmetric pectus excavatum with the deepest impression on the right side. On the chest radiograph there was loss of normal lung markings in the right upper and mid zones and a low grade opacity mass lesion in the area of the right hilum (figure). Bronchography and bronchoscopy showed atresia of the anterior segmental bronchus of the right upper lobe. Pulmonary angiography showed downward displacement of the middle and lower lobe arteries due to emphysema in the upper lobe. For psychological reasons correction of the pectus deformity was performed. In the same session the hyperinflated right anterior segment and posterior subsegment were resected to prevent further bronchopulmonary infections. Examination of the specimen showed a proximal blind ending bronchus with a mucocoele. Distally very small bronchi up to 3 mm in diameter were seen to be connected with emphysematous, deformed alveoli. Some of the distal bronchi did not contain cartilage.

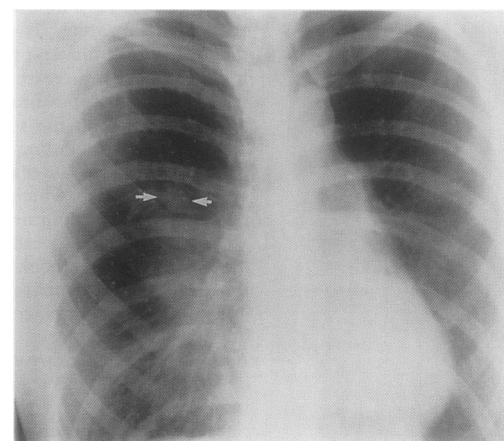
### PATIENT 2

A 7 year old boy was admitted in December 1981 for correction of pectus excavatum for psychological reasons. The deformity had been present at birth, but had become worse over the previous two years. He was symptom free. Physical examination showed an asymmetric pectus excavatum with the deepest impression on the left side. A chest wall correction was performed. Postoperatively he developed recurrent bronchopulmonary infections and a left sided tension pneumothorax. The scarce vasculature in the left upper zone on the preoperative chest radiograph, with an air-fluid level near the hilum, suggested the presence of congenital bronchial atresia. Bronchography and bronchoscopy disclosed atresia of the left upper lobe bronchus. Scintigraphy showed that there was no perfusion or ventilation in the affected area. In July 1982 left upper lobectomy was performed. Examination of the specimen showed bronchial atresia with a central mucocoele of 3.5 × 2.7 cm and alveolar emphysema.

## Discussion

Congenital bronchial atresia is a rare anomaly characterised by normal bronchial ramification from a central blind bronchial sac filled with mucus (mucocoele). The regional hyperinflation is due to a check valve mechanism in the collateral ventilation through the alveolar pores of Kohn, the bronchoalveolar channels of Lambert, or the interbronchiolar channels. It usually affects one or two segments of a lobe, and is more common on the left side.<sup>3</sup> Unlike other patients with congenital regional emphysema, who often show life threatening respiratory distress and are all developing symptoms by six months of age, patients with congenital bronchial atresia are usually young adults. Sixty per cent are symptomless, their anomaly being discovered on a routine chest radiograph.<sup>3</sup> Although we used bronchography for diagnosis, computed tomography (with contrast if necessary) is now the diagnostic test of choice.<sup>3</sup>

A cause and effect relationship between an airway abnormality and pectus excavatum has



*Hyperlucency in the right upper and middle lung field: mass lesion (mucocoele) above the right hilum (arrows).*

**Department of  
Pulmonary Medicine**  
R J van Klaveren  
A L Cox  
J Festen

**Department of  
Thoracic and Cardiac  
Surgery**  
L K Lacquet  
W J Morshuis

**Department of  
Radiology**  
F M J Heystraten

**University Hospital  
Nijmegen, Nijmegen,  
The Netherlands**

Correspondence to:  
Dr R J van Klaveren,  
University Lung Centre  
Dekkerswald, University of  
Nijmegen, Nijmeegsebaan  
31, 6560 GB Groesbeek, The  
Netherlands

Received 11 November  
1991

Returned to authors  
17 January 1992

Revised version received  
3 February 1992

Accepted 4 February 1992

been reported before. An increased negative intrathoracic pressure during inspiration to overcome airway obstruction has been suggested as resulting in costosternal retraction.<sup>4</sup> It was found that relief of airway obstruction by tonsillectomy or surgical treatment of laryngomalacia resulted in resolution of pectus excavatum.<sup>4</sup> In asthmatic children the prevalence of pectus excavatum was found to be two to three times greater than even the highest prevalence in the normal population.<sup>5</sup> Godfrey reported four children with pectus excavatum and a collapsible segment in the main bronchus due to lack of cartilage support.<sup>6</sup> A relationship between pectus excavatum and congenital regional emphysema was suggested by Shaw.<sup>7</sup> Whether pectus excavatum can be solely ascribed to an underlying lung abnormality is, however, questionable. Overgrowth of the costal cartilage has been generally accepted as a causative mechanism of pectus excavatum.<sup>8</sup> Decreased mechanical stability as a result of age dependent morphological and biochemical changes found in costal cartilage does account for the progression of asymmetry with increasing age.<sup>9</sup> In patients with congenital bronchial atresia costosternal retraction during the efforts to overcome airway obstruction due to encroachment of the hyperinflated segments on normal lung tissue may aggravate the natural course of pectus excavatum. This theory might be supported by the fact that the side of the deeper impression corresponds with the side of the congenital bronchial atresia.

When congenital bronchial atresia gives rise to symptoms (recurrent bronchopulmonary infections, dyspnoea, chest pain) surgical treatment should be undertaken.<sup>3</sup> The treatment of symptomless patients, however, is controver-

sial. Because 85% of them have been operated on in the past, the natural history is unknown.<sup>3</sup> Recurrent bronchopulmonary infections, pneumothorax, or encroachment on normal lung tissue by the hyperinflated lung might occur and justify surgical excision to avoid such complications in future. When pectus excavatum is present we advise operating on congenital bronchial atresia at the same session. The optimal age for operating on pectus excavatum is 5–10 years.<sup>10</sup> Careful examination of the routine chest radiograph should be performed in patients with pectus excavatum to exclude the possible presence of congenital bronchial atresia.

- 1 Ramsay BH, Byron FX. Mucocèle, congenital bronchiectasis and bronchogenic cyst. *J Thorac Surg* 1953;26: 21–30.
- 2 Aalbers R, Postmus PE, vd Jagt ES. Congenital bronchial atresia in a 66-year old man. *Eur J Respir Dis* 1987;71: 127–9.
- 3 Jederlinic PJ, Sicilian LS, Baigelman W, Gaensler EA. Congenital bronchial atresia. A report of 4 cases and a review of the literature. *Medicine* 1986;65:73–83.
- 4 Lane RW, Weider DJ, Steinem C, Marin-Padilla M. Laryngomalacia: a review and case report of surgical treatment with resolution of pectus excavatum. *Arch Otolaryngol* 1984;110:546–51.
- 5 Cserhati EF, Gegesi-Kiss A, Poder G, Mezie G, Kelemen J, Puskas J. Thorax deformity and asthma bronchiale. *Allergol Immunopathol (Madr)* 1984;12:7–10.
- 6 Godfrey S. Association between pectus excavatum and segmental bronchomalacia. *J Pediatr* 1980;96:649–52.
- 7 Shaw RR. Localized hypertrophic emphysema. *Pediatrics* 1952;9:220–7.
- 8 Sanger PW, Taylor FH, Robicsek F. Deformities of the anterior wall of the chest. *Surg Gynec Obstet* 1963;16: 515–22.
- 9 Geisbe H, Mildenerberger H, Flach A, Fendel H. The aetiology and pathogenesis of funnel chest. *Prog Pediatr Surg* 1971;3:13–7.
- 10 Lacquet LK. Congenital deformities of the anterior chest wall. In: Grillo MC, Eschappasse H, eds. *International trends in general thoracic surgery*. Vol 2; Major challenges. Philadelphia: Saunders, 1987:328–37.