

## Short reports

### Asthma, pulmonary eosinophilia, and eosinophilic pericarditis

OMP JOLOBE, SC MELNICK

From the Department of Medicine, Dudley Road Hospital, Birmingham

Eosinophilic pericardial effusion is a rare condition. The case we report is the second example of its association with asthma and pulmonary eosinophilia.

#### Case report

A 32 year old Punjabi woman with a three year history of asthma (including one episode of status asthmaticus) was found to have radiological pulmonary infiltration and an eosinophil count of  $4.65 \times 10^9/l$ , with a white blood count (WBC) of  $15.0 \times 10^9/l$  during an asthmatic relapse. The infiltrates resolved and the asthma improved after treatment with prednisolone 40 mg/day. A month later, while she was taking only beclomethasone dipropionate powder, 200  $\mu g$  four times daily by inhalation, she developed chest pain, dyspnoea, and streaky haemoptysis. A chest radiograph showed an enlarged cardiac silhouette and bilateral basal effusions (fig 1). Echocardiography confirmed the presence of a pericardial effusion but there was no evidence of endocardial or myocardial abnormality. The

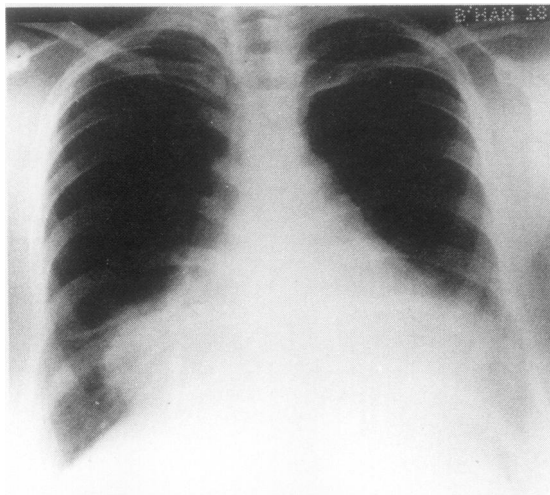


Fig 1 Chest radiograph showing a pericardial effusion and bilateral pleural effusions.

blood eosinophil count was  $6.22 \times 10^9/l$ , WBC  $12.2 \times 10^9/l$ , platelet count  $193 \times 10^9/l$ , erythrocyte sedimentation rate (ESR) 36 mm in one hour (Westergren). The haemoglobin concentration was 9.2 g/dl, serum iron 3.5  $\mu mol/l$ , total iron binding capacity 92.8  $\mu mol/l$ . She had right subcostal pain, and one out of six stool specimens were positive for occult blood. Sigmoidoscopy and radiological examination of the entire gastrointestinal tract showed no abnormality; ultrasonography showed a thick walled gall bladder without calculi. Pericardial aspiration yielded 540 ml of straw coloured fluid, which on microscopic examination was found to contain many eosinophils (fig 2). An appreciable decrease in the heart shadow occurred only after treatment with prednisolone (60 mg/day for seven days and 30 mg/day for a further seven days). Serum precipitins against *Aspergillus* species were not found and stool examinations for parasite ova were repeatedly negative. The serological tests for antinuclear factor and for filaria and the hepatitis B antigen test gave negative results. Immune complexes were present in a titre of 1/320 (platelet aggregation test) and the result of the rheumatoid arthritis latex fixation test was positive (titre 1/160, later falling to 1/40) although the patient had no arthritic symptoms and no stigmata of rheumatoid arthritis. There were no skin lesions, and no aneurysms or vasculitic lesions were seen on superior mesenteric and coeliac axis angiography. Six weeks after commencement of prednisolone, when the daily dose was 20 mg, the heart shadow was normal; the eosinophil count was  $76/mm^3$  and the ESR was 9 mm in one hour. Streaky haemoptysis and blood eosinophilia of  $960/mm^3$  recurred two weeks after she had inadvertently stopped taking prednisolone. She is now on a maintenance dose of 15 mg/day, and her haemoglobin is 11.6 g/dl, WBC  $8.6 \times 10^9/l$ , eosinophil count  $430/mm^3$ , ESR 18 mm in one hour. Bone marrow examination showed normal maturation of the red cell and neutrophil series. Fifteen per cent of the cells in the marrow were eosinophils, which were either mature or at the myelocytic stage. Pulmonary function test results were as follows (normal values in parentheses):  $FEV_1 = 1.75 l$  (2.68 l); forced vital capacity = 2.75 l (3.05 l), increasing to 2.05 l and 2.90 l respectively after 5 mg nebulised salbutamol. Transfer coefficient for carbon monoxide =  $1.97 mmol/min^{-1} kPa^{-1}/l^{-1}$  ( $1.84 mmol/min^{-1} kPa^{-1}/l^{-1}$ ).

#### Discussion

The present case report is the fifth report of eosinophilic

Address for correspondence: Dr OMP Jolobe, Selly Oak Hospital, Raddlebarn Road, Selly Oak, Birmingham B29 6TD

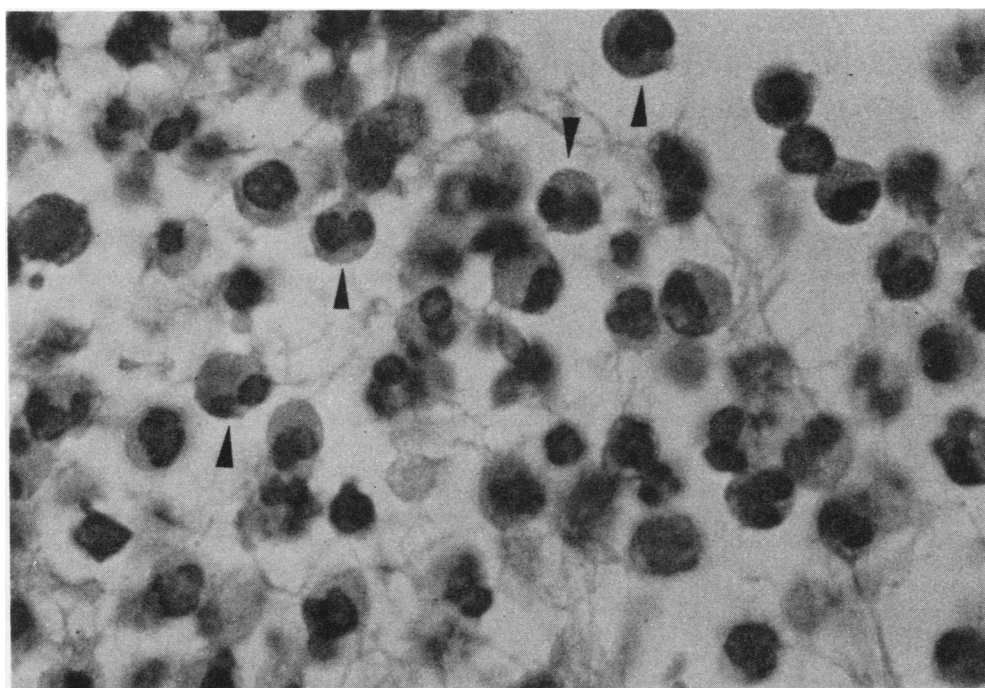


Fig 2 Photomicrograph of eosinophils in the pericardial fluid. Arrows indicate some typical eosinophils, recognisable here by their bilobed nuclei. About 80% of cells in the pericardial fluid are eosinophils. (Haematoxylin and eosin,  $\times 500$ .)

pericarditis in the literature. Our case, like the patient described by Slater,<sup>1</sup> initially had asthma and this was followed by pulmonary eosinophilia and by eosinophilic pericarditis. Only the latter two features were present in the case reported by Hall *et al.*<sup>2</sup> The other two reported examples of eosinophilic pericarditis occurred in patients with lymphosarcoma<sup>3</sup> and Hodgkin's disease<sup>4</sup> respectively.

Cardiac disease in asthmatics with eosinophilia may take the form of endomyocardial eosinophilic infiltration<sup>5</sup> or eosinophilic pericarditis.<sup>1</sup> The latter has been reported only as a complication of a systemic hypersensitivity reaction to sodium cromoglycate, a drug which had never been taken by our patient. In the presence of multisystem disease manifested by haemoptysis and non-calculous cholecystitis, vasculitis of the polyarteritis nodosa type seemed possible but we lacked histological proof.

## References

- <sup>1</sup> Slater E. Cardiac tamponade and peripheral eosinophilia in a patient receiving cromolyn sodium. *Chest* 1978;**73**:878-9.
- <sup>2</sup> Hall JW, Kozak M, Spink WW. Pulmonary infiltrates, pericarditis and eosinophilia. 1964;**36**:135-43.
- <sup>3</sup> Henderson AH, Mejia G. Malignant lymphoma presenting with eosinophilia, eosinophilic pleurisy and pericarditis. *Thorax* 1969;**24**:124-5.
- <sup>4</sup> Merab A, Taleb R, Saliby E, Elaine E, Naffiah MJ, Kyriakos S. Les pericardites Hodgkiennes. *Sem Hôp Paris* 1959;**35**:2590.
- <sup>5</sup> Frenkel R, Grieco MH, Garret R. Loeffler's endomyocarditis associated with bronchial asthma and eosinophilia. *Ann Allergy* 1975;**34**:213-8.