

Spontaneous dissection of the oesophagus

G N MORRITT AND P R WALBAUM

From the Thoracic Surgical Unit, City Hospital, Edinburgh

ABSTRACT Spontaneous rupture of the oesophagus is a well-known entity. Partial or intramural rupture of the oesophagus has been described but is not so well known, and the purpose of this paper is to draw attention to this condition. The clinical presentation, radiological appearances, and treatment of two such cases are described.

Spontaneous perforation of the oesophagus was first described by Boerhaave in 1724.¹ When Barrett reported three cases of spontaneous rupture of the oesophagus and reviewed the published cases in 1946 there was a total of 50 cases.² The next year Barrett reported the first successful repair of a spontaneous oesophageal perforation.³ In a more recent review there was a total of 300 reported cases.⁴ Usually the rupture is complete. However, it is possible for the oesophageal rupture to be intramural—that is, rupture of the mucosa alone leaving the muscle wall intact, with dissection of the mucosa off the muscle layer. This is a rare condition and has been described after instrumentation of the oesophagus.⁵ A few cases of spontaneous intramural dissection of the oesophagus have been described.⁶⁻⁸ We describe a further two cases.

Case reports

CASE 1

A 72-year-old woman felt nauseated after a large meal and shortly afterwards vomited profusely ("as if I was bringing up all the food I had eaten in the last two days") and experienced severe pain in the epigastrium radiating along the right costal margin which doubled her up and caught her breath. The severe pain lasted only a few minutes but she continued to have aching pain and retrosternal pain on swallowing. Twenty minutes later she vomited again and on this occasion there was blood in the vomit.

Over the next two days she felt very unwell but the pain on swallowing eased off and she was able to take liquids by mouth.

Address for reprint requests: Dr GN Morritt, Senior Registrar, Cardiothoracic Surgery, Freeman Hospital, High Heaton, Newcastle upon Tyne NE7 7DN.

She was admitted to hospital two days after the event. Clinical examination revealed no abnormality. In particular there was no surgical emphysema and no epigastric tenderness. A chest radiograph was normal. Barium meal showed a small sliding hiatus hernia and filling defects with an irregular posterior margin, the appearances being consistent with partial rupture. Oesophagoscopy was performed with a rigid instrument. At 28 cm from the upper alveolus there was a bulge in the posterior wall of the oesophagus and the overlying mucosa was purplish in colour. The oesophagoscope was not passed beyond this point. The appearances were those of an extensive submucosal haematoma probably the result of rupture of the oesophageal mucosa. No tear was seen. She was treated conservatively with intravenous fluids and no oral intake for four days. Her symptoms improved. Oral fluids introduced after this were well tolerated. She was discharged home in good health and swallowing normally on the fifteenth day after admission.

CASE 2

A 68-year-old widowed pensioner was admitted to hospital. She had no previous history of symptoms related to her upper gastrointestinal tract and had been in normal health except for episodes of chest discomfort which were diagnosed as angina. At 1800 on the day of admission she had her usual tea of scrambled eggs and toast. About an hour later she experienced retrosternal discomfort which was followed by repeated swallowing and belching of air. The retrosternal discomfort developed into an acute pain which was made worse by swallowing. She was seen by her family doctor 45 minutes later, by which time she was still in intense pain and was cold and sweaty. A diagnosis of possible myocardial infarction was made and

she was transferred to the local hospital's coronary care unit.

The next morning she regurgitated 10 ml of blood-stained saliva. She continued to complain of pain on swallowing. Serial electrocardiograms and cardiac enzymes showed no abnormality. She was kept under observation and given a normal diet. During the next five days she continued to experience dysphagia at mid-sternal level. On the sixth day after admission, a barium swallow examination was undertaken. This showed contrast medium outside the lumen of the oesophagus (fig 1) and she was transferred to the Thoracic Surgical Unit.

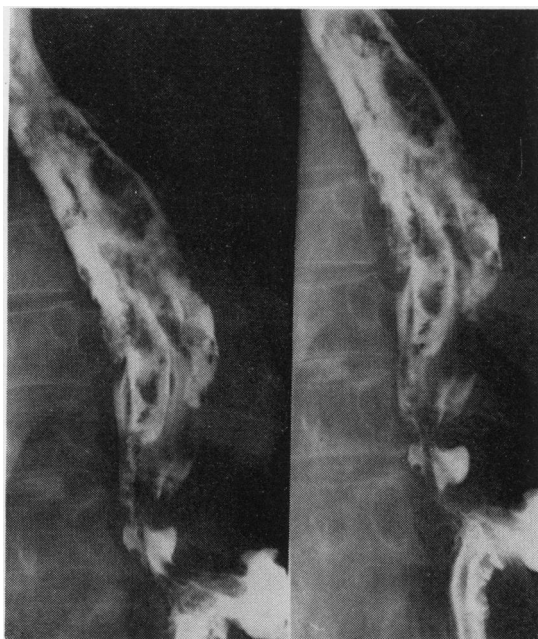


Fig 1 Barium swallow study six days after partial rupture showing contrast medium within the wall of the oesophagus.

On admission she was an obese woman in no obvious discomfort. She was afebrile, the pulse rate was 68 per minute and regular, her blood pressure was 170/90 mmHg, her jugular venous pressure was not raised, and there was no ankle oedema. There was no surgical emphysema in the neck. The heart sounds were normal. All peripheral pulses were palpable. Examination of the respiratory system was normal and her abdomen was soft. Her haemoglobin was 12.9 g/dl and WBC $5.4 \times 10^9/l$ with a normal differential count. Her only complaint was of retrosternal pain related to swallowing. The chest radiograph was normal and

in particular there was no evidence of pneumothorax, pleural effusion, or surgical emphysema in the neck or mediastinum. The barium swallow examination was repeated and showed that the contrast medium entered and collected within the wall of the oesophagus over a 7 cm length, approximately midway between the carina and the diaphragm. There was no free perforation.

On reviewing the films of the first barium examination intraluminal filling defects were seen—these probably represented blood clots that were present at that time and which had since cleared. In view of these findings a diagnosis of incomplete or intramural rupture of the oesophagus was made and she was treated conservatively with intravenous fluids and oral intake was withheld. Her dysphagia improved over the next days. Barium examination was repeated eight days later and was completely normal (fig 2). A normal diet was resumed and she was discharged from hospital in good health.

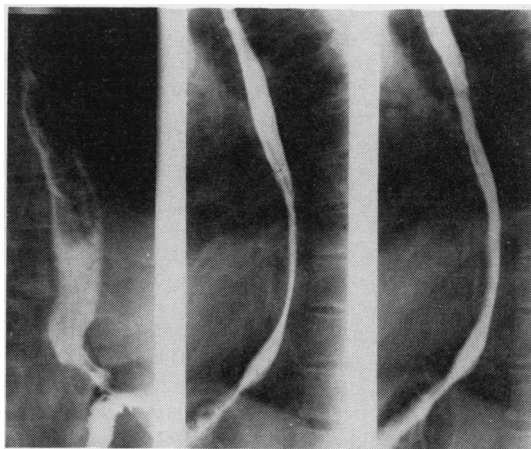


Fig 2 'Normal appearances' 16 days after spontaneous dissection.

Discussion

In 1968 the first case report of a spontaneous intramural oesophageal perforation was made from Capetown by Marks and Keats.⁷ Over the subsequent two years there were further case reports.^{6 9 10} These cases illustrate the essential features of the condition. The patients did not have any pre-existing oesophageal disease. They presented with discomfort in the retrosternal region which was not usually related to a meal. The discomfort occurred hours later, followed by severe pain radiating to the epigastrium or the back, associated with retching and occasional

small amounts of red blood in the vomit. This has to be differentiated from the Mallory Weiss Syndrome,¹² where haematemesis is the main feature, and from spontaneous complete transmural oesophageal perforation which usually occurs after a large meal followed by violent vomiting. Clinical examination reveals a low grade fever and absence of surgical emphysema in the neck. The chest radiograph is usually normal. The radiological changes produced by intramural dissection of the oesophagus may show a striking similarity to the typical findings in dissecting aneurysm of the aorta. The true and false oesophageal lumina may be demonstrated, separated by a mucosal stripe resembling the appearance of the intima in aortic dissection.¹¹ There may be longitudinal filling defects which represent blood clot in the oesophageal wall. Subsequent films will show contrast medium remaining in the oesophageal wall (fig 1). In addition there is absence of normal peristalsis over the affected area. These patients respond to conservative treatment—that is, antibiotics, withholding oral fluids, bed rest, and intravenous fluids. A repeat barium swallow usually shows a normal contour to the oesophagus some days later.

In our first case vomiting occurred one hour after a large meal and was followed by severe epigastric and retrosternal pain associated with dysphagia, which persisted for several days. Oesophagoscopy and barium swallow were diagnostic. In our second case there was no vomiting. Retrosternal pain occurred an hour after the last meal. In both cases there was a history of regurgitation of a small amount of red blood hours after the onset. The first case was correctly diagnosed. In the second case a diagnosis of myocardial infarction was made, despite the absence of supporting ECG and enzyme evidence and the presence of dysphagia and haematemesis. Spontaneous oesophageal perforation may be either complete (transmural) or incomplete (intramural/dissection). Vomiting is usually a prominent feature of the

former variety. Constant retrosternal pain with severe dysphagia for liquids without clinical and radiological abnormalities (on the chest radiograph) are the hallmarks of the latter variety. It is important to make the distinction between the two types of oesophageal perforation because the treatment in the first is operative whereas in the latter it is conservative.

References

- 1 Derbes VJ, Mitchell RE. Hermann Boerhaave's "Atrocis, nec Descripti Prinus Morbi Historia" first translation (from Latin, 1724) of classic case report of rupture of oesophagus, with annotations. *Bull Med Lib. Assoc* 1955; **43**:217.
- 2 Barrett ND. Spontaneous perforation of oesophagus—review of literature and report of three new cases. *Thorax* 1946; **1**:48–70.
- 3 Barrett NR. Successful treatment of spontaneous perforation of oesophagus. *Br J Surg* 1948; **35**:216–9.
- 4 Michaeliewicz R, Sherf S, Gilon E. Spontaneous rupture of the oesophagus. *Harefuah* 1975; **89**:247–8, 292 (Hebrew).
- 5 Lichter I, Borrie J. Intramural oesophageal abscess. *Br J Surg* 1965; **52**:185–8.
- 6 Borrie J, Sheat J. Spontaneous intramural oesophageal perforation. *Thorax* 1970; **25**:294–300.
- 7 Marks IM, Keat AD. Intramural rupture of the oesophagus. *Br Med J* 1968; **3**:536–7.
- 8 Itai Y. Submucosal dissection of the oesophagus—a case report. *Rinsho Hohasen* 1977; **22**:231–5.
- 9 Talley NA, Nicks R. Spontaneous submucosal haematoma of the oesophagus: "oesophageal apoplexy." *Med J Aust* 1969; **2**:146–50.
- 10 Joffe N, Millan VG. Post emetic dissecting intramural haematoma of the oesophagus. *Radiology* 1970; **95**:372–80.
- 11 Lowman RM, Goldman R, Stern H. The roentgen aspects of intramural dissection of the oesophagus. *Radiology* 1969; **93**:1329–31.
- 12 Mallory GK, Weiss S. Haemorrhage from laceration of the cardiac orifice of the stomach due to vomiting. *Am J Med Sci* 1929; **178**:506–15.