

## DOUBLE AORTIC ARCH IN AN INFANT TREATED SURGICALLY

BY

J. APLEY, F. G. M. ROSS, AND R. MILNES WALKER

*From the United Bristol Hospitals*

(RECEIVED FOR PUBLICATION FEBRUARY 26, 1957)

Among the causes of respiratory distress in infants and children must be included the interesting developmental anomalies of large arteries in the superior mediastinum. The tracheal compression which may result can cause respiratory disturbances such as dyspnoea, tachypnoea, and inspiratory retraction of the chest wall, as well as "wheeziness" or stridor. These disturbances are likely to be intensified by respiratory infection. This common and often recurrent complication, which can prove lethal, may mistakenly be considered to be the primary disorder. If the vascular anomaly is suspected a precise diagnosis can usually be made by radiological examination as described by Neuhauser (1946). It is important to make the diagnosis, because operation offers a cure.

A detailed account of this group of arterial anomalies was given by Quain (1844), who illustrated a case of double aortic arch originally described in 1737 by Hommel, an assistant of Haller. Gross (1955) has reported *inter alia* 26 patients with this abnormality. As far as we are aware, in this country only five clinical reports of the anomaly have appeared (Stevenson, 1950; Dolton and Jones, 1952; d'Abreu, Astley, and Parkes, 1952; Smithells, 1953; Jones and Walker, 1955). A further case, with dramatic improvement after surgical intervention, is described below.

### CASE REPORT

The patient was a girl, the second child in a healthy family, born at full term after an uneventful pregnancy. Delivery was normal and the birth weight was 9 lb.

A "noise in her throat" was noticed from birth. This stridor gradually became more marked and there was increasing difficulty in breathing while feeding.

On admission (May 26, 1955) under our care at 10 weeks of age, she was of good colour but below the expected weight. Stridor, most marked on inspiration, was loud and persistent. Its intensity varied with feeding or crying. There was inspiratory recession of the neck and chest wall. On clinical exami-

nation no other abnormalities were found and the chest was clear.

On radiological examination of the chest, no abnormality was shown in the size or shape of the cardiovascular outline, the mediastinum, or lung fields. A thymic shadow was present. The trachea was central, and the lateral radiographs showed variation in its calibre with differing respiratory phases. It appeared narrowed slightly from before backwards at its lower end.

The appearances after a barium swallow are illustrated in Figs. 1 and 2.

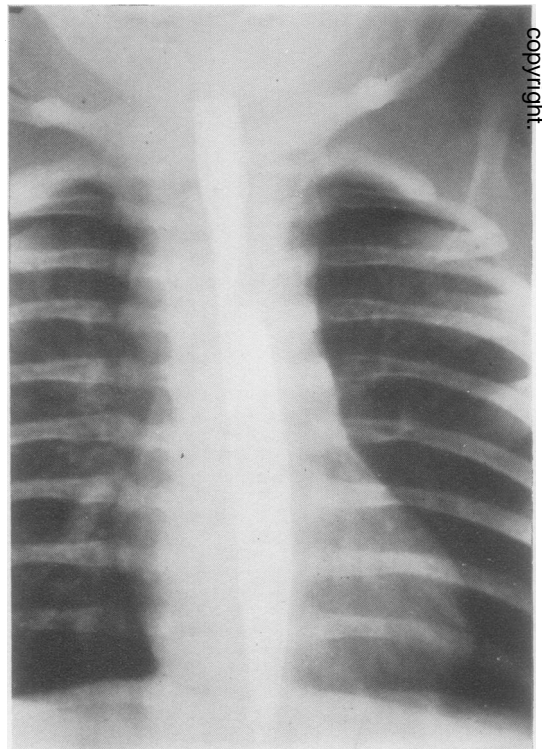


FIG. 1.—Antero-posterior view of barium swallow. At the level of D.V.3 and 4 the oesophagus is narrowed from side to side, more marked on the left. The variability of the appearances in this projection is shown by comparison with Fig. 2a.

copyright

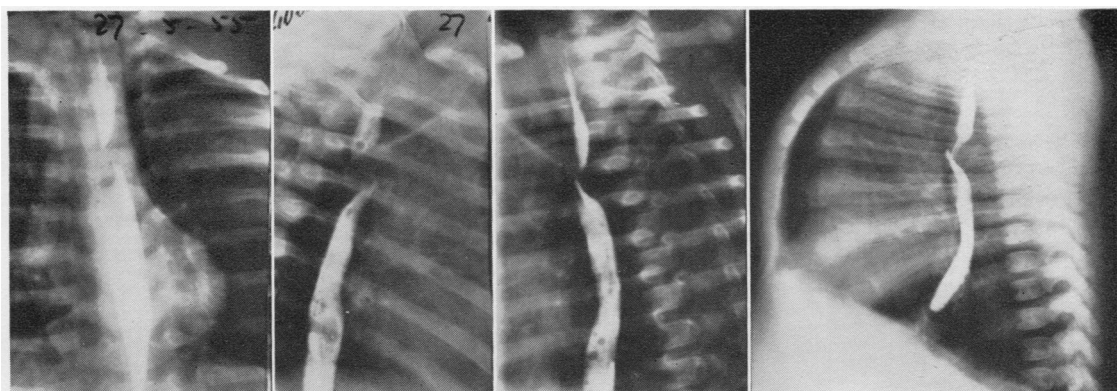
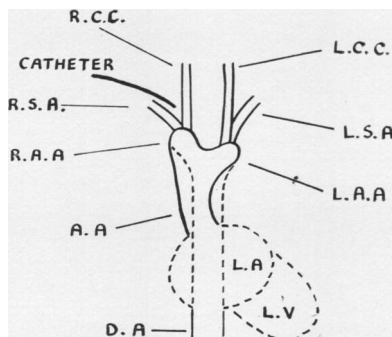


FIG. 2.—Results of barium swallow. A deep posterior impression on the oesophagus, directed obliquely downwards from left to right at an angle of 45° and about 1 cm. in width, is shown at the same level as the side-to-side narrowing. There is also anterior oesophageal displacement.



A.A. = Ascending aorta	L.S.A. = Left subclavian artery
D.A. = Descending aorta	L.V. = Left ventricle
L.A. = Left auricle	R.A.A. = Right aortic arch
L.A.A. = Left aortic arch	R.C.C. = Right common carotid artery
L.C.C. = Left common carotid artery	R.S.A. = Right subclavian artery

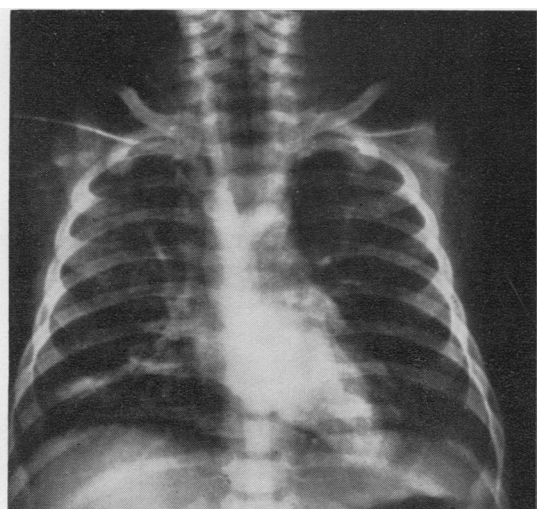


FIG. 3.—Angiocardiogram. The ascending aorta bifurcates at the level of D.V.4 into a double arch, the limbs of which are of equal calibre. The right arch is vertically directed and the left one oblique. They unite posteriorly to the right of the midline to form the descending aorta which reaches the midline in the upper abdomen.

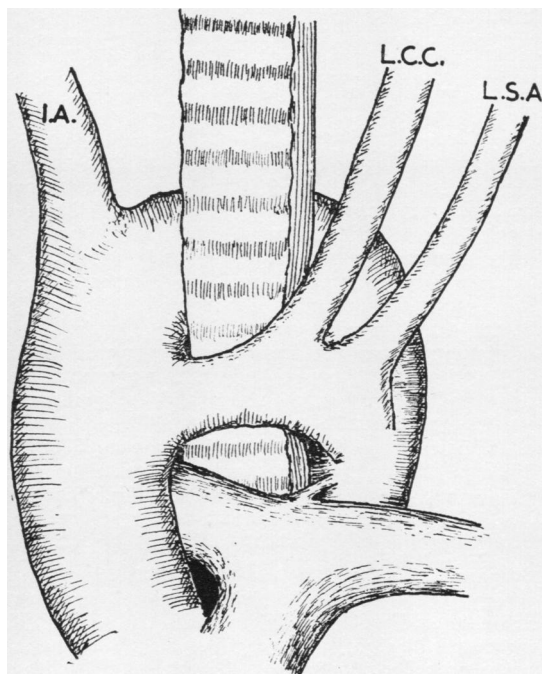


FIG. 4.—The appearance at operation.  
I.A. = Innominate artery    L.C.C. = Left common carotid artery  
L.S.A. = Left subclavian artery

Tracheography suggested some narrowing of the lower end of the trachea.

The radiological examination demonstrated a constricting vascular ring, but did not, in our opinion, determine its exact anatomical type. A double aortic arch was considered to be the most likely diagnosis.

She remained under observation for several weeks in hospital, while various modifications of feeding were made in an attempt to improve her general condition and weight. Progress was, however, extremely unsatisfactory (see Fig. 5), and feeding continued to be difficult, and indeed hazardous, because

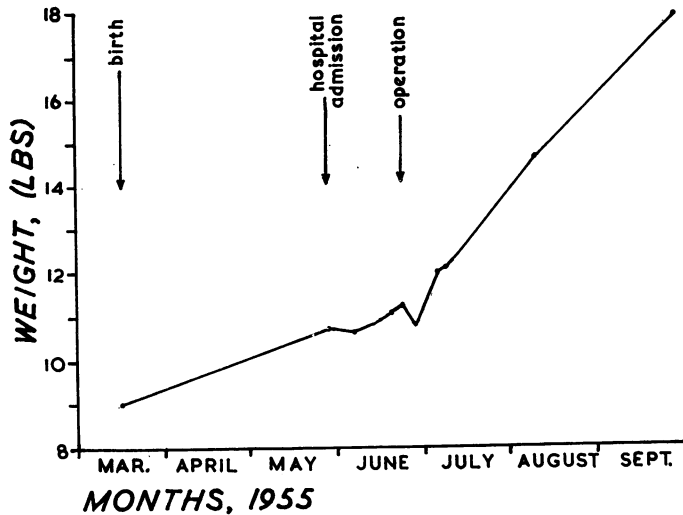


FIG. 5.—Weight Chart.

of the respiratory embarrassment. On one occasion she vomited and collapsed after being fed and urgent measures were needed to restore her. It was then decided that attempts to improve her general condition without correcting the vascular anomaly were unlikely to succeed and that early operation was necessary.

In order to determine as accurately as possible before operation the type of vascular ring, angiocardiology was performed by injecting 8.5 ml. of 70% "diiodone" through a polythene tube. Both right and left heart chambers and the pulmonary arteries were normal. Fig. 3 shows the appearances of the left side of the heart and the aorta. The two limbs of the double aortic arch encircled the oesophagus and the lower end of the trachea. The subclavian and common carotid arteries arose separately from their respective arches.

**OPERATION.**—On June 24 a left anterior thoracotomy through the second intercostal space was made, the left pleura opened, and the thymus displaced to the right. This exposed the segment of the aortic arch lying in front of the trachea with the left carotid and subclavian arteries arising from it. The arch was 1 cm. in diameter between these vessels (Fig. 4). A large vessel coming from the posterior arch

was assumed to be the innominate artery, but the angiogram suggested that, in fact, the right carotid and subclavian arteries came off the aorta as separate vessels. Ligatures were placed on the left subclavian artery and the anterior segment of the aortic arch distal to the origin of this vessel. The proximal end of the anterior arch and the left common carotid artery were temporarily controlled by clamps and the arch divided between the origins of the carotid and subclavian arteries. The two ends were closed by suture; on being released they retracted widely, exposing the trachea with the recurrent laryngeal nerve on its surface. The chest wound was closed with a temporary drain.

**POST-OPERATIVE PROGRESS.**—Her general condition improved dramatically. After the operation she could feed without difficulty or distress for the first time, and began to gain weight satisfactorily (see Fig. 5). The stridor improved more slowly. After a few weeks it was heard only with feeding, but after three months it was no longer audible, though the oesophageal deformity seen radiologically still persisted. Fifteen months after the operation she seemed a healthy, active, well-grown child with no apparent disability.

#### DISCUSSION

Herbut (1943) found two examples of double aortic arch in 5,800 unselected necropsies. Among infants with stridor, in whom one would expect a fairly high incidence of this and similar vascular anomalies, they are still relatively uncommon. In 80 children investigated for stridor, there was, in addition to one case of aberrant subclavian artery and one of anomalous innominate artery, only one vascular ring (type undetermined) (Apley, 1953).

There are several factors which evidently play a part in making double aortic arch seem rarer in clinical practice than would be expected. First, an unknown proportion of subjects with this anomaly are free from symptoms. Second, it is likely that in some patients dying of superimposed respiratory disease, an underlying arterial anomaly has not been detected. Third, some diagnosed cases are not published. The striking differences in the numbers of cases reported from different countries suggest that the apparent incidence is too low and that a considerable number remain undiagnosed.

**MORTALITY.**—It is very likely that without surgery our own patient would have died in infancy, and indeed she nearly did, because operation was

delayed while the attempt to improve her general condition was being made. There is general agreement about the considerable risk of death from acute collapse, respiratory infection, marasmus, or a combination of all these. If serious symptoms occur surgical intervention is essential to prevent sudden death or recurrent pulmonary infection (Exalto, Dicke, and Aalsmeer, 1950; Apley, 1951). A wide, non-constricting double aortic arch may produce no symptoms and be compatible with health. Curnow in 1875 described a patient with such a double arch who died at the age of 87 but had never had distress in swallowing or breathing. In the majority of cases the anomaly is a serious one.

**DIAGNOSIS.**—The diagnosis should be suggested by symptoms which arise from oesophageal or tracheal compression, and by the tendency to pulmonary complications.

Oesophageal compression is relatively unimportant, especially in infancy when the diet is exclusively fluid. A hesitation in swallowing has been described, and vomiting may occur. The common failure to thrive and gain weight is attributed to the difficulty in breathing while feeding.

The most obvious manifestation of tracheal compression is stridor, which is usually observed soon after birth. It is commonly heard both in inspiration and expiration, and is accentuated by feeding or excitement. Occasionally it is so soft as to be overlooked until pulmonary infection has supervened. With feeding or infection cyanosis may develop. The breathing is characteristically rapid, and the accessory muscles of respiration are often seen to be in action. The child may lie with the head hyperextended, presumably because in this position the trachea becomes taut and so lessens the degree of compression. Inspiratory recession of the chest wall, and the soft structures of the neck and abdomen, is commonly seen, its extent depending on the degree of tracheal narrowing.

If the diagnosis is suspected radiological investigation is essential for confirmation or exclusion. A precise diagnosis should be made before surgical intervention is attempted to decide the best means of approach and because the actual anomalies may be difficult to recognize during the operation.

**RADIOLOGICAL DIAGNOSIS.**—According to Gross (1955), the combination of a posterior impression on the barium-filled oesophagus and an anterior tracheal defect, in the absence of a tumour, is almost certain proof of the presence of some type

of encircling vascular ring. The actual site and degree of compression exerted on the trachea and oesophagus vary with the type of malformation. Usually there is little difficulty in determining the type of oesophageal compression, as the oesophagus can be well outlined by barium. It may, however, be very difficult to decide whether the trachea is compressed, because the appearance of the infant's trachea varies through the respiratory cycle and with different positions of the head. In doubtful cases tracheography should be performed, and usually a good delineation of the trachea can be obtained by this method.

The radiological appearances of double aortic arch have been reported very fully by Neuhauser (1946) and Gross (1955). The depth of the impressions, particularly on the oesophagus, gives an indication of the relative size of each arch. The left anterior arch, in the majority of patients, is the smaller.

A double aortic arch must be distinguished from other vascular anomalies. Abnormalities of origin of single arteries from the aorta, such as aberrant right and left subclavian, innominate and left carotid arteries, do not produce compression of both the trachea and the oesophagus. The condition most likely to be confused with double aortic arch is a right-sided aortic arch associated with a left-sided ligamentum arteriosum. In this anomaly Gross (1955) states that the right aortic arch causes an elongated indentation on the right side of the lower end of the trachea and in addition there is an anterior tracheal indentation, produced by the pulmonary artery, with another indentation on the left side due to the ligamentum arteriosum. The barium-filled oesophagus shows a deep and narrow indentation on its left lateral and posterior aspects, with occasionally a second posterior indentation directed obliquely upwards and to the left due to an aberrant left subclavian artery. In spite of the apparent differences in the indentations produced on the trachea and oesophagus Gross admits that occasionally it is not possible to distinguish between these two types of vascular ring. In this event angiocardiology should be undertaken, but it must be borne in mind that the entire vascular ring may not be demonstrated by this method, as portions of it may not be patent.

In the case reported here doubt as to the exact type of vascular ring present arose because of (a) the variable appearances of the trachea in successive radiographs, (b) the compression of the oesophagus, which was marked posteriorly and on the left side, but was not conspicuous on the right

side (Fig. 1). Angiocardiography was therefore performed to permit as complete a diagnosis as possible.

#### SUMMARY

A case of double aortic arch, treated by operation, is reported. The methods of investigation are discussed. In this condition, the occurrence of severe symptoms is an indication for early operation. The complications of pulmonary consolidation or collapse should be treated, but operation should be undertaken as soon as possible.

#### REFERENCES

- d'Abreu, A. L., Astley, R., and Parkes, A. (1952). *Brit. J. Surg.*, **40**, 70.  
 Apley, J. (1951). *Arch. chir. neerl.*, **3**, 250.  
 — (1953). *Arch. Dis. Childh.*, **28**, 423.  
 Curnow, J. (1874). *Trans. path. Soc. Lond.*, **26**, 33.  
 Dolton, E. G., and Jones, H. Everley (1952). *Lancet*, **1**, 537.  
 Exalto, J., Dicke, W. K., and Aalsmeer, W. C. (1950). *Arch. chir. neerl.*, **2**, 170.  
 Gross, R. E. (1955). *Circulation*, **11**, 124.  
 Herbut, P. A. (1943). *Arch. Path. (Chicago)*, **35**, 717.  
 Jones, C. H., and Walker, J. K. (1955). *J. Fac. Radiol. (Lond.)*, **6**, 281.  
 Neuhauser, E. B. D. (1946). *Amer. J. Roentgenol.*, **56**, 1.  
 Quain, R. (1844). *The Anatomy of the Arteries of the Human Body*, p. 22. Taylor and Walton, London.  
 Smithells, R. W. (1953). *Arch. Dis. Childh.*, **28**, 204.  
 Stevenson, J. J. (1950). *Brit. J. Radiol.*, **23**, 319.