

Numerous metallic foreign bodies in whole body after acupuncture

Yun-Seong Kang,¹ Deog Kyeom Kim²

¹Division of Pulmonary and Critical Care Medicine, Department of Internal Medicine, Seoul National University Hospital, Seoul, South Korea

²Division of Pulmonary and Critical Care Medicine, Department of Internal Medicine, Seoul Metropolitan Government-Seoul National University Boramae Medical Center, Seoul National University College of Medicine, Seoul, South Korea

Correspondence to

Dr Deog Kyeom Kim, Department of Internal Medicine, Seoul Metropolitan Government Seoul National University Boramae Medical Center, 20, Boramaero-5-gil, Dongjak-gu, Seoul 156-707, Korea; kimdkmd@gmail.com

Received 1 August 2016

Accepted 16 August 2016

Published Online First

8 September 2016

A 60-year-old man was referred to our clinic for the evaluation of numerous radio-opaque densities on a screening chest radiograph. He was a former smoker without any significant medical history, except for a history of pulmonary TB in his youth. On screening spirometry, he was diagnosed with mild COPD associated with smoking and previous TB. However, he did not report any symptoms, such as chest pain, shortness of breath, fever or chills. The laboratory results, including inflammatory markers, were not remarkable. After taking a detailed history, we found that he had been in a car accident 10 years ago, and had thereafter experienced chronic pain throughout his whole body, especially in the neck, anterior chest wall and back. Initially, he received acupuncture using golden needles to control the pain from a traditional Korean medicine doctor. However, he continued to undergo acupuncture with commercial golden needles, administered by himself and his wife, without any further medical advice. The chest radiograph showed numerous thin linear metallic foreign bodies scattered diffusely, especially in the neck, upper chest and trunk (figure 1). This feature was more prominent on

chest CT scans. Furthermore, the short needles were not restricted to the subcutaneous and intramuscular area, but were also found adjacent to the tracheal wall, in the thyroid glands and even in the anterior mediastinum and pleura, lung parenchyma, liver, spleen, stomach, intestine and kidneys (figure 2). Despite the shocking images, the patient did not present with any symptoms related to the needles and there was no sign of inflammation on his physical examination, so we have been observing him without intervention.

Acupuncture is a traditional Eastern medicine that uses needles to purportedly stimulate certain points on the body to alleviate pain.¹ Recently, even in Western countries, the prevalence of therapeutic strategies involving acupuncture is increasing,² and their widening acceptance demands continual updating of safety regulations.³ In this case, acupuncture with golden needles penetrating to the internal organs caused radiographic artefacts on chest radiographs. Although there were no complications in this case, it demonstrates the need for awareness of the possibility of improper use of acupuncture.

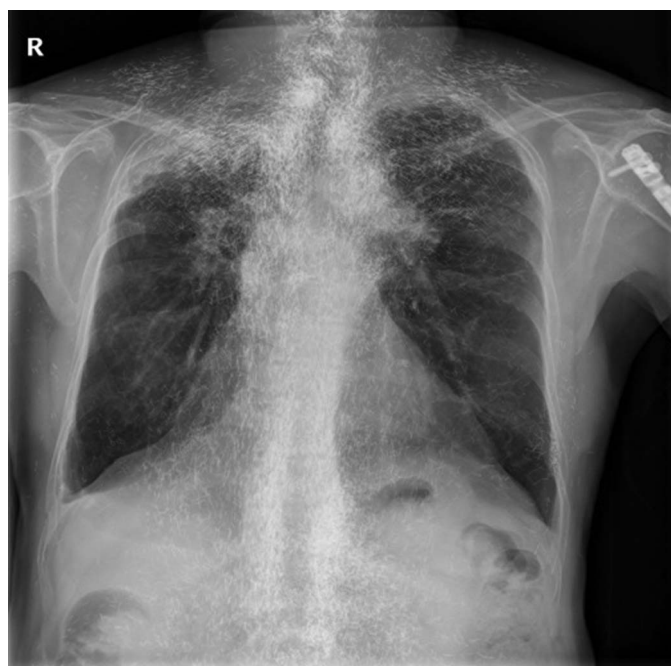

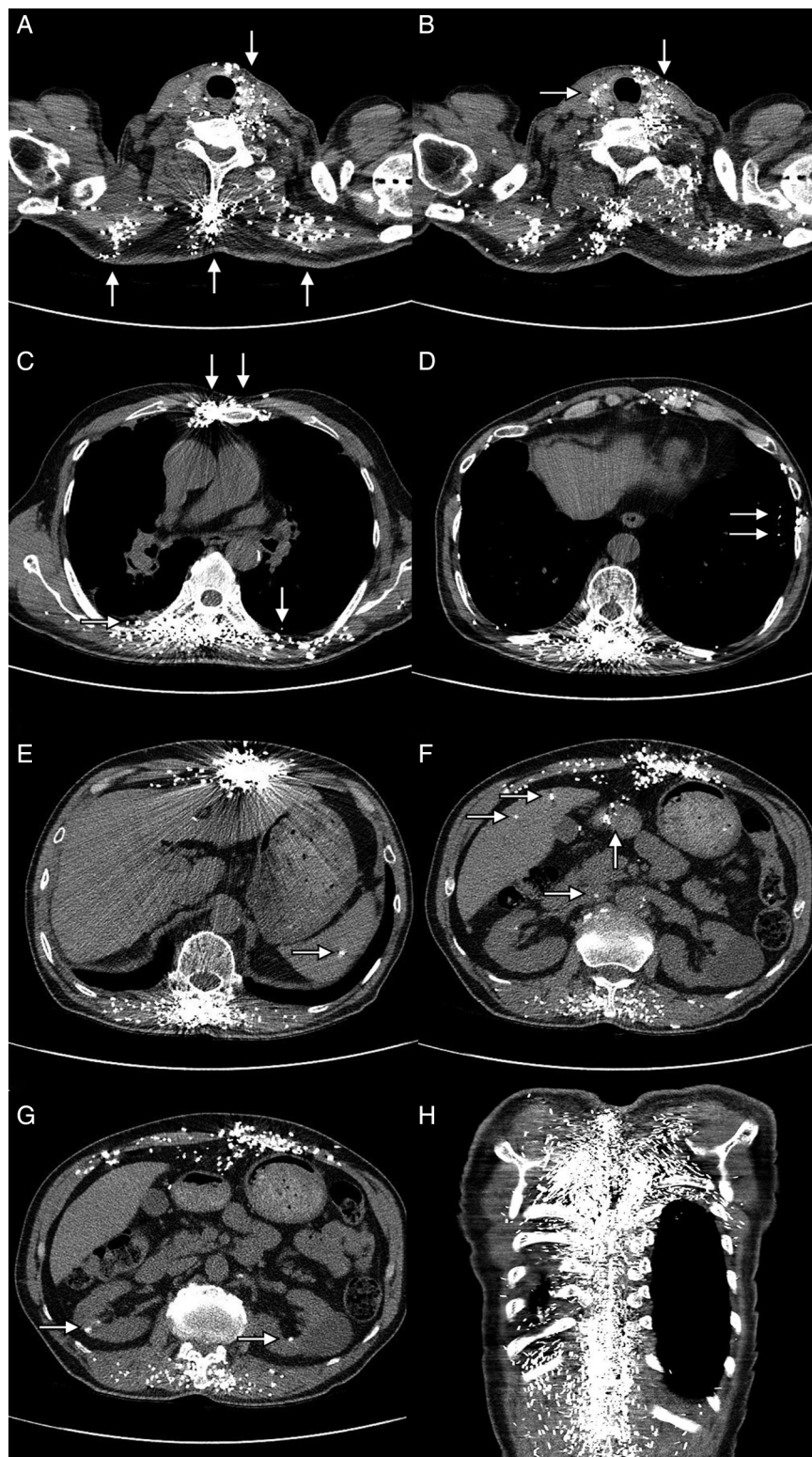
Figure 1 Chest X-ray showed numerous thin linear metallic radio-opaque densities scattered on whole body especially in neck, upper chest and axial part.



CrossMark

To cite: Kang Y-S, Kim DK. *Thorax* 2017;**72**:196–197.

Figure 2 On CT images, a lot of short needles are not restricted in the subcutaneous and intramuscular area but they were located adjacent to tracheal wall, in thyroid glands and even in anterior mediastinum and pleura, lung parenchyma, liver, spleen, stomach, intestine and kidneys ((A–G) show the cross-section view, (H) shows the coronal view; arrows indicate the needles penetrating the above-mentioned organs).



Contributors Conception and design: DKK. Drafting of the manuscript: DKK, Y-SK. Approval of the final version of the manuscript: DKK and Y-SK.

Competing interests None declared.

Patient consent Obtained.

Provenance and peer review Not commissioned; internally peer reviewed.

REFERENCES

- 1 Lin JG, Chen WL. Acupuncture analgesia: a review of its mechanisms of actions. *Am J Chin Med* 2008;36:635–45.
- 2 Burke A, Upchurch DM, Dye C, et al. Acupuncture use in the United States: findings from The National Health Interview Survey. *J Altern Complement Med* 2006;12:639–48.
- 3 White A. A cumulative review of the range and incidence of significant adverse events associated with acupuncture. *Acupunct Med* 2004;22:122–33.