



IMAGES IN THORAX

Unusual cause of localised bronchiectasis

Wen-Ting Siow, Pyng Lee

Division of Respiratory and Critical Care Medicine, National University Hospital, Singapore, Singapore

Correspondence to

Professor Pyng Lee, Division of Respiratory and Critical Care Medicine, National University Hospital, 1E Kent Ridge Road, Singapore 119228, Singapore; mdclp@nus.edu.sg

Received 15 May 2016

Revised 16 July 2016

Accepted 21 July 2016

Published Online First

11 August 2016

A 49-year-old man presented with 3 months' productive cough. He denied weight loss, fever and haemoptysis. He was an ex-smoker of 10 pack-years and was a pedestrian in a road traffic accident 20 years ago. He sustained an open skull fracture that led to residual hemiparesis and cranial diabetes insipidus. Physical examination revealed a well-nourished man. He had normal vital parameters with a heart rate of 80 bpm, blood pressure of 115/80 mm Hg and oxygen saturation of 96% on room air. Coarse crepitations were auscultated over the lower third of the left hemithorax, and there was no clubbing or cervical lymphadenopathy. Neurological examination showed mild hemiparesis on the left, without cognitive or speech deficits.

Serial chest roentgenograms (CXR) showed non-resolving left lung infiltrates despite oral antibiotics, and sputum cultures for mycobacteria were negative. Chest CT demonstrated an irregular, narrowed left main bronchus (LMB) and bronchiectasis of the left lower lobe (figure 1). Flexible bronchoscopy revealed a narrowed LMB with erythematous nodular mucosa. Advancing the bronchoscope revealed a foreign body (FB) angled flush against the LMB wall (figure 2A). An intact 2.8×2 cm plastic denture fragment with jagged edges was removed with alligator forceps after laser application failed to split it (figure 2B). Airway mucosa biopsies were negative for malignancy.

Our case highlights the complementary role of bronchoscopy in the evaluation of patients with localised bronchiectasis. Our patient's FB was CXR and CT occult since it was positioned flush against the bronchial wall and made of plastic. We postulate that the fragment was dislodged and aspirated during the road traffic accident.

FB aspiration is common in children but rare in adults unless they have comorbid conditions such as advanced age, alcohol intoxication and neurological

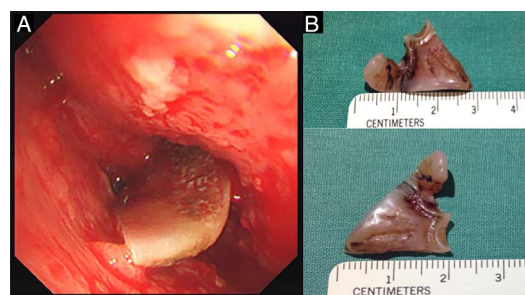


Figure 2 Endoscopic view of foreign body lodged in left main bronchus (A), and foreign body after removal, identified as a fragment of plastic denture, measuring 2×2.8 cm with laser marks (B).

disorders that increase the risk for aspiration.¹ Prompt diagnosis requires a high index of suspicion especially in patients without a history of aspiration. Radiological manifestations may include direct visualisation of radio-opaque FB or indirect inferences of non-resolving pneumonia, atelectasis, unilateral hyperinflation or localised bronchiectasis. Bronchoscopy is the gold standard for diagnosis and management of airway FB. Rigid bronchoscopy is preferred for large/asphyxiating FB as it not only secures the airway but facilitates its removal. Flexible bronchoscopy aided by direct suction and accessory instruments such as grasping forceps, inflatable balloon catheters, magnetic extractors, pronged snares, Dormia or fishnet baskets, and cryoprobe has led to successful FB retrieval in adults.¹ A systematic review reports 89.6% successful retrieval of airway FB in adults via flexible bronchoscopy and accessories with 3.3% requiring conversion to rigid bronchoscopy.² Adherent FB from granulation tissue overgrowth may require electrocautery, laser, rigid bronchoscopy or surgery for extraction, and laser has been used to fragment

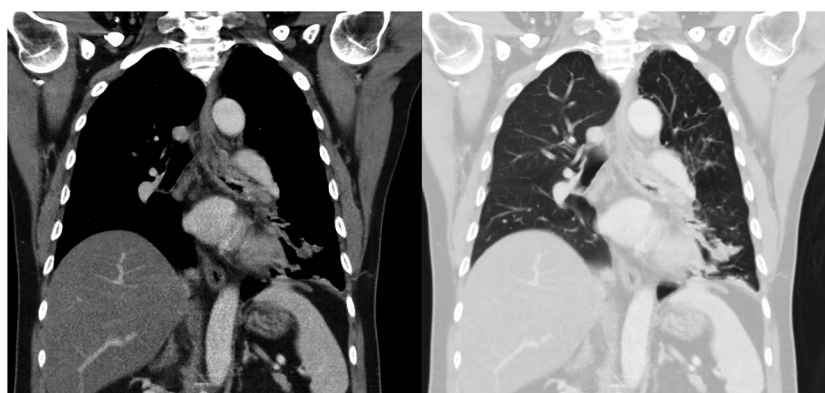


Figure 1 CT Thorax showing left main bronchus narrowing and left lower lobe bronchiectasis.



To cite: Siow W-T, Lee P. *Thorax* 2017;**72**:191–192.

large FB to aid in its removal.³ For our patient, we had the rigid instruments on standby.

Non-resolving pneumonia or localised bronchiectasis should raise suspicion of bronchial obstruction by FB or stricture, and prompt further evaluation. Following FB removal, our patient has remained well on follow-up, with complete resolution of his symptoms.

Competing interests None declared.

Patient consent Obtained.

Provenance and peer review Not commissioned; externally peer reviewed.

REFERENCES

- 1 Swanson KL, Prakash UBS, McDougall JC, *et al*. Airway foreign bodies in adults. *J Bronchol* 2003;10:107–11.
- 2 Sehgal IS, Dhooria S, Ram B, *et al*. Foreign body inhalation in the adult population: experience of 25,998 bronchoscopies and systematic review of the literature. *Respir Care* 2015;60:1438–48.
- 3 Mahajan AK, Khandhar SJ. Successful bronchoscopic removal of a chicken bone lodged in airway for 4-years. *Am J Respir Crit Care Med* 2016.