



AUDIT, RESEARCH AND GUIDELINE UPDATE

The utility of ultrasound-guided thoracentesis and pleural biopsy in undiagnosed pleural exudates

Coenraad Frederik N Koegelenberg,¹ Elvis Malcom Irusen,¹
 Florian von Groote-Bidlingmaier,¹ Johannes Willem Bruwer,¹ Enas Mansour A Batubara,¹
 Andreas Henri Diacon^{1,2}

¹Division of Pulmonology, Department of Medicine, Stellenbosch University & Tygerberg Academic Hospital, Cape Town, South Africa
²Division of Medical Physiology, Department of Biomedical Sciences, Stellenbosch University & Tygerberg Academic Hospital, Cape Town, South Africa

Correspondence to
 Dr Coenraad FN Koegelenberg,
 Division of Pulmonology,
 Department of Medicine,
 Stellenbosch University &
 Tygerberg Academic Hospital,
 PO Box 241, Cape Town
 8000, South Africa;
 coeniefn@sun.ac.za

Received 11 November 2014
 Revised 27 January 2015
 Accepted 26 April 2015
 Published Online First
 21 May 2015

ABSTRACT

We assessed the utility of ultrasound to guide the selection of closed pleural biopsy technique and site and to assess the respective contributions of repeat thoracentesis and closed pleural biopsy in 100 consecutive patients with undiagnosed pleural exudates. Thoracentesis was more likely to be diagnostic in TB than malignancy (77.8% vs 31.0%, $p < 0.001$). The addition of ultrasound-guided biopsy increased the combined yield for all diagnoses from 48.0% to 90.0% ($p < 0.001$), for malignancy from 31.0% to 89.7% ($p < 0.001$) and for TB from 77.8% to 88.9% ($p = 0.688$). Our findings suggest that this minimally invasive approach has a high diagnostic yield.

INTRODUCTION

The most efficient and cost-effective approach to pleural exudates not diagnosed on pleural fluid analysis remains uncertain.¹ Transthoracic ultrasound offers a low-cost and mobile guide to minimally invasive procedures, including thoracentesis and closed pleural biopsy.^{1–3}

The main aim of this prospective study was to assess the utility and safety of ultrasound-guided thoracentesis and biopsy in patients with undiagnosed exudates. The objectives were to investigate whether transthoracic ultrasound could guide the selection of closed pleural biopsy technique and site and to assess the respective contributions of repeat thoracentesis and closed pleural biopsy to the diagnostic yield in a cohort representative of everyday clinical practice.

METHODS

Patients ≥ 18 years referred to Tygerberg Academic Hospital (Cape Town, South Africa) from February 2012 to September 2013 were candidates for this prospective observational study provided at least one prior thoracentesis confirmed an exudate, a diagnosis could not be ascertained and an effusion of ≥ 10 mm was confirmed on ultrasound. Patients with a known coagulopathy were excluded.

Based on transthoracic ultrasound as well as available chest radiography, patients were categorised as either having (a) an associated distinct well-circumscribed mass lesion abutting or invading the chest wall with lesion–pleura contact arc length of ≥ 20 mm; (b) diffuse pleural thickening or nodularity (≥ 10 mm) or (c) insignificant or no pleural thickening (figure 1). Patients were scanned in the sitting position by pulmonologists. All the zones were screened,

whereafter a focused evaluation of anticipated thoracentesis and biopsy site was performed.

Ultrasound-guided thoracentesis was performed on all. Samples were obtained for pH analysis, chemistry, microbiology, cell counts and cytology. The chemical analyses included pleural fluid adenosine deaminase (ADA) levels. Microbiological investigations included routine gram stains and cultures, as well as stains for acid-fast bacilli and TB cultures.⁴ A lymphocytic predominant effusion was defined as one with $> 75\%$ lymphocytes and/or a lymphocyte:neutrophil ratio > 0.75 .⁵

Ultrasound-guided transthoracic biopsy was performed immediately after the thoracentesis. All aspirations and biopsies were performed ‘freehand’ (not under direct ultrasound guidance), as previously described.² The same insertion site was used for fluid aspiration and biopsy, unless a mass abutting the chest wall was present.

Ultrasound-guided transthoracic fine needle aspiration (TTFNA) with rapid on-site evaluation (ROSE) and ultrasound-assisted cutting needle biopsy (CNB), where indicated, was performed in case of an overt pleural-based mass. At least four aspirates were harvested with a 22 G spinal needle connected to a 10 mL syringe and directly expressed onto slides, smeared and submitted for ROSE as previously described.⁶ CNB was obtained following TTFNA in all cases where the provisional on-site diagnosis was not lung cancer. Manually operated 14 G Tru-cut biopsy needles with a specimen notch of 20 mm (Allegiance, Chateaubriand, France) were used. Three or more passes were performed until macroscopically satisfactory material was harvested.

In the presence of pleural thickening, ultrasound-assisted biopsy aimed at the area of interest was performed with an Abrams (10–24 mm thickening) or a Tru-cut needle (≥ 25 mm thickening). In the absence of overt pleural abnormalities, ultrasound-assisted pleural biopsy of the basal pleura (at least two interspaces above the costophrenic recess) was performed with an Abrams needle. Both Abrams and Tru-cut needle biopsies were performed using standard methods.^{1,2} A total of six macroscopically satisfactory specimens were obtained and transported in 4% formalin (five specimens) and 0.9% saline (one specimen).

The biopsy site was rescanned immediately after the procedures and a chest radiograph was obtained if any sign of a pneumothorax was present.^{1,2}



CrossMark

To cite: Koegelenberg CFN, Irusen EM, von Groote-Bidlingmaier F, et al. *Thorax* 2015;**70**: 995–997.

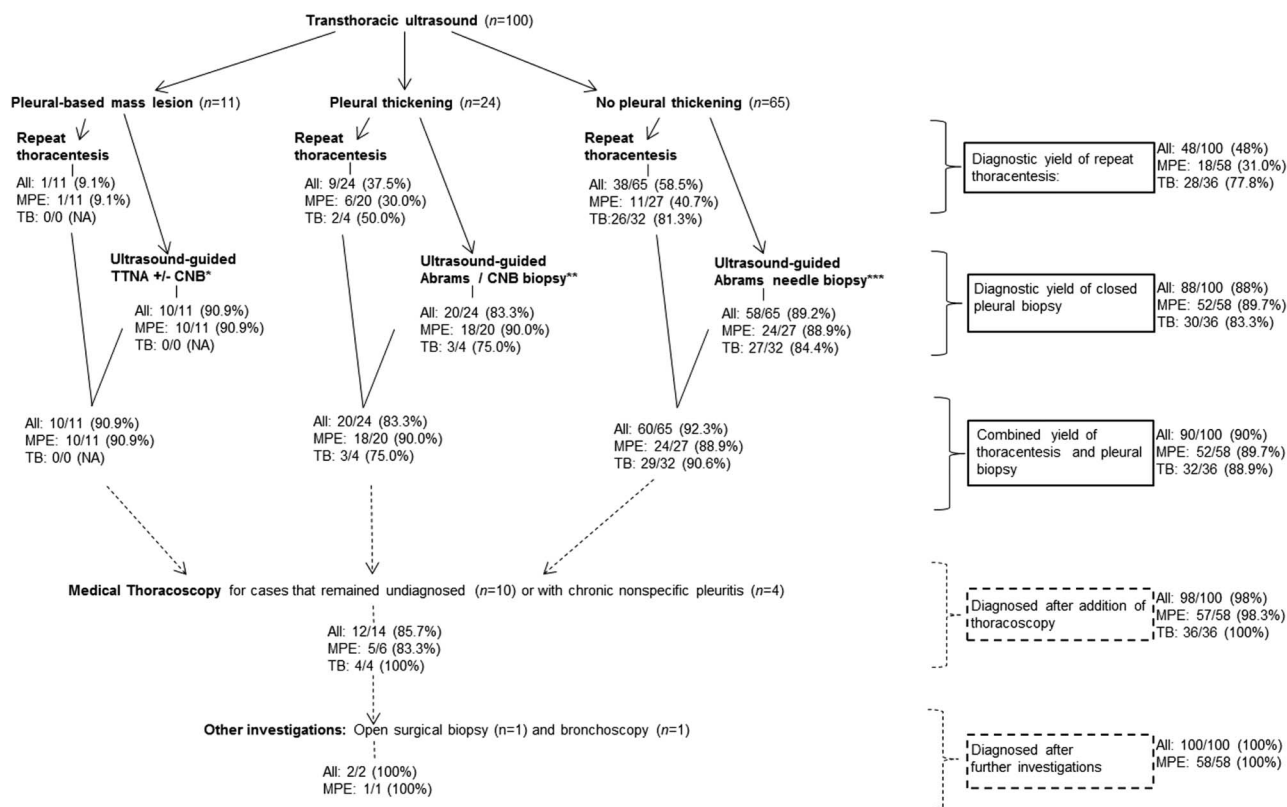


Figure 1 Participant flow through the study according to image stratification and cumulative diagnostic yields for all diagnoses (All, n=100), malignant pleural effusions (MPE, n=58) and pleural tuberculosis (TB, n=36). Dashed lines and boxes refer to subsequent investigations performed to establish final diagnoses. NA, not applicable. *Ultrasound-guided transthoracic fine needle aspiration (TTFNA) with rapid on-site evaluation with or without ultrasound-assisted cutting needle biopsy (CNB), where indicated (see text). **Ultrasound-guided biopsy aimed at the area of interest was performed with an Abrams needle (10–24 mm thickening) or a CNB (Tru-cut) needle (≥ 25 mm thickening). ***Ultrasound-assisted pleural biopsy of the basal (low supradiaphragmatic) pleura was performed with an Abrams needle.

Pleural TB was diagnosed in the presence of lymphocytic effusions with an ADA >50 IU, if acid-fast bacilli were present, if *Mycobacterium tuberculosis* could be cultured (from pleural fluid or tissue) or if the histology yielded caseating granulomata. Definitive cytology or histology was required to diagnose malignant pleural effusion.

Medical thoracoscopy was undertaken in all cases that remained undiagnosed and where closed biopsy yielded non-specific pleuritis to establish a final diagnosis. Further investigations were at the discretion of the treating physician. Cases with chronic pleuritis on thoracoscopic biopsy were followed up for at least 6 months and lack of clinical and radiological progression was mandatory for categorisation as non-specific pleuritis. McNemar's test was used to compare the cumulative diagnostic yield of thoracentesis and pleural biopsy with thoracentesis alone. χ^2 or Fisher's exact tests (where indicated) were performed on dichotomous categorical variables.

RESULTS

We enrolled 100 consecutive patients (51.4 ± 16.0 years; 68 men). No patient was excluded. The majority had malignant disease (n=58), including lung cancer (n=35), malignant mesothelioma (n=12) and other metastatic malignancies (n=11). Other diagnoses included pleural TB (n=36), non-specific pleuritis (n=4), empyema (n=1) and a ruptured hydatid cyst (n=1). Eleven patients had an associated mass lesion that abutted the chest wall (all malignant), 24 had pleural thickening of ≥ 10 mm

(20 malignant) and 65 had no or insignificant thickening (of which 32 had TB and 27 malignancy).

The combined diagnostic yields of ultrasound-guided thoracentesis and pleural biopsy for all diagnoses, pleural malignancy and pleural TB are summarised in figure 1. The ultrasound-guided thoracentesis was more likely to be diagnostic in TB compared with malignancy (77.8% vs 31.0%, $p < 0.001$). The addition of pleural biopsy to the thoracentesis increased the yield for all diagnoses from 48.0% to 90.0% ($p < 0.001$), for malignancy from 31.0% to 89.7% ($p < 0.001$) and for TB from 77.8% to 88.9% ($p = 0.688$).

ROSE was used in 11 cases stratified to TTFNA and confirmed sufficient material in 5/6 with lung cancer. One case with adenocarcinoma and four with mesothelioma were diagnosed with CNB performed on the day. A single case was referred for thoracoscopy.

Twenty-three Abrams needle and one Tru-cut biopsy were obtained from patients with diffuse pleural thickening; histology yielded a diagnosis in 20/24 (83.3%). Most closed pleural biopsies (n=65) were performed in the presence of no or insignificant pleural thickening. Concordant histological diagnoses were made in 58 (89.2%), including four with non-specific chronic pleuritis that also underwent thoracoscopy and a single case of empyema. Two cases of pleural TB were diagnosed on pleural fluid analysis alone; no case of malignancy had positive pleural fluid cytology without concordant histology.

The diagnostic yield of closed pleural biopsy for all diagnoses did not differ according to the presence or absence of pleural

thickening (83.3% vs 89.2%; $p=0.479$). Complications of closed pleural biopsy included mild haemoptysis ($n=1$), pneumothorax (not requiring intervention, $n=1$) and local haemorrhage ($n=1$). All aspirations and CNBs were uncomplicated.

Histological diagnoses were made in 12 of the 14 patients (85.7%) who were referred for thoracoscopy. The remaining two cases were diagnosed as small cell lung cancer on bronchoscopy and as a ruptured hydatid cyst by open surgical biopsy.

DISCUSSION

In this prospective observational study in patients with undiagnosed exudates at least 10 mm in depth, we found ultrasound-guided thoracentesis and biopsy to have a combined diagnostic yield of 90%. The ultrasound-guided thoracentesis proved to be particularly useful in diagnosing TB, whereas the addition of ultrasound-guided pleural biopsy to thoracentesis resulted in clinically meaningful and statistically significant increases in the yields for all diagnoses and pleural malignancy. Ultrasound-guided procedures were well tolerated, and no serious complications were observed.

The significant difference observed in the yields for malignancy of ultrasound-guided thoracentesis and biopsy in the present study can be attributed to the fact that we preselected patients with at least one previous non-diagnostic aspiration. A second thoracentesis in this setting has been shown to have a sequential gain of 27% for pleural malignancy.¹ We observed a very similar figure (31%). The utilisation of ultrasound to both direct procedure selection and guide biopsy increased the combined yield of the two procedures to almost 90%, making it a feasible and minimally invasive approach in this setting, particularly in patients who are unfit or unwilling to undergo thoracoscopy. Moreover, the approach was just as likely to yield a diagnosis whether or not pleural thickening was present.

Almost 80% (28/36) of cases with pleural TB could be diagnosed on thoracentesis alone. It is plausible that the study design itself leads to a preselection of cases of early pleural TB. Pleural fluid findings are known to evolve from early neutrophil to lymphocytic predominance in tuberculous effusions, which provides at least one explanation for the seemingly high diagnostic yield observed in patient who previously had had a non-diagnostic thoracentesis.² In high-burden and resource-constrained settings, it may therefore be appropriate to repeat

ultrasound-guided thoracentesis before proceeding to pleural biopsy, although this approach may delay the diagnosis in a minority of cases.⁵ The positive predictive value of a high ADA in the presence of a lymphocytic effusion in a low TB prevalence setting is significantly less, and even if present, would not negate the need for pleural biopsy.^{1,2} Our findings should thus be interpreted within the context of a high TB prevalence and may need replicating in different settings, including those where closed pleural biopsies are infrequently performed.

Our study has some limitations. We made use of the 'free-hand' biopsy technique. Pleural biopsy under direct real-time guidance may have an even higher diagnostic yield. The study was also not designed to challenge the status of thoracoscopy as the gold standard for pleural biopsy, but rather to validate the use of ultrasound to direct procedure selection and guide biopsy as an adjunct to pleural aspiration.

In conclusion, ultrasound-assisted thoracentesis and pleural biopsy has a high diagnostic yield and is safe and can be considered first-line investigations in undiagnosed pleural exudates.

Contributors Recruitment of patients, collection of data: all authors. Analysis of data: CFNK and AHD. Preparation of manuscript: CFNK and AHD. Critical revision of the manuscript: EMI, FvG-B, JWB and EMAB. CFNK conceived the idea and is the guarantor of the paper, taking responsibility for the integrity of the work as a whole, from inception to published article.

Competing interests None declared.

Patient consent Obtained.

Ethics approval Stellenbosch University Human Research Ethics Committee.

Provenance and peer review Not commissioned; externally peer reviewed.

REFERENCES

- 1 Koegelenberg CF, Diacon AH. Image-guided pleural biopsy. *Curr Opin Pulm Med* 2013;19:368–73.
- 2 Koegelenberg CF, Diacon AH. Pleural controversy: closed needle pleural biopsy or thoracoscopy—Which first? *Respirology* 2011;16:738–46.
- 3 Hallifax RJ, Corcoran JP, Ahmed A, *et al*. Physician-based ultrasound-guided biopsy for diagnosing pleural disease. *Chest* 2014;146:1001–6.
- 4 Koegelenberg CF, Bolliger CT, Theron J, *et al*. Direct comparison of the diagnostic yield of ultrasound-assisted Abrams and Tru-Cut needle biopsies for pleural tuberculosis. *Thorax* 2010;65:857–62.
- 5 Diacon AH, Van de Wal BW, Wyser C, *et al*. Diagnostic tools in tuberculous pleurisy: a direct comparative study. *Eur Respir J* 2003;22:589–91.
- 6 Diacon AH, Schuurmans MM, Theron J, *et al*. Safety and yield of ultrasound assisted transthoracic biopsy performed by pulmonologists. *Respiration* 2004;71:519–22.