

# Recurrent respiratory papillomatosis with lung involvement and malignant transformation

En-Li Shiau,<sup>1</sup> Ming-Feng Li,<sup>1</sup> Jung-Hsiu Hsu,<sup>1</sup> Ming-Ting Wu<sup>1,2</sup>

<sup>1</sup>Department of Radiology, Kaohsiung Veterans General Hospital, Kaohsiung, Taiwan  
<sup>2</sup>School of Medicine, National Yang-Ming University, Taipei, Taiwan

## Correspondence to

Dr Ming-Feng Li, Department of Radiology, Veterans General Hospital-Kaohsiung, 386 Ta-Chung First Rd., Kaohsiung 813, Taiwan; oudinot@gmail.com

Received 6 November 2012

Revised 14 April 2013

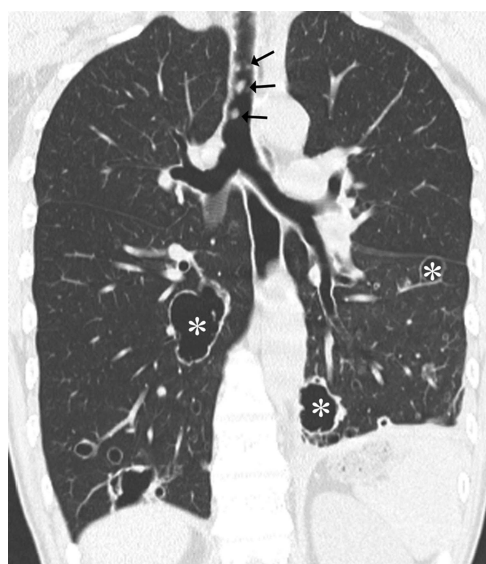
Accepted 25 April 2013

Published Online First

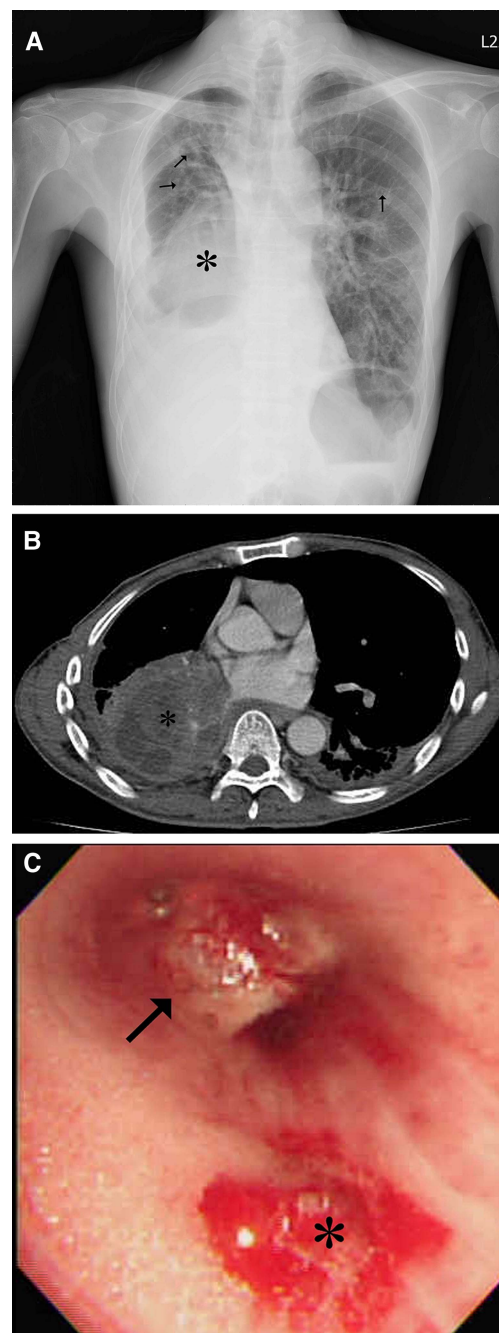
24 May 2013

A 49-year-old male had history of recurrent laryngeal papillomatosis spreading to the bronchus and lung parenchyma since childhood. He had been treated with repeated endoscopic CO<sub>2</sub> laser excision (figure 1). He had no smoking history. He was admitted with a 3-day history of worsening fever, cough and dyspnoea. Chest radiography showed a right lower lung mass, bronchiectasis, many cystic lesions and right pleural effusion (figure 2A). The right lower lobe mass measured 8.8×7.0 cm and had central hypodense areas consistent with necrosis (figure 2B, taken 8 years after figure 1) and there was mediastinal lymphadenopathy. Fiberoptic bronchoscopy showed numerous papillomas in the respiratory tract consistent with respiratory papillomatosis and an endobronchial tumour obliterating the right lower lobe bronchus, which bled on contact (figure 2C). Histopathology proved it a squamous cell carcinoma with papillomas identified in the tumour. Recurrent respiratory papillomatosis with malignant transformation was diagnosed. The patient received target therapy with erlotinib (Tarceva) and radiotherapy.

Recurrent respiratory papillomatosis, caused by infection with human papillomavirus, is usually localised to the laryngeal and subglottic region. Tracheal involvement has been reported to occur in 5% of cases, and fewer than 1% of cases show lung



**Figure 1** Coronal reconstructed CT image demonstrates multiple nodules (arrows) in the respiratory tract and multiple thin-walled cystic lesions (asterisks) in the lung parenchyma, indicating laryngeal papillomatosis with downward spreading to the airway and lung.



**Figure 2** (A) Chest radiography disclosed a right lower lung mass opacity (asterisk), bronchiectasis, many cystic lesions (arrows) and right pleural effusion (B) Contrast-enhanced CT scan demonstrates a growing mass lesion in the right lower lobe (asterisk) with central hypodense areas indicating necrosis. (C) Fiberoptic bronchoscopy discloses an endobronchial tumour (arrow) obliterating the right lower lobe bronchus, which easily bled on contact (asterisk).

**To cite:** Shiau E-L, Li M-F, Hsu J-H, et al. *Thorax* 2014;**69**:302–303.

involvement.<sup>1</sup> The image features of respiratory papillomatosis are solid or cystic nodules predominantly in the lower lobes, tracheal wall irregularity due to scars and papillomas, and bronchiectasis from obstruction and secondary infection. Malignant transformation into squamous cell carcinoma occurs in 2–3%, usually within 10 years of the diagnosis of pulmonary recurrent respiratory papillomatosis.<sup>2</sup> Clinicians should suspect malignant transformation when growth of a pulmonary nodule or mass is detected by serial imaging.

### Key messages

- ▶ Extra laryngeal spread in patients with recurrent respiratory papillomatosis is rare.
- ▶ The radiographic features of respiratory papillomatosis are solid or cystic nodules predominantly in the lower lobes, tracheal wall irregularity due to scars and papillomas and bronchiectasis from obstruction and secondary infection.
- ▶ Clinicians should suspect malignant transformation when growth of a pulmonary nodule or mass is detected by serial x-ray or CT.

**Contributors** ELS, MFL, JHH: concept, drafting, and revision of article. MTW: interpretation of imaging study. All authors gave final approval of the version to be published.

**Competing interests** None.

**Patient consent** Obtained.

**Provenance and peer review** Not commissioned; externally peer reviewed.

### REFERENCES

- 1 Kramer SS, Wehunt WD, Stocker JT, *et al.* Pulmonary manifestations of juvenile laryngotracheal papillomatosis. *AJR Am J Roentgenol* 1985;144:687–94.
- 2 Frauenfelder T, Marincek B, Wildermuth S. Pulmonary spread of recurrent respiratory papillomatosis with malignant transformation: CT-findings and airflow simulation. *Eur J Radiol Extra* 2005;56:11–6.