

3D contrast-enhanced lung perfusion MRI is an effective screening tool for chronic thromboembolic pulmonary hypertension: results from the ASPIRE Registry

Background Chronic thromboembolic pulmonary hypertension (CTEPH) is a complication of pulmonary embolism potentially curable by surgery. Perfusion scintigraphy is currently advocated as the imaging modality of choice to exclude CTEPH due to its high sensitivity. We have evaluated the diagnostic utility of lung perfusion MRI.

Methods Consecutive patients attending a pulmonary hypertension referral centre undergoing lung perfusion MRI, perfusion scintigraphy, CT pulmonary angiography (CTPA) and right heart catheterisation within 14 days were identified.

Results Of 132 patients, 78 were diagnosed as having CTEPH. Lung perfusion MRI correctly identified 76 patients as having CTEPH with an overall sensitivity of 97%, specificity 92%, positive predictive value 95% and negative predictive value 96% compared with perfusion scintigraphy (sensitivity 96%, specificity 90%) and CTPA (sensitivity 94%, specificity 98%). No cases of surgically accessible CTEPH were missed with either modality.

Conclusions Lung perfusion MRI has high sensitivity equivalent to perfusion scintigraphy in diagnosing CTEPH but does not require ionising radiation, making it an attractive initial imaging modality to assess patients with suspected CTEPH.

Chronic thromboembolic pulmonary hypertension (CTEPH) occurs in up to 3.8% of patients following pulmonary thromboembolism (PTE) and is a major cause of severe pulmonary hypertension (PH). Patients usually present with breathlessness following PTE or with unexplained PH. The diagnosis may be missed on CT pulmonary angiography (CTPA) by radiologists not experienced in pulmonary vascular disease, so perfusion scintigraphy has been recommended as a screening test, given its high sensitivity. In recent years, MRI has evolved into a holistic imaging modality in PH, allowing morphological assessment of the pulmonary vasculature and structural and functional assessment of the heart.¹ In addition, 3D contrast-enhanced lung perfusion MRI provides insight into regional pulmonary perfusion by tracking the dynamic passage of a contrast bolus. Previous studies have demonstrated the feasibility of this technique in acute PTE.² However, there is limited data on the performance of 3D contrast-enhanced lung perfusion MRI in diagnosing CTEPH in a high-risk population.^{3,4}

From a large PH referral centre, consecutive patients with suspected CTEPH or unexplained PH who had lung perfusion MRI, perfusion scintigraphy, CTPA and right heart catheterisation within 14 days were identified from the ASPIRE registry⁵ to compare the diagnostic utility of these imaging modalities. 3D MR lung perfusion images were acquired using a time resolved 3D spoiled gradient echo sequence with view sharing and were analysed by two radiologists blinded to the other imaging studies and clinical information. The final diagnosis of CTEPH was based on clinical assessment, right heart catheter and imaging, including MR angiographic studies (but not the MR perfusion images analysed in this study), CTPA and perfusion scintigraphy. The diagnosis of surgically accessible disease was confirmed at the national pulmonary endarterectomy centre at Papworth.

Of the 132 patients fulfilling the inclusion criteria, 78 had CTEPH. Forty-eight patients showed no evidence of CTEPH and included patients with a diagnosis of no PH (n=5), and all major forms of PH, including pulmonary arterial hypertension (n=18), PH associated with left heart disease (n=12), PH associated with lung disease (n=8) and PH multi-factorial (n=5). Six of the MR perfusion image data sets were of non-diagnostic quality. The MR perfusion images correctly identified

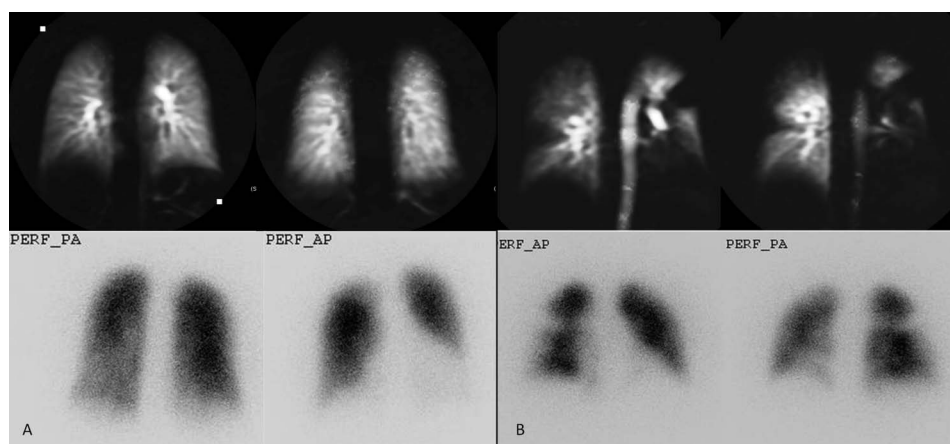
Table 1 Summary of diagnostic performance of perfusion scintigraphy, MR perfusion and CTPA in the diagnosis of CTEPH

	Q scan	MR perfusion*	CTPA
Sensitivity (%)	96 (95% CI 0.89% to 0.99%)	97 (95% CI 0.91% to 0.99%)	94 (95% CI 0.85% to 0.98%)
Specificity (%)	90 (95% CI 0.77% to 0.97%)	92 (95% CI 0.80% to 0.97%)	98 (95% CI 0.88% to 0.99%)
Positive predictive value (%)	94 (95% CI 0.86% to 0.98%)	95 (95% CI 0.88% to 0.99%)	99 (95% CI 0.92% to 0.99%)
Negative predictive value (%)	93 (95% CI 0.82% to 0.99%)	96 (95% CI 0.85% to 0.99%)	90 (95% CI 0.78% to 0.96%)
Accuracy (%)	94	95	95

*Inter-observer agreement, κ of 0.83.

CTEPH, chronic thromboembolic pulmonary hypertension; CTPA, CT pulmonary angiography.

Figure 1 (A) Selected coronal images of MR lung perfusion (top) and anterior and posterior view of perfusion scintigraphy images (bottom) in a patient with normal lung perfusion. (B) An example of a patient with chronic thromboembolic pulmonary hypertension with bilateral segmental perfusion defects seen on MR perfusion images (top) and perfusion scintigraphy (bottom).



76 patients to have CTEPH giving it a sensitivity of 97% (95% CI 0.91% to 0.99%) and specificity of 92% (95% CI 0.80% to 0.97%) (table 1). The results also showed CTPA, interpreted by the expert pulmonary vascular radiologists, and perfusion scintigraphy to be effective in the diagnosis of CTEPH with a sensitivity of 94% (95% CI 0.85% to 0.98%) and 96% (95% CI 0.89% to 0.99%), respectively (figure 1). None of the imaging modalities missed any of the patients with surgically accessible disease.

Accurate diagnosis of CTEPH is essential to identify a potentially treatable cause of PH. Here it is demonstrated that 3D lung perfusion MRI, as part of a pulmonary–vascular MRI protocol, has very high sensitivity for the diagnosis of CTEPH similar to that of perfusion scintigraphy and CTPA. The 3D data set allows image reconstruction in any plane, enabling better assessment of regional perfusion abnormalities and has superior temporal and spatial resolution to scintigraphy.

In conclusion, 3D lung perfusion MRI has high sensitivity for CTEPH and complements MR angiography and functional cardiac MRI in a single comprehensive

radiation-free imaging modality in the evaluation of patients with suspected CTEPH.

Smitha Rajaram,¹ Andrew J Swift,¹ Adam Telfer,¹ Judith Hurdman, Helen Marshall,^{2,1} Eleanor Lorenz,³ David Capener,¹ Christine Davies,⁴ Catherine Hill,⁴ Charlie Elliot,² Robin Condliffe,² Jim M Wild,¹ David G Kiely²

¹Academic Unit of Radiology, University of Sheffield, Sheffield, UK

²Sheffield Pulmonary Vascular Disease Unit, Royal Hallamshire Hospital, Sheffield Teaching Hospitals NHS Foundation Trust, Sheffield, UK

³Department of Nuclear Medicine, Sheffield Teaching Hospitals NHS Foundation Trust, Sheffield, UK

⁴Department of Radiology, Sheffield Teaching Hospitals NHS Foundation Trust, Sheffield, UK

Correspondence to Dr David G Kiely, Sheffield Pulmonary Vascular Disease Unit, Royal Hallamshire Hospital, Sheffield Teaching Hospitals NHS Foundation Trust, Glossop Road, Sheffield S10 2JF, UK; david.kiely@sth.nhs.uk

Competing interests None.

Ethics approval Sheffield teaching hospitals.

Provenance and peer review Not commissioned; internally peer reviewed.

► Additional material is published online only. To view please visit the journal online (<http://dx.doi.org/10.1136/thoraxjnl-2012-203020>).

To cite Rajaram S, Swift AJ, Telfer A, *et al.* *Thorax* 2013;**68**:677–678.

Received 19 November 2012

Revised 11 December 2012

Accepted 12 December 2012

Published Online First 24 January 2013

Thorax 2013;**68**:677–678.

doi:10.1136/thoraxjnl-2012-203020

REFERENCES

- 1 Swift AJ, Rajaram S, Condliffe R, *et al.* Diagnostic accuracy of cardiovascular magnetic resonance imaging of right ventricular morphology and function in the assessment of suspected pulmonary hypertension results from the ASPIRE registry. *J Cardiovasc Magn Reson* 2012;14:40.
- 2 Amundsen T, Kvaerness J, Jones RA, *et al.* Pulmonary embolism: detection with MR perfusion imaging of lung—a feasibility study. *Radiology* 1997;203:181–5.
- 3 Nikolaou K, Schoenberg SO, Attenberger U, *et al.* Pulmonary arterial hypertension: diagnosis with fast perfusion MR imaging and high-spatial-resolution MR angiography—preliminary experience. *Radiology* 2005;236:694–703.
- 4 Bergin CJ, Hauschildt J, Rios G, *et al.* Accuracy of MR angiography compared with radionuclide scanning in identifying the cause of pulmonary arterial hypertension. *AJR Am J Roentgenol* 1997;168:1549–5.
- 5 Hurdman J, Condliffe R, Elliot CA, *et al.* Aspire registry: assessing the spectrum of pulmonary hypertension identified at a referral centre. *Eur Respir J* 2012;39:945–55.

METHODOLOGY:

MR perfusion: MRI was performed on a 1.5 Tesla GE HDx Scanner (GE Healthcare, Milwaukee, USA). An 8 channel cardiac receive array RF coil was used. Contrast enhanced 3D MR lung perfusion images were acquired using a time resolved 3D spoiled gradient echo sequence with view sharing (TRICKS) [1]. The sequence parameters were: coronal orientation, TE 1.1ms, TR 2.5 ms, flip angle of 30°, FOV=48x48cm, matrix 200 x 80, SENSE R=2, 250 kHz bandwidth, slice thickness of 10mm. This sequence was acquired during full inspiratory breathhold after intravenous administration of 0.05 ml/kg of Gadovist (Schering, Berlin) injected at 4 ml/s followed by a 20ml saline flush. 40 3D image volumes were acquired consecutively depicting the passage of contrast bolus at an effective frame rate of two 3D volumes per second. To obtain full lung coverage, an average of 24 slices was obtained with a total breath hold time of 25 seconds. The perfusion images were generated by pixel-by-pixel subtraction of the pre-contrast data time point from the pixel which showed peak enhancement in the post contrast time course.

MR image analysis: The MR images were independently analysed by two radiologists who were blinded to the results of other imaging studies and clinical information. Images were analysed in the coronal plane and the image quality was graded on a three-point scale [2]: 1) un-interpretable 2) interpretable but of marginal image quality, or 3) of sufficient image quality to obtain a confident diagnosis. Two observers then independently evaluated the perfusion images for perfusion defects. A perfusion defect was defined as a lung region with decreased or no visible contrast enhancement. A diagnosis of CTEPH was made when there were one or more segmental and / or circumscribed perfusion defects, based on evidence from previous studies [3-4]. The distribution of perfusion defects was also recorded as upper, middle or lower zone in the right lung and upper and lower in the left lung. If the observers disagreed, a separate consensus reading took place and the consensus report was used in all further analysis. MR perfusion images were

evaluated without referring to other MRI techniques as the purpose was to evaluate the standalone value of perfusion MRI.

Perfusion scintigraphy: The perfusion scintigraphy images were obtained with the patient in the supine position following intravenous administration of technetium 99m labelled macro-aggregated albumin (dose of 100-MBq; MAASOL; Amersham Health, Vienna, Austria). Scanning was performed on a gamma camera system (GE Millennium, GE Infinia, or Siemens Symbia gamma camera systems) with a 256 x 256 matrix using a 20% window centered over the 140-keV energy peak. Four standard images (anterior, posterior, right posterior oblique and left posterior oblique) were obtained for 500,000 to 750,000 counts each. Images were interpreted according to the modified PLOPED criteria [5] and a high-probability scan was suggestive of chronic thromboembolic pulmonary disease [5-6].

CT pulmonary angiography: CTPA was performed on a 64 slice MDCT scanner (Light-Speed General Electric Medical Systems, Milwaukee, WI). Standard acquisition parameters were used: 100 mA with automated dose reduction, 120 kV, pitch 1, rotation time 0.5 s and 0.625mm collimation. The field of view was 400 x 400mm with an acquisition matrix of 512 x 512. 100ml of intravenous contrast agent (Ultravist 300; Bayer Schering, Berlin, Germany) was administered at a rate of 5ml/sec. CT findings of lack of contrast filling in the arterial vessel, intraluminal or eccentric contrast filling defects, calcified filling defects, recanalization, abrupt change in vessel calibre, strictures, post-stenotic dilatation, webs and parenchymal heterogeneity typical of perfusion abnormalities were considered suggestive of chronic thrombotic disease [7].

Final reference diagnosis: The final diagnosis of CTEPH or non-CTEPH was made at a multi-disciplinary meeting. This decision was based on clinical assessment, imaging findings and right heart catheter haemodynamics. The patients with a diagnosis of CTEPH were then referred to the national centre for pulmonary endarterectomy and a final diagnosis of surgically accessible or inaccessible disease was made. Appropriate patients with surgically

accessible disease were offered pulmonary endarterectomy. Follow-up data was retrieved on outcome following pulmonary endarterectomy.

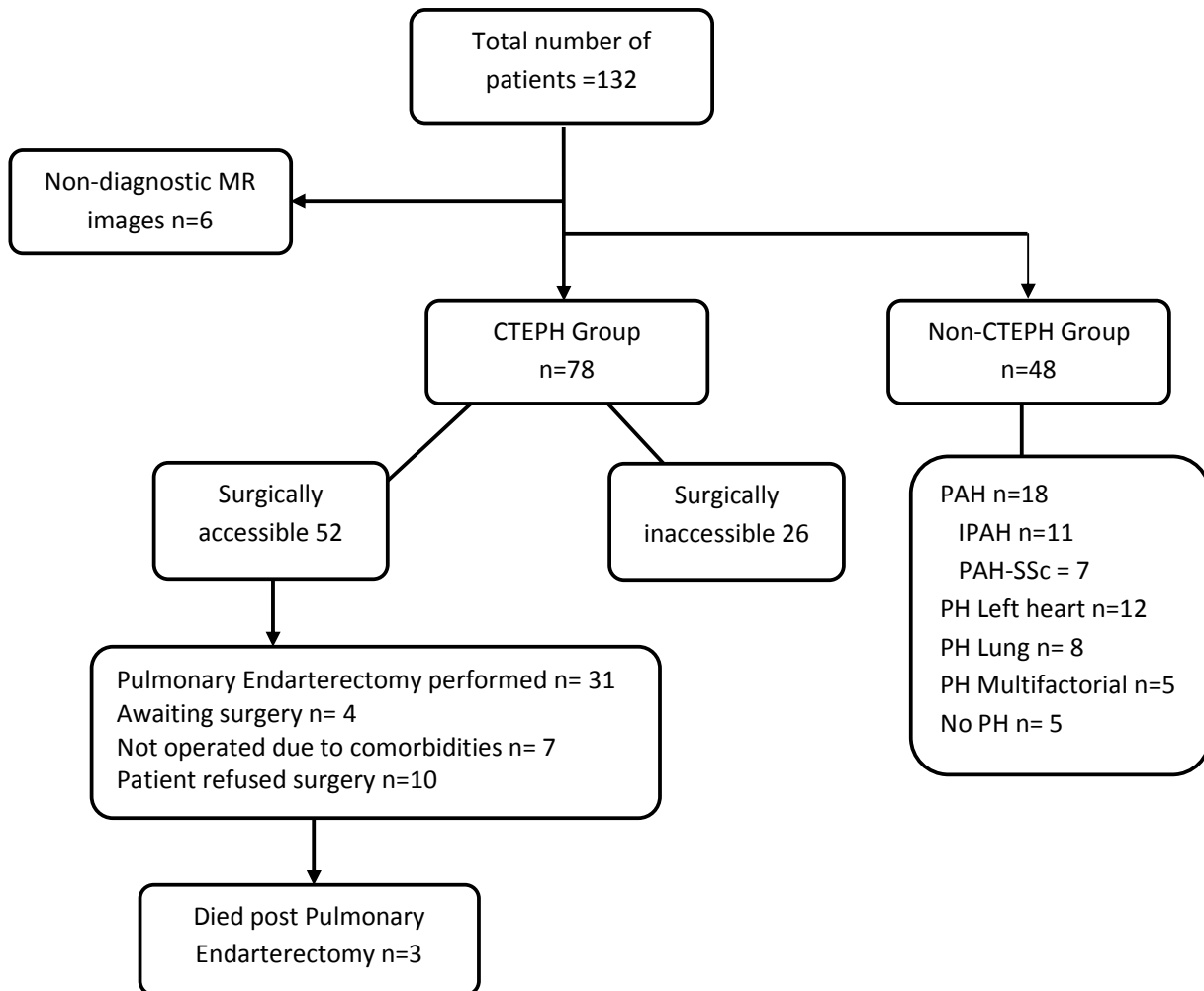
Statistical analysis: Sensitivity, specificity, positive predictive value and negative predictive value were calculated with 95% confidence interval (CI) for detection of CTEPH on MR perfusion images, perfusion scintigraphy and CTPA. Kappa statistics were used to analyze inter-observer agreement and to measure agreement between imaging modalities for the detection and location of perfusion defects. All statistical analysis was performed using commercially available software (SPSS program version 16.0 for Windows, Chicago, IL).

Patient demographics and right heart catheter parameters

	Whole Group n=126	CTEPH n=78	Non-CTEPH n=48	p-value
Age (yrs)	62(14)	59 (16)	64 (17)	0.47
Female (%)	58	56	66	0.9
mRAP (mmHg)	11(5)	11 (5)	10 (4)	0.67
mPAP (mmHg)	42 (13)	43 (11)	40 (14)	0.11
PCWP (mmHg)	12(6)	10(5)	14(6)	0.02
CI (L.min.m2)	2.7 (0.9)	2.9 (1)	2.7(1)	0.11
PVR (dyn.s.cm-5)	435 (365)	599(373)	429(365)	0.04
TPR (dyn.s.cm-5)	792 (267)	801(231)	789 (181)	0.4
mVO2 (%)	63 (8)	61(8)	66 (8)	0.008

Abbreviations: mRAP- mean right atrial pressure; mPAP- mean pulmonary artery pressure; PCWP- pulmonary capillary wedge pressure; CI-cardiac index; PVR -pulmonary vascular resistance; TPR- total pulmonary resistance; mVO2 - mixed venous oxygen saturation (standard deviation in brackets)

Patient classification



Abbreviations: CTEPH-chronic thromboembolic pulmonary hypertension; PH-pulmonary hypertension; IPAH - idiopathic pulmonary arterial hypertension; PAH- pulmonary arterial hypertension; SSc - Systemic Sclerosis

Summary of results for perfusion scintigraphy, 3D MR perfusion and CT images

Groups	Perfusion scintigraphy		3D MR perfusion		CT	
	+	-	+	-	+	-
CTEPH (n=78)	75	3	76	2	73	5
Non-CTEPH (n=48)	5	43	4	44	1	47

Summary of False-Positive perfusion MR, perfusion scintigraphy and CT images

Modality	Diagnosis
Perfusion MRI	1. Systemic sclerosis and pulmonary fibrosis (n=2) 2. PAH with background pulmonary emphysema (n=2)
Perfusion Scintigraphy	1. Scleroderma and pulmonary fibrosis (n=2) 2. PAH with background pulmonary emphysema (n=1) 3. PAH associated with congenital heart disease (n=1) 4. Pulmonary hypertension secondary to lung disease (n=1)
CT	1. PH associated with Pulmonary fibrosis (n=1)

PAH-pulmonary arterial hypertension; IPAH-idiopathic pulmonary arterial hypertension. Patients in 1 and 2 were the same for perfusion MRI and perfusion scintigraphy

REFERENCES:

1. Korosec FR, Frayne R, Grist TM, et al. Time-resolved contrast-enhanced 3D MR angiography. *Magn Reson Med* 1996;**36**(3):345-51
2. Matsuoka S, Uchiyama K, Shima H, et al. Detectability of pulmonary perfusion defect and influence of breath holding on contrast-enhanced thick-slice 2D and on 3D MR pulmonary perfusion images. *J Magn Reson Imaging* 2001;**14**(5):580-5 doi: 10.1002/jmri.1222 [pii][published Online First: Epub Date] |.
3. Amundsen T, Kvaerness J, Jones RA, et al. Pulmonary embolism: detection with MR perfusion imaging of lung--a feasibility study. *Radiology* 1997;**203**(1):181-5
4. Nikolaou K, Schoenberg SO, Attenberger U, et al. Pulmonary arterial hypertension: diagnosis with fast perfusion MR imaging and high-spatial-resolution MR angiography--preliminary experience. *Radiology* 2005;**236**(2):694-703 doi: 2361040502 [pii] 10.1148/radiol.2361040502[published Online First: Epub Date] |.
5. Freitas JE, Sarosi MG, Nagle CC, et al. Modified PIOPED criteria used in clinical practice. *J Nucl Med* 1995;**36**(9):1573-8
6. Freeman LM, Krynyckyi B, Zuckier LS. Enhanced lung scan diagnosis of pulmonary embolism with the use of ancillary scintigraphic findings and clinical correlation. *Semin Nucl Med* 2001;**31**(2):143-57
7. Remy-Jardin M, Duhamel A, Deken V, et al. Systemic collateral supply in patients with chronic thromboembolic and primary pulmonary hypertension: assessment with multi-detector row helical CT angiography. *Radiology* 2005;**235**(1):274-81 doi: 2351040335 [pii] 10.1148/radiol.2351040335[published Online First: Epub Date] |.