



## OPINION

# Middle airway obstruction—it may be happening under our noses

Philip G Bardin,<sup>1</sup> Sebastian L Johnston,<sup>2</sup> Garun Hamilton<sup>1</sup>

► Additional materials are published online only. To view these files please visit the journal online (<http://dx.doi.org/10.1136/thoraxjnl-2012-202221>).

<sup>1</sup>Lung and Sleep Medicine, Monash University and Hospital and Monash Institute of Medical Research (MIMR), Melbourne, Australia  
<sup>2</sup>Respiratory Medicine, Imperial College, London, UK

## Correspondence to

Professor Phil G Bardin, Lung and Sleep Medicine, Monash Medical Centre, 246 Clayton Road, Clayton 3168, Melbourne, Victoria 3168, Australia; [philip.bardin@monash.edu](mailto:philip.bardin@monash.edu)

Received 31 May 2012

Accepted 15 June 2012

Published Online First

19 July 2012

## ABSTRACT

**Background** Lower airway obstruction has evolved to denote pathologies associated with diseases of the lung, whereas, conditions proximal to the lung embody upper airway obstruction. This approach has disconnected diseases of the larynx and trachea from the lung, and removed the 'middle airway' from the interest and involvement of respiratory physicians and scientists. However, recent studies have indicated that dysfunction of this anatomical region may be a key component of overall airway obstruction, either independently or in combination with lung disease. New diagnostic modalities to effectively diagnose middle airway obstruction are being developed, and it has become feasible to identify and quantify middle airway obstruction.

**Conclusion** We, therefore, propose adding 'middle airway obstruction' to our nomenclature to embed it in diagnostic approaches, and to allow due emphasis on this neglected anatomical region.

## INTRODUCTION

Airway obstruction has conventionally been divided into lower and upper airway obstruction,<sup>1</sup> a distinction based on the anatomical location of the diseases causing symptoms. Lower airway obstruction has evolved over time to denote pathologies associated with diseases of the lung. In contrast, diverse conditions proximal to the lung have been grouped together as upper airway obstruction. To date, a logical additional demarcation (ie, upper airway: nose, sinuses, pharynx and middle airway: larynx, trachea) has not been proposed.

A one-dimensional approach to the upper airway is no longer in step with modern clinical practice. Nasal obstruction and tracheal stenosis, for example, are grouped together as upper airway obstruction although diagnostic and therapeutic approaches are vastly different. In a clinical context, middle airway dysfunction is frequently excluded from diagnostic pathways for common complaints, such as breathlessness. Current approaches, therefore, discourage recognition of the middle airway by respiratory physicians (traditional focus on the lung) and allergists (focus on the nose and sinuses).

The historical separation of upper and lower airway pathologies has also dogged attempts to link disease conditions involving both upper and lower airways. Experts rejected the notion that nasal rhinovirus infection is causally associated with asthma exacerbations, and it took almost 30 years for this conceptual error to be refuted.<sup>2</sup> The virus

is now understood to spread from nose to lung, and appropriate recognition of the close association between upper and lower airway pathologies has had positive outcomes. An example is novel strategies that may not be able to prevent colds, but that could ameliorate virus asthma exacerbations through the use of inhaled interferon.<sup>3</sup>

Accumulating evidence suggests that the middle airway plays a key role in airway obstruction either independently or with coexisting lung disease. In this paper, we consider why this component has been ignored, and propose that appropriate recognition of 'middle airway obstruction' may facilitate an integrated approach to optimised diagnosis and management of overall airway obstruction.

## Lower airway obstruction

Asthma and chronic obstructive pulmonary disease (COPD) are diseases characterised by lower airway obstruction, with breathlessness as a frequent symptom. This, in turn, leads to a search for other symptoms consistent with an obstructive abnormality (wheezing) and, when combined with classical lung function abnormalities, a clinical diagnosis of asthma or COPD can be verified. The possibility that anything other than lung disease and lower airway obstruction contribute significantly to a particular patient's symptoms is seldom considered. In asthma and COPD, an emphasis by respiratory physicians on the physiology, pathology and clinical aspects of lower airway obstruction has, therefore, become entrenched.

## Upper airway obstruction

The upper airway is defined as the anatomical area between the nose and the trachea, with the trachea mostly considered as part of the upper airway rather than the lung.<sup>4</sup> More logical subdivisions (ie, upper and middle airway) have not been proposed in spite of the differences in anatomical structure and function in the upper airway.

Interest in middle airway obstruction was kindled when vocal cord dysfunction (VCD) was described as a disorder that mimics asthma.<sup>5</sup> Subsequent studies suggested that VCD was common, also as a coexisting condition in asthma.<sup>6</sup> However, with time, interest in this association waned. In COPD, a body of research investigating a contribution of middle airway dysfunction to the symptoms and overall disease pathology in the condition has been distinctly lacking.

Nasal symptoms are easily differentiated from lung complaints, whereas, breathlessness originating in the middle airway is difficult to distinguish from

**To cite:** Bardin PG, Johnston SL, Hamilton G. *Thorax* 2013;**68**:396–398.

lung symptoms.<sup>7</sup> Additional unconventional symptoms (such as dysphonia) may alert the clinician but are often not elicited, and breathlessness is frequently the dominant complaint. In a clinical context, this leads to nasal symptoms being noted with other non-nasal respiratory symptoms being automatically attributed to new or existing lung disease. We are therefore caught in a trap of our own making: middle airway obstruction produces symptoms identical to lower airway obstruction, and these symptoms will be habitually attributed to the lung since it is the cause we are all familiar with—and understand.

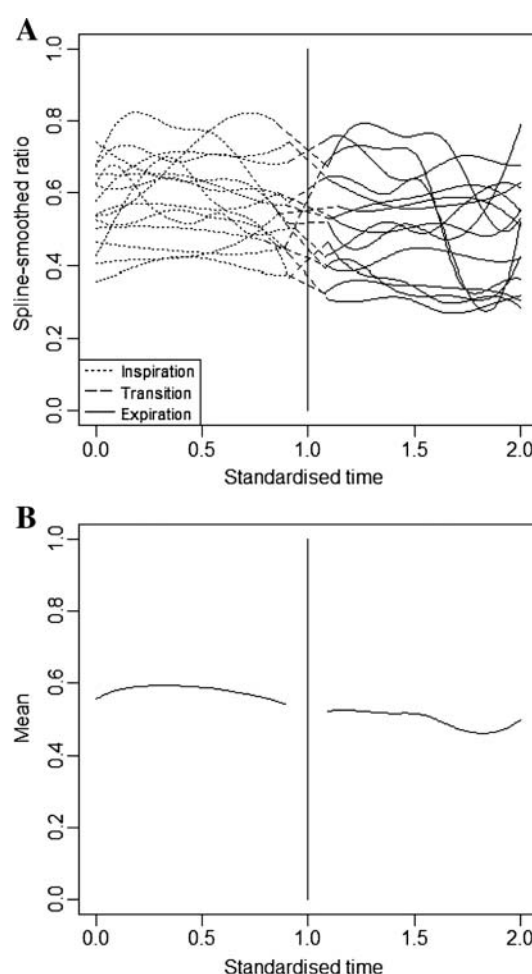
Why has middle airway dysfunction been able to masquerade for so long as a lung condition? Besides similar symptoms, the main reason is the difficulty to make a definitive diagnosis. Endoscopy was first used to diagnose VCD<sup>5</sup> and has remained the gold standard. However, endoscopy has important drawbacks and may not be available in the window period when patients have symptoms. The procedure is not pleasant and cannot be accurately quantified since it is dependent on the operator making a subjective assessment with diagnosis (yes or no) during physiological variations in airway calibre and vocal cord movement. Moreover, artifactual responses caused by the procedure itself are often present and usually difficult to exclude.

### Middle airway obstruction as a separate clinical entity

Croup in children is the quintessential disease of middle airway obstruction. It is an acute condition with explicit symptoms clearly referable to the larynx. However, this distinctive clinical scenario is not found in chronic diseases, and it is an unlikely consideration if coexistent lower airway illness provides an adequate explanation for patients' symptoms. We have argued that the middle airway has received limited attention, and in many respects it has been ignored. Why should this change, and why is there merit in changing our nomenclature to define 'middle airway obstruction' as a clinical entity?

The chief reason is that new diagnostic modalities to effectively diagnose middle airway obstruction are being progressively developed, and it has become feasible to identify and quantify middle airway obstruction. Significant developments have occurred in the context of asthma, a disease where many clinicians have long suspected that laryngeal dysfunction may play a complementary role in the causation of symptoms.<sup>7</sup> Diagnostic verification has been challenging, but recently, studies using non-invasive high-speed CT imaging of the larynx and trachea have provided indications of how this may be achieved.<sup>8,9</sup> Originally developed for cardiac investigation, 320-slice CT can be used to study the functions of the larynx and trachea in the middle airway. The technique generates images with 'volumes' of 16 cm<sup>3</sup> (rather than 4 cm<sup>3</sup> for 64-slice CT) with detailed capture of laryngeal and tracheal movement using moving-image reconstruction algorithms (Cine 1 and Cine 2 in online supplement). A continuous series of images generated by CT limits the requirement to 'stitch together' groups of images, thus avoiding artefact. Radiation levels are considerably reduced compared with 64-slice CT; for 320-slice CT it is ~0.5–2 mSv,<sup>8,9</sup> and within acceptable safety limits.

Studies in healthy individuals used 320-slice CT larynx to quantify airway obstruction employing a ratio of vocal cord lateral diameter to tracheal diameter.<sup>8</sup> Over the time of a full breath, this generated a curve depicting size of the airway at the level of the vocal cords. The lower limit of normal could be calculated as another curve 1.5 SD under the mean curve (figures 1 and 2A). In patients with difficult-to-treat asthma recruited from a severe asthma clinic, excessive narrowing of the



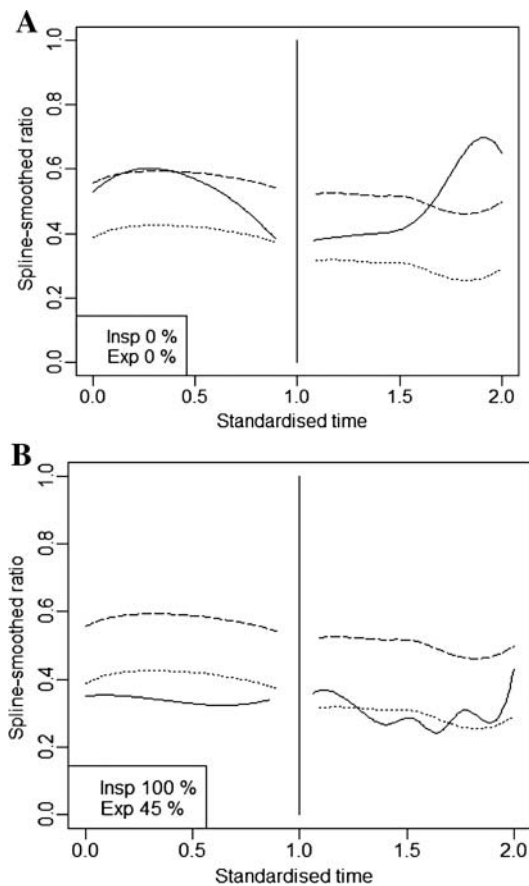
**Figure 1** Ratio of vocal cord diameter to tracheal diameter over a breath cycle in 15 healthy subjects is demonstrated (A). The patient curves were combined to produce the group mean curves shown in (B) (inspiration left panel, expiration right panel).

upper airway was detected in 23/46 (50%) patients with abnormalities being present during inspiration and expiration (figure 2). These unanticipated findings suggested that the middle airway could contribute to symptoms of breathlessness in this group, and further studies in milder asthma are now needed.

Middle airway dysfunction in COPD has been described resulting from excessive dynamic airway collapse (EDAC), or from narrowing associated with tracheomalacia. A recent study supports a renewed interest in the middle airway in COPD. Evaluation by 320-slice CT detected severe EDAC during COPD exacerbation, and demonstrated reversal of EDAC by treatment with continuous positive airway pressure.<sup>10</sup> Detailed studies are indicated to ascertain the prevalence and importance of EDAC in this patient group, but it supports the view that placing emphasis on the middle airway may also improve understanding of sources of breathlessness in COPD.

### SUMMARY: ADDING 'MIDDLE' TO AIRWAY OBSTRUCTION

The traditional clinical division of airway obstructive disease into upper and lower airway anatomical components is detrimental to advances in respiratory medicine. It has resulted in a limited appreciation of the potential participation of the middle airway in overall airway obstruction.



**Figure 2** Demonstrations of vocal cord function in two asthmatic patients using 320-slice CT larynx. Upper stippled curves denote mean ratio, and lower curves show the lower limit of normal (LLN). Patient curve (solid line) shows normal function in (A), and prolonged abnormality in (B) during both inspiration and expiration. In (B), vocal cord diameter is reduced below the LLN for 100% of inspiration and 45% of expiration time.

Upper airway obstruction has, therefore, become a partial misnomer. It is used to categorise a wide variety of conditions affecting the nose, pharynx, larynx and trachea, and has detracted from a comprehensive approach to the causes of airway obstruction. Moreover, it has compromised appropriate emphasis being placed on the middle airway as an independent or additional reason for symptoms usually solely attributed to lung disease. Adding 'middle airway obstruction' to our nomenclature will help to embed it in diagnostic algorithms, encouraging respiratory physicians to consider the role of dysfunction in this key anatomical region.

**Contributors** All authors participated in the conception of the 'opinion', drafting of the paper and review of the final draft. All participated in the revision of the paper.

**Competing interests** None.

**Provenance and peer review** Not commissioned; internally peer reviewed.

## REFERENCES

- 1 Stradling JR. Upper airway obstruction. In: Warrell DA, Cox TM, Firth JD, *et al*, eds. *Oxford Textbook of Medicine*. 4th edn. Oxford: Oxford University Press, 2003:1404–9.
- 2 Papadopoulos NG, Bates PJ, Bardin PG, *et al*. Rhinoviruses infect the lower airways. *J Infect Dis* 2000;181:1875–84.
- 3 Cakebread JA, Xu Y, Grainge C, *et al*. Exogenous IFN-beta has antiviral and anti-inflammatory properties in primary bronchial epithelial cells from asthmatic subjects exposed to rhinovirus. *J Allergy Clin Immunol* 2011;127:1148–54.e9.
- 4 Standring S, Berkovitz BK. Neck and upper aerodigestive tract. In: Standring S, Ellis H, Healy JC, *et al*, eds. *Gray's Anatomy*. London: Churchill Livingstone, 2005:531–646.
- 5 Christopher KL, Wood RP, Eckert RC, *et al*. Vocal-cord dysfunction presenting as asthma. *N Engl J Med* 1983;308:1566–70.
- 6 Newman KB, Mason UG, Schmalzing KB. Clinical features of vocal cord dysfunction. *Am J Respir Crit Care Med* 1995;152:1382–6.
- 7 Ayres JG, Mansur AH. Vocal cord dysfunction and severe asthma: considering the total airway. *Am J Respir Crit Care Med* 2011;184:2–3.
- 8 Low K, Lau KK, Holmes P, *et al*. Abnormal vocal cord function in difficult-to-treat asthma. *Am J Respir Crit Care Med* 2011;184:50–6.
- 9 Holmes PW, Lau KK, Crossett M, *et al*. Diagnosis of vocal cord dysfunction in asthma with high resolution dynamic volume computerized tomography of the larynx. *Respirology* 2009;14:1106–13.
- 10 Joosten S, MacDonald M, Lau KK, *et al*. Excessive dynamic airway collapse co-morbid with COPD diagnosed using 320-slice dynamic CT scanning technology. *Thorax* 2012;67:95–6.

## **ONLINE SUPPLEMENT**

### **Cine 1**

Coronal views with volumetric reconstruction demonstrating expiratory upper airway dysfunction in a patient with asthma. Studies were performed using Toshiba Aquilion-One CT (Toshiba Medical Systems, Tokyo, Japan). Images were generated every 0.35 seconds over the duration of the respiratory cycle and movement was reconstructed using moving-image algorithms. Note evidence of severe laryngeal dysfunction during expiration rather than isolated vocal cord dysfunction.

### **Cine 2**

Axial views at vocal cord level of 320-slice dynamic CT in the same patient. Technical details are as for Cine 1.