

Pulmonary puzzle

A 76-year-old lady with chronic cough and a discharging chest wall sinus

A 76-year-old lady was referred to the respiratory clinic with a 6-month history of a discharging left chest wall sinus. She also had a 6-month history of dry cough, left chest wall pain and breathlessness. There was no history of fever, haemoptysis, weight loss or night sweats. She was a lifelong non-smoker and there was no history of asbestos exposure.

Investigations showed elevated white blood cell count of $14.5 \times 10^9/l$ (neutrophil count $11 \times 10^9/l$) and C reactive protein 87 mg/L; renal and liver function tests were normal. Sputum cultures were negative.

She had a laparoscopic Nissen fundoplication 12 years earlier, complicated by perforation of the oesophagus. Subsequently, 6 years later, she developed dyspnoea; a chest x-ray at this time revealed a left-sided pleural-based abnormality. A thoracoscopic biopsy suggested benign pleural thickening/fibrosis. After thoracoscopy, she developed a discharging sinus around the access port site, which was excised.

The patient then relocated to the region and presented with a persistent discharge from the original chest wall sinus. Oral penicillin was commenced, although with only partial response and incomplete resolution of the discharge. Chest x-ray revealed

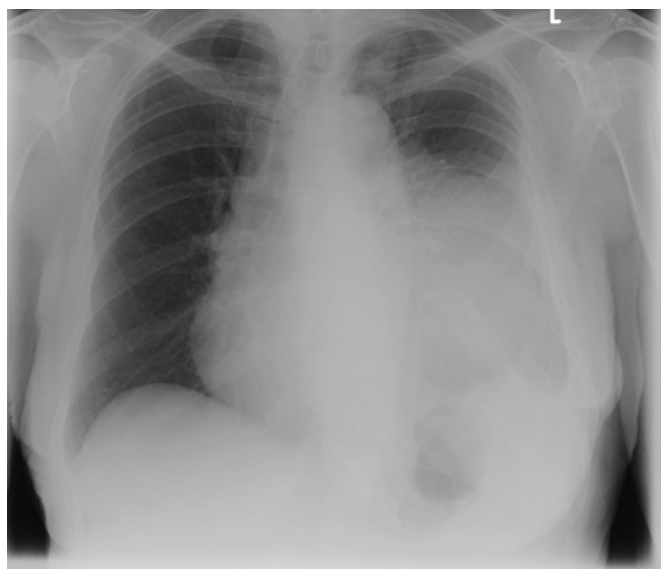


Figure 1 Chest x-ray, March 2010: extensive opacification within the left middle and lower zone.

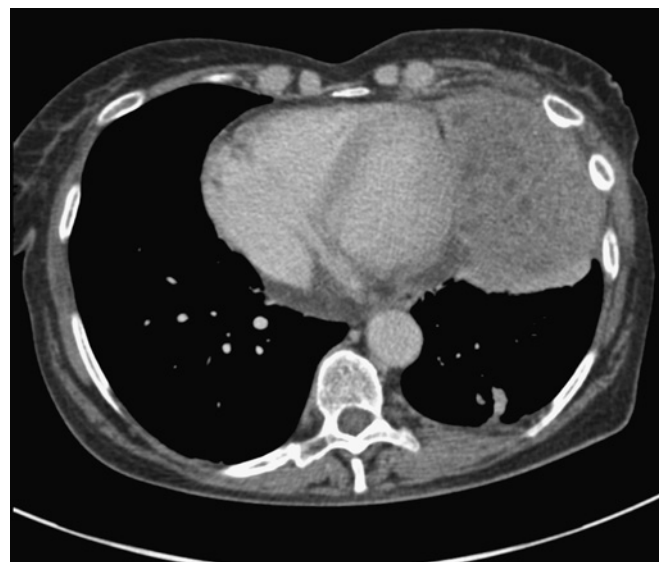

Figure 2 CT scan of chest, March 2010: large mass within the left pleural space, which appears to invade the anterior chest wall.

a mass lesion in the left hemithorax, which was confirmed by a CT scan (figures 1 and 2).

QUESTION

What is the diagnosis?

See page 738 for the answer

Mandar Deshpande,¹ Ajay Kamath,¹ Kieren Allinson,² Danielle Peat,² Wyn Parry³

¹Department of Respiratory Medicine, Norfolk & Norwich University Hospital, Norwich, UK; ²Department of Histopathology, Norfolk & Norwich University Hospital, Norwich, UK; ³Department of Thoracic surgery, Norfolk & Norwich University Hospital, Norwich, UK

Correspondence to Dr Mandar Deshpande, Specialty Registrar, Department of Respiratory Medicine, Norfolk & Norwich University Hospital, Colney Lane, Norwich NR4 7UY, UK; mandar.deshpande@nnuh.nhs.uk

AK and MD contributed equally to this work.

Correction notice This article has been corrected since it was published Online First. The order of authors and their affiliations were changed.

Competing interests None.

Patient consent Obtained.

Provenance and peer review Not commissioned; externally peer reviewed.

Published Online First 18 June 2011

Thorax 2011;**66**:733. doi:10.1136/thoraxjnl-2011-200109

ANSWER

From the question on the page 733

Our patient underwent thoracotomy and excision of the mass (figures 3–5).

The cut surface was yellow with numerous locules of pus. Microscopy confirmed widespread abscess formation within a cellular fibrous stroma admixed with macrophages and cholesterol clefts. Within each abscess was a colony of actinomyces organisms surrounded by neutrophils. Many of the filamentous bacteria showed eosinophilic glassy deposits—a typical Splendore-Hoeppli phenomenon.

Although microscopy and culture of the wound sinus were negative, culture of the excised abscess grew actinomyces as well.

Postoperatively the patient was given high-dose amoxicillin, initially intravenously 2 g four times a day for 2 weeks followed by 6 months of an oral 1 gm dose four times a day (figure 6).

Our patient had a good clinical response and the elevated inflammatory markers returned to normal.

DISCUSSION

Common causes of large pleural-based masses include benign or malignant pleural tumours, as well as metastatic pleural deposits among other diagnostic possibilities. Thoracic actinomycosis, although less common, can occur but can easily elude diagnosis.

Actinomycosis is an infection caused by the actinomyces organism, a gram-positive anaerobic bacterium. The most common species is *Actinomyces israelii*. Pulmonary actinomycosis accounts for the 15% of the cases.¹

Although sulphur granules are pathognomonic in the diagnosis of actinomycosis, similar findings are also noted in infections caused by *Nocardia brasiliensis*, *Streptomyces madurae* and *Staphylococcus aureus* causing botryomycosis. Sulphur granules consist of colonies of micro-organisms surrounded by polymorphonuclear neutrophils.¹

There may be chronic pneumonia associated with pleuritis, abscess and fibrosis. Empyema allows extension to the chest wall and may lead to a fistula. Radiographic findings include

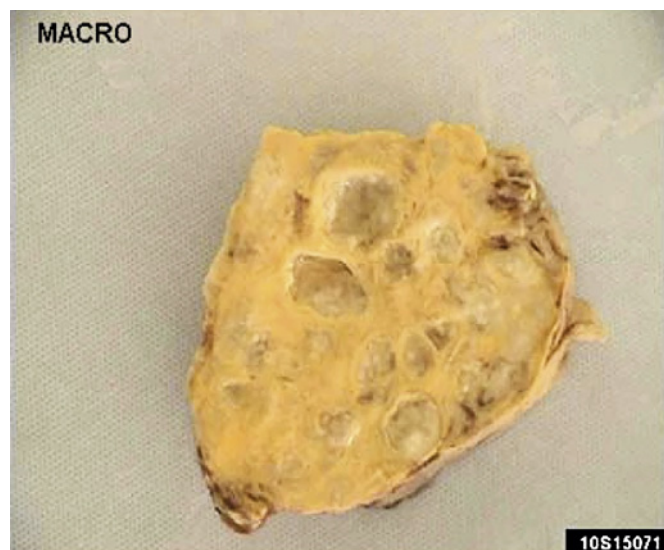

Figure 3 The pleural mass weighing 267 g was received in several fragments, the largest up to 8 cm in size. The cut surface was yellow with numerous locules of pus.

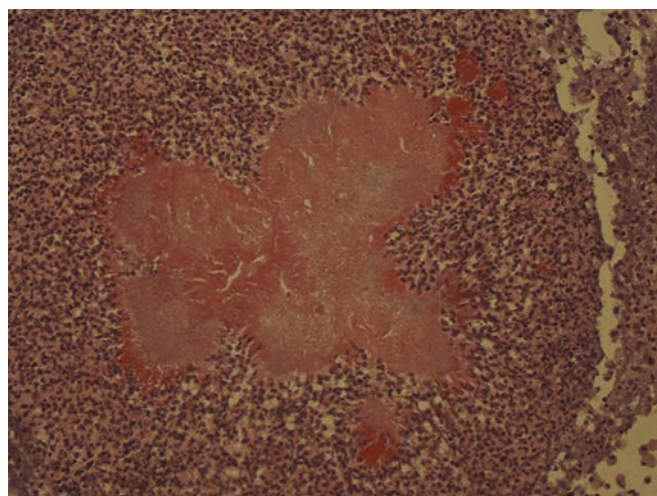


Figure 4 H&E stain showing a sulphur granule in a patient with actinomycosis. Many of the filamentous bacteria showed eosinophilic glassy deposits—a typical Splendore-Hoeppli phenomenon.

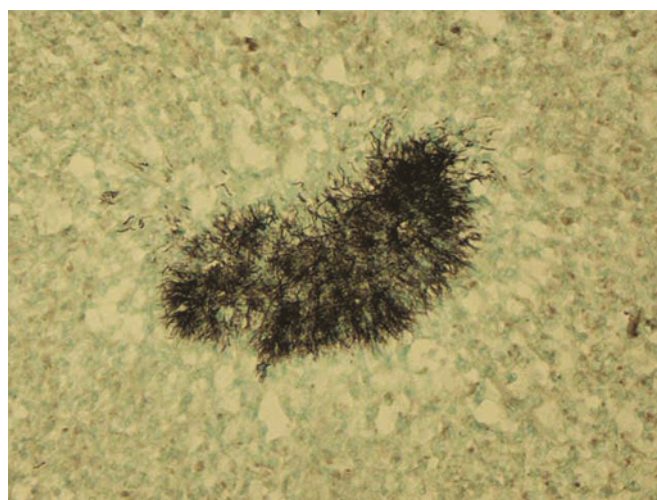

Figure 5 Actinomycosis colonies under Grocott's methenamine silver stain.

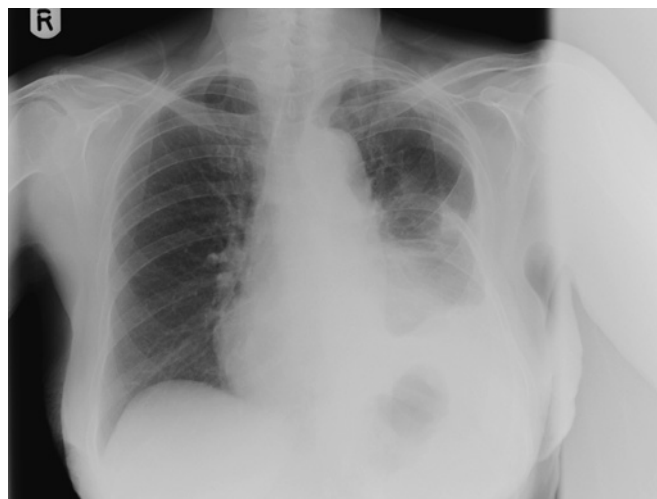

Figure 6 Follow-up chest x-ray, September 2010: loss of volume of the left lung and partial rib resection due to the previous thoracotomy. There is blunting of the left costophrenic angle, elevation of the left hemidiaphragm and increased density at the left base due to the previous thoracotomy. The right lung is clear.

peripheral non-segmental basilar infiltrates, mass-like consolidation, cavitation and pleural effusion or pleural thickening.²

Thoracic actinomycosis is usually the result of aspiration of infected material from the oropharynx. Normal gravitational and anatomical factors result in a predominance of lower-lobe pulmonary disease.³ Given the usual aetiology of thoracic actinomycosis, the likely factor in our patient's history was oesophageal perforation many years earlier.

Penicillin is the treatment of choice, in high dose and for a prolonged duration, most usually suggested for several months, but infections could also be polybacterial needing other antibiotics, especially if the recovery is slow. Complications include chronic and progressive sepsis, which may prove fatal. Surgery is reserved as a treatment option where diagnosis is uncertain (suspected neoplasm) or where there is no initial response to antibiotics.⁴

To conclude, there should be a high level of suspicion for the presence of actinomyces in cases with draining chest wall sinuses or with spontaneous discharge of an empyema. Recognition of these symptoms might avoid the need for surgery as actinomyces is an extremely penicillin-susceptible organism.

Thorax 2011;**66**:738–739. doi:10.1136/thoraxjnl-2011-200109

REFERENCES

1. **Mabeza GF**, Macfarlane J. Pulmonary actinomycosis. *Eur Respir J* 2003;**21**:545–51.
2. **Kim TS**, Han J, Koh WJ, *et al*. Thoracic actinomycosis: CT features with histopathologic correlation. *AJR Am J Roentgenol* 2006;**186**:225–31.
3. **Andreani A**, Cavazza A, Marchioni A, *et al*. Bronchopulmonary actinomycosis associated with hiatal hernia. *Mayo Clin Proc* 2009;**84**:123–8.
4. **Song J**, Park HY, Jeon K, *et al*. Treatment of thoracic actinomycosis: A retrospective analysis of 40 patients. *Ann Thorac Med* 2010;**5**:80–5.

Journal club

Scotland's smoking ban means fewer kids in hospital with asthma

The aim of this study was to determine whether the ban on smoking in public places in Scotland, which was initiated in March 2006, influenced the rate of hospital admission for childhood asthma. The risk of hospital admission was determined from January 2000 to October 2009 among children aged <15 years. Before the ban imposed in March 2006, the number of hospital admissions for asthma was rising by 5.2% a year among children aged <15 years. The public smoking ban reduced the annual rate of serious childhood asthma attacks by 18% per year. The benefits following the ban were seen in both preschool children and those of school age.

This study shows that there was a reduction in the rate of hospitalisation for childhood asthma after the introduction of legislation to make public places smoke-free, suggesting that the benefits of such legislation can extend to populations other than those with occupational exposure to environmental tobacco smoke.

► **Mackay D**, Haw S, Ayres J, *et al*. Smoke-free legislation and hospitalization for childhood. *N Engl J Med* 2010;**363**:1139–45.

Atul Gupta

Correspondence to Atul Gupta, Senior Research Fellow, Royal Brompton Hospital and NHLI Imperial College, Sydney Street, London SW3 6NP, UK; atulgupta@doctors.org.uk

Published Online First 29 October 2010

Thorax 2011;**66**:739. doi:10.1136/thx.2010.153510