

- 25 Humbert M, Deng Z, Simonneau G, *et al.* BMPR2 germline mutations in pulmonary hypertension associated with fenfluramine derivatives. *Eur Respir J* 2002;**20**:518–23.
- 26 Roberts KE, McElroy JJ, Wong WP, *et al.* BMPR2 mutations in pulmonary arterial hypertension with congenital heart disease. *Eur Respir J* 2004;**24**:371–4.
- 27 Runo JR, Vnencak-Jones CL, Prince M, *et al.* Pulmonary veno-occlusive disease caused by an inherited mutation in bone morphogenetic protein receptor II. *Am J Respir Crit Care Med* 2003;**167**:889–94.
- 28 Grant BJ, Lieber BB. Clinical significance of pulmonary arterial input impedance. *Eur Respir J* 1996;**9**:2196–9.
- 29 Burke CM, Glanville AR, Morris AJ, *et al.* Pulmonary function in advanced pulmonary hypertension. *Thorax* 1987;**42**:131–5.
- 30 Morris TA, Auger WR, Ysrael MZ, *et al.* Parenchymal scarring is associated with restrictive spirometric defects in patients with chronic thromboembolic pulmonary hypertension. *Chest* 1996;**110**:399–403.
- 31 Rich S, Dantzker DR, Ayres SM, *et al.* Primary pulmonary hypertension. A national prospective study. *Ann Intern Med* 1987;**107**:216–23.
- 32 Steenhuis LH, Groen HJ, Koeter GH, *et al.* Diffusion capacity and haemodynamics in primary and chronic thromboembolic pulmonary hypertension. *Eur Respir J* 2000;**16**:276–81.
- 33 Bonderman D, Nowotny R, Skoro-Sajer N, *et al.* Bosentan therapy for inoperable chronic thromboembolic pulmonary hypertension. *Chest* 2005;**128**:2599–603.
- 34 Ghofrani HA, Schermuly RT, Rose F, *et al.* Sildenafil for long-term treatment of nonoperable chronic thromboembolic pulmonary hypertension. *Am J Respir Crit Care Med* 2003;**167**:1139–41.
- 35 Ghofrani HA, Wiedemann R, Rose F, *et al.* Combination therapy with oral sildenafil and inhaled iloprost for severe pulmonary hypertension. *Ann Intern Med* 2002;**136**:515–22.
- 36 Hoeper MM, Kramm T, Wilkens H, *et al.* Bosentan therapy for inoperable chronic thromboembolic pulmonary hypertension. *Chest* 2005;**128**:2363–7.
- 37 Hughes R, George P, Parameshwar J, *et al.* Bosentan in inoperable chronic thromboembolic pulmonary hypertension (letter). *Thorax* 2005;**60**:707.
- 38 Hughes RJ, Jais X, Bonderman D, *et al.* The efficacy of bosentan in inoperable chronic thromboembolic pulmonary hypertension: a 1-year follow-up study. *Eur Respir J* 2006;**28**:138–43.
- 39 D'Alonzo. Survival in patients with primary pulmonary hypertension: results from a national prospective registry. *Ann Intern Med* 1991;**115**:343–9.
- 40 Hodgkins D, Sharples LC, Fowler SJ, *et al.* Survival in pulmonary hypertension: the Papworth experience. *American Thoracic Society Conference* 2005:A802.

PULMONARY PUZZLE

Prolonged fever, dyspnoea and diffuse pleural thickening in a 20-year-old man

Clinical presentation

A 20-year-old man was referred for intermittent high fever, night sweat and loss of body weight for 6 months associated with progressive exertional dyspnoea which developed 4 weeks before admission. The patient was unresponsive to antibiotics and 14 day pre-emptive antituberculous chemotherapy with rifampicin, isoniazid, ethambutol and pyrazinamide. His temperature was 39.8°C, heart rate 96 beats/min, blood pressure 110/70 mm Hg, breath rate 22/min with decreased breath sounds in the left upper thorax without cyanosis, clubbing and hepatosplenomegaly.

Laboratory examinations showed mild microcytic hypochromic anaemia, erythrocyte sedimentation rate 46 mm/h, severe restrictive airflow limitation with impairment of transfer factor. Blood biochemistry including angiotensin converting enzyme (ACE), electrolytes including calcium, immunological profiles including antinuclear antibody, extractable nuclear antigens, antineutrophil cytoplasmic antibody, and HIV antibody, tuberculin skin test, Ziehl-Neelsen stain, repeated blood culture, abdomen ultrasonography and fibrobronchoscopy were unremarkable.

Plain chest radiography showed bilateral pleural thickening without parenchymal abnormality. A high resolution CT

(HRCT) scan of the chest displayed thickening of the mediastinal, lateral and interlobar pleura (some >1 cm in thickness), multilobar subpleural pulmonary micronodules and thickening of bronchovascular bundles without intrathoracic adenopathy (fig 1A, B).

Question

What is the likely diagnosis and how should it be confirmed?

See page 637

This case was submitted by:

C Cai

Department of Pulmonology, General Hospital of Guangzhou Military Command, Guangzhou, China

D R Li, Q S Zeng, S Q Zhong, N S Zhong

Guangzhou Institute of Respiratory Disease, First Affiliated Hospital of Guangzhou Medical College, Guangzhou, China

Correspondence to: Dr Chuang Cai, Department of Pulmonology, General Hospital of Guangzhou Military Command, No 111 Lihua Rd, Guangzhou, China 510010; skinblack1966@yahoo.com.cn

doi: 10.1136/thx.2007.081232

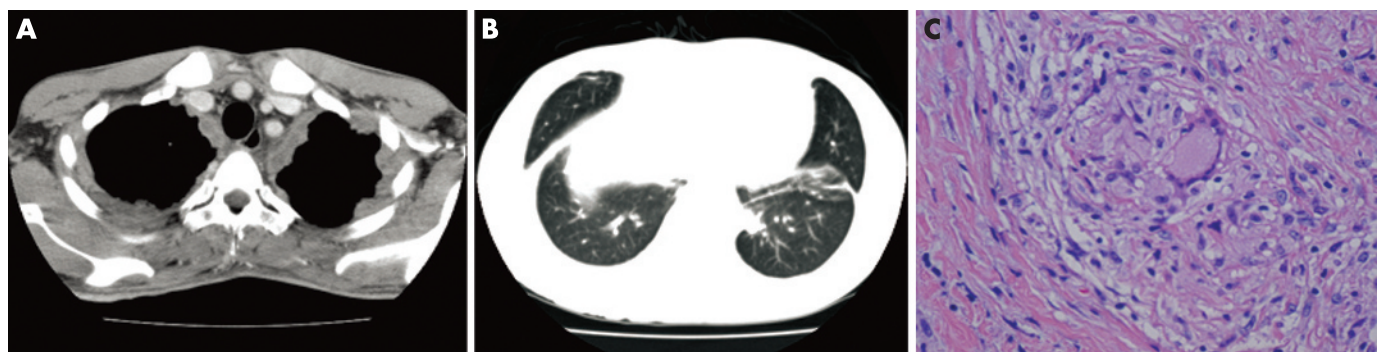


Figure 1 (A) High resolution CT (HRCT) scan showing diffuse thickening of lateral and mediastinal pleura with pleural nodularity, some >1 cm in thickness. (B) HRCT scan showing diffuse subpleural micronodules, thickening of bronchovascular bundles and thickening of interlobar septa. (C) Histological examination showing non-caseating epithelioid granuloma with focal central necrosis in biopsied pleura (H&E; ×400).