

Case reports

Pulmonary hypertension secondary to neurofibromatosis: intimal fibrosis versus thromboembolism

Noah Samuels, Neville Berkman, Eli Milgalter, Jacob Bar-Ziv, Gail Amir, Mordechai R Kramer

Abstract

Neurofibromatosis has been known to involve blood vessels throughout the body. Pulmonary involvement with interstitial fibrosing alveolitis has been described but no case of pulmonary vascular involvement has been reported to date. A 51 year old patient with cutaneous neurofibromatosis is described who presented with severe pulmonary hypertension and radiographic, scintigraphic, and angiographic evidence of chronic thromboembolic pulmonary hypertension. Severe intimal fibrosis consistent with vascular involvement with neurofibromatosis was found on endarterectomy with no evidence of pulmonary thromboembolism. Neurofibromatosis of pulmonary arteries should be considered as a possible cause of pulmonary hypertension.

(Thorax 1999;54:858–859)

Keywords: neurofibromatosis; pulmonary thromboembolism; intimal fibrosis

Neurofibromatosis, a common single gene disorder of the nervous system, has been found to involve the lungs with either parenchymal tumours or fibrosing alveolitis.¹ We present the case history of a patient with neurofibromatosis who developed severe pulmonary hypertension. Thromboembolic disease was initially suspected because of the findings on lung perfusion-ventilation scanning, spiral CT scanning, and pulmonary arteriography.

Case report

A 51 year old man with neurofibromatosis presented with progressive dyspnoea on exertion (NYHA class 3) whose symptoms progressed during the ensuing year. He had initially been diagnosed elsewhere as having primary pulmonary hypertension and received treatment with warfarin and nifedipine with no improvement in his condition. He denied chest pain, orthopnoea, or paroxysmal nocturnal dyspnoea, or any history of deep vein thrombosis or other thromboembolic disease. He also denied exposure to toxic inhalants, cigarette smoking, or use of appetite suppressants.

Physical examination showed a thin dyspnoeic (24 breaths/min) man without peripheral or central cyanosis. He had numerous cutaneous neurofibromas on both the upper and lower extremities with no café au lait pigmentations. No clubbing was found. He had a raised jugular venous pulse and mild pedal oedema. A fixed split second heart sound was heard, while the rest of the physical examination, including the chest, was normal. Laboratory results showed a normal blood count with normal renal and liver function tests. Studies for hypercoagulability were all within normal limits. Arterial blood gas tensions (on room air) were as follows: pH 7.45, Pco₂ 32 mm Hg, Po₂ 57 mm Hg, Sao₂ 91% with an alveolar–arterial gradient of 40 mm Hg.

The chest radiograph showed enlarged pulmonary arteries with no infiltrates or interstitial findings. Electrocardiography showed right ventricular hypertrophy and echocardiography revealed normal left ventricular size and function, dilated right atrium and ventricle, and severe pulmonary hypertension (estimated pulmonary artery gradient of 80–90 mm Hg transoesophageally).

Spirometric tests showed a forced vital capacity (FVC) of 3.39 l (77% predicted), forced expiratory volume in one second (FEV₁) of 2.59 l (73% predicted), and FEV₁/FVC of 76%. Corrected carbon monoxide transfer factor (TLCO) was 49% of the predicted value. A Doppler ultrasound investigation of the deep leg veins showed no evidence of thrombosis.

A ventilation-perfusion lung scan was performed and revealed large bilateral perfusion defects interpreted as highly probable for diffuse multiple pulmonary emboli. A subsequent spiral CT scan showed multiple bilateral filling defects in the pulmonary arterial tree. Pulmonary angiography was performed, showing multiple peripheral filling defects on the left and central defects in the right main pulmonary artery. Towards the end of this procedure an inferior vena caval filter (bird's nest) was inserted.

With a diagnosis of suspected major vessel chronic thromboembolic pulmonary hypertension the patient underwent pulmonary thrombendarterectomy of both left and right

Institute of Pulmonary Medicine

N Samuels
N Berkman
M R Kramer

Department of Cardiothoracic Surgery

E Milgalter

Department of Radiology

J Bar-Ziv

Department of Pathology

G Amir

Hadassah University Hospital, Jerusalem, Israel 91120

Correspondence to:
Dr M R Kramer, Institute of Pulmonary Medicine, Rabin Medical Center (Beilinson), Petah Tikva, Israel 49100.

Received 23 June 1997
Returned to author
24 October 1997
Revised manuscript received
16 January 1998
Accepted for publication
30 January 1998

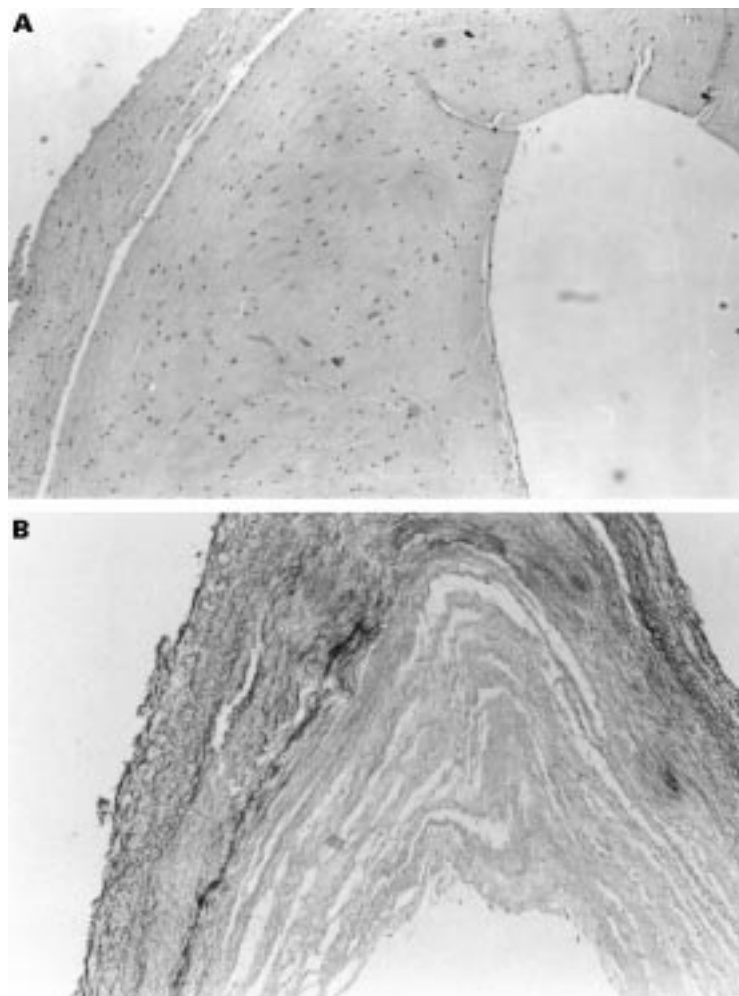


Figure 1 Microscopic section of a biopsied pulmonary artery. (A) Haematoxylin-eosin stain ($\times 100$) shows a thin rim of media and extensive irregular thickening of the intima by fibrous tissue. No evidence of thromboembolic disease was found. (B) Elastic van Gieson stain ($\times 100$) shows fragmentation of the elastic layers in the media and marked fibrous intimal thickening in another area of the same artery.

pulmonary arteries and their major branches. Preoperative catheterisation showed a cardiac index of 3.38 l/min/m^2 and a pulmonary vascular resistance index of $236.7 \text{ dyne.s.min}^2/\text{cm}^5$. No evidence of thrombi was found at surgery, while severe diffuse intimal thickening was noted throughout the pulmonary vessels. Because of the widespread involvement of the pulmonary vasculature, stenting of the arteries was not attempted. The pathological specimens taken from the endarterectomy showed extensive irregular thickening of the intima by fibrous tissue (fig 1).

The patient was discharged after a protracted postoperative stay in hospital and an echocardiogram performed four months later showed a systolic gradient on the tricuspid valve with an estimated pulmonary arterial pressure of 47 mm Hg . At this time his functional status had also improved (NYHA class 1–2).

Discussion

Pulmonary involvement in patients with neurofibromatosis has been reported with both neurofibromatous tumours within the lung parenchyma and with fibrosing alveolitis.¹ In

our patient no evidence of either of these conditions was found on CT scanning or by measurement of the TLCO. To the best of our knowledge, involvement of the pulmonary arteries with neurofibromas has not previously been reported although vascular complications of neurofibromatosis have been seen in other organ systems. The retinal,² lumbar,³ mesenteric,⁴ and renal arteries⁵ have all been reported to be involved with neurofibromatosis, as have both the intracranial and extracranial arteries.⁶ The generalised mesenchymal dysplasia of neurofibromatosis predisposes these arteries to rupture or aneurysm formation.⁶ Biopsy specimens of the arterial wall in these patients have shown marked intimal thickening with proliferation of fibroblastic spindle cells.^{4,5} Histopathological studies have found expression of neurofibromatosis mRNA in cells of the tunica intima of involved blood vessels.⁷ In addition, rapidly growing neurofibromas show a higher proportion of insulin-like growth factor 1 immunoreactivity in vascular cells (endothelial cells, smooth muscle cells, and fibroblasts) than in slower growing tumours.⁸

Our patient presented with severe pulmonary hypertension and findings mimicking chronic thromboembolic pulmonary hypertension, a diagnosis supported by the ventilation-perfusion scan, spiral CT scan, and angiography. Biopsy specimens of the arterial wall showed changes consistent with those found in other patients with vascular involvement with neurofibromatosis, changes which apparently caused the vasculo-occlusive picture found in the tests described.

In conclusion, we have described a case of pulmonary hypertension secondary to involvement of the pulmonary arterial tree with intimal fibrosis due to neurofibromatosis. This entity must be considered in the differential diagnosis of pulmonary hypertension found in patients with neurofibromatosis as it can mimic clinical and angiographic evidence of thromboembolic disease. Although endarterectomy resulted in partial improvement in the pulmonary hypertension in our patient, the value of this procedure remains unclear.

- 1 Massaro D, Katz S. Fibrosing alveolitis: its occurrence, roentgenographic and pathologic features in von Recklinghausen's neurofibromatosis. *Am Rev Respir Dis* 1966;93:934–42.
- 2 Moadel K, Yannuzzi LA, Ho AC, et al. Retinal vascular occlusive disease in a child with neurofibromatosis. *Arch Ophthalmol* 1994;112:1021–3.
- 3 Shimizu Y, Tanaka T, Nakae A, et al. A case report of spontaneous rupture of bilateral lumbar artery in a patient with von Recklinghausen disease. *Nippon Geka Gakkai Zasshi* 1993;94:420–3.
- 4 Tatemichi M, Nagata H, Morinaga S, et al. Protein-losing enteropathy caused by mesenteric vascular involvement of neurofibromatosis. *Dig Dis Sci* 1993;38:1549–53.
- 5 Westenend PJ, Smedts F, de Jong MC, et al. A 4 year old boy with neurofibromatosis and severe renovascular hypertension due to renal arterial dysplasia. *Am J Surg Pathol* 1994;18:512–6.
- 6 Schievink WI, Michels VV, Piepgras DG. Neurovascular manifestations of heritable connective tissue disorders: a review. *Stroke* 1994;25:889–903.
- 7 Ahlgren-Beckendorf JA, Maggio WW, Chen F, et al. Neurofibromatosis 1 mRNA expression in blood vessels. *Biochem Biophys Res Commun* 1993;197:1019–24.
- 8 Hansson HA, Brandsten C, Lossing C, et al. Transient expression of insulin-like growth factor I immunoreactivity by vascular cells during angiogenesis. *Exp Mol Pathol* 1989; 50:125–38.

Laryngeal aspergillosis following high dose inhaled fluticasone therapy for asthma

A J Fairfax, V David, G Douce

Abstract

The case history is presented of a 75 year old man with chronic asthma who was treated with inhaled fluticasone propionate in a daily dose of 2 mg using a Diskhaler. After three years of treatment he developed progressive hoarseness. Both vocal cords were colonised by *Aspergillus fumigatus* which formed a white slough on the surface. Biopsy specimens showed changes suggestive of laryngeal aspergillosis with an ulcerated epithelium, fibrinopurulent debris, and colonies of fungal hyphae. A slow recovery occurred after three months of treatment with topical amphotericin and with cessation of inhaled corticosteroids. Laryngoscopy is recommended if hoarseness occurs during treatment with fluticasone.

(Thorax 1999;54:860–861)

Keywords: laryngeal aspergillosis; *Aspergillus fumigatus*; asthma; fluticasone propionate

Hoarseness is a well recognised complication of treatment with inhaled beclomethasone and budesonide. Fluticasone has greater glucocorticoid receptor potency as a topical steroid. We report a serious complication of fungal colonisation of the larynx with *Aspergillus fumigatus* which occurred during treatment of asthma with high doses of fluticasone.

Case report

The patient, a 75 year old man, had started treatment with inhaled corticosteroids for asthma in December 1986. He had smoked approximately six cigarettes a day for 40 years until 1975. Lung function testing between 1986 and 1997 showed some irreversible airflow obstruction: forced expiratory volume in one second (FEV₁) was in the range 1.0–2.2 litres (72% predicted). Gas transfer factor and diffusion constant were normal and there was no clinical evidence of emphysema. Sputum samples showed numerous eosinophils. IgE was 101 kU/l (normal <200) and the α_1 -antitrypsin level was 1.6 g/l. Repeated blood counts showed no eosinophilia. Skin allergy tests, including tests to *Aspergillus fumigatus*, were negative. There was no clinical evidence of immunosuppression. He suffered from mild osteoporosis and oral steroids were therefore avoided. He had had a bilateral orchidectomy for carcinoma of the prostate in 1986. A repeat TURP operation and staging in 1995 showed no evidence of residual disease. In 1987, after accidentally choking on a lump of food, an indirect laryngoscopy showed a normal larynx.

Between 1986 and November 1993 he was treated with inhaled bronchodilators and beclomethasone in a dose of 2 mg daily. Because of persistent symptoms his GP changed the corticosteroid to fluticasone 1 mg twice daily using a Diskhaler. Although there was no evidence of improvement, this dose was continued for just over three years. In December 1996 he had influenza (confirmed by raised influenza A titre) which exacerbated his chest. He presented in February 1997 with a five week history of progressive hoarseness of the voice which resulted in complete aphonia. Fibreoptic bronchoscopy showed white slough on both vocal cords and a small ulcer at the carina. A micro-laryngoscopy was performed and biopsy samples of both cords were taken, followed by stripping of the slough under direct vision. The biopsy samples showed abundant fibrinopurulent debris, inflamed ulcerated epithelium, and masses of fungal hyphae identified morphologically and on culture as *Aspergillus fumigatus*. Inhaled corticosteroids were discontinued and the patient was treated with nebulised bronchodilator therapy and nedocromil. Amphotericin lozenges, 10 mg four times daily, were given. After four weeks his voice showed some improvement. A repeat bronchoscopic examination after seven weeks showed apparently normal vocal cords (although he was still hoarse). The ulcer at the carina had healed completely. After 14 weeks from onset his voice was still gruff but intelligible. *Aspergillus* precipitins were weakly positive during the illness, becoming negative after the laryngeal aspergillosis had resolved.

The patient has been followed up for 13 months since the onset of laryngeal aspergillosis. He has refused all inhaled corticosteroid preparations and there has been no recurrence of the fungal infection. Rather surprisingly, his lung function during 1997 improved while taking a combination of regular nedocromil and salmeterol with nebulised doses of bronchodilators as required. He has had two admissions to hospital for asthma during this period.

Discussion

Hoarseness is a recognised complication of inhaled steroid therapy. Overall, it has been reported in 2% of adults receiving fluticasone (n = 3640) and in 1% of patients on beclomethasone.¹ In a one year study of asthmatic patients treated with 1.5 mg of fluticasone propionate daily, hoarseness was reported in 6% of patients.² Fluticasone is a fluorinated corticosteroid with a greater topical potency and greater tissue retention and a

Departments of
Respiratory Medicine,
Ear, Nose & Throat
Surgery and
Pathology,
Staffordshire General
Hospital, Weston
Road, Stafford
ST16 3SA, UK
A J Fairfax
V David
G Douce

Correspondence to:
Dr A J Fairfax.

Received 15 September 1997
Returned to author
12 January 1998
Revised manuscript received
11 February 1998
Accepted for publication
2 March 1998

longer elimination half life than beclomethasone.³ Dose for dose, some side effects such as adrenal suppression reflect this greater activity.⁴

Corticosteroids are known to enhance fungal colonisation of epithelial surfaces. Oropharyngeal candidiasis is a well recognised side effect and this complication has been reported in 4% of patients given fluticasone in a dose of 1.5–2 mg daily.^{2,5} It is known that a substantial proportion of inhaled corticosteroid through dry powder devices is deposited in the upper airway, including the larynx. Colonisation of the larynx by *Aspergillus fumigatus* is therefore likely to be a direct consequence of the deposition of topical corticosteroid on the superior surface of the vocal cords.

Primary aspergillosis localised to the larynx is an extremely rare condition. A literature search over 30 years has produced fewer than 12 cases in total. Presentation with hoarseness is characteristic.^{6–8} The rarity of aspergillosis emphasises the normal resistance of the larynx to colonisation by fungi, including *Aspergillus*, despite the presence of spores in inhaled air. In the absence of generalised immunosuppression, laryngeal aspergillosis has been treated with debridement alone or with topical antifungal drugs.⁹ In our case the condition slowly cleared with cessation of fluticasone therapy

and treatment with topical amphotericin given as lozenges.

We suggest that patients who develop hoarseness while taking fluticasone propionate, particularly in doses above 1 mg daily, should be fully investigated by laryngoscopy and, if necessary, biopsy specimens should be taken and fungal cultures performed. The case highlights possible adverse effects which may result from the current tendency of general practitioners to use very high doses of inhaled corticosteroid therapy, sometimes without any improvement in the control of asthma.

- 1 International Registration Dossier, Allen & Hanburys Limited.
- 2 Fabbri L, Burge PS, Croonenborgh L, et al. Comparison of fluticasone propionate with beclomethasone dipropionate in moderate to severe asthma treated for one year. *Thorax* 1993;48:817–23.
- 3 Harding SM. The human pharmacology of fluticasone propionate. *Respir Med* 1990;84:25–9.
- 4 Clarke DJ, Lipworth BJ. Adrenal suppression with chronic dosing of fluticasone propionate compared with budesonide in adult asthmatic patients. *Thorax* 1997;52:55–8.
- 5 Ayres JG, Bateman ED, Lundback B, et al. High dose fluticasone propionate, 1 mg daily, versus fluticasone propionate, 2 mg daily, or budesonide, 1.6 mg daily, in patients with chronic severe asthma. *Eur Respir J* 1995;8:579–86.
- 6 Rao PB. Aspergillosis of larynx. *J Laryngol Otol* 1969;83:377–9.
- 7 Ferlito A. Primary aspergillosis of the larynx. *J Laryngol Otol* 1974;88:1257–63.
- 8 Kheir SM, Flint A, Moss JA. Primary aspergillosis of the larynx simulating carcinoma. *Hum Pathol* 1983;14:184–6.
- 9 Benson-Mitchell R, Tolley N, Croft CB, et al. Aspergillosis of the larynx. *J Laryngol Otol* 1994;108:883–5.

LETTERS TO THE EDITOR

Beta agonist dose reduction in asthma

I write with regard to the article by Harrison *et al*¹ who described their findings of reducing β agonist use in asthma patients with a methodology involving placebo inhalers. This study describes an interesting design as well as interesting outcomes with an apparent reduction in β agonist use without loss of control.

There are several pieces of information which would make the article more useful in understanding how widely these results may be extrapolated. Firstly, the baseline inhaled corticosteroid use and the distribution between the two groups is important information. It would also help if the authors of the paper could clarify whether the patients continued on their usual maintenance inhaled corticosteroids throughout the study and whether the budesonide that was added at weeks 4–6 was in addition to baseline steroid use. The next issue concerns the instructions the patients were given about the use of β agonists. How many of them were told to use doses on a four times a day basis rather than as required? I also would like to know the proportion of patients who recognised they were receiving placebo with no active medication compared with those who were not aware that they had been switched to placebo. Finally, were specific instructions given to patients that they might need to ignore some

some symptoms of breathlessness to enable the reduction in the use of β agonists?

The above information would be helpful in understanding more completely the population and how applicable this dosage reduction scheme may be to other patients with asthma.

D RUFFIN

Head, Division of Medicine,
The Queen Elizabeth Hospital Campus,
Woodville South,
South Australia 5011

- 1 Harrison TW, Osborne J, Wilding PJ, et al. Randomised placebo controlled trial of β agonist dose reduction in asthma. *Thorax* 1999;54:98–102.

AUTHOR'S REPLY We thank Dr Ruffin for his interest and comments on our randomised placebo controlled trial of β agonist dose reduction in asthma.¹ The mean (range) baseline inhaled steroid dose was 600 (300–1000) $\mu\text{g}/\text{day}$ in the β agonist reduction group and 757 (200–1200) $\mu\text{g}/\text{day}$ in the control group (difference not significant). Six subjects were taking budesonide, one fluticasone propionate, and the remainder beclomethasone dipropionate, and all but one via a metered dose inhaler. Dr Ruffin is correct in stating that the two weeks of budesonide was in addition to the subjects' usual inhaled steroid, the dose of which was unchanged for the duration of the study. All subjects were given their usual dose of β agonist as terbutaline in four divided doses with additional terbutaline as required. We are unable to comment on the number of subjects who correctly guessed they were on placebo, but since the use of as required terbutaline was similar in each group there was probably not an important difference. Finally, subjects were not given any special instructions about ignoring their symptoms but all were informed that they had a

50% chance that their "regular" study inhaler would contain placebo. Clearly, one explanation for our findings is that many subjects take their β agonist out of habit or for non-asthma symptoms and can therefore withdraw it without leading to a deterioration in lung function or an increase in asthma symptoms.

T W HARRISON

Division of Respiratory Medicine,
City Hospital,
Nottingham NG5 1PB,
UK

- 1 Harrison TW, Osborne J, Wilding PJ, et al. Randomised placebo controlled trial of β -agonist dose reduction in asthma. *Thorax* 1999;54:98–102.

Effect of inhaled corticosteroid therapy on bone markers and bone density

Hughes and associates are to be congratulated on their important study evaluating the effect of high dose inhaled steroids on bone markers and bone mineral density.¹ High dose inhaled corticosteroid therapy has been associated with a decrease in serum osteocalcin levels and a negative effect on bone density.² Surprisingly, Hughes *et al* found that osteocalcin and bone mineral density increased in patients receiving high dose inhaled corticosteroids. Possible reasons for these unexpected results could be that patients maintained adequate calcium and vitamin D intake, an appropriate level of weight bearing exercise, were mostly non-smokers, and had limited alcohol ingestion.³ Unfortunately, the article does not report the calcium and

vitamin D intake, an appropriate level of weight bearing exercise, were mostly non-smokers, and had limited alcohol ingestion.² Unfortunately, the article does not report the calcium and vitamin D intakes of the participants. This is important since calcium and vitamin D may prevent corticosteroid induced bone loss.³ Whether pharmacological interventions prevent osteoporosis in patients receiving long term inhaled glucocorticoids is an important question that remains to be answered.

MARIE-FRANCE BEAUCHESNE

Faculty of Pharmacy,
Pharmacy Department,
Hôpital Sacré-Cœur de Montréal,
5400 Boulevard Gouin Ouest,
Montréal (Québec),
Canada H4J 1C5

- 1 Hughes JA, Conry BG, Male SM, *et al.* One year prospective open study of the effect of high dose inhaled steroids, fluticasone propionate, and budesonide on bone markers and bone mineral density. *Thorax* 1999;54:223-9.
- 2 Ledford D, Apter A, Brenner AM, *et al.* Osteoporosis in the corticosteroid-treated patient with asthma. *J Allergy Clin Immunol* 1998; 102:353-63.
- 3 Buckley LM, Leib ES, Cartularo KS, *et al.* Calcium and vitamin D3 supplementation prevents bone loss in the spine secondary to low-dose corticosteroids in patients with rheumatoid arthritis. A randomized, double-blind, placebo-controlled trial. *Ann Intern Med* 1996; 125:961-8.

AUTHORS' REPLY Marie-France Beauchesne highlights the rise in serum osteocalcin levels and bone mineral density seen in our study and raises possible reasons for this result. The study did not obtain data on calcium and vitamin D intake but no patients received supplemental calcium or vitamin D during the study period. Exercise was broken down into light (32%), moderate (56%), and heavy (12%) average weekly physical exercise; 83% of the patients were non-smokers and 17% were current smokers; 31% drank no alcohol and, of the 69% consuming alcohol, the weekly median intake was 5 units (25th percentile 2.0; 75th percentile 14).

Although calcium and vitamin D intake is clearly important in assessing overall bone loss, our patients were not taking supplements and therefore this should not have influenced the rise in bone mineral density and osteocalcin levels seen in the study.

Of our study population 76% had been taking beclomethasone dipropionate prior to being enrolled in the study and, as both Egan *et al*¹ and Pauwels *et al*² reported either no change or increases in bone mineral density in patients on fluticasone propionate but decreases in those taking beclomethasone dipropionate, the type of inhaled corticosteroid may be important in determining bone mineral density and bone marker changes over time. Furthermore, Ford *et al*³ found no differences in lumbar bone mineral density after a two year period when 500 µg fluticasone propionate given twice daily via a diskhaler was compared with placebo.

Future studies are therefore needed to differentiate between possible effects from specific inhaled corticosteroids. General

statements concerning the safety and efficacy of inhaled corticosteroids need to take into account these differences.

J A HUGHES
Kent & Sussex Hospital,
Tunbridge Wells,
Kent TN4 8AT, UK

- 1 Egan J, Kalra S, Adams J, *et al.* A randomised double blind study comparing the effects of beclomethasone dipropionate 2000 µg/day vs fluticasone propionate 1000 µg/day on bone density over 2 years. *Thorax* 1995;50(Suppl 2):A78.
- 2 Pauwels RA, Yernault JC, Demedts MG, *et al.* Comparison of long term safety and efficacy of fluticasone propionate and beclomethasone dipropionate in patients with moderate to severe asthma. *Am J Respir Crit Care Med* 1998;157:827-32.
- 3 Ford LB, Welsberg S, Chervinsky P, *et al.* Effects of fluticasone propionate rotadisk on the adrenal, ophthalmic and skeletal systems after 2 years of treatment. *Am J Respir Crit Care Med* 1997;155:A354.

Summer tuberculosis

We wish to confirm previous reports of the seasonality of tuberculosis.^{1,2} The Second National Prevalence Study (SNPS) documented the prevalence of hospital and community acquired infections in 37 111 hospitalised patients in 157 centres in the UK and Ireland between 1993 and 1994.³ Hospital acquired lower respiratory tract infections were reported in 2.4% of the population (882 cases). Community acquired lower respiratory tract infections were reported in 6.1% of patients (2282 cases), of which 55 cases were tuberculosis. The prevalence rate of community acquired tuberculosis in the winter quarters (January to March, October to December) was 1.0/1000 patients and doubled in the summer months (April to June, July to September) to 1.9/1000 patients (OR 1.72, 95% CI for OR 1.0 to 2.97, $p \leq 0.05$). The mechanism for such an increase in prevalence is unclear, although it is hypothesised that the seasonal fluctuation in vitamin D serum levels may contribute to impaired host defence mechanisms to *Mycobacterium tuberculosis*.^{1,4} We are unaware of any publication relating to the date of onset of symptoms as opposed to the date of diagnosis or notification. Are people more tolerant of coughs in the winter?

M C KELSEY
C A MITCHELL
Department of Microbiology,
Whittington Hospital,
Highgate Hill,
London N19 5NE, UK

M GRIFFIN
Department of Primary Care & Population Science,
Royal Free & University College Medical School,
Archway Campus,
Highgate Hill,
London N19 5NE, UK

A M EMMERSON
Division of Microbiology,
Infectious Diseases & PHLS,
University Hospital,
Queen Mary's Centre,
Nottingham NG7 2UH, UK

- 1 Medical Research Council Tuberculosis and Chest Diseases Unit. National survey of tuberculosis notifications in England and Wales, 1978-9. *BMJ* 1980;281:895-8.
- 2 Douglas AS, Strachan DP, Maxwell JD. Seasonality of tuberculosis: the reverse of other respiratory diseases in the UK. *Thorax* 1996;51: 944-6.
- 3 Emmerson AM, Enstone J, Kelsey MC. The second national prevalence survey of infections in hospitals: methodology. *J Hosp Infect* 1995; 30:7-29.
- 4 Davies PDO. Seasonality of tuberculosis (letter). *Thorax* 1997;52:398.

NOTICES

Biology of Air Pollution

A meeting on the Biology of Air Pollution organised by the British Association for Lung Research, the Institute of Biology and the British Society for Immunology will be held at the Science Societies Lecture Theatre, London on 25 and 26 October 1999. The meeting will bring together the various specialities concerned with the biology of air pollution including history, sources, epidemiology, molecular/cell biology, pulmonary and cardiovascular aspects. For further details contact Jonathan Cowie, Institute of Biology, 20-22 Queensberry Place, London SW7 2DZ.

20th International Symposium on Intensive Care and Emergency Medicine

The 20th International Symposium on Intensive Care and Emergency Medicine will be held on 21-24 March 2000 at the Congress Center in Brussels, Belgium. For further information contact Carl Vanhaesendonck, Telephone: 322 555 3215/3631. Fax: 322 555 4555. email: sympicu@ulb.ac.be.

Pharmacology of Asthma

A course on the "Pharmacology of Asthma" organised by Professor Peter Barnes will be held at the Imperial College School of Medicine at the National Heart & Lung Institute in collaboration with the Royal Brompton Hospital on 22-25 November 1999. For further information contact the Postgraduate Education Centre, National Heart & Lung Institute, Imperial College School of Medicine, Dovehouse Street, London SW3 6LY, UK. Tel: 0171 351 8172; fax: 0171 376 3442.