

Case reports

Non-Hodgkin's lymphoma arising in cryptogenic fibrosing alveolitis

T R Orchard, C D Eraut, A G Davison

Abstract

The case report is presented of a patient with longstanding cryptogenic fibrosing alveolitis who developed a high grade B cell non-Hodgkin's lymphoma in an area of fibrosis.

(Thorax 1998;53:228-229)

Keywords: cryptogenic fibrosing alveolitis; non-Hodgkin's lymphoma; bronchus associated lymphoid tissue (BALT)

Carcinoma of the lung and pulmonary fibrosis may be associated,¹⁻³ particularly in cryptogenic fibrosing alveolitis (CFA)^{1,2} and scar tissue.³ However, there have been no reports of intrathoracic non-Hodgkin's lymphoma originating in such tissue. We report the development of a high grade B cell non-Hodgkin's lymphoma in an area of fibrosis in a case of longstanding CFA.

Case report

A 76 year old woman was admitted to hospital with a two week history of being confined to bed by lethargy, shortness of breath, and abdominal pain. Her appetite was poor and she had lost 8 kg in weight over the previous three months.

Three years previously she had presented with increasing dyspnoea. On examination she had finger clubbing and bilateral basal crackles. Thin section high resolution computed tomographic (CT) scanning of the lungs showed bilateral basal reticular shadowing consistent with fibrosing alveolitis, and transbronchial biopsy specimens showed interstitial fibrosis. She had smoked 20 cigarettes a day for 40 years until three years previously. Her pulmonary function tests showed a mixed restrictive and obstructive ventilatory defect with an FEV₁/FVC ratio of 70%, a total lung capacity of 75%, and transfer factor approximately 50% of predicted. She made a good symptomatic response to steroid therapy and had remained well for two years.

Examination on admission revealed a low grade pyrexia of 37.2°C, bilateral inspiratory crackles at the lung bases, and some mild epigastric tenderness. There was no palpable

lymphadenopathy. Investigations on admission revealed an anaemia of 9.8 g/dl with anisocytosis, polychromasia, and poikilocytosis. Her total white cell count was raised at $33.8 \times 10^9/l$ with a neutrophilia of $31.7 \times 10^9/l$ and normal lymphocyte count. Her ESR was 123 mm/hour. Chest radiography demonstrated bilateral basal reticulonodular shadowing consistent with CFA but the shadowing at the left base had increased. Ultrasound scanning of the abdomen was normal. A CT scan of the chest demonstrated a mass associated with collapse of the anterolateral segment of the left lower lobe.

Unfortunately the patient's condition deteriorated rapidly after admission and she died 10 days later. Post mortem examination revealed a wedge shaped tumour measuring 7.0 cm in maximum diameter at the base of the left lower lobe. The remainder of this lobe was congested. There was also marked bilateral enlargement of the hilar lymph nodes and nodes within the angle of the bifurcation of the trachea. This was greater on the left side with the largest node measuring 4.0 cm in diameter and being situated behind the left main bronchus. Histological examination confirmed bilateral fibrosis consistent with cryptogenic fibrosing alveolitis and demonstrated that the tumour in the left lower lobe was a high grade non-Hodgkin's lymphoma with mediastinal lymph node involvement. The infiltrate showed features of a diffuse large lymphoid cell non-Hodgkin's lymphoma (a grade II lymphoma). The tumour cells stained positive for CD20 and CD79a, indicating their B cell lineage. This was therefore a high grade B cell lymphoma with no evidence of a low grade BALT (bronchus associated lymphoid tissue) lymphoma. There was no evidence of lymphoma elsewhere at necropsy.

Discussion

It is recognised that patients with CFA have an increased relative risk of developing lung cancer, even allowing for other factors such as smoking.¹ Previously it has been noted that there is an increased incidence of malignant lung tumours, particularly adenocarcinomas and bronchiolar-alveolar carcinomas, in fibrotic scars in the lung.^{2,3} Although intrathoracic involvement in non-Hodgkin's lymphoma is common (occurring in about 10-25% of cases),^{4,5} it has not been described arising in an area of CFA.

The most common intrathoracic manifestations of non-Hodgkin's lymphoma are mediastinal, hilar and paratracheal lymphadenopathy, although pleural effusions and lone pulmonary manifestations may occur.^{4,5} The latter may consist of single or multiple nodules, pneumonic areas, or peribronchial infiltration.⁴ The prognosis for those with single or multiple

Heart and Chest
Clinic, Southend
Hospital, Westcliff on
Sea, Essex SS0 0RY,
UK

T R Orchard
C D Eraut
A G Davison

Correspondence to:
Dr C D Eraut.

Received 7 October 1996
Returned to authors
16 December 1996
Revised version received
24 March 1997
Accepted for publication
14 April 1997

pulmonary nodules and pleural effusion is generally poor,⁴⁻⁶ all cases being associated with extrathoracic manifestations of lymphoma in one study.⁴ The prognosis is more favourable in patients who have lymphadenopathy in the absence of other signs of intrathoracic involvement. In this case the lymphoma in the lung parenchyma was associated with mediastinal lymph node involvement without signs of extrathoracic disease and was therefore a primary lymphoma of the lung.

The commonest form of primary lung lymphoma arises from bronchus associated lymphoid tissue (BALT).⁷ It is a low grade B cell lymphoma, similar histologically to MALTomas of the gastrointestinal tract. However, unlike the mucosal associated lymphoid tissue (MALT) in the gut, BALT is found in only a minority of humans, although it is more prevalent in other species.⁸ Its role in normal immune regulation in the lung is not fully understood, but it is known that certain conditions, including smoking,⁹ can induce the presence of BALT. The effect of CFA on the presence or absence of BALT is, however, unknown.

In this case the lymphoma was high grade and it was of B cell origin. BALTomas have been found to undergo transformation to high grade lymphomas in a small number of cases⁷ where there is histological evidence of low grade BALT tumour in addition to the high grade lymphoma. However, in this case there was no histological evidence of BALT derived tumour. Isolated high grade B cell tumours are also described as are primary T cell lymphomas, although rare, and high grade unclassifiable tumours accounted for 3.2% of lymphomas in one study.⁷ It is therefore possible that in this case the lymphoma was a BALToma that had undergone transformation to a high grade lymphoma or a primary high grade B cell lymphoma.

Histologically, CFA is characterised by an inflammatory infiltrate in which lymphocytes may predominate and lymphoid aggregates occur. Subsequently there is fibrosis and disruption of normal pulmonary architecture. Other conditions which cause a chronic stimulation of the lymphoid system such as Hashimoto's thyroiditis¹⁰ and gluten enteropathy¹¹ have an increased incidence of lymphoma. It is therefore possible that, in recruiting lymphocytes into the affected area and by causing chronic lymphocytic stimulation, the disease process of CFA creates an environment which predisposes to the development of lymphoma. This may be a direct effect of lymphocyte recruitment or may be mediated by the induction and subsequent malignant transformation of bronchus associated lymphoid tissue.

We thank Dr D Donald, consultant pathologist, and Dr A Lamont, consultant oncologist, for their help in the preparation of this report.

- 1 Turner-Warwick M, Lebowitz M, Burrows B, *et al.* Cryptogenic fibrosing alveolitis and lung cancer. *Thorax* 1980;35:496-9.
- 2 Jones AW. Alveolar cell carcinoma in idiopathic pulmonary fibrosis. *Br J Dis Chest* 1970;64:78-84.
- 3 Spencer H. *Pathology of the lung*. Oxford: Pergamon Press, 1985.
- 4 Manoharan A, Pitney WR, Schonell ME, *et al.* Intrathoracic manifestations in non-Hodgkin's lymphoma. *Thorax* 1979;34:29-32.
- 5 Jenkins PF, Ward MJ, Davies P, *et al.* Non-Hodgkin's lymphoma, chronic lymphatic leukaemia and the lung. *Br J Dis Chest* 1981;75:22-30.
- 6 Weick JK, Kiely JM, Harrison EG, *et al.* Pleural effusion in lymphoma. *Cancer* 1970;30:848-53.
- 7 Li G, Hansmann M-L, Zwingers T *et al.* Primary lymphomas of the lung: morphological, immunohistochemical and clinical features. *Histopathology* 1990;16:519-31.
- 8 Pabst R, Gehrke I. Is the bronchus-associated lymphoid tissue (BALT) an integral structure of the lung in normal mammals, including humans? *Am J Respir Cell Mol Biol* 1990;3:131-5.
- 9 Richmond I, Pritchard GE, Ashcroft T, *et al.* Bronchus associated lymphoid tissue (BALT) in human lung: its distribution in smokers and non-smokers. *Thorax* 1993;48:1130-4.
- 10 Burke JS, Butler JJ, Fuller LM. Malignant lymphomas of the thyroid. *Cancer* 1977;39:1587.
- 11 Swinson GM, Slavin G, Coles EC, *et al.* Coeliac disease and malignancy. *Lancet* 1983;i:111.

A vibrating trachea

M J Doherty, D P S Spence, D Graham,
B M G Cheetham, X Q Sun, J E Earis

Abstract

A case of relapsing polychondritis presenting as tracheomalacia is reported in which an unusual low pitched sound was heard at the mouth and over the chest wall during expiration. The sound was associated with expiratory airflow limitation and oscillation on the flow trace of approximately 50 Hz. Spectral analysis of the sound showed it to have the characteristics of sounds produced by flutter in flow limited flexible tubes. These observations suggest that the sound was produced by airflow induced flutter in the trachea and main airways and is further evidence in support of the dynamic flutter theory of wheeze production.

(Thorax 1998;53:230-231)

Keywords: relapsing polychondritis; tracheomalacia; wheeze; spectral analysis

Relapsing polychondritis is an uncommon condition in which recurrent episodes of inflammation lead to destruction of cartilage, most commonly in the ear, nose, joints and the respiratory tract.¹ When the respiratory tract is affected the loss of cartilaginous support in the trachea and main bronchi (tracheomalacia) results in airflow obstruction, failure to expectorate sputum, and recurrent infections. We report such a case which was associated with the production of an unusual expiratory sound. The spectral analysis of this sound and its relationship to airflow is presented. Possible mechanisms of sound production are discussed and related to the current theories of dynamic flutter and wheeze in floppy tubes.

Case report

A 55 year old woman who was a life long non-smoker with no history of previous chest disease was admitted to hospital with a two month history of dyspnoea and wheeze. On examination she was obese, tachypnoeic, and a low pitched expiratory "wheezing" sound was heard at the mouth. On auscultation the sound occurred on deep and forced breathing but not with tidal breathing. It was present in all areas but was loudest over the upper anterior chest wall. Investigations revealed airflow obstruction (FEV₁ 0.9 l, FVC 2.0 l, FEV₁ 35% of predicted normal), a normal chest radiograph, and a mild eosinophilia. A diagnosis of late onset asthma was made and treatment with inhaled β agonists, inhaled corticosteroids, and oral aminophylline was started. She did not respond to this medication and further investigations were undertaken.

A flow-volume loop showed attenuation most marked in the expiratory limb (PEFR

0.8 l/s, PIFR 1.86 l/s). The overall pattern of the flow-volume envelope was characteristic of major airway intrathoracic obstruction.² When superimposed, the tidal and maximal expiratory envelopes coincided suggesting that global airflow limitation had occurred during tidal breathing. An obvious saw tooth oscillation with a frequency of approximately 50 Hz, occurring at the same time as the low pitched expiratory sound, was also present on the expiratory limb of the flow trace (fig 1A).

Fibreoptic bronchoscopy under local anaesthetic revealed tracheobronchomalacia, the trachea, lobar and segmental bronchi collapsing on expiration with the anterior and posterior walls touching on forced manoeuvres. There were no abnormalities of the ear lobes, nose or joints to suggest that the cause of the tracheomalacia was due to relapsing polychondritis.

A recording of the sound was made using an air coupled electret condenser microphone (Monacor, ECM-2002, Radioshack; free field frequency response in air 50-16 000 Hz) placed on the upper right anterior chest wall. The sound was recorded onto magnetic tape using a frequency modulated (FM) tape recorder (Store 7D, Racal Electronics, Southampton, UK). Simultaneously, flow measured by a Fleisch no. 3 pneumotachograph was recorded onto a second channel. The recorded sounds were low pass filtered by a fourth order active Butterworth-type analogue filter with cut off frequency of 1.6 kHz and digitised at a sampling rate of 4 kHz with a 12 bit analogue to digital converter. Overlapping 128 point (32 ms) segments were spectrally analysed using a Fast Fourier Transforms (FFT) algorithm with a Hanning window (Ultra Digital Systems, C3M, interfaced to an IBM PC compatible computer).

Ten randomly chosen expiratory sounds were analysed and displayed as a three dimensional colour spectrogram and a power spectral plot. The spectrogram showed that the sound started abruptly with five or six high energy harmonic components spaced 48 Hz apart. The harmonic components fell by approximately 10 Hz during expiration. Figure 1B shows the corresponding power spectral plot (power in decibels against frequency in kHz). The distinct harmonic peaks (which are marked by arrows) are clearly seen, the first at 48 Hz (0.048 kHz) is the fundamental frequency and the subsequent peaks all spaced 48 Hz apart are harmonics (the fundamental frequency is always equal to the frequency difference between the harmonic peaks).

The patient subsequently had multiple admissions to hospital with increased dyspnoea and sputum production, usually precipitated by infection. Ten years after her first presentation she died in acute respiratory failure precipitated by bronchopneumonia.

Post-mortem examination revealed narrowing of the trachea (circumference 2.8 cm) and both main bronchi (internal diameter of the left main bronchus was 2 mm). The right lower lobe bronchi showed mucus plugging and bronchiectasis. Much of the cartilage had been destroyed and replaced with fibrous tissue; his-

Aintree Chest Centre,
Fazakerley Hospital,
Liverpool L9 7AL, UK

M J Doherty
D P S Spence
D Graham
J E Earis

Department of
Electrical Engineering
and Electronics,
University of
Liverpool, Liverpool,
UK

B M G Cheetham
X Q Sun

Correspondence to:
Dr J E Earis.

Received 15 April 1996
Returned to authors
16 December 1996
Revised version received
5 March 1997
Accepted for publication
1 April 1997

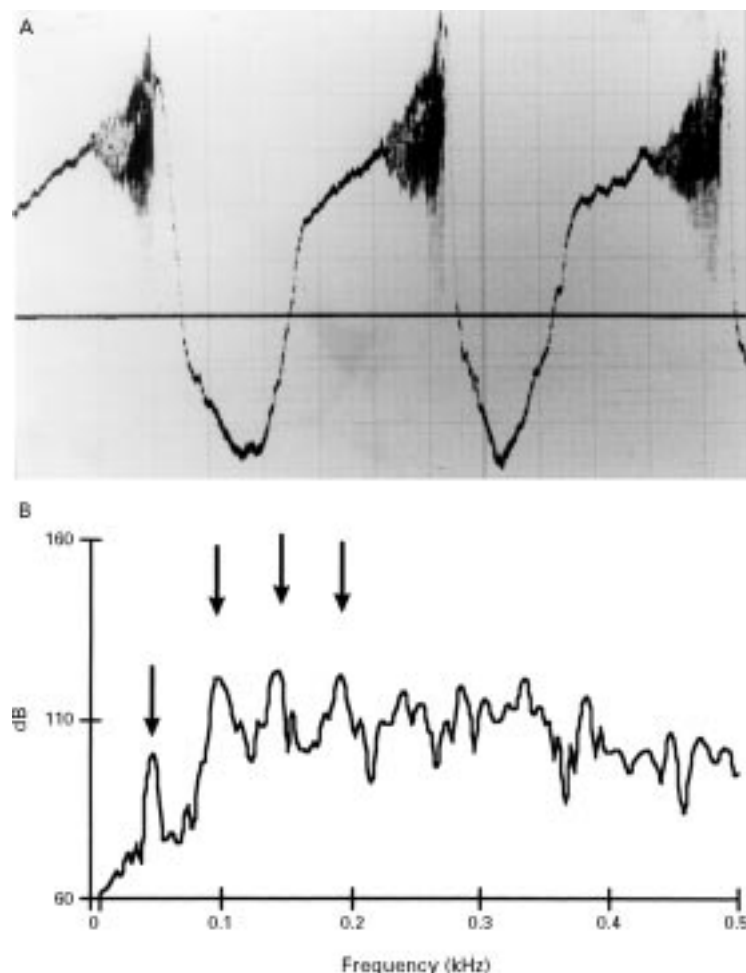


Figure 1 (A) Flow tracing (zero flow marked by the horizontal line; inspiration is in an upward direction and expiration is in a downward direction). Note the onset of oscillations on the expiratory limb which coincided with the low pitched sound. (B) Power spectrum of the expiratory sound, frequency in kHz on the horizontal axis and power in dB on the vertical axis. The arrows point to the peaks of energy (harmonics). The first arrow on the left points to the fundamental frequency of the sound at 48 Hz and the subsequent three arrows to the harmonics. Note that each harmonic is spaced 48 Hz apart.

ological examination of the surviving cartilage showed a low grade lymphocytic and plasma cell infiltration, diagnostic of relapsing polychondritis.

Discussion

This patient's initial clinical presentation with severe airflow obstruction was thought to be due to asthma. However, poor reversibility to bronchodilators and the presence of an unusual low pitched expiratory sound raised doubts about the diagnosis and bronchoscopic examination revealed the presence of severe tracheobronchomalacia of unknown aetiology. At the time there was no evidence of generalised cartilaginous disease, the diagnosis of relapsing polychondritis being made after death. Respiratory tract involvement with polychondritis has been reported to occur in 56% of cases but in only 14% is it the initial presenting symptom.³ In this case even after 10 years the disease remained limited to the chest.

Relatively little is known about the production of wheezing sounds. Gavriely and co-workers,

using mathematical models⁴ and observing flow in flexible tubes,^{5,6} have demonstrated that wheeze is due to a complex interrelationship between the fluid and elastic forces inducing airway wall flutter at a flow-limiting segment. The thicker and wider the tube the lower the pitch of the wheezing sound. In methacholine induced wheezing in asthmatic subjects the association of expiratory wheezing with tidal airflow limitation has recently been confirmed⁷ and, as predicted by Gavriely's model, the pitch of the wheeze fell during expiration as the geometry of the airway changed.

In this case the sound corresponded to oscillations in the flow tracing and suggests that airflow was clearly linked to the sound production. The multiple harmonic components seen in the spectrograph and power spectrum of the sound (fig 1B) were similar to the analysis of flutter in flow limited floppy tubes.⁵ Although airflow limitation does not usually occur in the trachea, in this case the lack of tracheal support was obvious at bronchoscopy and in these unusual circumstances airflow limitation at the level of the trachea is possible. The fundamental frequency of this expiratory sound was 48 Hz so it was not a wheeze (defined as having power peaks above 200 Hz⁸). However, the frequency of any "wheezing sound" is inversely related to the calibre of the airway producing the sound,⁴ suggesting that the sound was produced in a large airway such as the trachea. Furthermore, the dynamic nature of the sound, falling in pitch during expiration as the geometry of the trachea changes, is similar to the finding described during expiration in asthmatic wheezing.⁷

In this patient relapsing polychondritis resulted in a floppy trachea and produced a unique set of circumstances which allowed insights into the mechanism of dynamic flutter and wheeze production. This is the first time that a low pitched fluttering sound has been reported in association with tracheomalacia. It was the sound that suggested an alternative diagnosis and this may prove to be a useful physical sign in the diagnosis of tracheomalacia.

- 1 Kaye RL, Soner DA. Relapsing polychondritis: clinical and pathological features in fourteen cases. *Ann Intern Med* 1964;60:653-64.
- 2 Miller RD, Hyatt RE. Obstructing lesions of the larynx and trachea; clinical and physiological characteristics. *Mayo Clin Proc* 1969;44:145.
- 3 McAdam LP, O'Hanlon MA, Bluestone R, et al. Relapsing polychondritis: prospective study of 23 patients and a review of the literature. *Medicine (Baltimore)* 1976;55:193-215.
- 4 Grotberg JB, Gavriely N. Flutter in collapsible tubes: a theoretical model of wheezes. *J Appl Physiol* 1989;66:2262-73.
- 5 Gavriely N, Snee TR, Cugell DW, et al. Flutter in flow-limited collapsible tubes: a mechanism for generation of wheezes. *J Appl Physiol* 1989;66:2251-61.
- 6 Gavriely N, Grotberg JB. Flow limitation and wheezes in a constant flow and volume lung. *J Appl Physiol* 1986;64:17-20.
- 7 Spence DPS, Graham D, Calverley PMA, et al. The relationship between wheezing and lung mechanics during methacholine induced bronchoconstriction in asthmatic subjects. *Am J Respir Crit Care Med* 1996;154:290-4.
- 8 Fentron TR, Pasterkamp H, Chernick V. Automated spectral characterization of wheezing in asthmatic children. *IEEE Trans Biomed Eng* 1985;32:50-5.

Upper airways sarcoidosis presenting as obstructive sleep apnoea

R N H Shah, P R Mills, P J M George, J A Wedzicha

Abstract

Sarcoidosis may present in a number of different ways, affecting many organ systems. The case history is presented of a 32 year old woman who presented with symptoms of severe obstructive sleep apnoea (OSA) due to infiltration of the upper airway by sarcoidosis. To our knowledge this presentation of sarcoidosis has not previously been described.

(Thorax 1998;53:232-233)

Keywords: obstructive sleep apnoea; sarcoidosis; continuous positive airway pressure ventilation; sleep study

A 32 year old woman of West Indian descent was referred to our hospital with a three month history of worsening hypersomnolence and loud snoring. She was repeatedly falling asleep during the daytime and, as a result, was having difficulty looking after her children. It had also been noted that she snored loudly and had prolonged apnoeic episodes throughout the night. During the week prior to admission the patient had developed a sore throat and hoarse voice.

She had been diagnosed as having cutaneous sarcoidosis four years previously which was treated successfully with a six month course of oral steroids. One year prior to referral to our hospital she was diagnosed as having diabetes insipidus secondary to cranial sarcoid involvement. She had been on intranasal desmopressin since then.

On admission a coherent history was difficult to obtain from the patient as she was unable to stay awake for longer than a few minutes. On examination the patient had marked lupus pernio as well as erythema nodosum on her shins. A hoarse voice and mild stridor were noted. There were no other abnormalities detected on physical examination. Notably her chest was clear on auscultation with good air entry throughout both lung fields. The patient's weight was 132 kg.

Full blood count, urea, and electrolytes were normal. The corrected calcium level was 2.77 mmol/l and the serum angiotensin converting enzyme (ACE) level was 181 u/l (normal range 10-70 u/l). Arterial blood gas analysis on air showed a pH of 7.44, P_{aCO_2} of 6.65 kPa, P_{aO_2} of 8.43 kPa, and oxygen saturation (S_{aO_2}) of 92%. Respiratory function tests showed a peak expiratory flow rate (PEFR) of 254 l/min (65% of predicted). Forced expiratory volume in one second (FEV_1) was 2.35 l (77% of predicted), forced vital capacity (FVC) 3.17 l (91% of predicted) with an FEV_1/FVC ratio of 74%. The chest radiograph was normal, the lung fields were clear, and there was no hilar lymphadenopathy. Radiography of the neck soft tissue showed no tracheal obstruction.

Multichannel monitoring of chest wall motion, airflow, S_{aO_2} , and heart rate (EdenTrace, Nellcor Puritan Bennet, Minnesota, USA) was recorded directly on admission, which was during the daytime, with 2 l/min supplemental oxygen (fig 1).

Nasendoscopic examination showed severe swelling of the nasal mucosa with mucoid discharge. There was disrupted architecture of the left glottis, with a narrowed and irregular subglottis to approximately 50% of the normal diameter. Tissue biopsy specimens confirmed the presence of non-caseating granulomas.

The patient was started on high dose oral corticosteroids and nasal continuous positive pressure ventilation (CPAP) at a pressure of 7.5 cm H_2O . Within 24 hours the patient was noticeably more alert and was discharged home with a nasal CPAP machine for nocturnal use six days after admission. Optimum CPAP pressure was titrated by a repeat sleep study while on treatment.

One month after discharge she was not experiencing any apnoeas or complaining of hypersomnolence. She admitted to not using the CPAP and had not altered in weight. Arterial blood gas tensions on air showed a pH of 7.41, P_{aCO_2} of 5.39 kPa, P_{aO_2} of 10.20 kPa, and an S_{aO_2} of 95%. Respiratory function tests showed an FEV_1 of 3.1 l (102% of predicted), FVC of 3.7 l (106% of predicted), with an FEV_1/FVC ratio of 84%. The serum ACE concentration was 52 u/l. Six months after initial presentation a sleep study on air without nasal CPAP produced normal results.

Discussion

Laryngeal involvement in sarcoidosis is rare (0.5-1.4% of cases).¹ It classically causes supraglottic swelling and erythema which is thought to be pathognomonic. It usually

Department of Respiratory Medicine, The London Chest Hospital, Bonner Road, London E2 9JX, UK

R N H Shah
P R Mills
P J M George
J A Wedzicha

Correspondence to:
Dr J A Wedzicha.

Received 16 December 1996
Returned to authors
19 February 1997
Revised version received
25 April 1997
Accepted for publication
12 May 1997

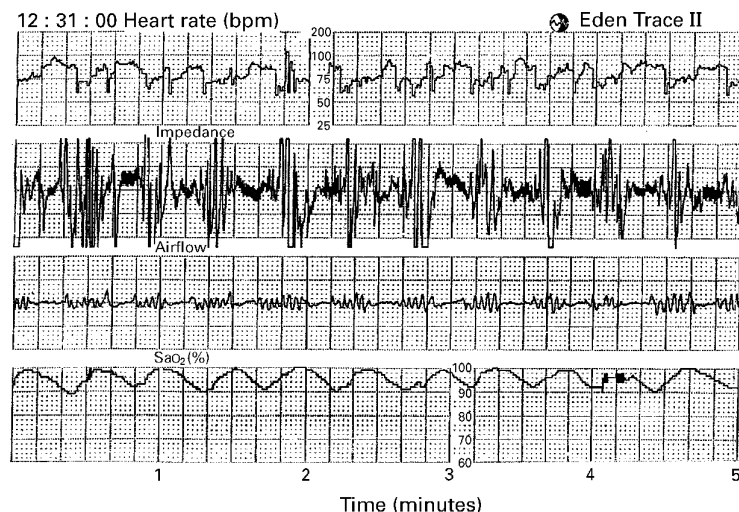


Figure 1 Recording from EdenTrace showing variations in heart rate, airflow, impedance and pulse oximetry with time.

presents with stridor but has also been reported to present with dysphagia² as well as being in the differential diagnosis of childhood epiglottic enlargement.³ Laryngeal sarcoidosis may be treated with systemic corticosteroids, intralesional steroid injections, microendoscopic surgery, as well as tracheostomy if needed.⁴

Sleep apnoea has been associated with a wide range of metabolic and structural disorders; however, to our knowledge, there is no previous report of sleep apnoea being caused by infiltration of the upper airway with sarcoidosis. This patient had laryngeal sleep apnoea due to sarcoidosis infiltration as opposed to the more common pharyngeal sleep apnoea seen in clinical practice. Upper airway obstruction is notoriously difficult to diagnose clinically, particularly when the chest radiograph is normal. The diagnosis was aided in this patient by the combination of a low PEFr, hoarse voice, and the presence of stridor.⁵

Our case report describes a patient with the rapid onset of symptoms of life threatening obstructive sleep apnoea. Her initial sleep study, which was performed during the day-

time due to the severity of her initial presenting symptoms, showed marked sleep apnoea. Nasendoscopic examination and biopsy specimens confirmed the presence of laryngeal sarcoidosis infiltration. CPAP provided effective and rapid resolution of her symptoms before definitive treatment with systemic corticosteroids had an effect. Infiltration of the upper airway with sarcoidosis should be considered as a reversible cause of obstructive sleep apnoea in the appropriate clinical setting.

We would like to acknowledge the assistance of Mrs Rubina Ishtiaq in the preparation of this manuscript.

- 1 Mayock RL, Bertrand P, Morrison CE, *et al*. Manifestations of sarcoidosis: analysis of 145 patients with a review of nine series selected from the literature. *Am J Med* 1963;35:67-81.
- 2 Deron P. Dysphagia with systemic diseases. *Acta Oto-Rhino-Laryngol Belg* 1994;48:191-200.
- 3 McHugh K, deSilva M, Kilham HA. Epiglottic enlargement secondary to laryngeal sarcoidosis. *Paediatr Radiol* 1993;23:71.
- 4 Gallivan GJ, Landis JN. Sarcoidosis of the larynx: preserving and restoring airway and professional voice. *J Voice* 1993;7:81-94.
- 5 Empey DW. Assessment of upper airways obstruction. *BMJ* 1972;3:503-5.

LETTERS TO THE EDITOR

Why are there so few papers on elderly patients in *Thorax*?

We all know that chest diseases are very common in the elderly. In a recent issue of the *BMJ* Bugeja *et al*¹ noted that there were no original research papers published in *Thorax* between 1 June 1996 and 1 June 1997 that were specific to elderly people (≥ 75 years), and that during this time elderly people were excluded unjustifiably in 39 relevant papers in *Thorax*.

Research in elderly people is difficult, more time consuming, and may be more expensive. The biology of old age differs from middle or young age, and to get valid and, hopefully, reproducible results related to the elderly we must make every effort to include them in clinical trials. With changing demography worldwide this is becoming more relevant.

I hope the paucity of good papers related to the elderly was the only reason for this disappointing number in *Thorax* compared with other leading journals such as the *BMJ*, *Lancet*, and *Gut*. Maybe the editors are able to throw more light on this and, in the process,

perhaps make us all (who have a particular interest in chest diseases) aware of the special need for research into the aging lungs.

M MAMUN
University Clinical Department,
The Duncan Building,
Liverpool L69 3GA, UK

- 1 Bugeja G, Kumar A, Banerjee AK. Exclusion of elderly people from clinical research: a descriptive study of published reports. *BMJ* 1997;315:1059.

EDITORS' REPLY Thank you for drawing the *BMJ* publication to our attention. It does not surprise us that *Thorax* publishes fewer papers specific to elderly people than more general journals such as the *BMJ* and the *Lancet*. We note that, although *Thorax* did not have any papers specific to elderly people in the time in question, almost half of the studies published in *Thorax* had no age limit set and would therefore have included elderly patients. Although you single out *Thorax* from the *BMJ* paper, the figures for *Gut* look remarkably similar. The fault in the matter, if indeed there is any, lies with the contributors rather than the Editors as contributors often specifically exclude elderly people from their studies. There are a number of possible reasons for this, many of which may be justified. Dr Mamun can therefore rest assured that there is no ageist editorial policy with the journal. Indeed, one of us has previously published a paper exclusively in the elderly!¹ *Thorax* accepts high quality papers in all areas of respiratory medicine with the main criteria of acceptance being their ability to stand up to a rigorous peer review

system, thereafter ensuring scientific quality. If a paper is good enough it will be published irrespective of the age of the patients included. Our message to Dr Mamun, as indeed to anyone dealing with elderly patients with chest disease, is this: If you feel that your paper is good enough, send it to us. We promise a very rapid review² and a rigorous review process³ which we feel is fair.

A J KNOX
J BRITTON
Thorax Editorial Office

- 1 Knox AJ, Mascie-Taylor BH, Page RL. Fibreoptic bronchoscopy in the elderly: four years' experience. *Br J Dis Chest* 1988;82:290-3.
- 2 Knox AJ, Britton J. Annual Report October 1996 to September 1997. *Thorax* 1997;52:1023.
- 3 Britton J, Knox AJ. *Thorax*: from the new Editorial Office. *Thorax* 1996;51:561.

Passive smoking in children with asthma

I have just read, with mounting incredulity, the paper by Irvine *et al* on what determines levels of passive smoking in children with asthma.¹ These authors have surveyed 501 families with an asthmatic child, recording the smoking habits of the adults in the home and relating these data to exposure of the child to smoke as measured by salivary cotinine levels. They found that exposure is related to total amount smoked by parents,

amount smoked in the home by parents, frequency of parental smoking in the same room as the child, smoking by both parents, and contact with smokers other than parents. They conclude that "... it is proximity to smoking adults which determines passive exposure of the children".

What other conclusion could possibly have been envisaged? What hypothesis was being tested? I would say that these "results" are totally predictable to anyone with a smattering of common sense and that this "investigation" has no scientific merit. It is merely a waste of precious research funding when many more useful projects are being turned down for lack of funds.

I note, with even further astonishment, that the same group is now conducting a trial to see whether it is possible to reduce passive smoking by the children by encouraging parents to protect them from smoke, again funded by the Wellcome Trust! I hope the results will not be published in *Thorax* as I feel the reputation of this journal can only be damaged by association with pseudo science of this sort.

T ASHCROFT
Department of Histopathology,
Freeman Hospital,
High Heaton,
Newcastle upon Tyne NE7 7DN, UK

1 Irvine L, Crombie IK, Clark RA, *et al.* What determines levels of passive smoking in children with asthma? *Thorax* 1997;52:766-9.

AUTHORS' REPLY It was with some disappointment that we read the letter from Dr Ashcroft. He claims that the research was pointless because the findings were obvious. Even if this were true, the research would still be needed. How often in the history of medicine have we seen obvious or common sense ideas totally refuted by subsequent research? It is the purpose of research to test our preconceptions.

However, in our case the findings were not obvious. We were surprised and concerned at the number of asthmatic children exposed to high levels of passive smoke. We had expected social factors to be strongly related to the children's cotinine levels but they were not. We were also surprised at the strength of the effect of age, particularly as we had constructed an argument for the age effect being in the opposite direction to that found. Finally, we were surprised at the strength and consistency with which the proximity factors predicted cotinine levels to the exclusion of all other variables except age.

Dr Ashcroft may be interested to know that his opinions are not shared by the three expert referees who reviewed the paper nor the many colleagues with whom we have discussed our findings. Indeed, the results attracted much interest when presented at the American Thoracic Society and Scottish

Thoracic Society earlier this year. Currently we are receiving requests for reprints from scientists throughout the world. We can only wonder what prompted Dr Ashcroft to make his intemperate and unwarranted comments.

IAIN CROMBIE
LINDA IRVINE
Department of Epidemiology and Public Health,
Ninewells Hospital and Medical School,
Dundee DD1 9SY, UK

BOOK REVIEW

Self-Assessment Colour Review of Respiratory Medicine Spiro SG, Albert RK, Fielding D. (Pp 192; £14.95). Manson Publishing Ltd, 1997. 1 874545 77 4.

The preface to this book states that its aims are to present key points on topics across the spectrum of respiratory diseases. These include both primary pulmonary disorders and pulmonary manifestations of systemic disease.

The format of the book, with questions on one side of the page and answers immediately following on the reverse, is ideal. The range of topics covered is wide and their random order makes for interesting and stimulating reading. The quality of answers is very good and, while all aspects of a topic cannot always be discussed in detail in the space provided, this can be followed up where necessary with further reading. An important feature of this book is that the photographs are of excellent quality and most of the chest radiographs, which are notoriously difficult to reproduce, demonstrate the abnormality well enough. In summary, this book will be a useful learning aid for both undergraduate and postgraduate students alike.

NOTICES

The Lung in Adverse Environments

A symposium on "The Lung in Adverse Environments" organised jointly by the British Association for Lung Research (BALR) and the Defence Evaluation Research Agency (DERA) will be held at Porton Down on 6 April 1998. For further details please contact Dr Gary J Phillips, CBD Porton Down, Salisbury, Wiltshire SP4 0JQ, UK. Telephone: +44 (0)1980 613818. Fax: +44 (0)1980 613741. e mail: cbmdc@dera.gov.uk (fao: G Phillips)

Julia Polak Lung Transplant Fund

A celebration organised by the Julia Polak Lung Transplant Fund on "Lung Transplant: Impact on Lung Disease" will be held on 22-23 June 1998 at the Wolfson Conference Centre, Imperial College School of Medicine, London. For further details please contact: Professor J M Polak, Department of Histochemistry, Imperial College School of Medicine, Hammersmith Campus, Du Cane Road, London W12 0NN. Telephone: 0181 383 3231. Fax: 0181 743 5362. E mail: jpolak@rmps.ac.uk.

Infections in Respiratory Medicine

A one day symposium on "Infections in Respiratory Medicine" will be held at York Race Course on 2 June 1998. For further information and a full programme please contact Ruth Leckie, Conference Administrator, Scunthorpe General Hospital, Cliff Gardens, Scunthorpe, N Lincs DN15 7BH, UK. Telephone: 01724 290144. Fax: 01724 865680.

1998 PHLS/BTS/ DH National Survey of Tuberculosis in England and Wales

The Public Health Laboratory Service (PHLS) Communicable Disease Surveillance Centre (CDSC) is coordinating the 1998 National Survey of Tuberculosis in England and Wales, in collaboration with the British Thoracic Society and the Department of Health. Unlike previous surveys, patients of all ages diagnosed with tuberculosis between 1 January and 31 December 1998 (inclusive) and notified to the local Consultants in Communicable Disease Control (CCDCs) will be included. In addition, efforts will be made to ascertain other cases of tuberculosis which are diagnosed in the survey period but not notified. Information about the survey has been sent to all chest physicians, medical microbiologists, regional epidemiologist, CCDCs, and general physicians with an interest in respiratory medicine. However, the Steering Committee would like the survey brought to the attention of all doctors who might diagnose a case of tuberculosis. Further information about the survey can be obtained from the Survey Coordinator, Ms Angela M C Rose, 1998 National Tuberculosis Survey, 61 Colindale Avenue, London NW9 5EQ.