

Endobronchial leiomyoma: a case report

Uğur Özçelik, Esin Kotiloğlu, Ayhan Göçmen, M Emin Şenocak, Nural Kiper

Abstract

Leiomyoma of the lung is very rare in children. The case history is presented of an 8 year old boy with an endobronchial leiomyoma which caused total atelectasis of the left lung.

(Thorax 1995;50:101-102)

Benign tumours of the lung are relatively uncommon and leiomyomas are even more rarely encountered. In a series of 130 benign lung tumours reported from the Mayo Clinic the incidence of pulmonary leiomyomas was 1.5%.¹ Review of the literature reveals that most cases occur in females and, in a collection of 15 cases, there were only four cases in patients younger than 15 years of age.²⁻⁵

We describe an 8 year old boy who was admitted to hospital for persistent cough and fever, and whose radiograph showed total atelectasis of the left lung. This is a rare entity as a cause of atelectasis in childhood.

Case report

An 8 year old boy was admitted to Hacettepe University Children's Hospital with two month history of coughing and fever resistant to medical treatment. He had little sputum and only once had an haemoptysis. There was no history of foreign body aspiration or contact with tuberculosis.

Body temperature was 37.5°C with a pulse rate of 132 beats/min and respiratory rate of 30 breaths/min. The physical examination suggested collapse of the left lung and this was confirmed by radiography. Bronchoscopy revealed a polypoid mass protruding into the lumen of the left main bronchus which was completely removed by a biopsy forceps with a large cup through the endoscope. A chest radiograph taken after bronchoscopy showed that the left lung had re-expanded (fig 1).

Histological examination of the mass demonstrated a non-capsulated but well demarcated nodule beneath the respiratory epithelium composed of interdigitating bundles of spindle cells (fig 2). The cells were uniform in size and shape, the nuclei were elongated with blunt ends, and no mitoses were seen. Mallory's trichrome stain, and an avidin-biotin technique

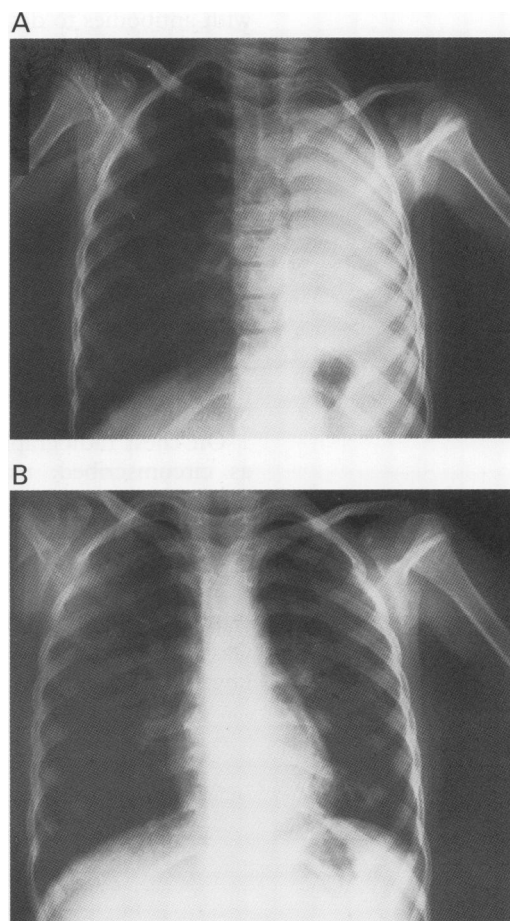


Figure 1 Chest radiographs taken (A) before bronchoscopy showing total atelectasis of the left lung and (B) after excision of the tumour.

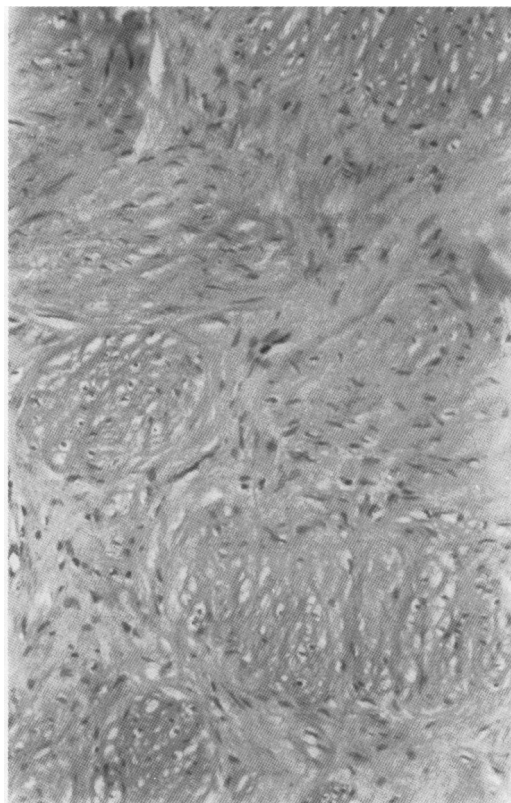


Figure 2 Histological section of the tumour showing interdigitating bundles of smooth muscle cells. Stain: haematoxylin and eosin, original magnification $\times 132$ reduced to 92% in origination.

Department of
Pediatric Chest
Disease
U Özçelik
A Göçmen
N Kiper

Department of
Pediatric Pathology
E Kotiloğlu

Department of
Pediatric Surgery
ME Şenocak

Hacettepe University,
Faculty of Medicine,
Ankara, Turkey

Reprint requests to:
Dr U Özçelik, Hacettepe
Children's Hospital, 06100
Hacettepe, Ankara, Turkey.

Received 4th January 1994
Returned to authors
4 February 1994
Revised version received
1 March 1994
Accepted for publication
2 March 1994

with antibodies to desmin and smooth muscle actin confirmed that the mass was of smooth muscle origin and it was diagnosed as an endobronchial leiomyoma.

Discussion

Leiomyomas are very rare tumours of the lung. They are mostly parenchymal lesions which rarely cause symptoms.³ Endobronchial leiomyomas are even less frequently encountered but may cause dyspnoea, cough, and pneumonia because of partial or total obliteration of an airway.¹³⁴⁷

On chest radiography leiomyomas are seen as circumscribed, usually round masses of homogeneous density.⁵ Multiple leiomyomas have been reported but are either hamartomas or metastases from uterine leiomyomas.⁸⁻¹⁰

We therefore conclude that not all collapsed lungs in children are secondary to foreign bod-

ies or infection and tumours, although rare, are occasionally seen.

- 1 Arrigoni MG, Woolner LB, Bernatz PE, Miller WE, Fontana RS. Benign tumours of the lung: a ten year surgical experience. *J Thorac Cardiovasc Surg* 1970;**60**:589-99.
- 2 Williams RS, Daniel RA. Leiomyoma of the lung. *J Thorac Surg* 1950;**19**:806-10.
- 3 Agnos JW, Starkey G.W.B. Primary leiomyosarcoma and leiomyoma of the lung. Review of the literature and report of two cases of leiomyosarcoma. *N Engl J Med* 1958;**258**:12-7.
- 4 Guida PM, Fulcher T, Moore SW. Leiomyoma of the lung. Report of a case. *J Thorac Cardiovasc Surg* 1965;**49**:1058-64.
- 5 Sherman RS, Malone BH. A roentgen study of muscle tumours primary in the lung. *Radiology* 1950;**54**:507-15.
- 6 Brooks JW. Tumours of the chest. In: Chernich V, Kendy EL, eds. *Disorders of the respiratory tracts in children*. Philadelphia: WB Saunders, 1990:614-48.
- 7 Hirose FM, Hennigar GR. Intrabronchial leiomyoma. *J Thorac Surg* 1955;**29**:502-11.
- 8 Kaplan C, Katoh A, Shamoto M, Rogow E, Scott JH, Cushing W, et al. Multiple leiomyomas of the lung: benign or malignant. *Am Rev Respir Dis* 1973;**108**:656-9.
- 9 Del Pozo E, Mattei IR. Multiple pulmonary leiomyomatous hamartomas. A case report. *Am Rev Respir Dis* 1969;**100**:388-90.
- 10 Hull MT, Gonzalez-Crussi F, Grosfeld JL. Multiple pulmonary fibroleiomyomatous hamartomata in childhood. *J Pediatr Surg* 1979;**14**:428-31.