

POST-TUBERCULOUS BRONCHO-STENOSIS AND BRONCHIECTASIS OF THE MIDDLE LOBE *

BY

R. C. BROCK

Guy's Hospital, London

About a year ago I was asked to see in consultation a doctor, 45 years of age, who had had alarming chest symptoms. The story was that nine months earlier he had coughed up a mouthful of blood ; a radiograph of the chest was advised but not done. A month before I saw him he had had a rigor followed by four days of pyrexia and then had coughed up another mouthful of dark blood with some purulent material ; he continued to cough blood-stained sputum for three days. A radiograph of the chest showed an opacity spreading out from the lower part of the right hilum (Fig. 1*a*). A presumptive diagnosis of bronchial carcinoma was made and it was arranged that he should enter hospital for bronchoscopy and probable thoracotomy. This naturally caused considerable alarm amongst his relatives, and his brother-in-law (also a doctor), who had been hastily summoned from a distance, requested me to see the patient urgently to give an independent assessment. In addition to the above history I was informed that some 15 years ago he began to have feverish attacks lasting for two to three days accompanied by slight cough but no pain ; these had occurred most winters since the first onset. Fortunately it was possible to relieve the anxieties of these two rather distraught doctors by telling them straight away that I did not think a bronchial carcinoma was present. Subsequent investigations showed that this observation was correct.

I have begun by mentioning this case not because it is especially unusual, it is in fact typical of many that I have seen, but it so happens that the circumstances of the urgent, rather anxious consultation impressed themselves upon me. The condition from which he was suffering, post-tuberculous broncho-stenosis of the middle lobe with recurrent attacks of acute infection, is one which is relatively common, is of great diagnostic importance, and yet is known and understood by far too few physicians and surgeons working on diseases of the chest. I am repeatedly seeing such cases in middle-aged and elderly patients who have been misdiagnosed or incompletely diagnosed in various ways. It is for this reason that a full account of the condition is needed ; it is most desirable that it should be widely known and frequently thought of in differential diagnosis.

DIAGNOSIS

A proper approach to the radiographic study of this case should have led the earlier advisers to suggest the correct diagnosis. Failure to do so arose probably in great part from ignorance of the condition itself but also from failure to consider

* A paper delivered before the South-Eastern Regional Tuberculosis Society in September, 1949.

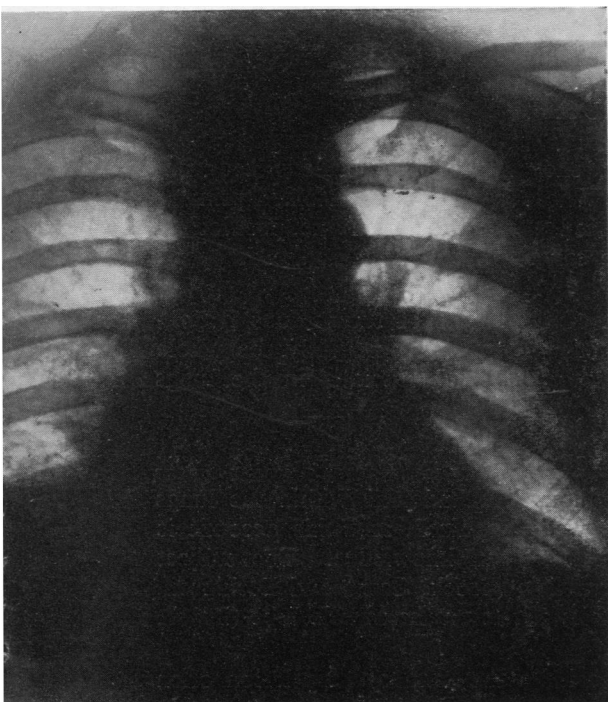
the first fundamental of good diagnosis, namely *localization of the exact anatomical site of the lesion*. I have always taught that this is the first step in all diagnosis in any part of the body and it is essential to consider it most carefully in the diagnosis of lung disease. We are still far too prone to study chest radiographs loosely and to omit to apply the important knowledge of broncho-pulmonary segmental anatomy.

The shadow at the right hilum, which resembled and was assumed to be a bronchial carcinoma, was easily recognized as due to an opacity situated in the middle lobe and caused by consolidation of that part of the lung; a lateral radiograph at once indicated this.

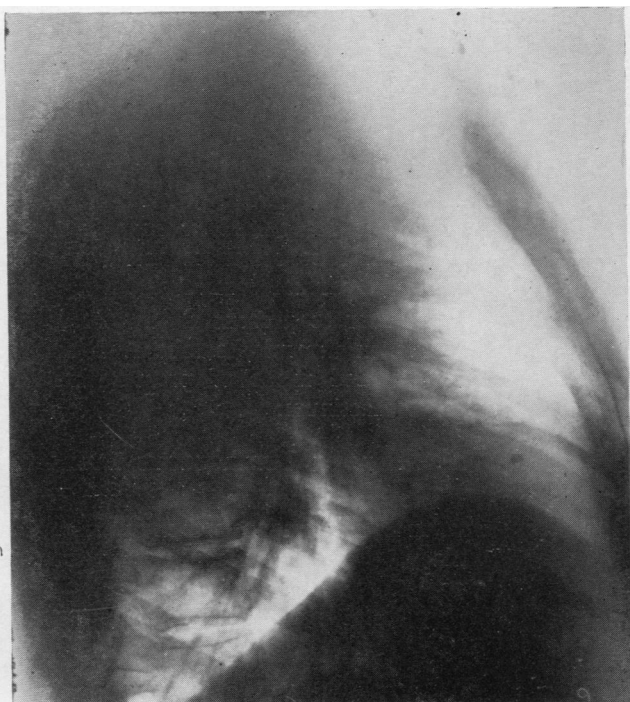The second step in diagnosis follows logically from the first step of anatomical localization, namely, *having regard to the age of the patient and the history, what is the most likely thing to occur in that situation*. The age and history certainly tend to support a diagnosis of carcinoma, but what about the frequency of carcinoma in the middle lobe? In a series of some 1,200 cases of bronchial carcinoma I have seen only eight cases of carcinoma occurring in the middle lobe, and in all of these the growth presented itself primarily as a rounded mass of the peripheral or parenchymatous type, even though in some it also caused obstruction and therefore total consolidation of the middle lobe. In no case did the carcinoma arise in the stem bronchus of the middle lobe and cause obstruction and secondary consolidation. I have seen this occur in two cases from a benign tumour of the middle lobe bronchus; one was an adenoma and the other a so-called "lipoma"; in a third case the middle lobe contained a large rounded benign tumour, a haemangio-endothelioma. These cases are, of course, quite distinct from cases of carcinoma causing obstruction of both the middle and lower lobes, a very common occurrence.

In contradistinction to these eight cases of carcinoma arising solely in the middle lobe, I have seen 60 cases of obstruction and infection of the middle lobe due to active or old tuberculous lymphadenitis, and these 60 cases form the basis of this article.

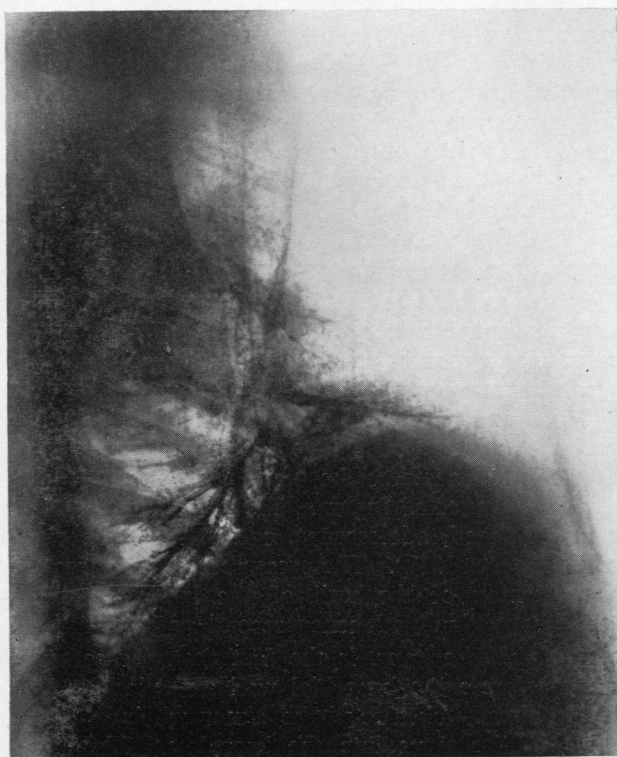It will thus be seen that the "most likely thing to occur" in the middle lobe is not a carcinoma but a lesion due to post-tuberculous broncho-stenosis or bronchiectasis. This being so one looks for corroborative evidence which is best supplied by observing the presence of a calcified primary complex affecting the middle lobe region. Such a calcified complex could be clearly seen in the case under discussion (Fig. 1*a* and *b*); once this had been identified it was easy to suggest with confidence that the diagnosis was not likely to be carcinoma. The additional history of rigors and pyrexial attacks dating back over a period of 15 years, and occurring each winter, lent strong support to this diagnosis. Bronchoscopy showed no abnormality in the stem of the middle lobe bronchus; a bronchogram (Fig. 1*c*) showed a block of the lateral division of the middle lobe bronchus with corresponding contracture of the lateral segment. Thus the anatomical localization was rendered still more precise; from experience with the incidence of bronchial carcinoma it would be extremely rare for a segmental type of bronchial carcinoma to occur in this site; on the other hand obstruction of the lateral division of the middle lobe bronchus with consolidation or atelectasis of the



(a)



(b)



(c)

FIG. 1.—Radiograph of a typical middle lobe opacity, wrongly diagnosed as due to carcinoma. An obvious calcified primary complex is seen in 1a and 1b ; 1c shows a complete block of the lateral branch of the middle lobe.

lateral segment is one of the commonest sites for post-tuberculous broncho-stenosis, as will be shown more fully later. When, in addition, a calcified primary complex is recognized nearby with a calcified gland exactly in the position of the middle lobe bronchus itself, coincidence can be discounted and the diagnosis becomes a virtual certainty.

In order to present a complete account of the effects of tuberculous lymphadenitis on the middle lobe it is first necessary to survey more fully the whole problem and mode of presentation of tuberculous lymphadenitis in the lungs and mediastinum.

PATHOLOGY OF TUBERCULOUS LYMPHADENITIS IN THE LUNGS AND MEDIASTINUM

The occurrence and behaviour of tuberculous lymphadenitis within the lungs and mediastinum are generally known and well-recognized, and this account is little more than a recapitulation of what is common knowledge. The subject was dealt with somewhat fully in an earlier article (Brock, Cann, and Dickinson, 1937); brief mention has also been made of its effects on the middle lobe (Brock, 1943 and 1946).

When the primary complex occurs in the lungs the primary lung lesion often remains small and insignificant; the secondary lymph-glands are more severely affected and become large and caseous. In the more severe cases, more particularly in infants and young children, the mediastinal and hilar glands may be widely and severely affected, forming large clumps of glands which cause considerable obstruction. From their position, which is usually in the angle formed by the dividing bronchi of the larger orders, their enlargement inevitably causes pressure on and partial or complete obstruction of the adjacent bronchi. The smaller the bronchus the more severe is the obstruction likely to be, but not even the main bronchi can escape when the lymphadenitis is severe and a large hard mass of inflamed or caseous glands is formed. The younger the patient the smaller and softer are the bronchi, and the glandular reaction is also likely to be more severe; hence the worst forms are seen in the very young.

Once enlarged in this way the glands may cause obstruction for many months; this can easily be appreciated if one thinks of the large hard masses of glands that may persist for many months in the neck where they can be more easily studied. Prolonged pressure on the bronchi in this way may be followed by shrinkage of the glands and by complete resolution of the results of obstruction. On the other hand the obstruction is likely to be followed by infection of the obstructed bronchi and this increases the probability of permanent bronchiectatic changes developing in the affected region. There is little doubt that many cases of bronchiectasis in childhood, adolescence, or adult life are caused in this way (Brock, Cann, and Dickinson, 1937). The pressure of the enlarged, inflamed glands may also cause weakening of the wall of the bronchus which also favours prolongation of the obstruction and hence secondary bronchiectasis.

More serious than this, however, is the fact that a caseous gland or glands may adhere to and perforate the bronchial wall and ulcerate into the lumen of the bronchus. If not already obstructed the lumen will now be filled by caseous lymphatic tissue which discharges into the bronchus. The obstruction is then

not only complete but is likely to be long-continued while the caseous gland is being either extruded and coughed up or undergoes healing. In some cases the process of ulceration and discharge into the bronchus may be very late when partial calcification has occurred in the caseous gland, and calcified masses or "bronchololiths" are now added to the picture. Even when the caseous material has been coughed up and the obstruction is relieved a further obstructive process may occur, namely fibrous contracture of the bronchus which has been perforated and ulcerated by the caseous process. In this way a tight fibrous stricture may remain or the bronchus may even be completely obliterated at the site of ulceration and healing. Permanent bronchiectatic changes are then inevitable.

We may thus have a temporary bronchial obstruction with no significant residual broncho-stenosis or bronchiectasis; we may have no broncho-stenosis but a residual bronchiectasis; or we may have severe broncho-stenosis with permanent bronchiectasis. In any or all of these the original caseous gland may remain as a partly or totally calcified structure which can be recognized radiologically and demonstrated on the specimen itself (see numerous later figures).

The Anatomical Site of the Glands.—The disposition of the mediastinal and hilar glands is well known. The main groups lie disposed around the lower end of the trachea and its bifurcation; the right, left, and inferior tracheo-bronchial groups are thus formed. In addition, other glands lie in the angles formed by the origin of the lobar and segmental bronchi; they are chiefly in direct relation to the bronchi, but some are placed in the divisions of the associated lobar and segmental arteries which closely follow the course of the bronchi. In this way any bronchus, main, lobar, or segmental, may be affected; the smaller the bronchus the weaker and more vulnerable is its wall. The middle lobe bronchus is peculiarly vulnerable in this way. It is a long, narrow structure and, as has been pointed out already (Brock, 1943), it is surrounded by glands which lie in the inferior angle formed by its origin from the stem bronchus and which also flank it on each side (Figs. 2 and 3). In this way the stem bronchus of the middle lobe may be affected, or either its lateral or medial division, the lateral much more commonly than the medial.

Moreover, the glands disposed around the middle lobe bronchus receive infection not only from the middle lobe itself but also from the lower lobe, quite apart from the additional hazard of retrograde infection from the glands of the right upper lobe or even from the left lung. This high vulnerability of the middle lobe bronchus is shown by the common incidence of broncho-stenosis and bronchiectasis in later years. Thus in my own series of 93 cases of post-tuberculous broncho-stenosis or bronchiectasis the relative incidence was as in Table I.

TABLE I
RELATIVE ANATOMICAL INCIDENCE OF POST-TUBERCULOUS BRONCHO-STENOSIS OR BRONCHIECTASIS

Site	No.	Site	No.
Right main bronchus	4	Left main bronchus	3
Right upper lobe	10	Left upper lobe	3
Right lower lobe	10	Left lower lobe	3
Middle lobe	60		

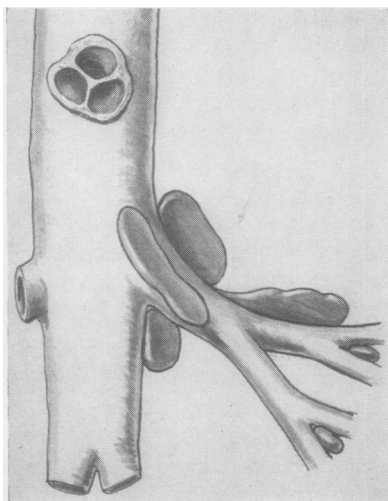


FIG. 2.

FIG. 2.—Drawing (semi-diagrammatic) of dissection of lymph glands in relation to the middle lobe bronchus.

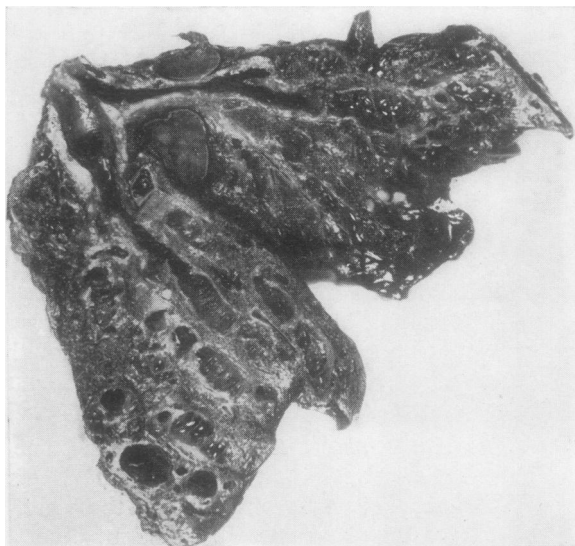


FIG. 3a.

FIG. 3.—Photographs of specimens of bronchiectatic lobes removed at operation, showing the close relationship of lymphatic glands to the middle lobe bronchus and its branches.

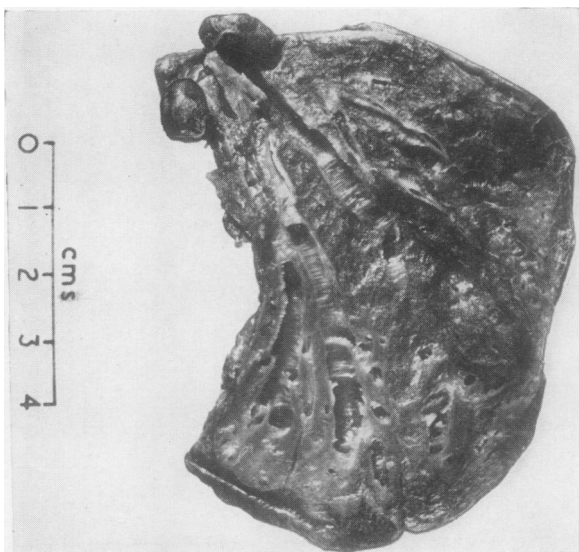


FIG. 3b.

The only large series of cases of bronchial obstruction in primary pulmonary tuberculosis that I have been able to discover in the literature is reported by Richards (1944), who also states that he has himself found no large series comparable with the one he records. This consists of 445 cases of primary tuberculosis in children occurring at High Wood Hospital. Richards states that of 239 patients under 6 years of age 50, or 21%, developed a sector or lobar collapse due to bronchial obstruction. Above this age there were 114 cases with 7% showing bronchial obstruction; there were 92 cases over 10 years of age, with obstruction in 6.5%. Richards found that the lobe most frequently affected was the middle lobe which was obstructed in 23 out of 66 affected lobes; next came the right lower lobe or right basal bronchi with 13; then the right upper lobe and the left upper lobe with 9 each; finally the lingula and left basals with 6 each. In four children more than one lobe was obstructed.

With regard to the immediate prognosis 32 (that is 50% of 64 cases) re-expanded without incident. The shortest time from collapse to re-expansion was one month; the longest time was two years. Ten of the 64 cases (15.6%) developed bronchiectasis; the right middle lobe accounted for six of these ten cases. Collapse was still present on discharge from hospital in 22 (34.4%).

It will thus be seen that these figures amply confirm the general statements made above.

Zdansky (1946) has also drawn attention to the vulnerability of the middle lobe bronchus to compression and obstruction by enlarged lymphatic glands in virtue of its anatomical position and its narrow lumen and thin wall; he describes it as a *punctum minoris resistentiae* in the lung. He describes two cases of post-tuberculous broncho-stenosis of the middle lobe and one of the pectoral right upper with recurrent attacks of infection; in one case a broncholith the size of a cherry stone was coughed up with relief of most of the symptoms; in a second case, that of a man aged 72, it was left undecided clinically and radiologically whether the diagnosis was bronchial carcinoma or an old broncho-stenosis; death followed from a massive haemorrhage, and it was found that a gland had penetrated both into the middle lobe bronchus and into a branch of the pulmonary artery.

Although in the analysis of my own figures in Table I the localization is given in lobes,

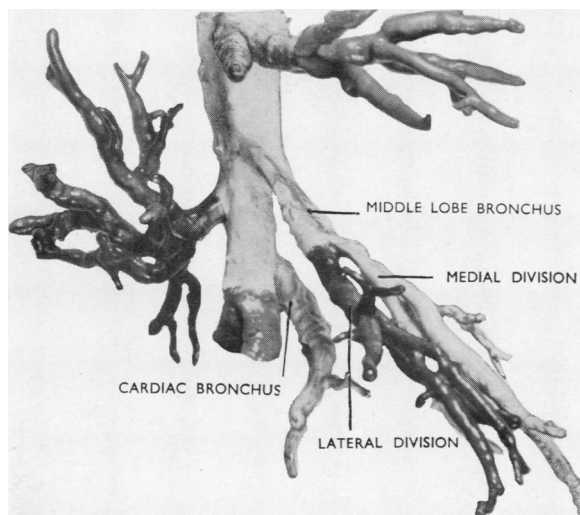


FIG. 4.—Photograph of a metal cast to show the origin and disposition of the middle lobe bronchus, the apical lower, the cardiac, and the pectoral bronchus.

in a number of these the obstruction was segmental within the lobe and did not affect the whole lobe. Thus of the ten cases cited as right upper lobe in five the anterior (pectoral) segment was alone involved; in one the apical and posterior segments were involved. In the three cases ascribed to the left upper lobe, in one the lingula alone was affected and in another the anterior (pectoral) segment. In the three left lower lobe cases the apical lower segment alone was affected in one. The ten right lower lobe cases include six in which the middle lobe was obstructed as well; in one the anterior basal was the site of obstruction and in another the apical lower segment was picked out.

Moreover, of the 60 cases in which the middle lobe was obstructed, in two the anterior (pectoral) segment of the right upper lobe was affected as well, and in two more the cardiac segment was also involved; in one both the cardiac and the anterior segment of the right upper lobe were involved, and in yet another the lateral basal was obstructed. This rather patchy incidence of the condition should be noted; it is readily understood when one thinks of these long, slender,

tertiary bronchi with enlarged glands in close relation to them. We well know from study of cervical adenitis how scattered groups of enlarged glands may occur.

Particularly important is the association of middle lobe disease with the cardiac segment and the anterior (pectoral) right upper. As can be seen from Fig. 4 these three bronchi are almost in series; the associated glands are almost touching. Fig. 5 shows an example of bronchiectasis of the middle lobe and cardiac segment in a girl of 18 in whom the development of the process was watched over several years and which was eventually treated by operation; a typical calcified primary complex was present. Similarly, bronchiectasis of the middle lobe and of the anterior right upper segment may co-exist, or all of these segments may show bronchiectasis and triple resection is needed. Less common is association

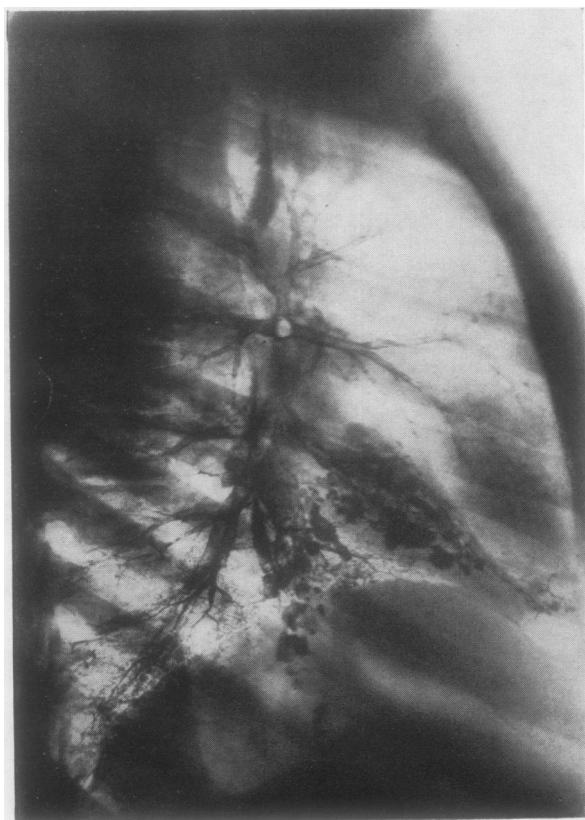


FIG. 5.—Bronchogram to show saccular bronchiectasis of the middle lobe and the cardiac segment, secondary to old tuberculous lymphadenitis.

of the middle lobe with the apical lower, but Fig. 4 shows the close anatomical association of the bronchi.

Non-tuberculous Lymphadenitis with Obstruction.—Although this paper deals primarily with post-tuberculous bronchiectasis there is little doubt that the middle lobe bronchus is also vulnerable to continued pressure from glands enlarged from non-specific infection. Anyone who has observed the large, chronically inflamed glands in the hilum which are often displayed during lobectomy for bronchiectasis and other septic conditions should appreciate this possibility. If the glands are acutely and severely affected by a very acute process the bronchus can readily become obstructed. A vicious circle may then develop; resolution of the obstructed infected lobe is retarded by the interference with bronchial drainage and resolution of the inflamed obstructing glands is retarded by persistence of the infection within the lobe. This would appear to be a reasonable explanation of the occasional cases one sees of middle lobe bronchiectasis and infection in which there is no positive evidence of previous or present tuberculous lymphadenitis. At operation on such a case I have been impressed with the complete absence of destruction or involvement of the fascial planes around the middle lobe bronchus and the vessels, in contrast to the post-tuberculous cases in which previous severe peri-adenitis has always caused obliteration of fascial planes and often extremely dense adherence between the glands and the hilar structures. Obstruction and consolidation of the middle lobe may also be caused by extensive malignant mediastinal lymph-gland involvement; in these cases a mediastinal mass is revealed radiographically.

Graham, Burford, and Mayer (1948) have recently described 12 examples of compression of the middle lobe bronchus by enlarged lymph nodes in non-tuberculous cases. Haemoptysis and recurrent episodes of pulmonary infection were the major presenting symptoms, and in the intervals between the episodes the patient complained of feeling unwell and tiring easily. All 12 patients were submitted to middle lobectomy. At operation the proximal portion of the middle lobe bronchus was compressed in all 12 cases by enlarged, firm lymph nodes; the key node was most frequently found on the inferior surface of the bronchus. Graham and his colleagues state that the compression was definite and unmistakable, and, when the node was removed, the groove in the bronchus remained. The main bronchus to the middle lobe showed cicatricial stenosis most prominent at the point of maximum compression, and the authors suggest that this stenosis may not be due entirely to pressure by enlarged glands but may in part be caused by spread of infection through the bronchial wall from the glands. They do not, however, mention whether the excised lobes were radiographed to demonstrate or exclude the presence of calcification within the lobe or lymph nodes.

Zdansky (1946) states also that non-specific glandular infection can cause obstruction of the middle lobe bronchus.

The Anatomical Involvement of the Middle Lobe.—The origin of the middle lobe bronchus is shown in Fig. 4 and also in various bronchograms; one should note the long slender stem curving downwards and forwards from the main bronchus before it divides into its two divisions, medial and lateral, to which medial and lateral segments are related. The disposition of the glands around

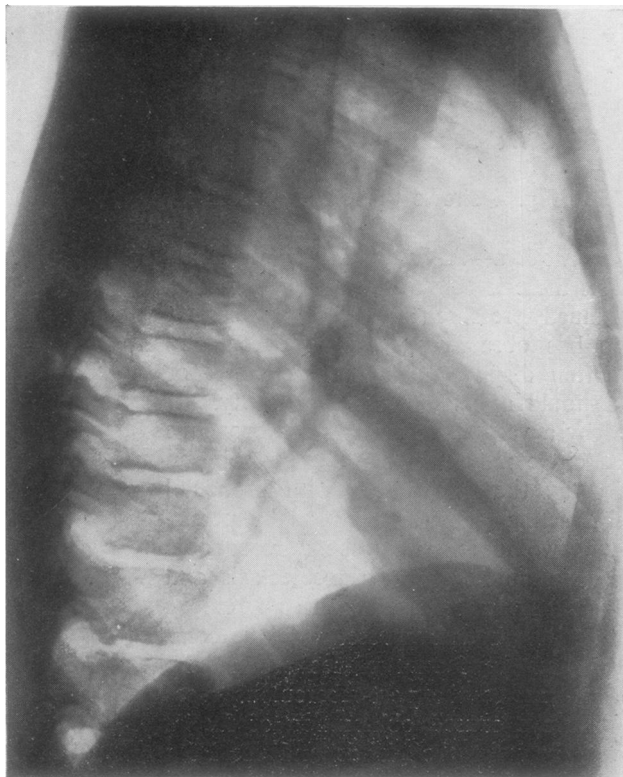


FIG. 6a.—Plain lateral radiograph showing narrow opacity due to a collapsed middle lobe. A calcified primary focus is seen in the adjacent part of the lower lobe, and two large calcified glands can be seen in relation to the hilar portions of the middle lobe.

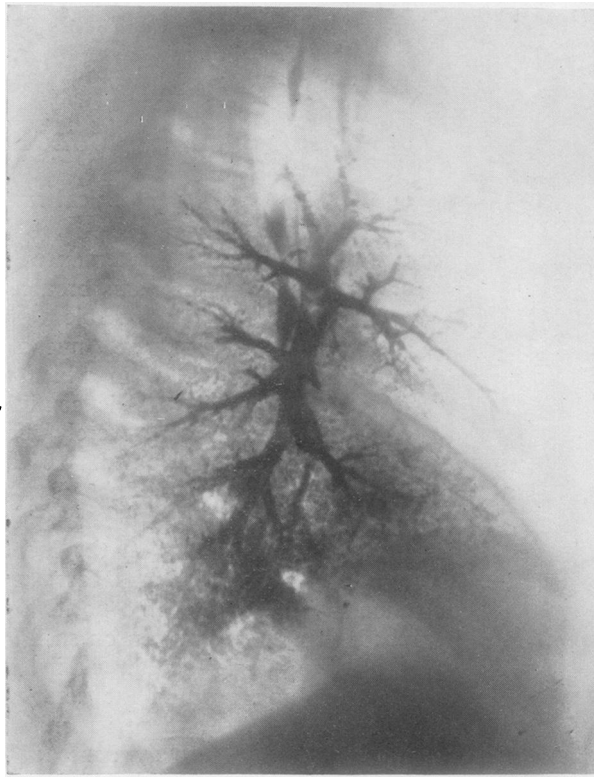


FIG. 6b.—Right lateral bronchogram of the same case, in which complete stenosis of the middle lobe bronchus is seen about 1 cm. from its origin.

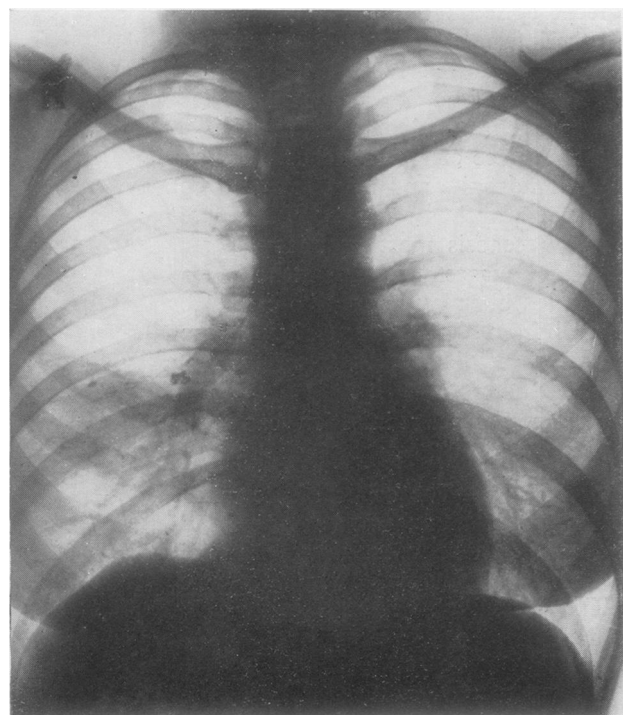


FIG. 7a.—Plain radiograph showing vague "clouding" of lateral part of middle lobe. A calcified primary focus can be seen lying in this area in relation to the fourth rib in front. Calcified glands can be seen at the root.

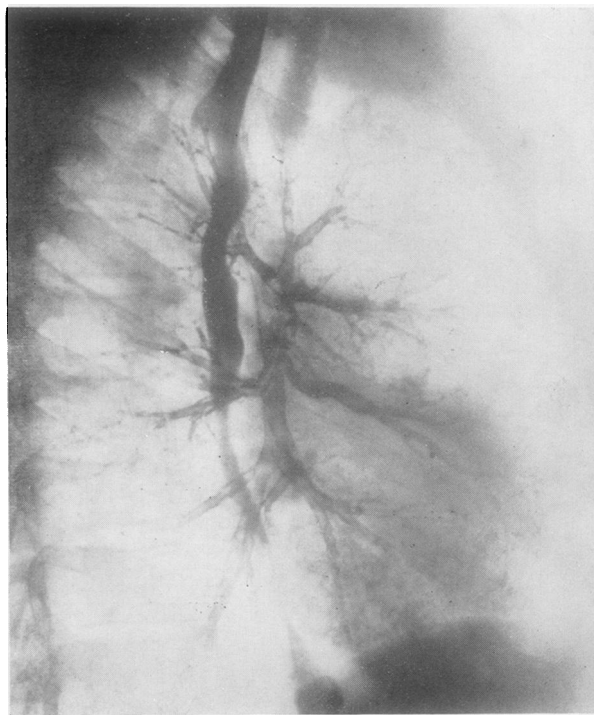


FIG. 7b.—Right lateral bronchogram of the same case, in which only the medial branch of the middle lobe bronchus is filled. The lateral branch can be seen to be blocked at its origin.

the bronchus is shown in Figs. 2 and 3; Fig. 17 shows especially well the site of a gland which appears to be the one most commonly responsible for obstruction and even destruction of the middle lobe bronchus. The whole middle lobe may be involved (Fig. 6) and this occurred in 50 cases; in nine the lateral division was affected (Fig. 7); the medial division alone was affected in only one instance (Fig. 8). There is little doubt that a broncho-stenosis or bronchiectasis confined to the lateral segment of the middle lobe is strongly indicative of a post-tuberculous lesion.

Morbid Anatomy and Pathology.—It is necessary to consider the morbid anatomy and pathology of the condition as it affects the middle lobe throughout the various stages of its development, even though in this article we are more concerned with the later secondary manifestations. Thus in the present series only five cases occurred in children under 12; 13 patients were in the late teens or early twenties; the remaining 41 were all ages up to 72, and it is clear that in most of these one was dealing with the results of a primary disease nearly as old as the patient

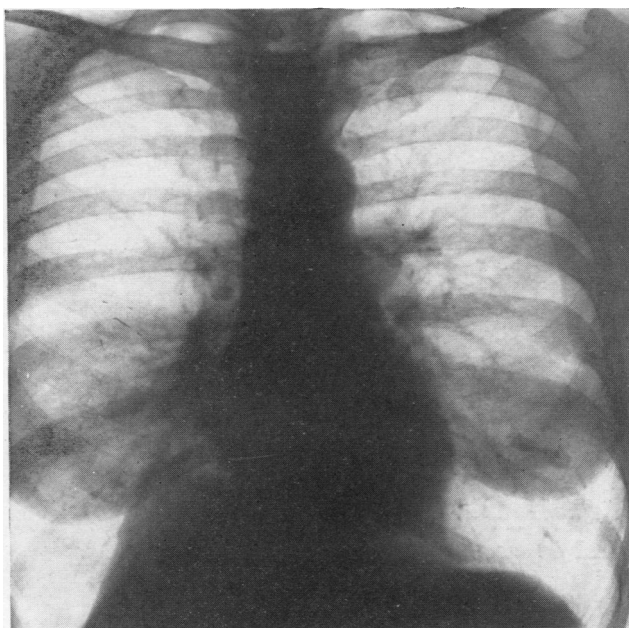


FIG. 8a.—Plain radiograph showing opacity in medial segment of the middle lobe; the diaphragm is raised and distorted. A calcified primary focus can be seen lying in relation to the sixth rib in front. Calcified glands can be seen at the root.

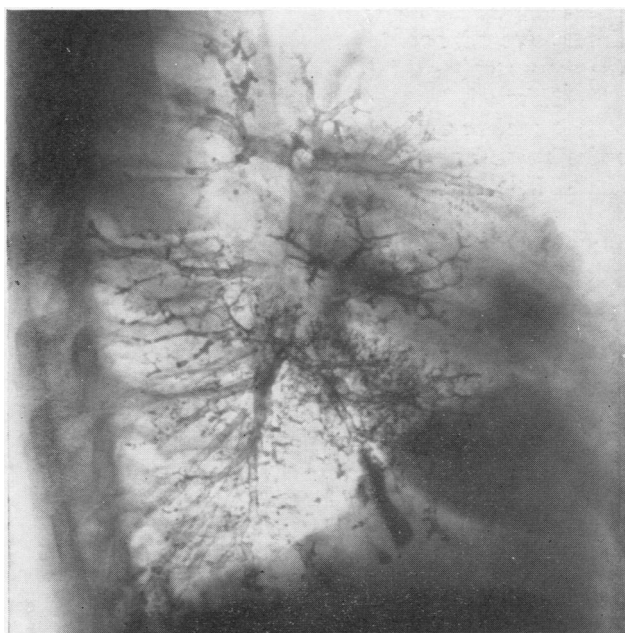


FIG. 8b.—Right lateral bronchogram of the same case in which only the lateral branch of the middle lobe bronchus is filled; the medial portion of the lobe shows the opaque area seen in 8a.

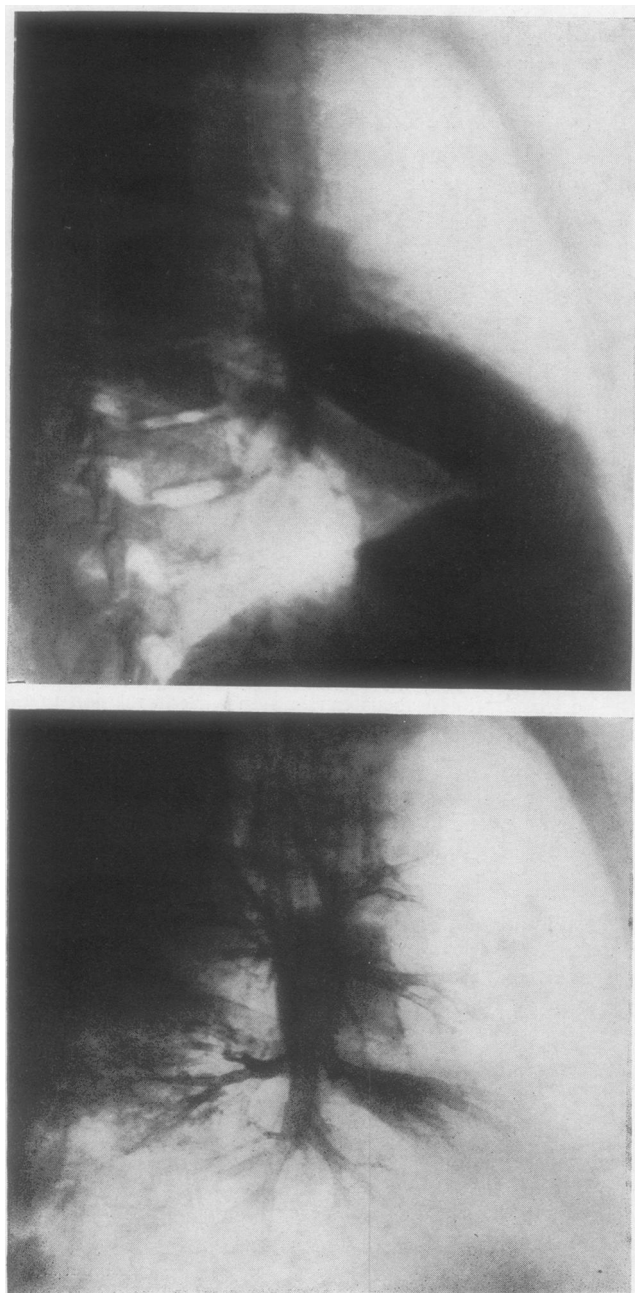


FIG. 9.—Case 1; radiograph shows consolidation of the middle lobe, and the bronchogram a sessile filling defect in the floor of the middle lobe bronchus; biopsy demonstrated tuberculous granulation tissue.

himself. This indeed is one of the striking features, that half a century or more may elapse before significant symptoms arise.

In children one is dealing with a recent infection, and the pathological and radiological picture is predominantly one of enlarged mediastinal and hilar lymph glands with secondary obstruction of the middle lobe. The glandular masses may entirely dominate the picture and it is unusual to observe less than total middle lobe involvement. The obstructed bronchus may be merely pressed upon or it may be filled by caseous granulomatous material which may be seen and partly removed at bronchoscopy.

More important to us now are those cases in the late teens or early twenties. In these patients the possibility of a tuberculous basis for the presenting lesion may not be suspected; it cannot be too strongly emphasized that if one is confronted with a predominating middle lobe lesion in an adolescent or young adult one must think of tuberculosis and diagnose it as the primary lesion until it has been positively excluded. The same rule applies to any segmental lesion (e.g., pectoral or lingula) in a young adult. If this is

ignored one may make a grave error in advising operation unless full consideration has been given to the possibility of active tuberculous disease still being present. A few years ago it was a very serious and usually fatal matter to operate on a case diagnosed as bronchiectasis in which active tuberculous adenitis was present; the old tourniquet method of resection inevitably led to infected tissue being left behind, and fistula formation, pyothorax, and spill-over infection of the lung invariably occurred. The danger is less to-day with the clean dissection technique used, but it is still no excuse deliberately to invite the hazard of local or general dissemination of the tuberculous process. I find one is still asked to operate on young people with an obstructed middle lobe and much obvious associated lymphadenitis in whom the presence of active tuberculosis has never been considered. Apart from the dangers incurred by operation it is by no means possible to say in such cases whether an operation will even eventually be needed. To operate in the presence of active lymphadenitis is unjustifiable. If the process is given time to resolve

B

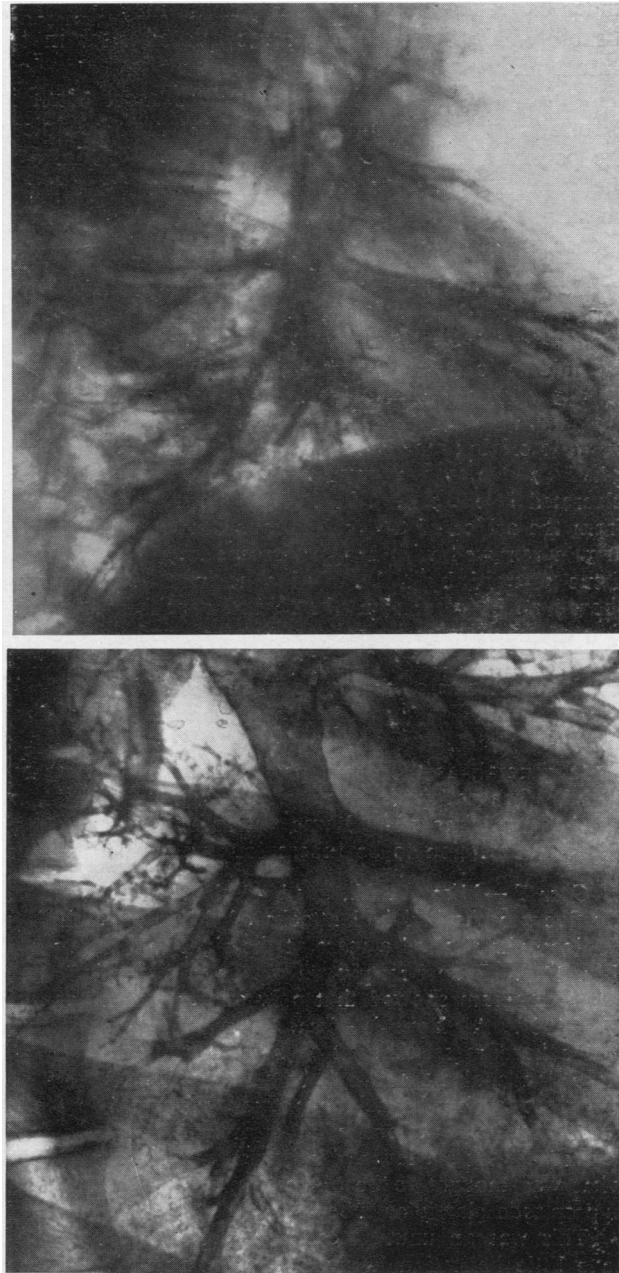


FIG. 10.—Further bronchograms of Case 1 to show progressive resolution of the tuberculous process ulcerating into the middle lobe bronchus; slight tubular bronchiectasis remains.

under expectant treatment the patient may be left with little residual disease or disability. A study of the cases quoted later in this paper should support this statement.

Since the primary infection occurs most often in the first few years of life it follows that the tuberculous element may be quiescent even in the teens. Thus the patient whose radiographs are shown in Fig. 6 was only 15 years of age and the process is clearly an old one. On the other hand the infection may still be smouldering, or late primary infection may occur. Figs. 9 and 10 are of such a case.

Case 1.—The patient, a sailor 22 years old, had had a chest radiograph two years earlier which showed normal lungs. It is probable that his primary infection occurred soon after his enlistment. His first illness was due to pneumonic consolidation of the middle lobe associated with painful pleurisy. Radiographs showed consolidation of the middle lobe (Fig. 9). A bronchogram is most instructive (Fig. 9), for it shows an undoubted filling defect in the floor of the middle lobe bronchus about 1.5 cm. from its origin; moderate distal tubular bronchiectasis can be seen. Such an obstruction could be due to a growth, but the site is the site of election of a tuberculous gland ulcerated into the bronchus. Bronchoscopy confirmed that this was so; about 1 cm. from the orifice of the middle lobe bronchus a grey, oedematous polyp could be seen. It was removed with biopsy forceps and was reported to be tuberculous granulation tissue covered by a layer of squamous epithelium. Later bronchograms (Fig. 10) show a steady regression of the intrabronchial projection and virtually complete restoration of the lumen; bronchoscopy confirmed this healing. There is no doubt that this patient suffered from ulceration of a tuberculous gland into the bronchial lumen, and it is interesting to observe that, in spite of this, healing has not inevitably been followed by stricture. Whether the tubular bronchiectatic changes are reversible time alone can tell.

In general, as the years pass, it is less likely that active tuberculosis will still be found. One patient in this series, a woman aged 44, was an exception. She was seen in 1941 at a time when I was not fully familiar with the importance of considering a middle lobe lesion to be tuberculous until proved otherwise.

Case 2.—Miss M. Y., aged 44, had suffered from asthma for several years, and for five months had had attacks of dyspnoea with fever, sputum, and loss of weight. Radiographs showed a mass at the right root in the neighbourhood of the middle lobe (Fig. 11a). Bronchoscopy revealed narrowing just inside the middle lobe orifice, and a bronchogram showed that only one branch of one division of the middle lobe filled (Fig. 11b). A diagnosis of carcinoma was made and thoracotomy advised. At operation a hard mass, thought to be malignant, surrounded the root of the middle lobe; large glands, also thought to be malignant, were present in the hilum and in the inferior and right tracheo-bronchial groups; one gland in the anterior mediastinum and others high up in the posterior mediastinum were enlarged. A diagnosis of inoperable carcinoma seemed certain; a large gland was removed for biopsy and macroscopically contained what was thought to be obvious growth. Histological examination revealed a typical hyperplastic glandular tuberculosis.

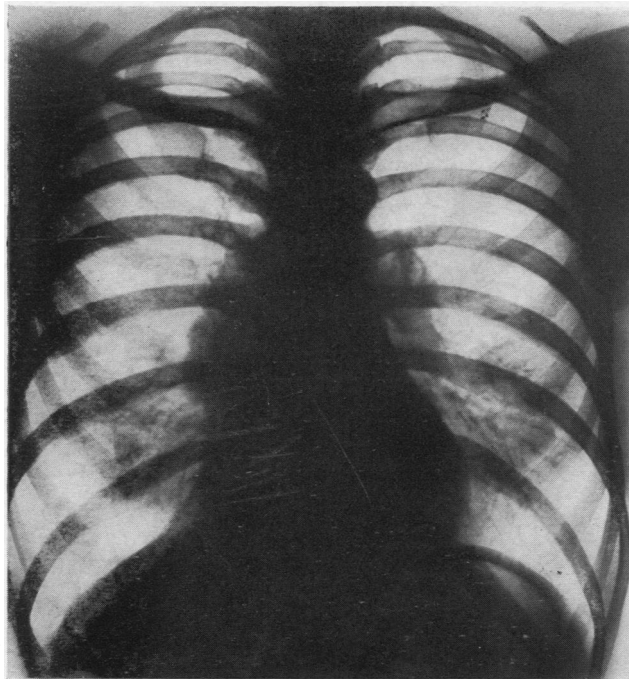
This was an unusual case both clinically and pathologically, but to-day I should have little hesitation in making a pre-operative diagnosis of tuberculosis before that of growth.

In all the 40 cases in the older age groups the pathological changes were, or seemed to be, those of the late secondary manifestations of the disease. The

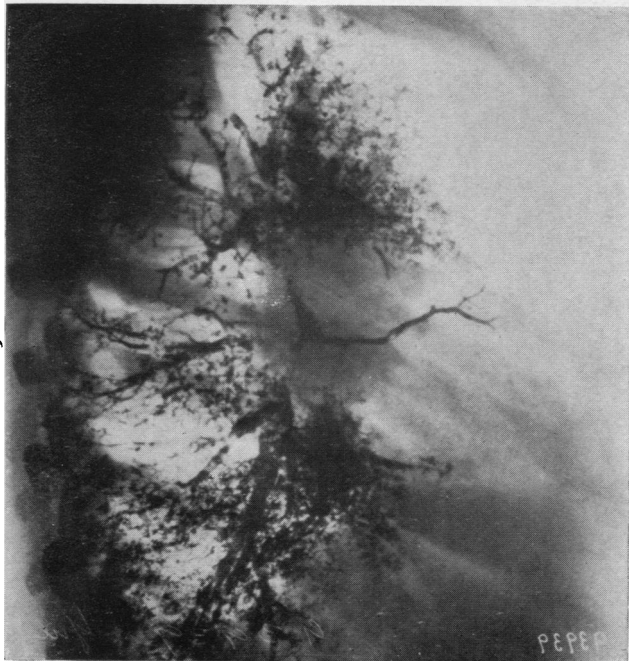
morbid anatomical changes to be considered are fourfold, (1) fibrosis and bronchiectasis, (2) stricture formation, (3) calcification, and (4) the varying grades of inflammation associated with these.

FIBROSIS AND BRONCHIECTASIS

Although the lumen of the obstructed bronchus may be completely restored, the secondary effects on the bronchi and lung tissue may have caused permanent bronchiectasis and pulmonary fibrosis of varying degrees of severity. The ultimate clinical presentation may indeed be solely that of bronchiectasis. Fig. 5, already commented upon, shows a perfect example of saccular bronchiectasis affecting the cardiac segment as well as the middle lobe. In Fig. 22 is seen a thin, shrunken, fibrous bronchiectatic lobe, albeit the stem bronchus is quite patent. The adjacent calcified gland is well shown in the postero-anterior radiograph in Fig. 22*a*. Fig. 3 shows photographs of actual specimens removed at operation in which fibrosis and bronchiectasis are present.



(a)



(b)

FIG. 11.—Radiographs of Case 2; simulation of bronchial carcinoma by a mass of hyperplastic tuberculous mediastinal lymph glands; 11*b* shows almost complete block of the middle lobe bronchus.

STRICTURE FORMATION

Stricture of the bronchus may be partial or complete. It may affect either the main stem or the lateral or the medial division; the order of frequency has been indicated above. When specimens are dissected it may be found that a smaller bronchus is strictured (Fig. 16*a*). Although the actual stricture may in this way affect only a branch of the middle lobe bronchus, it often happens that coincidentally the whole lobe is affected by bronchiectasis and fibrosis, indicating that it had been completely obstructed during the primary process but the lumen has been restored except in the branch which has been more severely affected. Sometimes the strictured branch is the only one affected and the rest of the middle lobe branches are normal (Figs. 1*c*, 7*b*, and 8*b*).

When the main stem is strictured the obstruction always occurs about 1 cm.-1.5 cm. from the mouth of the bronchus (Figs. 6*b*, 9*b*, and 23*b*). In Fig. 9*b* the site of ulceration of the causal gland is particularly well shown. When the lateral division is affected the stricture is usually at its very origin (Figs. 1*c* and 7*b*).

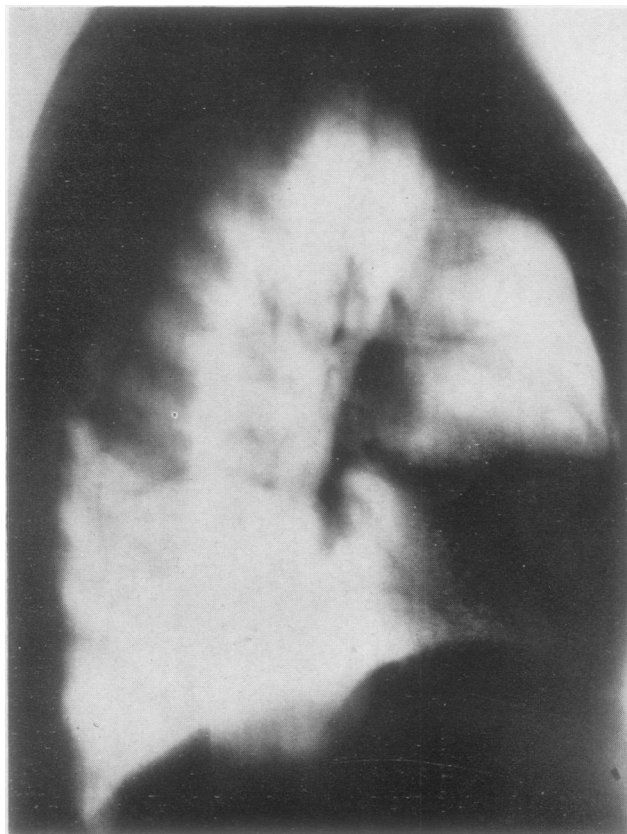


FIG. 12.—Lateral tomograph to show a calcified gland in close relation to the hilar connexions of an atelectatic middle lobe.

If the stricture is complete the bronchi and lung behind it may become shrunken and fibrous; this is less likely than distension with mucus or muco-pus to form a mucocele or pyocele. Fig. 24 shows a middle lobe removed at operation in which complete stenosis had occurred just before the stem bronchus divided (the usual site). The two branches are grossly dilated and formed two oval cystic spaces full of dirty muco-pus; at operation the lobe closely resembled an obstructed, distended, and fibrous gall-bladder.

If stenosis occurs while the tuberculous process is still active a tuberculous pyocele of the bronchus results (Fig. 16).

CALCIFICATION

Calcification occupies a prominent position in the syndrome. Since the condition is caused principally by glands which have been so severely infected as to caseate, calcification is inevitable. This may be of little pathological or clinical significance except in so far as its demonstration radiographically is of assistance in diagnosis. On the other hand the calcification may be responsible for some of the gravest secondary effects if the calcified material ulcerates from the containing gland capsule into the lung or bronchus. A broncholith may be associated with few secondary changes and may be coughed up with little disturbance; occasionally a number of calcified fragments may be coughed up in this way. More usually it cannot escape owing to its size or to the presence of a stricture, and thus a severe inflammatory process results. Fig. 15 is of a case in which a whole chain of broncholiths were present; they caused a severe, almost fulminant suppurative pneumonitis with abscess formation.

Fig. 21*a* shows a case in which the middle lobe bronchus ended after about 1 cm. in a large irregular fibrous cavity within the lung which contained a number of free calcified fragments or "pneumoliths." This cavity had secondary extensions into the upper and into the lower lobes, and the pneumoliths had actually passed in this way from the middle lobe to secondary foci in the other two lobes.

The presence of calcification or of calcified glands may constitute a serious technical complication at operation, for it may be found that the bronchus and branches of the pulmonary artery are almost inextricably fused in a densely adherent, irregular mass of fibrous calcified tissue. Calcification may sometimes be shown much more clearly in tomo-

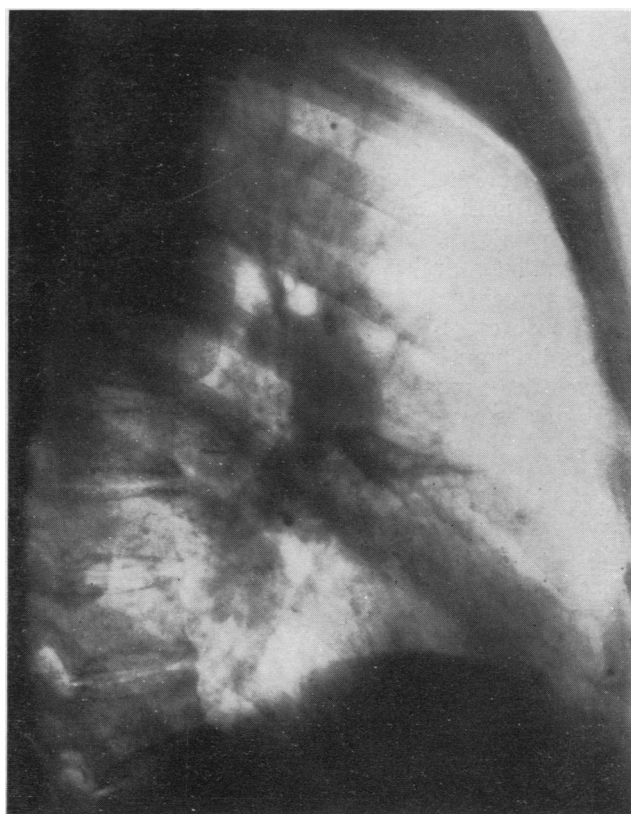


FIG. 13.—Lateral radiograph to show a contracted "honey-combed" lateral segment of the middle lobe. Calcified primary foci can be seen in the lung and also at least one calcified gland.

graphs. Fig. 12 is a lateral tomograph in which a calcified gland is clearly seen in relation to the origin of the middle lobe bronchus in association with a collapsed middle lobe.

THE GRADES OF SECONDARY INFLAMMATION

As already mentioned the original disease process may leave a bronchiectatic lobe without broncho-stenosis, or it may leave the whole lobe bronchiectatic with stenosis of the main bronchus or of one division or of a small branch only. Sometimes the stenosed division (e.g., lateral) alone is bronchiectatic, the rest of the lobe being normal. From these basic patterns the changes in the lobe or distal to the stricture vary, chiefly dependent upon the presence or severity of infection. When no stricture is present the changes are likely to be less severe.

The whole lobe or a segment may be consolidated from acute or chronic pneumonitis (Figs. 1*a*, 6*a*, 9*a*, 14*a* and *b*, and 19) or it may be shrunken and airless (Fig. 22). Sometimes it is honeycombed (Fig. 13) or it may exhibit larger cystic spaces that may be empty when uninfected but can become a mass of suppurating cavities that present as one or more large abscess cavities.

The more serious results occur when there is severe stricture formation, for the onset of a mild catarrhal infection may, by causing mucosal swelling and thickened exudate, precipitate complete obstruction with consequent increase in the severity of the infection and its secondary effects. If broncholiths or pneumoliths are also present a very severe, even gangrenous, infection results. An obstructed infected lobe or segment which cannot drain proximally just goes on distending until it bursts into the pleura and a severe, almost fulminant, pleural infection follows. I have seen this on a number of occasions; in one case, to be described later, drainage of the empyema was followed by an extensive, progressive cutaneous gangrene and a persistent bronchopleural fistula.

In such cases disease which had been confined to the middle lobe or even to one of its branches may cause secondary suppuration throughout the same lung or even the opposite lung. Finally metastatic septic foci may be caused, notably cerebral abscess.

CLINICAL FEATURES

The clinical manifestations of the post-tuberculous middle lobe syndrome vary greatly in different cases and at different times. Many of them can be inferred from the description of the pathology.

There seems to be little difference in the sex incidence; in this series 34 cases occurred in women and 26 in men.

The age incidence is important and is analysed in Table II.

TABLE II
AGE INCIDENCE

Age Group (Years)					No. of Cases	Age Group (Years)					No. of Cases
0-10	5	41-50	18
11-20	4	51-60	9
21-30	12	61-70	6
31-40	5	Over 70	1

It should be noted that the greatest incidence was in the fifth decade and that more than half (34 out of 60) of the patients were over 40 years of age; 16 were over 50 years of age. It is thus clear that it overlaps the cancer age and must be thought of in differential diagnosis in any middle-aged or elderly patient. Most of the elderly patients had had trivial previous chest symptoms or no previous chest symptoms at all.

The main presentation may be in one or more of the following ways:—

- (a) Bronchiectasis.
- (b) Recurrent haemoptysis.
- (c) General unfitness, often associated with local pain.
- (d) Single acute pneumonic episode.
- (e) Lung abscess or suppurative pneumonitis.
- (f) Acute empyema.
- (g) "Unresolved pneumonia."
- (h) Recurrent pyrexial attacks.
- (i) Simulating bronchial carcinoma.

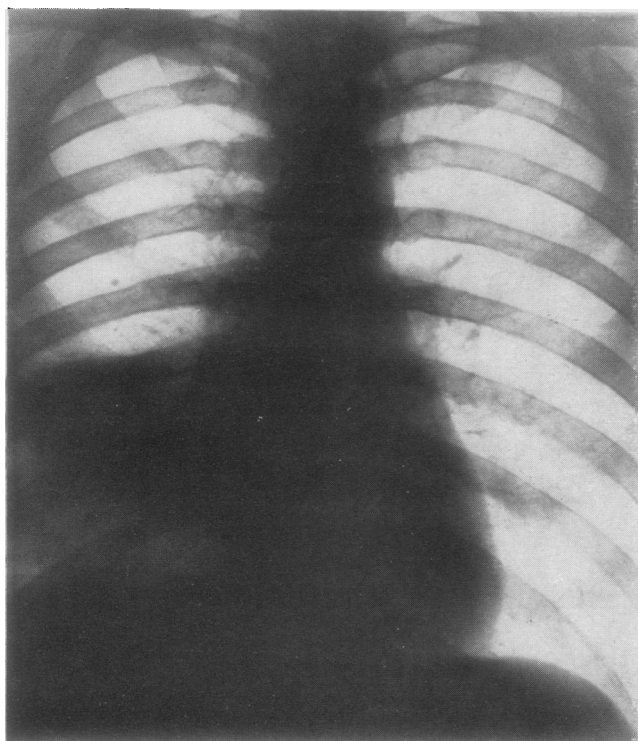
Little need be said about the bronchiectatic aspect except to re-emphasize that in any case of a middle lobe lesion, especially in a young adult, the probable tuberculous basis should be remembered and allowed for in diagnosis and treatment.

Haemoptysis is rarely the sole symptom, being mostly associated with cough and sputum or a febrile attack. The amount of blood spat up may, however, be considerable and may dominate the clinical picture. Blood-stained sputum or minor haemoptyses are also common. Haemorrhage in some form was present in 31 cases, i.e., more than half. It will be referred to again in connexion with the mimicry of bronchial carcinoma.

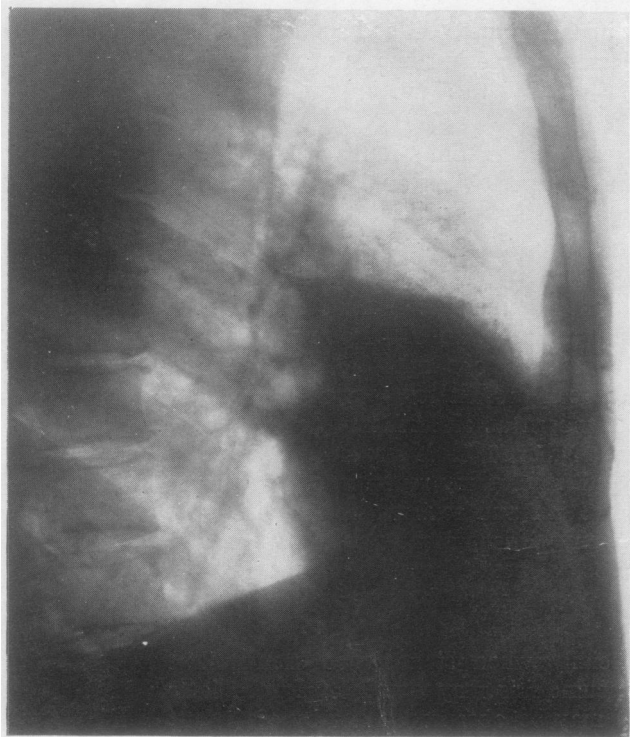
General unfitness is an especially interesting symptom; it may be a vague but leading symptom and can be completely relieved when an infected lobe has been removed. In one patient with a completely obstructed lobe (Fig. 23), unfitness and flitting arthritis with nagging pain in the lower right chest were the only symptoms.

A single acute pneumonic episode may be the first manifestation of the condition and this may occur even in an elderly patient; it was, for instance, the first sign of the disease in two patients aged 60 and in one aged 66, although the underlying pathological condition must have been present for over half a century in each case. The acute attack may be diagnosed as an ordinary acute specific pneumonia, and this diagnosis may be strengthened if it proceeds to pleural infection and empyema. Chronicity, delayed resolution, recurrence, or abscess formation may lead to more careful consideration and revision of the diagnosis. It is necessary to repeat once more that in any patient at any age in whom the disease is predominantly in the middle lobe, a post-tuberculous basis for the attack must be considered before all else. In younger patients active tuberculosis must be allowed for.

In the severe forms of infection, especially when stenosis or broncholiths are present, lung abscess or suppurative pneumonitis may develop. In the later stages its primary origin in the middle lobe may be obscured either by secondary

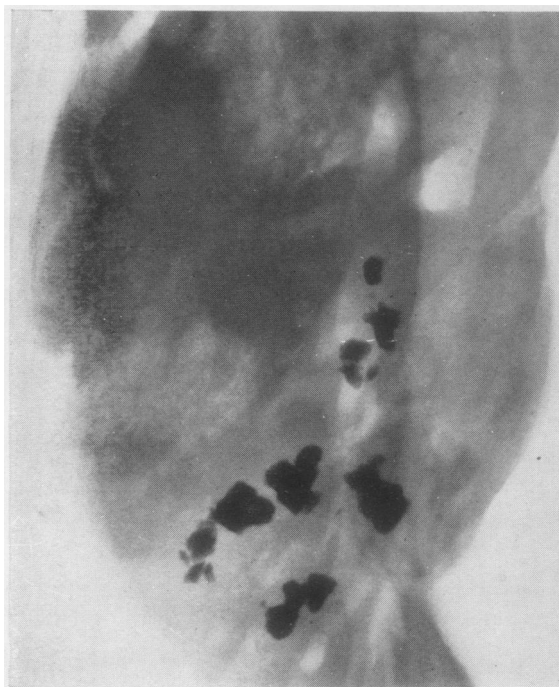

(a)

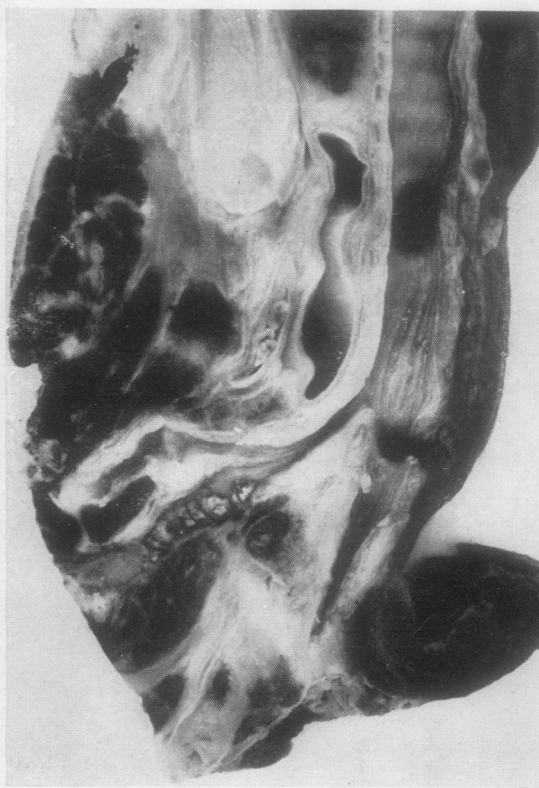

(b)

FIG. 14.—Radiographs of Case 3, showing consolidation of the middle lobe associated with abscess formation. Calcified lung foci and calcified glands can be detected, but the dense opacity conceals many others (see Fig. 15).



(a)



(b)

FIG. 15.—Radiograph and photograph of the specimen removed post-mortem from Case 3. The radiograph shows numerous calcified areas, some of which are in the lymph glands; others, as shown in 15b, are lying loose in the middle lobe bronchus as "broncholiths."

involvement of other lobes or by pleural infection. If the lesion can be recognized as originating in the middle lobe the rule already stressed should be applied, namely that the abscess is almost certainly part of a post-tuberculous syndrome. Unfortunately it is common to find that once a diagnosis of lung abscess or suppurative pneumonitis has been made little further thought is given to the problem of aetiology. The whole question of the importance of trying to find the primary cause in every case of lung abscess is fully discussed in an earlier article on the aetiology of lung abscess (Brock, 1948). The following is an illustrative case of severe lung abscess secondary to post-tuberculous broncho-stenosis with broncholith formation.

Case 3.—Mr. F. Y. a gas worker aged 44, had no previous history of cough or sputum before he was taken ill with “pleurisy and pneumonia” on August 20, 1944. A diagnosis of lobar pneumonia was made at the hospital to which he was admitted, even though radiographs showed two abscess cavities in the middle lobe, affecting both segments, and he was coughing up six ounces of purulent sputum per day. It is possible that a lung abscess was not diagnosed because the sputum was not offensive. He was transferred to the Horton Chest Unit in mid-November; he had been having irregular bouts of fever, but during the last few days fever had increased and the sputum had reached as much as 15 oz. It was purulent but still not offensive; it had been blood-stained once. Radiographs showed consolidation of the middle lobe; two calcified foci could be seen in the right lung and the hilar glands showed much calcification (Fig. 14 *a* and *b*).

A diagnosis was made of broncho-stenosis due to old tuberculous lymphadenitis with secondary infection and abscess formation. Because of the large amount of sputum external drainage was advised; in view of later events it is unfortunate that lobectomy was not performed at once in spite of the abundant sputum and the poor general condition of the patient.

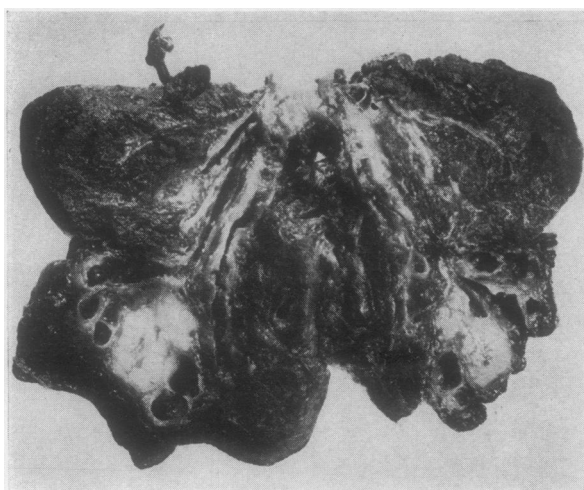
On December 23 a segment of the fourth rib in the axilla was resected; the pleura was densely adherent and three large abscess cavities were found in the middle lobe; they contained inoffensive pus and lung sloughs.

After temporary improvement the patient's condition became worse and an abscess in the posterior basal segment of the right lower lobe had to be drained. He then developed a septic pneumonitis which was beginning to improve when he suddenly became unconscious and died in less than 24 hours.

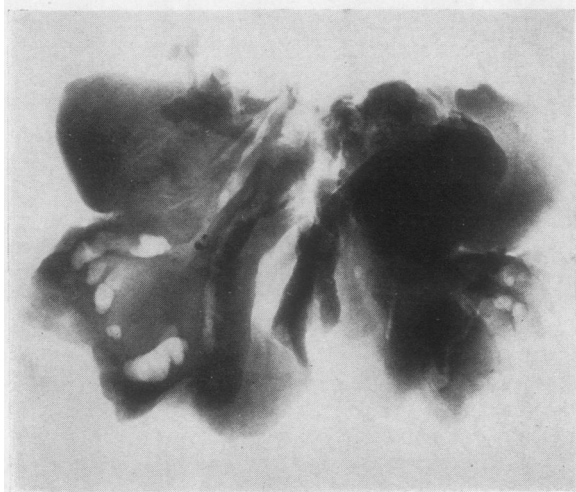Necropsy revealed a large abscess in the parietal lobe of the cerebrum. The middle lobe bronchus was narrowed so as just to admit a fine probe with which gross calcification could be felt. A radiograph of the specimen before dissection is shown in Fig. 15*a*. Dissection revealed that the middle lobe bronchus was distorted and its lumen irregularly stenosed in conformity with adjacent calcified glands. The lateral branch was grossly abnormal; at its origin a mass of calcified tissue was lying half within the bronchial lumen and half outside the bronchial wall causing obstruction; distal to this were two large broncholiths and three smaller ones. Beyond these the bronchus widened into a small residual abscess cavity. The narrowed stem of the middle lobe bronchus and the broncholiths in its lateral branch are shown in Fig. 15*b*.

The following case well illustrates how it is difficult to over-emphasize the need for attributing a post-tuberculous basis for any middle lobe lesion, especially in a young adult in whom the probability of the tuberculous infection still being active renders the probability of very great importance.

Case 4.—Miss D. E., a medical practitioner aged 25, had undergone tonsillectomy five years before; this had been followed by severe haemorrhage and the development of an acute lung abscess. Radiographs taken at this time showed consolidation of the



(a)



(b)

FIG. 16.—Photograph and radiograph of specimen removed at operation from Case 4. The lateral branch of the middle lobe bronchus and its branches are grossly dilated and in the fresh state were full of thick pus containing tubercle bacilli. This segment also includes a roughly oval, solid caseous focus or "tuberculoma." One small branch of the bronchus is completely blocked. The radiograph reveals a small, finely calcified area.

middle lobe, with an abscess cavity containing a fluid level in its lateral segment. This eventually resolved and she continued her medical training without further trouble. While doing a house appointment she developed a minor catarrhal infection associated with some cough and sputum and pain in the right chest; radiographs revealed an opacity in the middle lobe. Although her symptoms soon subsided the radiographic opacity persisted. In this case there seemed no reason to doubt the original nature of the post-tonsillectomy lung abscess, and the persistent opacity seemed to be explicable on the basis of infection in a fibrous lobe. Dr. Hoyle advised operation in view of the risk of recurrence of infection; and middle lobectomy was performed.

It is worthy of note that although this patient had no symptoms and no cough or sputum at the time of operation, when the excised lobe was held up and gently squeezed thick pus dripped from the bronchus. This pus contained tubercle bacilli, and when the lobe was cut open it was seen to contain active tuberculosis. There were numerous miliary tubercles, but the main lesion (Fig. 16a) was caseating tuberculosis in the lateral segment behind a broncho-stenosis; the bronchi of this segment were grossly dilated and full of thick pus; one small division of this bronchus was surrounded and occluded by calcified and

caseous material. The radiograph (Fig. 16*b*) demonstrates the calcification which is too small in amount to show in the photograph of the specimen and was too small to be recognized in the chest radiographs.

If the general rule had been applied of attributing a tuberculous basis to a middle lobe lesion, and a possibly active one in a young adult, no surprise would have been felt when the true nature of the lesion was disclosed. Presumably the localization of the post-tonsillectomy infection and abscess was decided by a pre-existing broncho-stenosis and bronchiectasis; the stenosis led to imperfect resolution of the process.

As opposed to frank abscess formation, severe suppurative pneumonitis, probably with an accompanying acute empyema, may be seen. In the following case a diagnosis of "pneumonia and empyema" had been made, but the full story reveals that such a diagnosis is woefully inadequate, as is, indeed, often the case.

Case 5.—Mr. L. J., aged 61, developed right-sided "pneumonia and pleurisy" in August, 1944; this was followed by an empyema which was drained by rib-resection in September, 1944. A condition of progressive cutaneous gangrene developed in the operation wound and spread until it eventually extended from the nape of the neck to the loin, and from the midline behind to nearly the midline in front. This process was eventually checked by excision and penicillin and the huge area successfully skin-grafted by Mr. Coleman, of Llandudno.

In April, 1945, the wound began to discharge again and the patient also coughed up chocolate-coloured sputum, which he was still coughing up when I first saw him in July, 1945. Radiographs showed a small residual opacity and some honeycombing of the lung; moreover there was a calcified primary lung focus with a calcified gland in the middle lobe region, and the middle lobe seemed to be bronchiectatic.

Bronchoscopy showed some pus from the middle lobe bronchus which, however, showed no evidence of stenosis; a good view was obtained of the main stem as far as its division. A right bronchogram confirmed the presence of a large bronchiectatic cavity confined to the lateral division of the middle lobe bronchus; the medial division was normal.

Until this time he had been considered to be a case of residual lung fibrosis and destruction following an acute pneumonic episode; not an unreasonable diagnosis. While it is true that the recent acute inflammation must have caused much local destruction it is important to realize that this attack occurred as a result of pre-existing disease, old broncho-stenosis with bronchiectasis dating back probably more than half a century. Apart from purism in diagnosis this conception is of practical importance, for its presupposes an unfavourable mechanical state of affairs in the obstructed lobe which might well cause recurrence of the recent severe inflammatory episode in a volcanic-like eruption. Unfortunately his age, frailty, and the recent extensive progressive cutaneous gangrene influenced me against advising operation and in favour of delaying. This was a wrong decision in view of later events; perhaps the continued expectoration of some 2 oz. of chocolate-coloured sputum each day should have been a deciding factor.

In February, 1947, he developed fever and pain in the left side of the chest; he improved temporarily under treatment, but then relapsed and suddenly coughed up about 20 oz. of sputum in four hours; he was readmitted in May coughing up 10 oz. of sputum and with a left basal encysted empyema with a fluid level. This was drained by rib-resection and he made a good recovery.

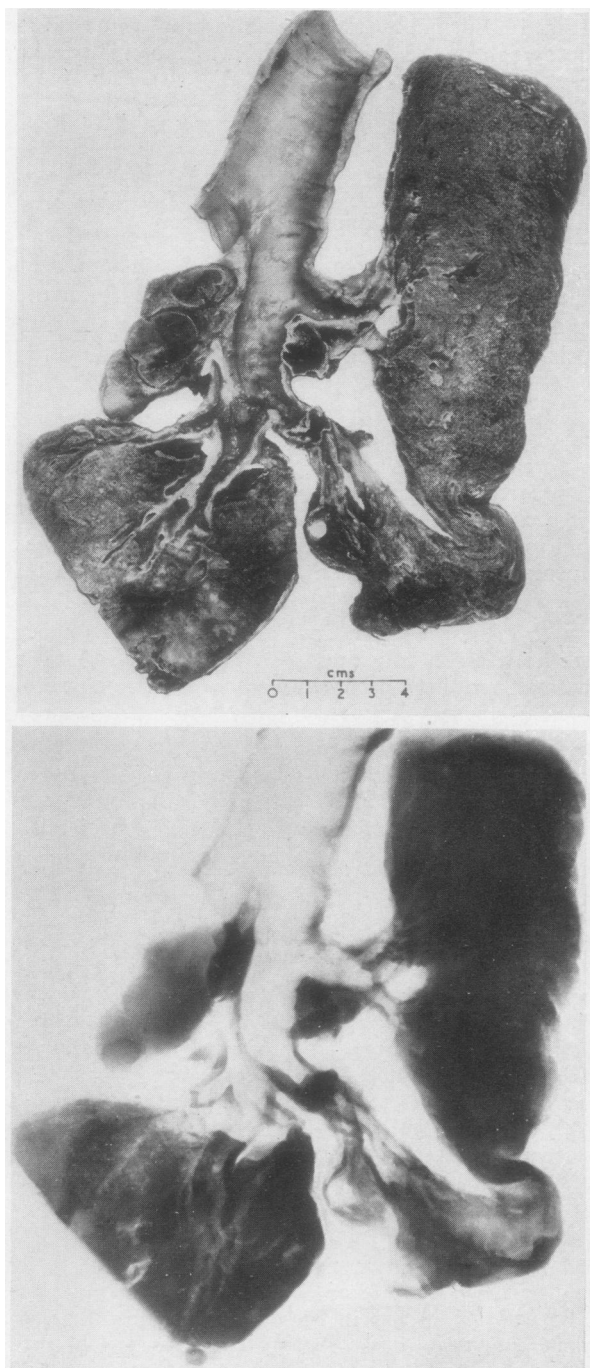
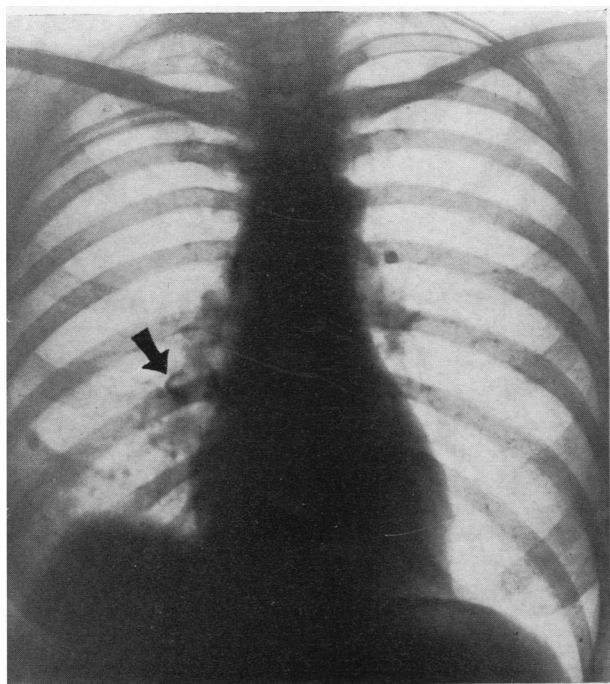


FIG. 17.—Photograph and radiograph of right lung from Case 5. The lateral segment of the middle lobe is shrunken and contains a bronchiectatic abscess cavity. A striking feature is the calcified gland.

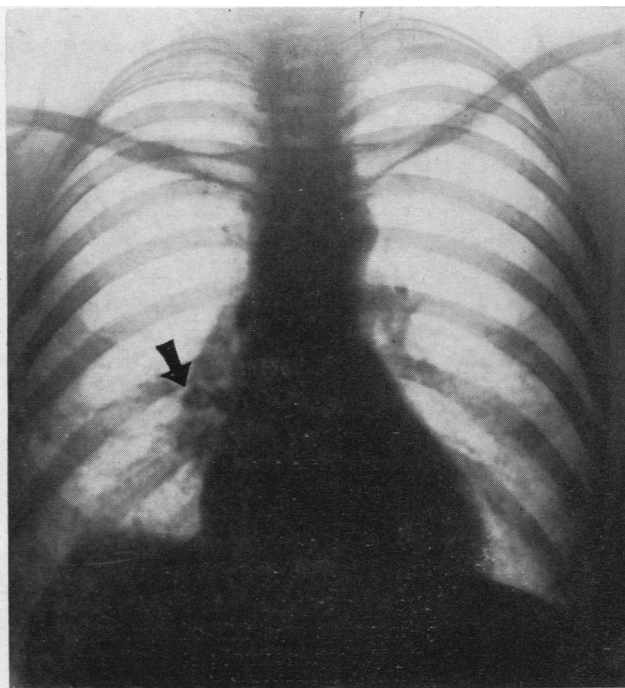
Clearly he had suffered a spill-over infection of his left lung from the persistent focus in the middle lobe, and he was told that lobectomy could no longer be avoided. He was discharged from hospital on June 28 to return for lobectomy after a period of convalescence. Four days later he returned with signs of a cerebral abscess to which he succumbed. Post-mortem examination revealed multiple cerebral abscesses and a bilateral septic pneumonitis in addition to the underlying basic pathology shown in Fig. 17.

The medial segment of the middle lobe is relatively normal; the lateral segment shows a large, bronchiectatic abscess cavity. Firmly adherent to the stem of the middle lobe bronchus, just before its bifurcation, is an almost completely calcified gland. Although the lumen is unobstructed at this level it is not going too far to suppose that when this gland was caseous and swollen it did obstruct the bronchus and gave rise to the secondary changes in the lateral segment of the middle lobe which, many decades later, were to pave the way for the secondary pyogenic infection which was responsible for his death.

The following case also illustrates severe suppurative pneumonitis and abscess formation consequent upon an old post-tuberculous broncho-stenosis with the formation of pneumoliths. It is another example of the onset of symptoms very late in life, although from the

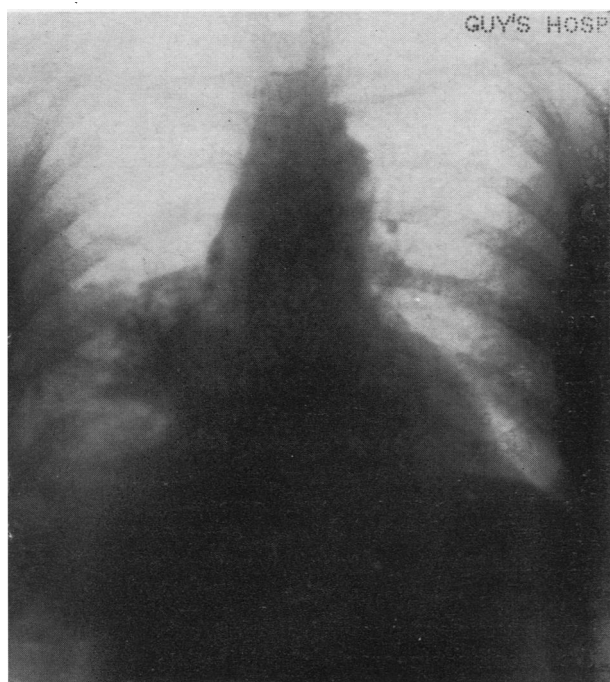


(a)

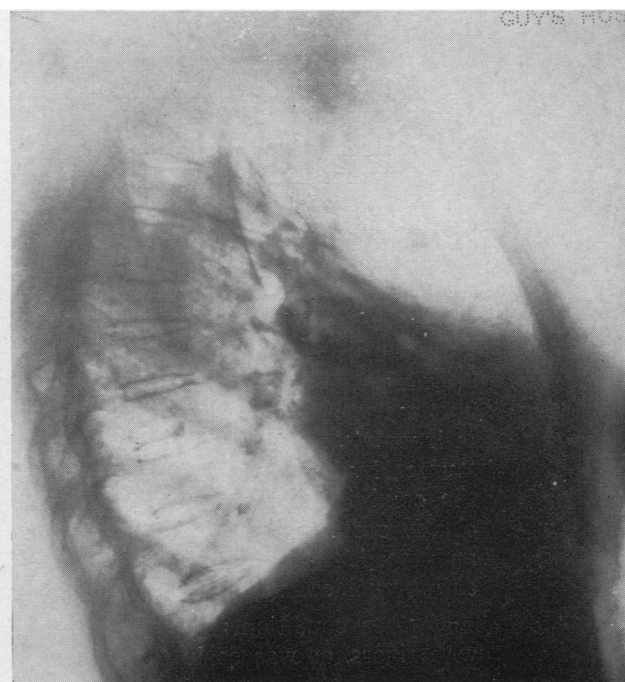


(b)

FIG. 18.—Early radiographs from Case 6, showing a typical calcified primary complex. The calcified fragment marked by arrows has changed its position in the two radiographs, conclusive proof that it is lying loose in a cavity as a “pneumolith.”



(a)



(b)

FIG. 19.—Later radiographs of Case 6 after the onset of suppurative pneumonitis; the major localization to the middle lobe is evident. The calcified area in the pectoral segment appeared suddenly and is due to migration of a pneumolith.

nature of the lesion gross changes must have been present for very many years. It also illustrates the way in which the disease, originally confined to the middle lobe, may spread to invade the whole lung.

Case 6.—Mrs. C. H., aged 59, had an attack of haemoptysis in 1945 and was admitted to a sanatorium. Radiographs at that time showed a middle lobe opacity with considerable calcification. It can be seen from Fig. 18*a* and *b* that a calcified fragment near the hilum has changed its shape and disposition, conclusive proof that it must be lying free in a cavity as a pneumolith. She continued to have attacks of haemoptysis and also began to cough up sputum; later she experienced febrile attacks, and the sputum became thick and purulent and at times offensive.

When she was admitted to Guy's Hospital in July, 1947, the sputum had increased to 4 oz. and was still intermittently offensive. On direct inquiry she stated that she had at times noticed gritty material in the sputum. Radiographs now showed considerably greater opacity in the lower half of the right lung (Fig. 19*a* and *b*), and at least two calcified masses had left their original site and each was associated with an abscess cavity. One of these was in the pectoral right upper segment, the other appeared to be in the lateral part of the apical right lower segment.

Bronchoscopy showed muco-pus coming from the right upper lobe; the middle lobe bronchus was full of pus, and when this was sucked away the lumen seemed to be larger than normal; it bled easily and contained obvious foreign matter that kept blocking the sucker tube. Several portions were removed with peanut forceps and were seen to consist of brown, paste-like material containing small calcified fragments; the pus was offensive.

At a second bronchoscopy, thick, offensive pus oozed from the middle lobe, and a sucker tube could be passed for several centimetres and at once became blocked with thick, faecal-like material.

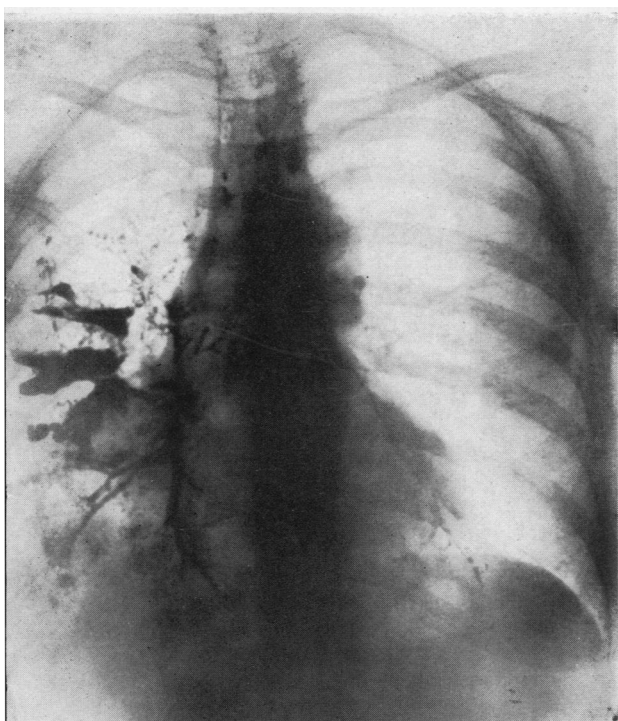
A bronchogram (Fig. 20*a* and *b*) showed numerous large irregular abscess cavities which filled with lipiodol, in addition to others that did not fill. These cavities seemed to occupy all three lobes.

Pneumonectomy was performed in December, 1947; a large calcified gland below the carina made it difficult to secure the right main bronchus.

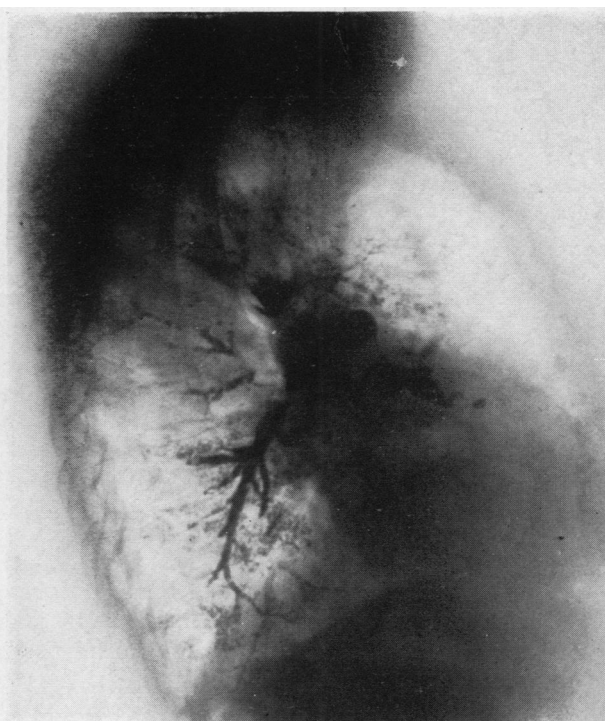Examination of the specimen (Fig. 21*a* and *b*) revealed that the middle lobe bronchus, after a course of about 1 cm., entered a large irregular abscess cavity in the middle lobe containing thick foul pus and several large pneumoliths. Irregular extensions of this cavity traversed the fissures into the upper and lower lobes, and other pneumoliths lay in these lobes. Their migration was now easily explained. The extensive calcification and numerous pneumoliths were well shown in a radiograph of the specimen.

Unresolved pneumonia is a diagnosis less often made to-day than 20 years ago because we have learnt that it is liable to be a dangerous diagnosis in that it is incomplete and often conceals a serious condition such as carcinoma. If the "unresolved pneumonia" is situated in the middle lobe then the possibility of the condition being due to a post-tuberculous broncho-stenotic syndrome must clearly come to the fore. The recognition of a related calcified primary complex and the demonstration, by bronchoscopy and bronchograms, of broncho-stenosis and bronchiectasis should clinch the matter.

Such a condition may well be associated with recurrent pyrexial attacks, even with rigors, as was so in the case cited in the opening paragraph of this article.

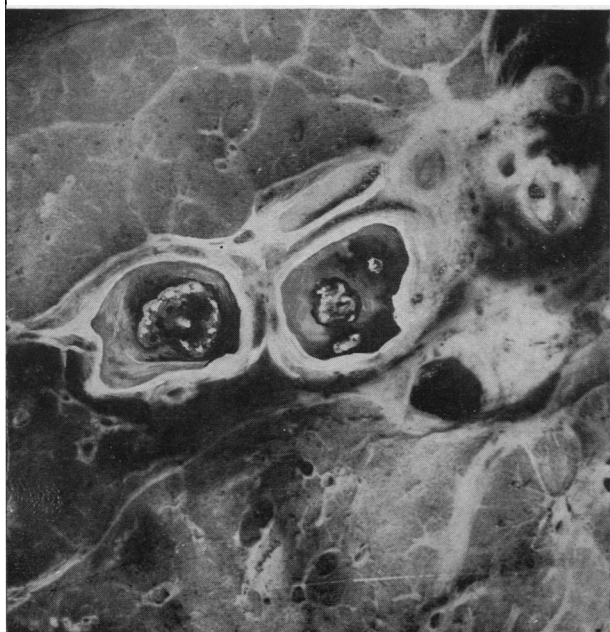


(a)

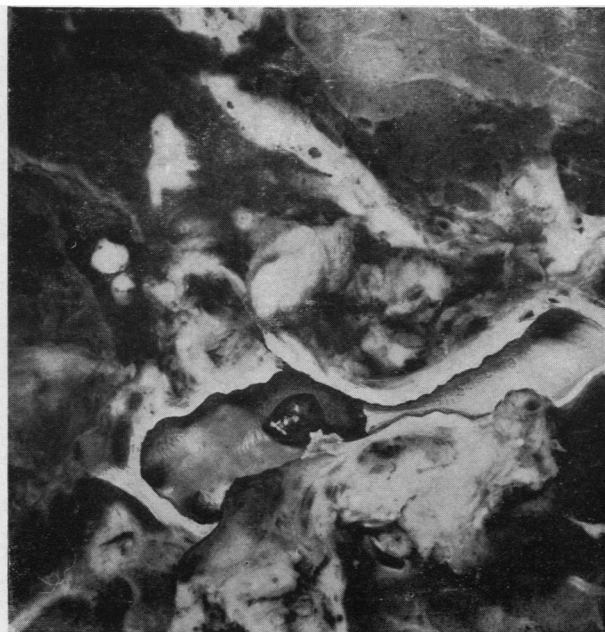

(b)

FIG. 20.—Bronchograms of Case 6 to show extensive bronchiectatic abscess cavity formation in all three lobes.



(a)



(b)

FIG. 21.—Photograph of specimen from Case 6; in 21a can be seen two groups of pneumoliths lying in cavities in the right upper lobe. In 21b the middle lobe bronchus is seen to end abruptly in an abscess cavity containing a dark, irregular pneumolith.

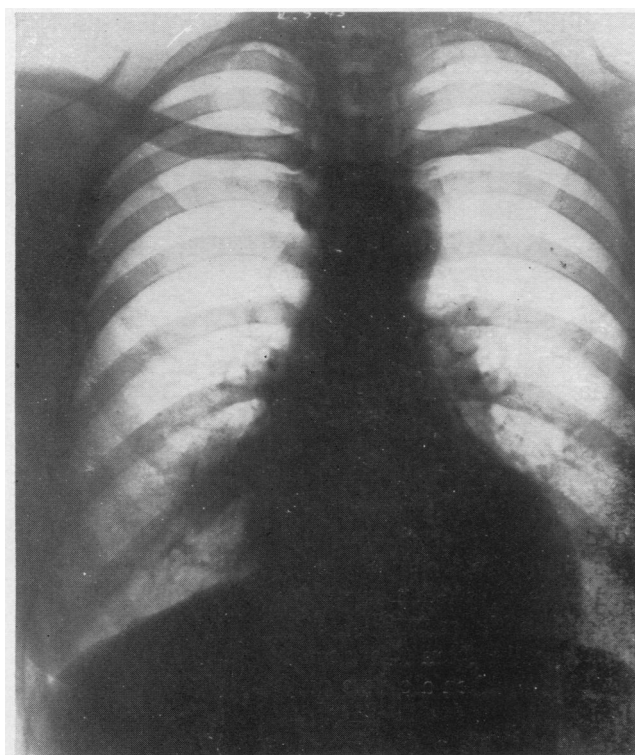
The simulation of bronchial carcinoma is perhaps the most important feature of this post-tuberculous middle lobe syndrome. The late age of acute onset of symptoms has already been mentioned. The incidence is greatest in the fifth decade (18 of 60 patients), and more than half of the patients in this series (34 of 60) were over 40 years of age; 16 were over 50 years of age. The occurrence of a minor or major febrile illness in a patient of this age, associated with haemoptysis or blood-staining of the sputum, as occurred in 31 of the 60 cases, and accompanied by the radiological demonstration of an opacity spreading out from the hilar opacity must inevitably give rise to a presumptive diagnosis of bronchial carcinoma. By far the majority of the 60 cases in my series were referred to me with a presumptive diagnosis of bronchial carcinoma. There can be no question of the very great importance of the recognition of this post-tuberculous middle lobe syndrome in the differential diagnosis of bronchial carcinoma. That the condition has hitherto been virtually completely overlooked and unrecognized may be seen at once from the fact that it is just not mentioned in the present-day accounts of the differential diagnosis of bronchial carcinoma. Once more it must be emphasized that if the first fundamental of sound diagnosis is applied, namely localization of the *exact* anatomical site of the lesion, suspicion is bound to be aroused if the localization is found to be in the middle lobe; the recognition of an adjacent calcified primary complex should further strengthen the supposition that a post-tuberculous syndrome is present.

A word of warning is necessary about occasional cases of bronchial carcinoma in which the mediastinal lymphatic glands are predominantly involved; the middle lobe bronchus is still vulnerable to pressure from the enlarged glands even though they are malignant, and consequently the obstructed middle lobe will show radiologically. The significant feature in differential diagnosis will then be the presence of a mediastinal mass; also a calcified primary complex should not be present.

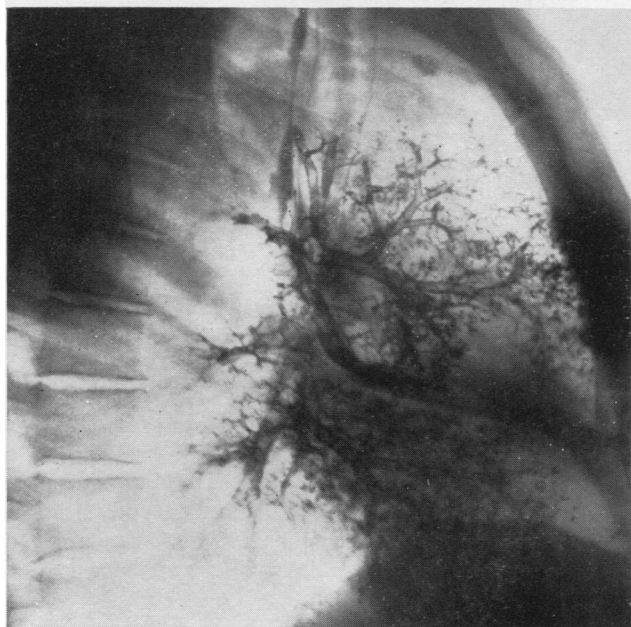
So much has already been said about the course and recognition of the condition that there is no need for further elaboration. The only feature that needs emphasis is the frequency of haemoptysis, a symptom of such ill-omen in a middle-aged patient with a radiating "hilar" opacity that it is liable to lend great support to a diagnosis of carcinoma; it is a frequent symptom in the post-tuberculous syndrome, probably due to the associated bronchiectasis, although in the more severe examples broncholiths or pneumoliths may be the cause.

It would also be possible to cite cases almost *ad nauseam* in which a wrong diagnosis of carcinoma had been made. One more alone should suffice.

Case 7.—Sister B. aged 41, a nursing sister in charge of a ward devoted to chronic pulmonary tuberculosis, suffered, in 1943, an acute febrile attack associated with a pain in the right chest and haemoptysis; radiographs showed an irregular opacity extending from the lower part of the right hilum (Fig. 22a). I was asked to see her as a probable case of bronchial carcinoma, although the nature of her work also introduced the possibility of active pulmonary tuberculosis. Examination of the radiographs disclosed that the opacity was undoubtedly due to a shrunken fibroid middle lobe. Not only was there a calcified primary complex but a densely calcified gland could be detected in the most central portion of the middle lobe shadow almost concealed



(a)



(b)

FIG. 22.—Radiographs from Case 7 to show a typical contracted, bronchiectatic middle lobe. In 22a a large densely calcified gland is virtually in the lobar opacity. In 22b the patency of the middle lobe stem bronchus is shown.

by the opacity of the lobe. A search was made for her chest radiographs done several years before when she was in training; exactly the same radiographic opacity was present then. A confident diagnosis of post-tuberculous bronchiectasis and fibrosis was made; bronchoscopy revealed a normal middle lobe bronchus, and a bronchogram confirmed the presence of a shrunk bronchiectatic lobe (Fig. 22b). This patient has been observed for several years since and her only symptom is a slight productive cough; the radiographic picture persists. Attention was drawn to the condition only because of the superimposition of a transitory respiratory infection which disclosed this *locus minoris resistentiae*.

That indeed is in great part the common factor in most of these cases. The condition, a silent one of many years' standing, reveals its presence when, as a result of an incidental catarrhal infection, some symptom, especially blood-spitting, causes a chest radiograph to be made. Although this infection may develop into one of acute intensity, or may smoulder on with recurrent exacerbations, as often as not it dies down again and gives no further symptoms, at any rate for some years.

TREATMENT

From what has just been said it is clear that in many cases no radical treatment is needed and that our main task lies in recognizing the probable nature of the condition and in taking steps to complete the diagnosis. The patient can be reassured, but instructed to continue under regular observation. The temporary, even transitory, nature of the illness often contraindicates operation, especially when it is appreciated that the underlying condition of a bronchiectatic, partly fibrous, lobe has been present for 20, 30, 40, 50, or even more years before a relatively minor inflammatory episode has drawn attention to it. Moreover, many of these patients are of a type unsuitable for major thoracic surgery. Some of the women, for instance, are obese in addition to being elderly. Age in itself is not necessarily a contraindication to radical operation, as will be seen from Cases 4 and 6; Case 6, that of a woman aged 59, needed pneumonectomy which was done with complete success; Case 4, a man aged 60, was not submitted to radical operation and lost his life.

From experience with the earlier cases, in which the chief problem was one of differential diagnosis and recognition of what was a comparatively mild inflammatory episode in a very old damaged part of the lung, I formed the opinion that the treatment of these cases should be essentially conservative. Fuller experience of more cases has caused revision of this conception; in quite a number the condition is, or becomes, sufficiently serious to demand radical treatment. This will have become evident already from the account of the various case histories described. It is particularly so when a severe acute infection has occurred or chronicity has supervened.

The most important feature in making a decision in regard to operation is consideration of the morbid anatomical changes present in the lobe. In this connexion one has to look for evidence of gross bronchial obstruction, or of irreversible secondary changes such as chronic cavitation; the presence of broncholiths or pneumoliths is of especial importance, and if their presence can be established for certain then operation is imperative.

BRONCHOLITHS AND PNEUMOLITHS

Evidence of broncholiths or pneumoliths is provided if they are coughed up or if they are demonstrated radiologically by a change in position of the opacities in successive radiographs (e.g., Case 6, Fig. 18). In some cases in which the stones lie loose in a relatively large cavity changes in position may be demonstrated by taking radiographs with the patient in different positions. One patient (a young man aged 22) with an acute suppurative pneumonitis and empyema had some hilar calcification, but the gross opacity from the infection concealed most of the finer detail in the lower part of the right lung. At bronchoscopy he coughed so violently and produced such large quantities of pus that it was not possible to make a full examination, nor to take a proper biopsy in spite of the fact that bleeding granulation tissue could be seen. The bronchoscope was withdrawn and he was told to cough into a kidney dish; he produced 2-3 oz. of thick, blood-stained pus. Since on other occasions I have been able to find large fragments of tuberculous granulation tissue in such cases the pus was

examined carefully and two quite large pneumoliths were found. Unless these had been sought for in this way they would have passed unnoticed and a very valuable guide to diagnosis and treatment would have been missed.

BRONCHIAL OBSTRUCTION

Bronchial obstruction, either total or subtotal, is a strong and often an absolute indication for operation. The whole middle lobe bronchus may be affected or only one of its divisions, more commonly the lateral one. The presence of obstruction is usually indicated clinically by a severe pyrexial illness, perhaps complicated by an empyema or by recurrent pyrexial attacks. Delay in resolution is also suggestive, especially when the lobe is consolidated and retains its full size as opposed to being small and contracted.

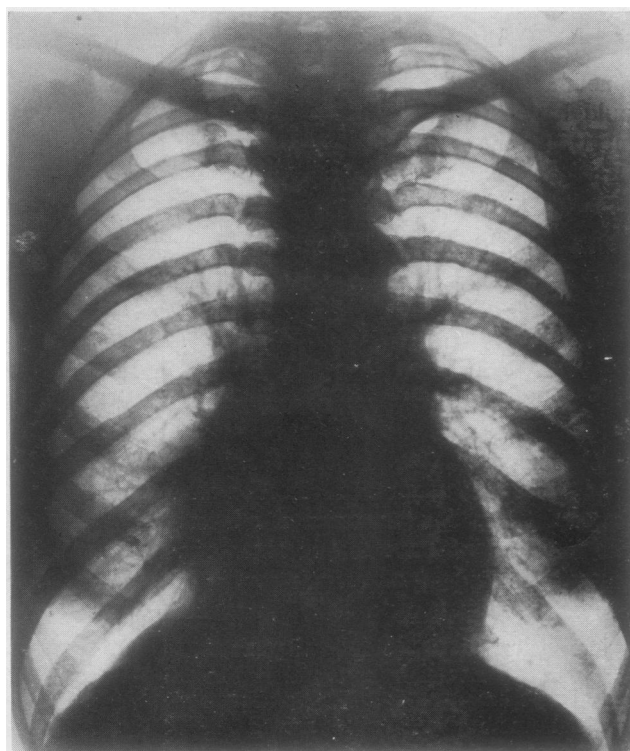
The final demonstration of obstruction is usually afforded by bronchography. Bronchoscopy is rarely directly informative; when the main stem is affected it is usually at a distance of 1 cm.–1.5 cm. beyond its origin, just beyond the usual range of adequate vision in a bronchus whose direction is often altered; obstruction of the lateral division can only very exceptionally be recognized bronchoscopically. Bronchograms demonstrating obstruction are to be seen in Figs. 6, 7, 8, and 23*b*.

The importance of obstruction is well demonstrated in the following case.

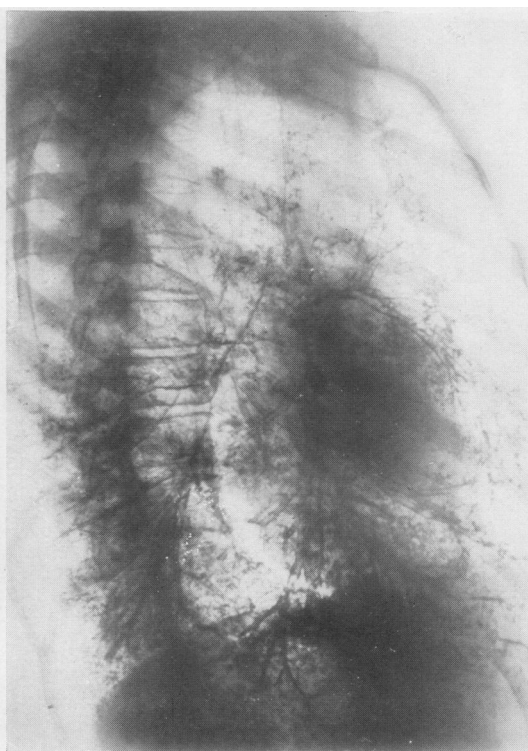
Case 8.—Mrs. E. S., aged 49, stated she had always had trouble with her chest since she was told at hospital as a child that her chest was weak. Up to the age of 14 she was in various convalescent homes on three occasions for an unproductive cough. Radiographs two and a half years ago were said to have shown "pneumonia." She now complained of general ill-health, pains in the lower front part of the right chest, aches and pains in various joints, and also occasional slightly productive cough, although she usually had but little cough and no sputum. Radiographs revealed a shrunken opaque middle lobe and a typical calcified primary complex (Fig. 23*a*). Bronchoscopy revealed a stricture of the middle lobe bronchus 1 cm. from its origin, and a bronchogram confirmed a typical cone-shaped block of the middle lobe stem at this site (Fig. 23*b*). In view of the rather vague nature of the symptoms, and also taking into account that she had recently lost her husband and had many worries that might account for a great part of them, it was decided not to advise operation in spite of this bronchial obstruction. As her symptoms persisted operation was advised after some 12 months of observation. The middle lobe was found to be densely adherent and its substance was tense and fluctuant, closely resembling a fibrous, contracted, obstructed gall-bladder. This resemblance was carried even further by the dense calcified material around its central attachments. The vessels were dissected only with the greatest difficulty, and it was quite impossible to define the stem bronchus clearly; the bronchus was cut across at the level of the stenosis, and some 20 ml. of thick pus escaped from the obstructed distended lobe.

As can be seen from the photograph and radiograph of the specimen (Fig. 24*a* and *b*) the two divisions of the middle lobe bronchus were grossly distended to form two large pyoceles or bronchiectatic abscesses; the calcification just outside the origin of the lateral branch is well shown.

It is clear that this obstructed lobe constituted a grave menace to the patient. Fortunately it had given rise to no more than the vague symptoms of poor general health and local and arthritic pains; presumably the infective element was low. It

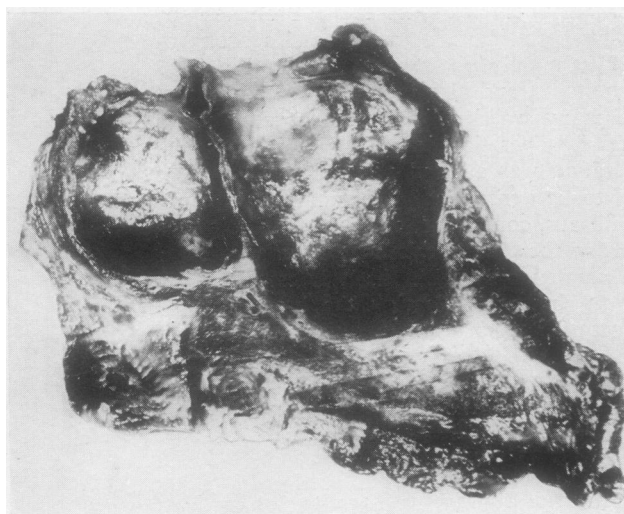


(a)

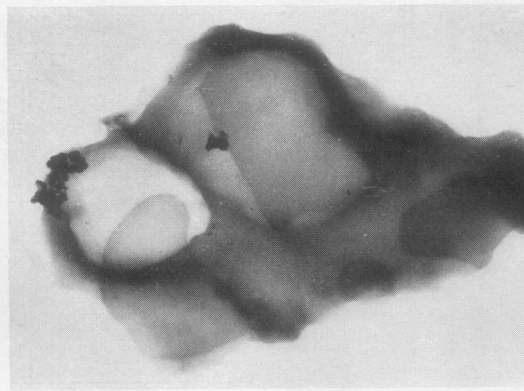


(b)

FIG. 23.—Radiographs from Case 8; a dense opacity projects from the lower part of the hilum and might readily be mistaken for a growth. A calcified lung focus is visible. The bronchogram (23b) shows complete block of the middle lobe bronchus just beyond its origin.



(a)



(b)

FIG. 24.—Photograph and radiograph of specimen from Case 8. The two grossly dilated cystlike spaces formed by the obstructed medial and lateral branches are to be seen: in the fresh state they were full of thick pus. Calcification is well shown in the radiograph.

was, however, almost like an unexploded bomb ; at any time it might have flared up into an intensely active acute inflammatory process. With its proximal bronchial drainage completely obstructed it must have ruptured into the pleura and have caused a grave, possibly fatal, illness. It would, for instance, be easy to understand the onset of a progressive cutaneous gangrene as occurred in Case 4.

This is an important case and illustrates well the significance that must be attached to bronchial obstruction and the need for treating it by radical operation, whatever the age of the patient, if serious complications are to be avoided.

CHRONIC ABSCESS FORMATION. ESTABLISHED INFECTED BRONCHIECTASIS

The demonstration of definite abscess cavity formation should indicate the need for operation ; at times the cavitation may be concealed in a featureless opacity (e.g., the last case or Case 5), but its presence may be inferred if feverish attacks occur and if purulent sputum is produced ; a block demonstrated bronchographically will be strong confirmation. The danger in these cases lies in the risk of spill-over infection and also of meta-static suppuration, especially cerebral abscess.

The presence of bronchiectasis alone, demonstrated bronchographically and with minimal and occasional or transient symptoms, presents no strong case for operation if there is no evidence of bronchial obstruction (e.g., Fig. 22). On the other hand, if suppuration is established within the dilated bronchi and there is a cough productive of purulent sputum (e.g., Fig. 5), then lobectomy is indicated just as in any other case of established infected bronchiectasis (see also specimens in Fig. 3). The need for taking into account the evidence of infection as well as anatomical bronchiectatic changes is seen from the case shown in Fig. 25. This patient was described in an article written in 1937 (Brock, Cann, and Dickinson, 1937), and the absence of symptoms commented upon ; the patient is now aged 29, is married and has two children, and is still virtually without symptoms.

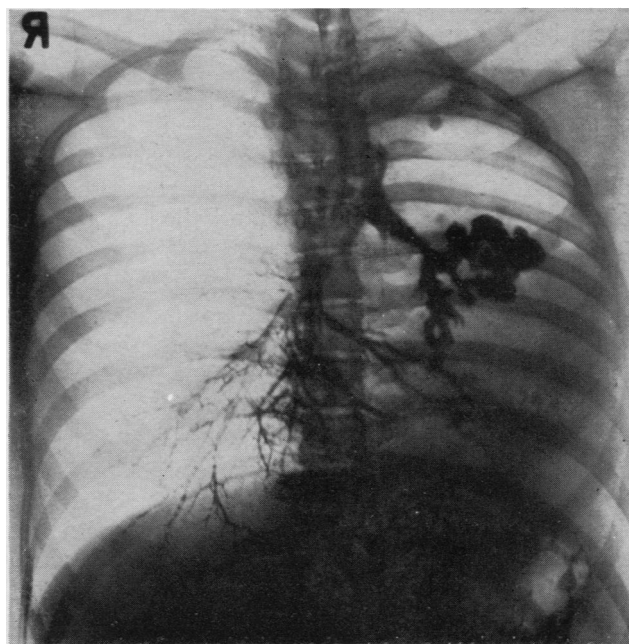


FIG. 25.—Bronchogram to show stricture of the left main bronchus and gross bronchiectasis of the small shrunk left lung; note the calcified focus in the left upper lobe. The patient has been observed since 1937 and has only trivial symptoms.

THE OPERATION

Operation may be extremely difficult technically owing to the dense fibrosis and calcification that may be found in and around the hilar structures in addition to the dense vascular adhesions that may surround the lobe itself. When it is remembered that the original causal process was one of severe caseating lymphadenitis, often with cold abscess formation, with intrabronchial rupture and with subsequent calcification it is not surprising that all normal fascial planes and anatomical arrangements are found at operation to be obliterated or grossly distorted. The dissection of the middle lobe hilar structures may be so difficult or indeed so nearly impossible that sacrifice of the lower lobe may be necessary; I have had to do this on two occasions. Indeed if the dissection is continued severe haemorrhage may suddenly occur, uncontrollable by any local effort. It may be possible to regain control by securing the lobar artery higher up above the middle lobe bronchus (thus inevitably sacrificing the lower lobe), or it may even be necessary to ligate the main right pulmonary artery, thus making pneumonectomy inevitable.

If difficulty is met with, even if it is decided to sacrifice the lower lobe as well, it is a sound plan to dissect out the main artery to the lung and place a controlling tape around it. If severe haemorrhage then occurs when the lower dissection is resumed it can be instantly controlled, and one stands a fair chance of being able to clear and control the damaged vessel; to do so in a torrent of blood may be impossible.

From these remarks it should be clear that it is unwise surgery to make a small thoracotomy incision just because one is removing only a small portion of lung. A full thoracotomy is needed so that one can gain complete control of the hilar structures without any hindrance.

Finally, the need must be stressed for some form of bronchial occlusion during anaesthesia to guard against spill-over flooding of the lungs. Even if the patient has no cough or sputum this should still be insisted upon, because much pus may be pent up behind a pin-hole stricture, and this is inevitably squeezed out during the manipulations of the adherent lobe. Even though one aims to dissect and clamp the bronchus as a first step, the local conditions may make this quite impossible until much manipulation and squeezing of the lobe has occurred. Even if the method of bronchial occlusion used may also include occlusion of the lower lobe this is less serious than risking infection or flooding of the other lung; in any case, as already mentioned, it may prove necessary, in a difficult case, to remove the lower lobe as well.

OPERATION FIGURES AND RESULTS

The need for or inevitability of operation in the post-tuberculous middle lobe syndrome is shown by the number of operations necessary in this series of 60 cases.

Operation was necessary in 17 patients and one more is awaiting lobectomy; including the patient awaiting operation the incidence is 30%.

The operations performed are shown in Table III.

TABLE III
OPERATIONS PERFORMED ON CASES OF MIDDLE LOBE SYNDROMES

Middle lobectomy	8 (2 with cardiac segmental resection as well)
Middle and lower lobectomy	4
Pneumonectomy	1
Drainage of empyema	2
Drainage of lung abscess	1
Exploratory thoracotomy	1

Two of these patients died, both from cerebral abscess. In one (Case 4) an empyema was drained on both sides and the patient developed a cerebral abscess while awaiting lobectomy. The other (Case 3) died after external drainage of lung abscesses; if primary lobectomy had been performed his life might have been saved.

Another patient, who developed a severe abscess of his middle lobe with secondary suppuration in his right lower lobe, was treated by primary middle and lower lobectomy with a good result.

In one case, that of a girl aged 20 in whom middle and lower lobectomy was performed by tourniquet technique in 1941, tuberculous empyema with a bronchial fistula followed operation, and this needed treatment for several years.

In eight patients lobectomy (either middle, five cases, or middle and lower, three cases) was needed for symptoms essentially those of bronchiectasis. In two of the middle lobectomies resection of the cardiac segment was needed as well.

The final result in all those patients who have recovered from operation is good.

REFERENCES

- Brock, R. C. (1943). *Guy's Hosp. Rep.*, **92**, 82.
 — (1946). *Anatomy of the Bronchial Tree*. London.
 — (1947). *Guy's Hosp. Rep.*, **96**, 141.
 — Cann, R. J., and Dickinson, J. R. (1937). *Ibid.*, **87**, 295.
 Graham, E. A., Burford, T. H., and Mayer, J. H. (1948). *Postgrad. Med.*, **4**, 29.
 Richards, W. F. (1944). *Proc. R. Soc. Med.*, **37**, 589.
 Zdansky, E. (1946). *Wien. klin. Wschr.*, **58**, 197.