

## Case reports

# Spontaneous migration of totally implanted venous catheter systems from subclavian into jugular veins

D Roblin, J C Porter, R K Knight

### Abstract

**Two cases of migration of totally implanted catheter systems are described. The complication is potentially life threatening.**

(*Thorax* 1994;49:281-282)

Totally implanted catheter systems such as the Port-a-cath (Pharmacia Deltec Inc, USA) have many advantages<sup>1,2</sup> and are thought to reduce the risk of potentially fatal catheter migration associated with external venous catheter systems.<sup>3</sup> We, however, present two cases of catheter migration in these systems, and describe warning signs which must alert physicians.

### Case report 1

A 32 year old woman with cystic fibrosis required an indwelling venous catheter. In March 1990 a totally implanted catheter was inserted under local anaesthesia into the left subclavian vein. The subcutaneous reservoir

was surgically attached to the anterior abdominal wall and the catheter tip correctly positioned in the superior vena cava (fig 1). This system was used successfully and was regularly flushed with heparinised saline after her last course of antibiotics in May 1992.

In July 1992 she presented to her local hospital with a sore neck and fever. An infective exacerbation of cystic fibrosis was assumed and ceftazidime was given via the catheter. Her symptoms failed to improve and she was transferred to this hospital. On arrival she complained of fever, headache, and a sore neck but with no change in sputum production or respiratory function. In June 1992 she had suffered a minor flexion-extension injury of the neck in a car accident. On examination she was pyrexial, with phlebitis of the left external jugular vein and a tender enlarged left submandibular lymph node. Coarse crepitations heard over both upper lobes were a normal finding. The clinical diagnosis was catheter migration with secondary thrombophlebitis. A chest radiograph (fig 2) confirmed that the catheter had migrated from the superior vena cava into the left internal jugular vein, and was pointing cranially. Injection of contrast medium into the catheter showed no evidence of pericatheter thrombus, and repositioning was therefore attempted using a snare introduced through the right femoral vein and manipulated under radiographic guidance. Unfortunately three attempts at radiological repositioning failed and the catheter had to be surgically removed.

### Case report 2

A 16 year old girl with cystic fibrosis underwent insertion of an implanted catheter system in January 1991. The catheter was inserted via the right subclavian vein, with a reservoir on

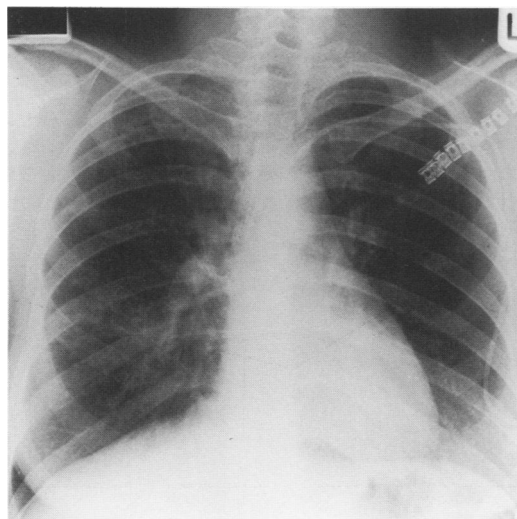


Figure 1 Chest radiograph from case no. 1 showing Port-a-cath tip in superior vena cava immediately after insertion.

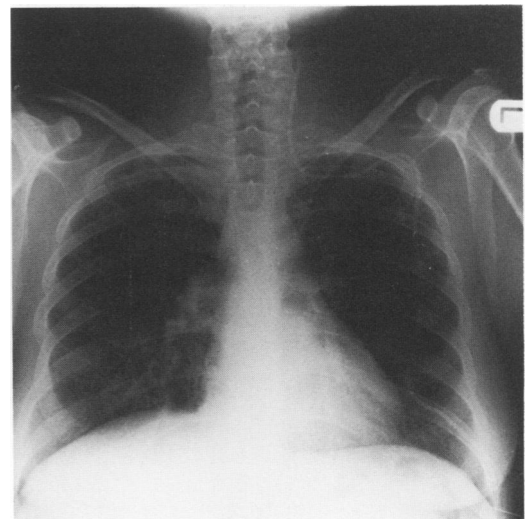


Figure 2 Chest radiograph from case no. 1 after migration into jugular vein.

Frimley Park  
Hospital, Portsmouth  
Road, Frimley,  
Camberley GU16 5UJ,  
UK

D Roblin  
J C Porter  
R K Knight

Reprint requests to:  
Dr D Roblin, 107  
Farningham Road,  
Caterham, Surrey CR3 6LN.

Received 9 February 1993  
Returned to authors  
23 March 1993  
Revised version received  
14 May 1993  
Accepted for publication  
25 May 1993

the anterior chest wall. A chest radiograph taken after insertion showed the catheter tip to be in the superior vena cava. Over the next few months two courses of antibiotics were successfully administered with this system. Patency was maintained with regular injections of heparinised saline.

In July 1992 she noticed increasing difficulty in flushing her catheter system and therefore attended the chest unit. On examination she was well, afebrile, and had scattered coarse crepitations on auscultation of the chest. Her concern that her catheter was partially blocked was confirmed and attempts to unblock it with urokinase were unsuccessful. The possibility of catheter migration was therefore considered. A chest radiograph showed the catheter tip in the right internal jugular vein pointing cranially. She declined radiological manipulation of the catheter, which was therefore removed under local anaesthesia.

### Discussion

We report two cases of migration of totally implanted catheter systems (Port-a-cath) in patients with cystic fibrosis. Although migration is uncommon, occurring in only two of 246 catheters implanted over a four year period at this hospital, it is potentially life threatening and all physicians should be aware of the possibility. This complication is well recognised with external catheters<sup>3</sup> but seldom described with totally implanted systems. A migrant catheter may provoke venous thrombosis, necrosis or even perforation and, if it remains patent, inadvertent cranial infusion of irritant drugs may cause neurological sequelae.<sup>4</sup>

In both cases migration occurred spontaneously, although the impact of a road traffic accident may have contributed in the first case. Both patients have cystic fibrosis and an essential part of treatment is regular, vigorous physiotherapy in the "tipped" head down position. This may encourage retrograde blood

flow and catheter migration into distended jugular veins, an effect augmented by repeated forceful coughing. In our experience, as patients become confident, they often administer intravenous therapy faster than recommended. A high flow rate at the catheter tip may produce a jet effect and displace the tip backwards and upwards.

If a catheter does migrate every attempt should be made to reposition the tip under radiographic guidance.<sup>5</sup> However, if unsuccessful the whole catheter system must be removed surgically. Before catheter manipulation or removal it is important to clear pericatheter thrombus with anticoagulants or thrombolytic agents (for example, urokinase) to avoid pulmonary emboli.

Totally implanted catheter systems have revolutionised the lives of patients with cystic fibrosis, allowing them to administer their own antibiotics intravenously at home or at work, and to take part in normal activities – even swimming – between courses of treatment. Their use is increasing dramatically as a result. Migration, although uncommon, may therefore be seen more frequently and it is essential that all physicians are aware of the possibility. A blocked catheter or symptoms suggestive of phlebitis or thrombosis of neck veins are indications for discontinuing intravenous therapy and urgent chest radiography. In addition, in our own unit we now recommend chest radiography before starting a new course of antibiotics if flushing the catheter has proved painful or difficult.

- 1 Ball AB, Duncan FR, Foster FJ, Davidson TI, Watkins RM, Hodson ME. Long term venous access using a totally implantable drug delivery system in patients with cystic fibrosis and bronchiectasis. *Respir Med* 1989;83:429–31.
- 2 Pegues D, Axelrod P, McClaren C, Eisenberg BL, Hoffman JP, Offery FD, *et al.* Comparison of infections in Hickman and implanted port catheters in adult solid tumour patients. *J Surg Oncol* 1992;49:156–62.
- 3 Dunbar RD, Mitchell R, Lavine M. Aberrant locations of central venous catheters. *Lancet* 1981;i:711–5.
- 4 Klein HO, Disegni E, Kaplinsky E. Unsuspected cerebral perfusion (a complication of the use of a central venous pressure catheter). *Chest* 1978;74:109–10.
- 5 Walker GT, Geller SC, Waltman AC, Malt RA, Athanasoulis CA. A simple technique for redirection of malpositioned Broviac or Hickman catheters. *Surg Gynecol Obstet* 1988;167:247–8.