

Investigation and management of pulmonary infiltrates following bone marrow transplantation: an eight year review

J H Campbell, N Blessing, A K Burnett, R D Stevenson

Abstract

Background—Although pulmonary infiltrates are common in bone marrow transplant recipients and add significantly to the morbidity and mortality of this group of patients, there is uncertainty as to the most appropriate investigation and a lack of information on the effects of investigations on management and outcome.

Methods—All bone marrow transplant recipients from one institution referred for respiratory investigation between 1982 and 1990 were reviewed.

Results—Of 204 bone marrow transplant recipients 27 developed pulmonary infiltrates which failed to respond to broad spectrum antibiotics. All were examined by bronchoscopy and bronchoalveolar lavage. A specific diagnosis was made in 20 cases, 17 with an infective cause and three with a non-infective aetiology. In 17 of the 27 episodes these investigations led to a positive change in treatment, but in only five did these changes result in patient survival beyond one month. Eighteen of the 20 deaths were due to progressive respiratory failure of an infective aetiology in 14 and non-infective in four.

Conclusions—Bronchoscopy and bronchoalveolar lavage are effective in establishing a diagnosis, but the impact on overall survival is disappointingly poor.

(Thorax 1993;48:1248-1251)

To address these uncertainties we have reviewed our experience in investigating pulmonary infiltrates in bone marrow transplant recipients over an eight year period; particular emphasis has been placed on the effect of invasive investigations on patient management and survival.

Methods

From January 1982 to December 1990 204 patients underwent bone marrow transplantation (110 allogeneic, 94 autologous) at our institution. Twenty seven patients (15 men, mean age 32 years, range 17-49) developed pulmonary infiltrates which failed to respond to broad spectrum antibiotics and required specialised respiratory investigation. The pre-transplantation haematological diagnoses are outlined in table 1. Treatment regimes used to induce remission varied. The preparative pretransplantation regime used was cyclophosphamide (60 mg/kg \times 2 intravenously) and total body irradiation (median dose 14 Gy, range 12-14.4) for those with haematological malignancies and cyclophosphamide alone for aplastic anaemia. Three patients received melphalan (130 mg/m²) instead of cyclophosphamide. The clinical details are summarised in table 2. Investigation of the respiratory incident included bacterial culture of blood, sputum, urine and throat swabs, and serological tests for virus, *Mycoplasma*, and *Legionella*. In each episode fiberoptic bronchoscopy and bronchoalveolar lavage were performed. All patients received supplemental oxygen and saturation was continuously monitored with pulse oximetry. Lavage was performed with warmed sterile saline (60-180 ml) instilled into a subsegmental bronchus. Thrombocytopenic patients (platelet count $<100 \times 10^9/l$) undergoing transbronchial

Department of
Respiratory Medicine
J H Campbell
R D Stevenson

Bone Marrow
Transplant Unit
N Blessing
A K Burnett

Glasgow Royal
Infirmary, Glasgow
G31 2ES

Reprint requests to:
Dr J H Campbell,
c/o M Floor Reception,
Royal Hallamshire Hospital,
Glossop Road,
Sheffield S10 2JF

Received 11 March 1993
Returned to authors
28 May 1993
Revised version received
25 August 1993
Accepted 31 August 1993

Pulmonary infiltrates developing in bone marrow transplant recipients continue to pose considerable problems in diagnosis and management, and add significantly to the morbidity and mortality in this group of patients.¹ Reports of several large series of bone marrow transplant programmes have led to the development of a timetable which predicts peak incidence of various infectious agents, dependent mainly on the stage of immunological reconstitution.²⁻⁶ This grading of relative risk has helped to rationalise the diagnostic approach to these difficult patients. Despite this, there is a lack of consensus on the most appropriate investigation and scant information on the effects of such investigations on patient management and its outcome.

Table 1 Pretransplantation haematological diagnoses

Diagnosis	Stage	No. of patients
Acute myeloid leukaemia	Remission	9
	Relapse	3
Acute lymphoblastic leukaemia	Remission	4
	Relapse	0
Chronic myeloid leukaemia	Chronic phase	6
Lymphoma	Remission	3
Aplastic anaemia	—	2

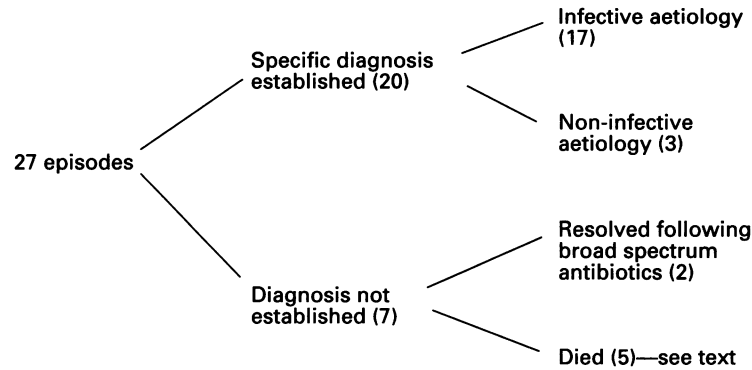
Thorax: first published as 10.1136/thx.48.12.1248 on 1 December 1993. Downloaded from http://thorax.bmj.com/ on April 9, 2024 by guest. Protected by copyright.

Table 2 Clinical presentation of pulmonary infiltrates in 27 patients following bone marrow transplantation

Clinical presentation	No. of patients
Cough	20 (74)
Breathlessness	12 (44)
Haemoptysis	4 (15)
Pleurisy	2 (7)
Weight loss	2 (7)
Fever	22 (81)
Arterial PO ₂ < 8 kPa (on air)	14 (52)
White cell count <0.5 × 10 ⁹ /l	11 (41)
Platelet count <50 × 10 ⁹ /l	16 (59)
Chest radiographic pattern	
Diffuse	19 (70)
Localised	8 (30)

Values in parentheses are percentages.

lung biopsies were given platelet cover, biopsies being performed under fluoroscopic control. All lavage samples were investigated with Gram and acid-fast stains and bacterial, mycobacterial and fungal cultures. The lavaged cells were examined cytologically and stained with Grocott's silver stain. For viral culture the fluid was inoculated into cultures of human lung embryo fibroblasts. From 1986 onwards samples were examined by a direct fluorescent antibody test with monoclonal antibodies to *Legionella pneumophila* and *Pneumocystis carinii*.



Causes of pulmonary infiltrates in 27 patients following bone marrow transplantation.

Table 3 Infective agents isolated from bronchoalveolar fluid

Organism(s)	Time from bone marrow transplantation (days)	Type of graft	No.
Mixed:			
<i>Pseudomonas</i>	224	Allogeneic	1
+ parainfluenza 111			
<i>Acinetobacter</i>	168	Allogeneic	1
+ parainfluenza 111			
<i>Aspergillus</i>	84	Allogeneic	1
+ parainfluenza 111			
<i>Aspergillus</i>	112	Allogeneic	1
+ <i>Staphylococcus</i>			
Viral:			
Cytomegalovirus	37;188	Allogeneic	2
Parainfluenza 111	14;140	Allogeneic	2
Influenza B	42	Autologous	1
Herpes simplex	14	Autologous	1
Fungi:			
<i>Aspergillus fumigatus</i>	82	Allogeneic	1
<i>Candida albicans</i>	7	Autologous	1
Bacteria:			
<i>Klebsiella</i>	280	Autologous	1
<i>Pseudomonas aeruginosa</i>	280	Allogeneic	1
<i>Haemophilus influenzae</i>	114	Autologous	1
<i>Legionella pneumophila</i>	7	Allogeneic	1
<i>Pneumocystis carinii</i>	120	Allogeneic	1

Results
A specific diagnosis was made in 20 of the 27 episodes investigated (figure). Fibreoptic bronchoscopy with bronchoalveolar lavage was the principal technique by which a diagnosis was made. Transbronchial lung biopsy was performed in four cases in the early years, but added little to the diagnostic yield and is no longer used routinely.

No diagnosis was made in seven episodes, two of which resolved after further courses of broad spectrum antibiotics and a presumptive diagnosis of treated bacterial infection was made. The remaining five cases died without a diagnosis. Four underwent a necropsy which showed that one died from a massive gastrointestinal haemorrhage secondary to peptic ulcer, post mortem examination revealing resolving pneumonia, two had non-specific interstitial pneumonitis, and one patient had disseminated candidiasis including lung involvement. In one case necropsy was refused.

INFECTIVE AGENTS ISOLATED
Infection accounted for 18 of the 27 episodes (67%), 17 of these being correctly identified before death (table 3). Viral agents, particularly parainfluenza 111 virus were the commonest pathogens isolated. Two patients had combined parainfluenza viral and Gram negative bacterial pneumonia. Cytomegalovirus pneumonitis was identified in only two cases. *Aspergillus* was the commonest fungus isolated (four of six episodes). In three episodes aspergillus infection was associated with another organism—*Pneumocystis carinii* (one), parainfluenza 111 (one), *Staphylococcus aureus* (one)—all three patients had chronic graft versus host disease. In the three episodes of aspergillus pneumonitis diagnosed before death, examination of bronchoalveolar lavage fluid revealed aspergillus hyphae and culture was positive. In two cases bronchoscopy revealed characteristic widespread tracheal and endobronchial ulcers, biopsies of which confirmed invasive aspergillosis and in one of these bronchoscopy was used to assess response and guide the duration of treatment. The radiographic pattern was not specific for any given aetiology but a focal infiltrate was more common in bacterial pneumonia (four of six episodes) than either viral (one of six) or fungal (one of four) cases.

Overall, four of the 17 infective episodes responded to specific treatment (defined as resolution of radiographic changes combined with a patient being discharged home and surviving at least six months). Of the remaining 13 the median duration of survival from the time of bronchoscopy was 18 days (range 3–74).

NON-INFECTIVE AETIOLOGY
This accounted for five of the 27 (19%) episodes, three of which were correctly identified before death. These were cytotoxic drug (busulphan) induced pneumonitis (one), pulmonary alveolar haemorrhage (one), and obliterative bronchiolitis plus non-specific

fibrosis (one). Cytotoxic drug induced pneumonitis and obliterative bronchiolitis were diagnosed from transbronchial lung biopsy specimens; both these patients subsequently died of progressive respiratory failure. The patient with drug induced pneumonitis recovered with steroids. The two undiagnosed cases died, and necropsies revealed non-specific interstitial pneumonitis.

COMPLICATIONS

There were no life threatening complications related to bronchoscopy and allied procedures. Three patients developed a pneumothorax following transbronchial lung biopsy, but all resolved without intervention.

EFFECT ON MANAGEMENT

In 17 of the 27 episodes (63%) these investigations led directly to a positive change in treatment as follows: steroid treatment (one); significant change in antibiotic regime (12); interferon therapy (two); cytomegalovirus immunoglobulin (two). In a further four cases the absence of a specific pathogen from the bronchoalveolar lavage was accepted as excluding serious opportunistic infection and escalation of the antibiotic regime was avoided; this decision was borne out by the subsequent favourable outcome in these patients. However, in only five of the 27 did these changes in treatment result in the patient surviving beyond one month. This correlated with the high mortality for this group as a whole.

Discussion

The investigation and management of pulmonary infiltrates in a group of autologous and allogeneic bone marrow transplant recipients is described. Bronchoscopy and bronchoalveolar lavage provided the diagnosis in 20 of the 27 episodes investigated—a diagnostic rate of 74% which is similar to other reported series.⁷ Infection was the major aetiological factor, accounting for 67% of cases, but the pattern of infectious agents differed from other series in several important aspects. Previous studies have cited cytomegalovirus as the most common pathogen isolated, accounting for 40–56% of infective cases with a high associated mortality.^{3–9} In contrast, although we found viral agents to be the commonest organism isolated (primary agents six, mixed infection three) cytomegalovirus pneumonia was diagnosed in only two cases. All except one of our fatal cases was subjected to necropsy and, in view of the severity of cytomegalovirus infection in bone marrow transplantation recipients, it is unlikely that patients not receiving specific treatment would improve spontaneously. *Pneumocystis carinii* pneumonia was also less common than previously documented. These differences probably reflect changing practices in transplant programmes, in particular the use of cytomegalovirus negative products and prophylactic Septrin.¹⁰ Fungal pneumonitis remains a problem despite the use of laminar airflow and prophylactic antibiotics.

Although identified by bronchoalveolar lavage in four cases, fungal infection accounted for the two undiagnosed infections in this series. One patient developed aspergillus pneumonia as a preterminal event superimposed on treated *Pneumocystis carinii* pneumonia. In two cases we were particularly impressed by the widespread involvement of the tracheo-bronchial tree by aspergillus infection; one of these patients survived the episode and bronchoscopy proved valuable in the assessment of the response to amphotericin and was used to guide the duration of treatment.

The role of lung biopsy in identifying the cause of pulmonary infiltrates in immunocompromised patients remains controversial. Confusion has arisen from the reporting of immunocompromised patients with various underlying diseases, often with very different predispositions, the yield from invasive investigations being influenced by selection of patients and the spectrum of underlying disease. We have previously shown the importance of transbronchial lung biopsy in diagnosing pulmonary infiltrates in patients with lymphoma and others have reported the benefits of open lung biopsy in bone marrow transplantation recipients.^{11,12} Robin *et al* make the point that, if patient survival is used as the outcome measure, few, if any, of the published series show a clear benefit from lung biopsy.¹³ The high incidence of profound thrombocytopenia following bone marrow transplantation makes transbronchial lung biopsy particularly difficult in this group and it was performed on only four cases in our series. Although it added little additional information to bronchoalveolar lavage, there are insufficient data to draw any firm conclusions from our findings. Lavage alone is unlikely to establish a non-infective diagnosis, so it seems reasonable to consider lung biopsy as a secondary procedure in patients with negative lavage who continue to deteriorate.

In this group of bone marrow transplant recipients pulmonary investigations significantly influenced subsequent management with a positive change in treatment being instituted in 17 of 27 episodes. However, the overall outcome of this group was very disappointing and in only five cases did these changes in treatment result in patient survival beyond one month. This poor overall outcome reflects the severity of illness in the group as a whole. All patients had abnormal chest radiographs on presentation and over half were critically ill with respiratory failure. Others have echoed the low survival once respiratory failure is established, and Milburn *et al*⁷ stressed the importance of considering bronchoscopy and bronchoalveolar lavage in symptomatic patients with normal chest radiographs. Whether earlier investigation and treatment in our group would have materially altered the outcome is not known.

Bronchoscopy and bronchoalveolar lavage are effective in establishing the cause of pulmonary infiltrates in bone marrow transplant recipients, but their impact on overall survival remains disappointingly poor.

- 1 Editorial. Lung disease following allogeneic marrow transplantation. *Lancet* 1989;ii:1368-9.
- 2 Winston DJ, Gale RP, Meyer DV, Young LS. Infectious complications of human bone marrow transplantation. *Medicine* 1979;58:1-31.
- 3 Krowtc MJ, Rosenow EC, Hoagland C. Pulmonary complications of bone marrow transplantation. *Chest* 1985;87:237-46.
- 4 Weiner RS, Bortin MM, Gale RP, Gluckman E, Key HEM, Kolb HJ, *et al.* Interstitial pneumonitis after bone marrow transplantation: assessment of risk factors. *Ann Intern Med* 1986;104:168-75.
- 5 Lum L. The kinetics of immune reconstitution after human marrow transplantation. *Blood* 1987;69:369-80.
- 6 Wingard JR, Mellits ED, Sostrin MB, Chen DYH, Burns WA, Sintas GW, *et al.* Interstitial pneumonitis after allogeneic bone marrow transplantation. *Medicine* 1988;67:175-86.
- 7 Milburn HJ, Prentice HG, Dubois RM. Role of bronchoalveolar lavage in the evaluation of interstitial pneumonitis in recipients of bone marrow transplants. *Thorax* 1987;42:766-72.
- 8 Neiman PE, Reeves W, Ray G, Flournoy N, Lerner KG, Sale GE, *et al.* A prospective analysis of interstitial pneumonia and opportunistic viral infection among recipients of allogeneic bone marrow grafts. *J Infect Dis* 1977;136:754-67.
- 9 Meyers JD, Flournoy W, Thomas ED. Non bacterial pneumonia after allogeneic marrow transplantation: review of ten year's experience. *Rev Infect Dis* 1982;4:1119-32.
- 10 Winston DJ, Ho WG, Gale RP, Champlin RE. Prophylaxis of infection in bone marrow transplants. *Eur J Cancer Clin Oncol* 1988;24:S15-S23.
- 11 Campbell JH, Raina V, Banham SW, Cunningham D, Soukop M. Pulmonary infiltrates—diagnostic problems in lymphoma. *Postgrad Med J* 1989;65:881-4.
- 12 Clark JG, Crawford SW. Diagnostic approaches to pulmonary complications of marrow transplantation. *Chest* 1987;91:477-9.
- 13 Robin D, Burke CM. Lung biopsy in immunosuppressed patients. *Chest* 1986;89:276-8.