

Q fever pneumonia presenting as an eosinophilic pleural effusion

P P MURPHY, S G RICHARDSON

From the Cardiac Unit, Belfast City Hospital, Belfast

ABSTRACT A patient with an eosinophilic pleural effusion due to Q fever is described.

Pleural fluid eosinophilia is associated with various disorders, including infection, neoplasia, and allergy. In a large proportion of cases the cause remains unknown. We report a case of Q fever presenting with an eosinophilic pleural effusion.

Case report

A 41 year old bricklayer gave a three month history of cough and left sided pleuritic chest pain, with night sweats and anorexia resulting in weight loss of 3.4 kg. He smoked 30 cigarettes a day. There was no history of asthma, allergy, or contact with animals.

A chest radiograph showed patchy consolidation in the left mid and upper zones. Pneumonia was diagnosed and a course of ampicillin prescribed, but no clinical improvement occurred. Co-trimoxazole was prescribed, again with no effect. A repeat chest radiograph after six weeks showed clear lung fields, but a left sided pleural effusion had developed (fig 1). He was referred for further investigation.

On admission his temperature was normal. The pleural effusion was tapped and biopsy specimens were obtained. The pleural fluid (850 ml) was straw coloured, with a protein content of 55 g/l and pH 7.45. On cytological examination the fluid contained about 70% eosinophils with no evidence of malignancy. Pleural biopsy specimens showed reactive changes only. Bacteriological examination of the fluid showed no organisms or acid fast bacilli and no growth on culture.

The white cell count was normal at $8.1 \times 10^9/l$ (46% neutrophils, 47% lymphocytes, 1% eosinophils). Liver function tests gave abnormal results, with increased γ glutamyl transpeptidase (165 U/l), alanine aminotransferase (56 U/l), and alkaline phosphatase (458 U/l). The bilirubin concentration was normal. Q fever antibody titres were raised at 1248, indicating recent infection. Other viral antibody titres were normal.

The patient was treated with a two week course of

tetracycline. On review three months later his clinical condition was much improved. There was no clinical or radiological evidence of a pleural effusion (fig 2) and liver function tests gave normal results. Q fever antibody titres remained raised at 1280 phase 2. Phase 1 titres had risen from 20 to 80. Both sets of titres, however, had returned to below 40 six months later, when he was discharged from follow up feeling well.

Discussion

Eosinophilic pleural effusion is poorly defined, the level of eosinophils necessary for the diagnosis varying from 5% to 20%.¹ The condition is probably underdiagnosed, with an incidence estimated to be from 1% to 8% of all pleural effusions.²

Pleural fluid eosinophilia has been reported in association

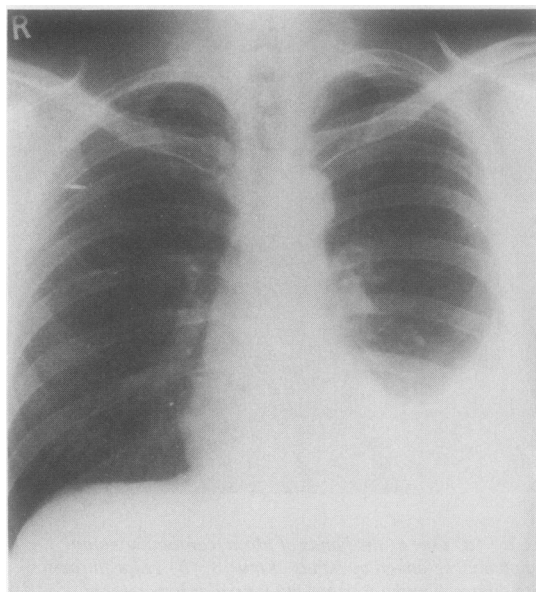


Fig 1 Chest radiograph at admission, showing left sided pleural effusion.

Address for reprint requests: Dr Philip Murphy, Cardiac Unit, Belfast City Hospital, Belfast BT9 7AB.

Accepted 2 December 1988

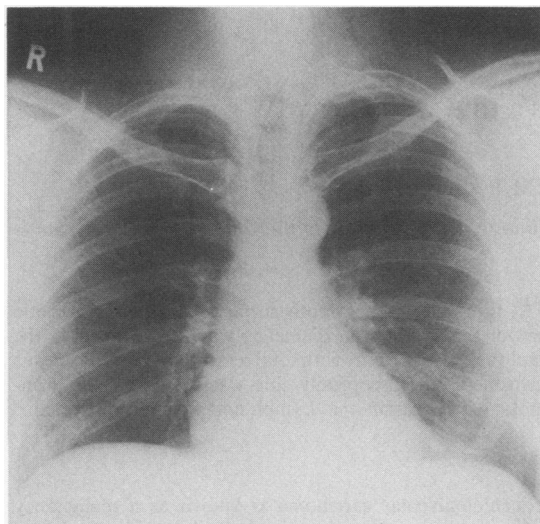


Fig 2 Chest radiograph three months later, showing resolution of the pleural effusion.

with a great variety of conditions. In a review of 343 reports published in English, 119 (35%) were classified as idiopathic, 95 (28%) as due to air in the pleural space (pneumothorax or

trauma), 39 (11%) as secondary to infection, and 27 (8%) as due to malignancy, with the remainder due to miscellaneous causes. The infectious causes were parapneumonic or tuberculous in most cases, with two cases described as "probably viral."³ Owing to its association with various disorders an eosinophilic pleural effusion has usually been considered a non-specific finding of little use in the differential diagnosis.³ It is usually associated with a favourable outcome of the underlying disease process.⁴

Eosinophilic pleural effusion in Q fever has been reported previously.⁵ In three cases of pleuropericardial lesions in association with Q fever two patients had a pericardial effusion and one a pleural effusion with 80% eosinophils.

References

- 1 Bower G. Eosinophilic pleural effusion. A condition with multiple causes. *Am Rev Respir Dis* 1967;**95**:746-51.
- 2 Hirsch A, Ruffie P, Nebut M, Bignon J, Chretien J. Pleural effusion: laboratory tests in 300 cases. *Thorax* 1979;**34**:106-12.
- 3 Adelman M, Albelda SM, Gottlieb J, Haponik EF. Diagnostic utility of pleural fluid eosinophilia. *Am J Med* 1984;**77**:915-20.
- 4 Pettersson T, Riska H. Diagnostic value of total and differential leukocyte counts in pleural effusions. *Acta Med Scand* 1981;**210**:129-35.
- 5 Caughey JE. Pleuropericardial lesion in Q fever. *Br Med J* 1977;*i*:1477.