

Rupture of the tracheobronchial tree

J C ROXBURGH

From the Department of Thoracic Surgery, Norfolk and Norwich Hospital, Norwich

ABSTRACT Eleven cases of tracheobronchial rupture are described. Nine were the result of external non-penetrating trauma and all but three had other serious injuries. The remaining two were caused by endobronchial intubation. Of the cases caused by external injury, respiratory tract injury was confined to the cervical trachea in three. Two required tracheostomy and repair and the third was managed conservatively; all made satisfactory recoveries. Intrathoracic rupture was recognised on or soon after admission in three cases. One patient died of uncontrollable pulmonary haemorrhage before he could be operated on; immediate repair gave good long term results in the other two. In three cases rupture of the main bronchus was not recognised until complete obstruction developed three, five, and 12 weeks after the accidents. The strictures were resected and the lung re-expanded. Robertshaw endobronchial tubes ruptured the left main bronchus in two patients undergoing oesophageal surgery. Uneventful recovery followed immediate repair. The difficulty of confirming rupture of a major airway is discussed and the importance of conserving the lung when the diagnosis has been missed is emphasised.

Rupture of the tracheobronchial tree, although described well over 100 years ago,¹ is a modern hazard. It is in the main associated with blunt trauma of the chest and is often an injury of high speed accidents. As the number of people travelling at high speed has increased so has the number of those sustaining injuries to the chest. Most patients with tracheobronchial ruptures will be seen in the accident and emergency departments of general hospitals and managed initially by general or orthopaedic surgeons or by neurosurgeons, depending on the extent of their associated injuries. The diagnosis of tracheobronchial rupture is not easy but failure to diagnose it may lead to death or long term disability. Once diagnosed it can be managed conservatively while a thoracic surgical opinion is sought. A good result can be expected.

Case histories

ACUTE INJURIES

1(a) Cervical

1 A 6 year old girl fell off her bicycle, sustained a blow to her neck, and soon afterwards coughed up a

little blood. Her voice was slightly altered. The only abnormality on physical examination was surgical emphysema around the neck and anterior chest wall. Bronchoscopy showed a 1.5 cm tear in the posterior wall of the trachea, 2 cm below the vocal cords. A tracheostomy was the only surgical intervention. Repeat bronchoscopy one week after that showed the tear was healing and she was extubated two weeks later. There have been no long term sequelae.

2 An 18 year old motorcyclist was admitted unconscious to the accident and emergency department after a road traffic accident in which he was "garrotted" by his haversack strap. There were extensive abrasions and surgical emphysema over the front of his neck. He was dyspnoeic but not cyanosed. The findings at the initial clinical examination were otherwise unremarkable. A chest radiograph showed a fracture of the right first rib and mediastinal emphysema. Bronchoscopy showed disruption of the trachea anteriorly and towards the right side. A temporary tracheostomy at the level of the third ring was the only treatment needed. He made an uneventful recovery.

3 A 30 year old man sustained multiple orthopaedic injuries in a light aeroplane crash. He was found unconscious but soon recovered consciousness. He had a compound fracture dislocation of his left ankle and a closed dislocation of his left hip. In addition there was bruising around a superficial laceration on the right side of his neck. His voice was hoarse. Exam-

Address for reprint requests: Department of Surgery, Middlesex Hospital, London W1N 8AA.

Accepted 4 March 1987

ination of his chest showed nothing remarkable. The dislocations were reduced under general anaesthesia without incident, and only at the end of the operation was it noticed that his neck had become swollen by surgical emphysema. Bronchoscopy then showed a circumferential tear of the left side of the trachea 1 cm below the vocal cords. A nasoendotracheal tube was used as a splint for one week. Three and a half years later his voice is a little husky as a result of the direct injury to the larynx but there has been no other disability.

1(b) Intrathoracic (blunt trauma)

4 A 16 year old stable lad fell from his horse and was kicked in the front of his chest. He rapidly became unrecognisable as a result of widespread surgical emphysema and on admission to hospital he was dyspnoeic and cyanosed. There were fractures of the 2nd-6th ribs on the right side with a large pneumothorax. After insertion of an intercostal tube 500 ml of fresh blood were drained from the chest and there was a brisk and persistent air leak. Bronchoscopy confirmed laceration of the trachea extending into the right main bronchus. At thoracotomy a large intrapulmonary haematoma associated with a laceration in the upper lobe was noted. There was a 3 cm tear in the membranous trachea running from above the origin of the left main bronchus obliquely across to join a semicircular tear between the first and second rings of the right main bronchus. The left main bronchus was selectively intubated, the laceration was repaired with interrupted sutures, and the suture line was protected with azygos vein and pleura. The patient made a rapid recovery and apart from minor problems with suture granulomas in the early months there were no complications. Thirteen years after the incident he remained well.

5 A 20 year old rider of a light motorcycle ran into the back of an unlit stationary lorry. On admission to the accident unit she was conscious, not shocked, and in no respiratory distress. She had a depressed frontal fracture of the skull, a fracture of the 4th thoracic vertebra with immediate paralysis, and a large right pneumothorax. There was no surgical emphysema. A chest drain was inserted and after this blood gas tensions were found to be normal. Her condition deteriorated two hours later and a very brisk air leak developed. A chest radiograph showed the right lung had failed to re-expand fully. Bronchoscopy confirmed that the bronchus was ruptured. At thoracotomy there was complete transection of the lower division of the right main bronchus, the tear extending spirally into the upper lobe bronchus. An upper lobectomy and a sleeve anastomosis (with interrupted 3/0 absorbable sutures) were performed. Apart from a tension pneumothorax on the left side, which devel-

Summary of cases of blunt tracheobronchial trauma

	Cervical	Intrathoracic	
	Acute	Acute	Chronic
Number	3	3	3
Age (y)	6-30	16-20	17-44
M:F	2:1	2:1	2:1
Surgical emphysema	3	2	3
Dyspnoea	1	2	2
Cyanosis	0	2	2
Other	2*		
Pneumothorax	0	3 (R2 B1)	3 (B)
Ribs	1	2	3 (B2)
Sternum	0	0	1
Major extrathoracic injury	2	1	3
Deaths	0	1 (2 h)	0

*Hoarse.

R—right; B—bilateral.

oped while she was still on intermittent positive pressure ventilation and which responded well to drainage, there were no short or long term respiratory sequelae.

6 A 20 year old man was admitted to the accident and emergency department after a motorcycle accident (he had been a pillion passenger). He was conscious, coughing blood continuously, deeply cyanosed and in great respiratory distress. There was considerable surgical emphysema. The blood pressure was 60/0 mm Hg. Chest radiographs showed a large left pneumothorax, a small right pneumothorax, and severe bilateral pulmonary contusions. Confirmation of the clinical diagnosis of tracheobronchial rupture by bronchoscopy was not possible owing to torrential intraluminal bleeding. Despite maximal cardiorespiratory support the patient died 2 hours after admission. At necropsy there was a complete rupture of the left main bronchus with deep lacerations of both lobes of the lung. The right lung was grossly contused.

1(c) Anaesthetic accidents

7 A 67 year old man underwent oesophago-gastrectomy for carcinoma of the cardia through a left thoracoabdominal incision. Later on the same day he was taken back to theatre for control of intraluminal bleeding from the stapled oesophago-gastric anastomosis. Periodically during this second operation the anaesthetist found it necessary to adjust the pressure in the bronchial cuff of the Robertshaw tube to maintain collapse of the lung. The handsewn reanastomosis was almost complete when the bronchial cuff was seen to be herniating through the back of the left main bronchus, and an intermittent air leak ensued. The patient was turned on to his back for a right endobronchial tube to be inserted, and after he had been repositioned exploration revealed a 2 cm slit in the membranous portion of the left main bronchus. The

Rupture of the tracheobronchial tree

was repaired with interrupted sutures and covered with a pericardial flap. The patient made an uneventful recovery.

8 A 78 year old woman with enormous achalasia was undergoing oesophagectomy through a right thoracotomy and had been intubated with a left Robertshaw tube. While the upper oesophagus was being mobilised surgical emphysema of the posterior mediastinum was noted. When the overlying pleura was incised an air leak developed, which became progressively larger. Exploration revealed that the membranous portion of the left main bronchus had been perforated by the tip of the Robertshaw tube. The tube was withdrawn slightly and the defect easily repaired with three interrupted sutures. The operation was completed without further incident and there were no long term sequelae.

CHRONIC INJURIES

Post-traumatic bronchial rupture

9 A 44 year old male moped rider was a victim of a road traffic accident and his left chest hit the kerb. When seen in the district general hospital he was dyspnoeic but not cyanosed and there was gross surgical emphysema over the anterior chest and neck. There was a large flail segment on the left side. A fracture of the base of the skull was diagnosed clinically. Chest radiographs confirmed multiple fractures of the left ribs and showed fractures of several right ribs. Bilateral pneumothoraces were present. Chest drains were inserted and a tracheostomy was performed for prolonged ventilation. Three weeks after the accident, with his lungs fully re-expanded and his rib fractures stabilising, he was transferred from the intensive care unit to a general surgical ward, where he continued to make slow progress. Two weeks later he complained of vague discomfort in the chest wall and soon afterwards he became dyspnoeic and cyanosed. A chest radiograph showed complete collapse of the right lung with mediastinal shift. He was referred for bronchoscopy, which showed the right main bronchus to be stenosed just below its origin. The stricture was resected and thick colourless mucus was sucked and expressed from the collapsed lung. The right main bronchus was reanastomosed with 3/0 non-absorbable sutures. The patient made an uneventful recovery, but later stuture granulomas necessitated bronchoscopic removal of two of the non-absorbable sutures. A perfusion lung scan one year after injury showed good function on the side of the bronchial anastomosis but only moderate function on the left, where the chest wall had been more severely damaged.

10 A 17 year old bicycle rider sustained severe crush injuries to his head and chest. On arrival in the accident and emergency department he was deeply unconscious and acutely hyperpnoeic. There was bruising

and gross surgical emphysema over the right chest and an obvious depressed fracture of the sternum. There was a large right sided pneumothorax and a smaller one on the left. Bilateral chest drains were inserted. He was admitted to a neurosurgical unit, where exploratory burr holes were made and bronchoscopy and tracheostomy were carried out. Although bleeding made examination difficult, bronchoscopy was reported as showing some oedema of both main bronchi but no evidence of rupture. Two weeks later the right lung had not fully expanded despite intensive treatment. He therefore had a repeat bronchoscopy and a stricture of the right main bronchus was identified. It was resected and an end to end anastomosis performed. Suture granulomas and a degree of renewed stenosis necessitated several bronchoscopies and bronchial dilatations during the first two years after operation but thereafter his respiratory tract remained satisfactory.

11 A 23 year old nurse had a road traffic accident in which she sustained very severe head injuries, fractures of the left clavicle, left 1st rib, right 1st and 2nd ribs, bilateral pneumothoraces, and a fracture of the shaft of the right femur. At the hospital to which she was admitted bilateral chest drains were inserted and when, 48 hours later, surgical emphysema had increased and she became hypoxic fibreoptic bronchoscopy was performed. The right main bronchus was reported to be oedematous but intact. She was transferred to the nearest cardiothoracic centre for management of her pulmonary complications; but her neurological condition was deteriorating, and with her respiratory function adequate she was moved to the regional neurosurgical centre in yet another hospital. After a brain scan she was kept under observation there and made slow but steady progress. Three weeks later with her head injury improving and both lungs fully expanded she was fit enough to be transferred to an orthopaedic unit near her home for continued management of her fractured femur.

While still an inpatient there she complained of vague chest symptoms and expiratory and inspiratory wheezes were audible. A radiograph showed only a little patchy consolidation of the lower lobe of the right lung (figure, *a*) and a chest physician prescribed bronchodilator treatment. Soon she was ambulant and able to be discharged to live with her parents. Three months after the original injury she was referred for emergency admission to the Norfolk and Norwich Hospital thoracic surgery unit. She was in considerable distress with chest pain and dyspnoea, both of sudden onset. A radiograph confirmed total collapse of the right lung with considerable mediastinal shift (figure, *b*) and bronchoscopy showed cicatricial occlusion of the right main bronchus. The patient underwent resection of the stricture with end to end

anastomosis of the bronchus, a large amount of clear mucus being expressed from the collapsed lung. Recovery was uneventful and six months later respiratory function tests, which included a flow-volume loop, gave results within normal limits.

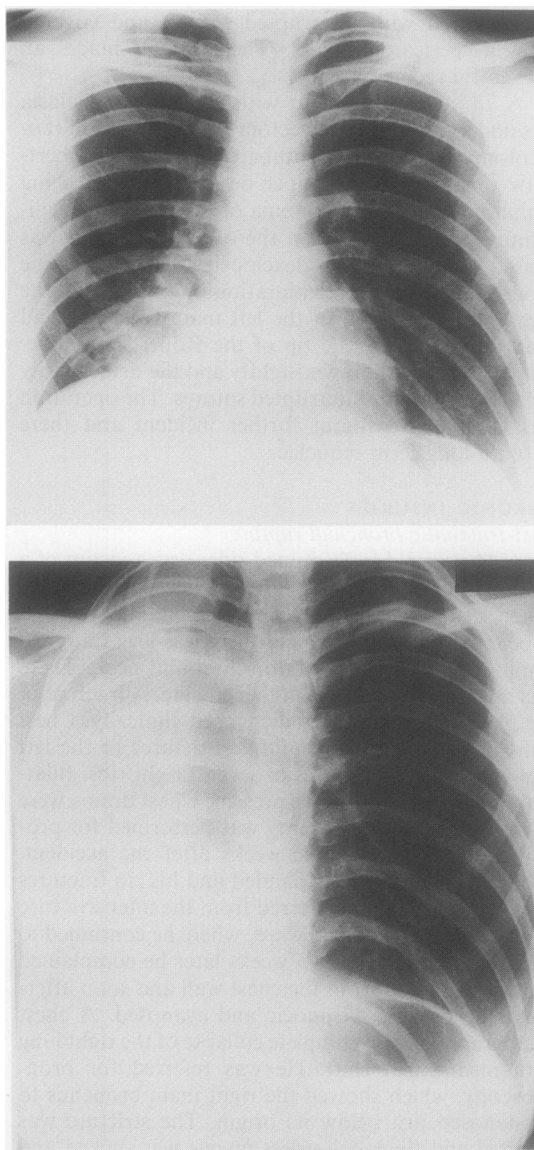
History

Rupture of the bronchus was first reported over 100 years ago. Webb¹ in 1848 reported the case of a man run over by a cart who died from a ruptured liver. At necropsy the left main bronchus was found to be ruptured. Winslow² in 1871 recorded the first example of survival from bronchial injury but the "patient" was a wild canvasback duck. A rupture of the left main bronchus had healed with development of a fibrous pouch. Nearly 60 years later the first human survivor was reported by Kritzinski³ His patient was a woman who had suffered severe right sided chest injuries at the age of 10 years. When she died from pulmonary tuberculosis at the age of 31, necropsy showed that the right main bronchus had been completely occluded and there was no evidence of tuberculosis on that side. The disease that killed her was confined to the left side.

The first attempt at surgical repair was made in 1913 by Hotz,⁴ who operated on a 2 year old girl with an acute tracheobronchial rupture. The girl had been run over by a wine wagon and sustained severe chest injuries. An emergency thoracotomy was performed as her condition deteriorated despite relief of her tension pneumothorax. At operation a rupture of the left main bronchus was repaired. The child died on the fourth postoperative day from fulminant sepsis. Thereafter the surgical management of the problems created by bronchial rupture aimed at relieving the symptoms of mediastinal shift or pulmonary sepsis. The mediastinal shift was treated by artificial pneumothorax⁵ or thoracoplasty⁶ or alternatively the lung was removed.⁶ Endoscopic dilatation or electrocautery of the bronchial stenosis was also used.⁷ Griffiths⁸ in 1948 was the first to report a successfully resected post-traumatic bronchial stricture and three years later the first successful primary repair was recorded by Scannell.⁹

Incidence

In the 100 years following Webb's initial report 61 cases were recorded and in the next 10 years (1948–58) a further 94,¹⁰ and by 1966 Chesterman¹¹ was able to collect from the published reports over 200 cases. In his review he noted a male preponderance of 75%, and most patients were under 40 years of age. In Britain and the USA the vast majority of blunt chest trauma arises from road traffic accidents, which mir-



Case 11: (a) six weeks and (b) 12 weeks after the original injury.

rors the increase in the number of people engaging in high speed travel. Our experience suggests that tracheobronchial injury might be becoming more common.

The incidence of tracheobronchial rupture is difficult to assess for two reasons. Firstly, many patients die from more lethal and therefore more obvious injuries before they reach hospital and, secondly,

Rupture of the tracheobronchial tree

a proportion of patients present with its complications long after the accident. In a review¹² of 1178 necropsies on trauma victims during the five years 1961–6 there were 33 cases of tracheobronchial rupture. Twenty eight of these patients had died within two hours of the accident from other injuries. The injury to the tracheobronchial tree was the cause of death in only five of the 33 cases and only two of these had reached hospital alive. Among 966 patients with chest injuries reaching one hospital alive after road traffic accidents, only seven cases of tracheobronchial rupture were found in 12 years, an incidence of 0.7%.¹³ A series of 353 patients with major chest injuries, treated in a referral centre over 10 years, was found to include eight (2.2%).¹⁴ The experience of 25 British thoracic surgeons led Bates¹⁵ in 1977 to estimate that a thoracic surgeon in the United Kingdom would be likely to see no more than two cases, only one of which would be acute, in a working life of 30 years. The nine cases of tracheobronchial rupture in this series occurred over a period of 15 years. The overall mortality rate in Burke's review of 167 bronchial ruptures was 30%, with 52% of the deaths occurring within the first hour.¹⁰ In most series about 80% of the injuries have affected the region of the tracheobronchial junction^{16,17} and the above figures reflect the seriousness of intrathoracic rupture. Injuries to the cervical trachea occur in 10–15% of cases¹⁷ and are estimated to carry a 15% mortality from "hypoxia."¹⁸ Life is more at risk in those with complete rupture than in those with partial circumferential or longitudinal lacerations.

Mechanisms of traumatic injury

Schönberg¹⁹ in 1912 was the first to propose a mechanism of bronchial rupture. He postulated that in a closed chest injury there is a reflex closure of the glottis and that this, along with the thoracic compression, causes a rapid rise in intraluminal pressure, which he argued would be highest in the larger airways. Thus rupture occurred once the pressure was too great for the bronchial elasticity. The theory is supported by experimental work on dogs,²⁰ which showed a fivefold increase in bronchial rupture when the chest was compressed against a closed glottis. The experiments also indicated that the lateral force required to cause bronchial rupture is one third of that required in a vertical direction. Sudden anteroposterior compression of the chest increases its transverse diameter and as the lungs remain in contact with the chest wall traction on the relatively fixed carina is produced.¹¹ The shearing force may well be too great for the elasticity of the bronchus and result in rupture.

All of these factors probably combine to cause the classic bronchial ruptures, of which over 80% occur

within 2.5 cm of the carina. This is most likely when the chest wall is elastic and so compressible, which may in part explain the higher incidence in the young. Since these injuries are not usually associated with parenchymal or hilar vascular damage it has been postulated that extreme violence is not essential.²¹ This is supported by the findings of other workers,^{11,18} who have shown that no more than half of these cases have associated injuries more severe than rib fractures. By contrast, the many people suffering extreme force to the chest, as evidenced by the incidence of other intrathoracic injuries, rarely sustain tracheobronchial injury, implying that the important factor is not the absolute force but the way in which it is applied to the chest wall.

The mechanism of cervical tracheal rupture is simple. The hyperextended neck causes the trachea to be stretched against the cervical spine. A direct blow to the unprotected trachea then results in rupture, often with no external evidence of trauma. Classically this is said to occur when the car passenger hits the dashboard, the so called "padded dash syndrome."

Intubation injury

Rupture of a major airway as a result of tracheal intubation for anaesthesia is rare. Only five cases occurred in over 2700 endobronchial intubations with Carlens tubes²²; the two cases in this series occurred in a period of only two years. Single and double lumen red rubber and polyvinyl chloride (PVC) tubes have all been implicated in tracheobronchial rupture.²³ An inexperienced operator, intubation stylets, and multiple attempts at intubation may all lead to rupture regardless of the nature of the tube. The Robertshaw tube, for example, curves in two planes and is made from stiff red rubber; the tip of the tube may therefore produce a laceration during placement or movement of the patient²⁴ (case 8). Many red rubber tubes have high pressure cuffs, which when overinflated may lead to bronchial rupture²⁵ (case 7); and if the cuff inflates asymmetrically, as many of them do, it may also drive the tip of the tube into the bronchial wall.²⁴ Overdistension may occur when excessive volumes of air are injected in an attempt to obtain a good cuff seal or by diffusion of nitrous oxide into the balloon during prolonged anaesthesia.^{23,26} The newer, softer PVC tubes with low pressure concentric cuffs assume the high pressure characteristics of red rubber tubes if more than 3 ml of air is used to inflate the balloon.²⁷ Patients undergoing oesophageal surgery²⁸ and those with chronic airways disease²⁵ are said to be more susceptible to this injury. Neonates as well as adults have been affected, the premature infant being most at risk.²⁹ The use of suction catheters has led to tracheobronchial perforation, the resulting pneumothoraces

requiring treatment by tube thoracostomy.³⁰ In a postmortem study of 14 premature infants the segmental bronchi could be perforated with ease, while in three term infants perforation did not occur.³⁰

Diagnosis

As tracheobronchial rupture is a comparatively rare condition, the diagnosis is easily missed. Except in cases of injury to the cervical trachea in which there has been a blow to the neck, the history is usually non-specific and clinical examination is seldom diagnostic. A high index of suspicion is therefore needed in the treatment of all chest injuries. Dyspnoea has been recorded in about 90% of cases,^{11 31-37} the degree of respiratory distress varying with the rate and amount of air loss. Cyanosis and serious respiratory embarrassment is present in 30% of cases.^{11 31-37} Surgical emphysema, including mediastinal emphysema, was found in only 65% of patients.^{11 31-37} It may be slight (case 5) or massive (case 4). Haemoptysis is less frequent, occurring in 20% of cases,^{11 31-37} but it may be a major problem (case 6). About two thirds of patients will have a pneumothorax, usually unilateral. Bilateral pneumothoraces occur in 5% of cases and are a major cause of hospital mortality¹¹ (case 6). Many authors^{18 38} consider a tension pneumothorax to be uncommon but some quote an incidence as high as 25%.¹¹

Two clinical types of bronchial rupture have been described.³⁹ Type I is obvious; the torn bronchus opens into the pleural cavity, a large pneumothorax develops, there is a brisk and inexhaustible air leak on drainage, the lung fails to expand, and indeed the patient's condition may worsen quite dramatically. The diagnosis of tracheobronchial rupture is all but confirmed. In type II the situation is quite different. There is little or no communication with the pleural cavity and the pneumothorax if present is usually small and responds to drainage, the pleural leak soon becoming sealed with fibrin. Fractured ribs, especially the upper three, have been said to be relevant in diagnosis⁴⁰ but their significance seems to have been exaggerated. In 200 cases of bronchial rupture "chest wall fractures" were present in no more than one third.¹¹ This is explained by the elasticity of the chest wall in the comparatively young victims. Conversely, in 140 patients with first rib fractures, 15 of which were bilateral, there were only three examples of bronchial rupture^{41 42} and in 823 cases of multiple rib fractures there were only seven tracheobronchial ruptures.¹³ Two radiological findings which may be of help are deep cervical emphysema, seen in films of the upper mediastinum,⁴³ and the rare "fallen lung sign," in which the transected bronchus allows the lung to fall away from the mediastinum instead of towards it,

as is the case in an ordinary pneumothorax.⁴⁴

Some points regarding injuries to the cervical trachea merit special mention. With little or no local evidence of trauma symptoms may range from those so slight as to be disregarded to those of severe respiratory obstruction, with only the pretracheal fascia maintaining the patency of the airway. This is illustrated by a case of Bessor and Saegesser.¹⁷ A woman walked to hospital holding her head after a 60 mph (96 km/h) collision in the car she had been driving. There was no surgical emphysema and her chest radiograph was normal, but when her head was tilted to take a Townes view of her cervical spine she suffocated. At necropsy there was complete transection of the cervical trachea.

Serious extrathoracic injuries may delay the recognition a tracheobronchial rupture for weeks or months, as in our cases 9, 10, and 11. They are found in only half of all cases^{11 18} and their presence does not help in assessing the likelihood tracheobronchial rupture. The early diagnosis of tracheal and bronchial rupture may be difficult. Only 53% of cervical and 40% of bronchial ruptures were diagnosed within 48 hours.¹⁶ The essential investigation is bronchoscopy but this is not always conclusive and cases 10 and 11 illustrate that even an experienced bronchoscopist looking for ruptures may be misled, particularly when bleeding from further down obscures the view. Another bronchoscopy after the bleeding has ceased is indicated if the slightest doubt remains.

Treatment and outcome

The initial treatment of tracheobronchial rupture consists of maintenance of the airway, reversal of shock and relief of the pneumothorax. Ideally, definitive surgical repair follows immediately; but when the patient is unfit for emergency thoracotomy the passage of an endotracheal or endobronchial tube to ventilate the distal tracheobronchial tree may stabilise a deteriorating respiratory function. The repair may then be performed later if the patient's condition improves. In some patients with multiple injuries treatment of more severe extrathoracic injuries may take precedence.

Small tears of the cervical trachea may be managed by tracheostomy alone or by splinting with a nasotracheal tube. Complete transections of the trachea, however, should be managed by careful suture care being taken to avoid damage to the recurrent laryngeal nerves. A tracheostomy is sited below and through the anterior wall of the repaired airway, protecting it from the peritracheal oedema that develops in the first few postoperative days. The tracheostomy is allowed to close when there is bronchoscopic evidence of healing, usually at 7-14 days. The management of the late sequelae of cervical rupture, such

Rupture of the tracheobronchial tree

subglottic stenosis, is best undertaken in a specialist centre.

While small lacerations have been successfully managed conservatively,⁴⁵ primary repair of bronchial rupture is the treatment of choice. There need be no cause for concern about the blood supply to the distal bronchus. It has been shown that the collateral supply from the pulmonary arteries is more than adequate to supply the distal bronchi,⁴⁶ and end to end anastomosis after sleeve resection is a well established procedure. Growth is also possible at the anastomosis, as shown by the successful repair of injuries in the young child.⁴⁷ The edges are debrided, the mucosa is carefully approximated, and the end to end anastomosis is fashioned, non-absorbable sutures being used. The suture line is protected by a pedicled pericardial, pleural, or intercostal muscle flap. Resection of pulmonary tissue, as in case 5, may be required in the more extensive ruptures.

Late presentation of bronchial rupture with pulmonary collapse and stricture formation requires treatment along much the same lines. Provided that there is no distal suppuration, reconstruction should be attempted regardless of the time that has elapsed since the original injury. Operations as long as 15 years after the original injury have led to partial recovery of pulmonary function.⁴⁸ Complete bronchial stenosis causing complete pulmonary atelectasis tends to prevent suppuration⁴⁹ (cases 9 and 11). This clinical observation has been confirmed experimentally.⁵⁰ It is important to aspirate and express all of the thick colourless mucus that has collected in the collapsed lung to assist re-expansion. In some cases irreversible fibrosis will have occurred and conservation is not possible. Three quarters of post-traumatic strictures are managed by resection and reanastomosis alone.¹⁷ The remainder are treated by resection of the infected or fibrosed lung, two thirds of these cases requiring pneumonectomy.¹⁷

The results of treatment of injuries to the cervical trachea are good,⁵¹ as cases 1–3 show; but associated lesions may cause long term morbidity. Injury of the larynx and trauma to the recurrent laryngeal nerve may result in a permanently hoarse voice or whisper speech.

Good long term results may be expected in 90% of patients with bronchial rupture treated by early repair.¹⁸ In the early postoperative months, however, suture granulomas are not infrequent when non-absorbable sutures have been used. Suture granulomas may present with stridor or wheezing but the sputum is not always blood stained; anastomotic strictures may present with varying degrees of respiratory embarrassment. Endoscopic suture removal with or without bronchial dilatation is all that is required in many cases (cases 4, 9, and 10).

Full recovery of respiratory function may take up to one year⁵² and in many cases recovery is only partial. The left to right shunt that develops between the pulmonary and bronchial arteries during the period of atelectasis may not be completely reversible.⁵¹ The concomitant parenchymal damage to either lung or indeed the residual deformity of the thoracic cage may be contributory factors (case 9).

The correct early diagnosis of tracheobronchial rupture will lead to a reduction in the long term morbidity associated with this condition, and possibly increased survival. The responsibility for the early diagnosis and initial management lies in many cases with general, orthopaedic, or neurological surgeons. These surgeons must therefore be aware of this important, albeit uncommon, injury. The widespread use of fiberoptic bronchoscopy should enable regular examinations of the suspect tracheobronchial tree to confirm or refute the diagnosis. In cases where effective intrabronchial suction is required, however, rigid bronchoscopy remains the investigation of choice.

I wish to thank Mr W F Kerr, Mr C Parish, and Mr B A Ross for allowing me to report their cases.

References

- 1 Webb A. *Pathologica indica or the anatomy of indian diseases*. 2nd ed. Calcutta: Thacker, 1848:147.
- 2 Winslow WH. Rupture of bronchus of wild duck. *Philadelphia Medical Times* 1871;1:225.
- 3 Krinitzki SI. Zur Kasuistik einer vollständigen Zerreibung des rechten Luftrohrenastes. *Virchows Arch Pathol Anat* 1928;266:815–9.
- 4 Vierheilig J. Die subkutane Bronchuszerreibung. *Beitrage zur Klinischen Chirurgie* 1914;93:201–21.
- 5 Clerf LH. Rupture of main bronchus from external injury. *Surgery* 1940;7:276–9.
- 6 Kinsella TJ, Johnsrud LW. Traumatic rupture of the bronchus. *J Thorac Surg* 1947;16:571–83.
- 7 Loeffler L, Nager F. Uber traumatische Bronchostenose und ihre Behandlung. *Schweiz Med Wochenschr* 1941;71:293–7.
- 8 Griffith JL. Fracture of the bronchus. *Thorax* 1949; 4:105–9.
- 9 Scannell JG. Rupture of the bronchus following closed injury to the chest. *Ann Surg* 1951;133:127–30.
- 10 Burke JF. Early diagnosis of traumatic rupture of the bronchus. *JAMA* 1962;181:682–6.
- 11 Chesterman JT, Satsangi PN. Rupture of the trachea and bronchi by closed injury. *Thorax* 1966;21:21–7.
- 12 Bertelsen S, Howitz P. Injuries of the trachea and bronchi. *Thorax* 1972;27:188–94.
- 13 Alyono D, Perry JF. Impact of speed limit I. Chest injuries: review of 966 cases. *J Thorac Cardiovasc Surg* 1982;83:519–22.
- 14 Dougall AM, Paul ME, Finley RJ, *et al*. Chest trauma—

- current morbidity and mortality. *J Trauma* 1977; 17:547-53.
- 15 Bates M. Rupture of the bronchus. In: Williams WG, Smith RE, eds. *Trauma of the chest* (the Coventry conference). Bristol: John Wright and Sons, 1977: 142-50.
 - 16 Dor J, Forster E, Le Brigand H. *Rupture traumatiques des bronches et de la trachee thoracique*. Vol 1. Paris: Doin, 1964:232.
 - 17 Beeson A, Seagesser F. *A colour atlas of chest trauma and associated injuries*. Vol 2. London: Wolfe Medical, 1983:12.
 - 18 Kirsh MM, Orringer MB, Behrendt DM, Sloan H. Management of tracheobronchial disruption secondary to non penetrating trauma. *Ann Thorac Surg* 1976;22:93-101.
 - 19 Schönberg S. Bronchialrupturen bei thorax kompression. *Berl klin Wochenschr* 1912;49:2218-21.
 - 20 Lloyd JR, Heydinger DK, Klassen KP, Roetlig LC. Rupture of the main bronchi closed chest injury. *Arch Surg* 1958;77:597-605.
 - 21 Black JBMcK, Lawson RAM. Rupture of the bronchus following closed injury to the chest. *J R Coll Surg Edinb* 1970;15:21-6.
 - 22 Guernelli N, Bragaglia RB, Briccoli A, Mastorilli M, Vecchi R. Tracheobronchial ruptures due to cuffed Carlens tubes. *Ann Thorac Surg* 1979;28:66-8.
 - 23 Burton NA, Fall SM, Lyons T, Graeber GM. Rupture of the left main-stem bronchus with a polyvinylchloride double-lumen tube. *Chest* 1983;83:928-9.
 - 24 Heisser M, Steinberg JJ, MacVaugh H, Klineberg PL. Bronchial rupture, a complication of use of the Robertshaw double-lumen tube. *Anesthesiology* 1979;51:88.
 - 25 Smith BAC, Hopkinson RB. Tracheal rupture during anaesthesia. *Anaesthesia* 1984;39:894-8.
 - 26 Forster JMG, Lau OJ, Alimo EB. Ruptured bronchus following endobronchial intubation. *Br J Anaesthiol* 1983;55:687-8.
 - 27 Brodsky JB, Shulman MS, Mark JBD. Airway rupture with a disposable double lumen tube [letter]. *Anesthesiology* 1986;64:415.
 - 28 Wagner DL, Gammage GW, Wong ML. Tracheal rupture following the insertion of a disposable double-lumen tube. *Anesthesiology* 1985;63:698-700.
 - 29 McLeod BJ, Sumner E. Neonatal tracheal perforation. *Anaesthesia* 1986;41:67-70.
 - 30 Anderson KD, Chandra R. Pneumothorax secondary to perforation of sequential bronchi by suction catheters. *J Pediatr Surg* 1976;11:687-93.
 - 31 Mazzei EA, Mulder DG. Closed chest injuries to the trachea and bronchus. *Arch Surg* 1970;100:677-80.
 - 32 Collins JP, Ketharanathan V, McConchie I. Rupture of major bronchi resulting from closed chest injuries. *Thorax* 1973;28:371-5.
 - 33 Grover FL, Ellestad C, Arom KV, Root D, Cruz AB, Trinkle JK. Diagnosis and management of major tracheobronchial injuries. *Ann Thorac Surg* 1979;28:384-91.
 - 34 Deslauriers J, Beaulieu M, Archambault G, LaForge J, Bernier R. Diagnosis and long term follow up of major bronchial disruptions due to nonpenetrating trauma. *Ann Thorac Surg* 1982;33:32-9.
 - 35 Mills SA, Johnston FR, Hudspeth AS, Breyer RH, Myers RT, Cordell AR. Clinical spectrum of blunt tracheobronchial disruption illustrated by seven cases. *J Thorac Cardiovasc Surg* 1982;84:49-58.
 - 36 Amauchi W, Birolini D, Branco PD, Oliveira MRD. Injuries to the tracheobronchial tree in closed trauma. *Thorax* 1983;38:923-8.
 - 37 Jones WS, Mavroudis C, Richardson D, Gray LA, How WR. Management of tracheobronchial disruption resulting from blunt trauma. *Surgery* 1984;95:319-22.
 - 38 Wiot JF. Tracheobronchial trauma. *Semin Roentgenol* 1983;18:15-22.
 - 39 Davies D, Hopkins JS. Patterns in traumatic rupture of the bronchus. *Injury* 1973;4:261-4.
 - 40 Crawford WO. Pulmonary injury in thoracic and non-thoracic injury. *Radiology* 1973;11:527-41.
 - 41 Albers JE, Rath RK, Glaser RS, Poddar PK. Severity of intrathoracic injuries associated with first rib fractures. *Ann Thorac Surg* 1982;33:614-8.
 - 42 Woodring JH, Fried AM, Hatfield DR, et al. Fractures of the first and second ribs: predictive value for arterial and bronchial injury. *AJR* 1982;138:211-5.
 - 43 Eijgelaar A, Van der Heide NH. A reliable early symptom of bronchial or tracheal rupture. *Thorax* 1970;25:116-25.
 - 44 Oh KS, Fleischner FG, Wyman SM. Characteristic pulmonary finding in traumatic complete transection of main-stem bronchus. *Radiology* 1969;92:371-2.
 - 45 McMillan I. In discussion. Bates M. Rupture of the bronchus. In: Williams WG, Smith RE, eds. *Trauma of the chest* (the Coventry conference). Bristol: John Wright and Sons, 1977:151-2.
 - 46 Ellis FH, Grindley JH, Edwardes JE. The bronchial arteries: 1—Experimental occlusion. *Surgery* 1951;30:810-26.
 - 47 Rahbar A, Chang FC, Farha SJ. Rupture of the bronchus: case report of successful resection and anastomosis in a 13 month infant. *J Trauma* 1978;18:140-1.
 - 48 Samson PC. In discussion: Mahaffey DE, Creech OR, Boren HG, DeBakey ME. Traumatic rupture of the left main bronchus successfully repaired eleven years after injury. *Thorac Surg* 1956;32:331.
 - 49 Paulson DL. Traumatic bronchial rupture with plastic repair. *J Thorac Surg* 1957;22:636-45.
 - 50 Tannenber J, Pinner M. Atelectasis and bronchiectasis. *J Thorac Surg* 1942;11:571-616.
 - 51 Wychulis AR, Neville WE. Tracheal and bronchial reconstructive procedures. *Surg Gynecol Obstet* 1974;139:433-55.
 - 52 Logeais Y, Florent D, Danrigal A, et al. Traumatic rupture of the right main bronchus in an eight year old child successfully repaired eight years after injury. *Ann Surg* 1970;172:1039-47.