

# Lung abscess in cystic fibrosis

GERARD J CANNY, JACQUES E MARCOTTE, HENRY LEVISON

From the Department of Paediatrics, Division of Chest Diseases, Hospital for Sick Children, Toronto, Canada

Almost all patients with cystic fibrosis eventually develop chronic pulmonary infection with specific bacterial pathogens, notably *Pseudomonas aeruginosa* and *Staphylococcus aureus*. Despite this, the development of large pulmonary abscess cavities in patients with cystic fibrosis is exceedingly uncommon. Similarly, bacteraemia in cystic fibrosis is surprisingly rare. We describe a patient with cystic fibrosis who had bilateral recurrent lung abscesses for two years, which were eventually the source of fatal *Pseudomonas* septicæmia.

## Case report

The patient was an 18 year old girl whose cystic fibrosis was diagnosed soon after birth because of meconium ileus. A subsequent sweat chloride concentration was raised (75 mEq/l). Her condition was initially extremely mild and when she was 16 her chest radiographs, pulmonary function, and arterial blood gas tensions had been normal. Her treatment included supplementary pancreatic enzymes and fat soluble vitamins, chest physiotherapy with postural drainage, and continuous cloxacillin treatment. Her sputum was intermittently infected with *S aureus*, which in vitro was invariably sensitive to cloxacillin.

At 17 years of age she presented to hospital with a history of increased cough, sputum production, and fever up to 39.5°C. A chest radiograph disclosed a large abscess with air-fluid levels in the posterior segment of the right upper lobe (fig 1). Sputum culture grew *S aureus*.

Parenteral cloxacillin 200 mg/kg a day was administered but the abscess persisted. A copious amount of purulent material was obtained during therapeutic bronchoscopy but cultures of this material for aerobic and anaerobic bacteria, acid fast bacilli, and fungi were negative. The patient was discharged having maintenance treatment with oral cloxacillin and during the ensuing four weeks the abscess cavity slowly diminished in size and the air-fluid levels disappeared.

The patient next presented four months later with a history of left sided pleuritic chest pain. A chest radiograph showed a large abscess with an air-fluid level in the apical segment of the left lower lobe and a small residual cystic lesion in the right upper lobe (fig 2). A course of parenteral cloxacillin was given without improvement. Culture of material obtained at therapeutic bronchoscopy yielded a growth of *Pseudomonas denitrificans*. The left lower lobe cavity became smaller during the following few weeks and the patient remained well until four months later a large abscess re-

curred in the left lower lobe. Cultures obtained at bronchoscopy grew *S aureus* sensitive to cloxacillin. Four weeks later the patient presented with bilateral abscesses affecting the right and left lower lobes. Bronchoscopy was repeated and *S aureus* was again cultured from the aspirated material.

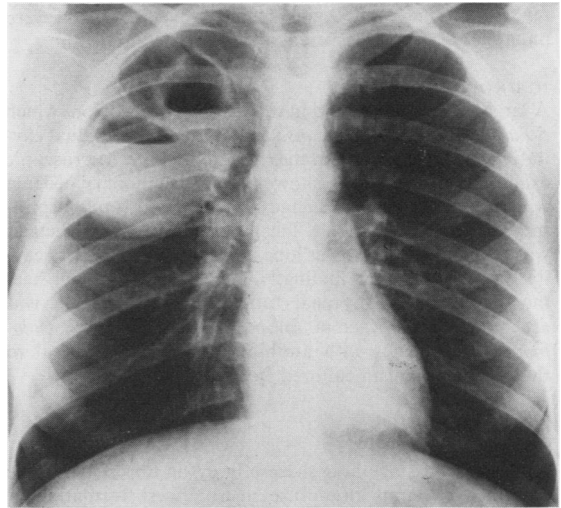


Fig 1 Chest radiograph showing the large abscess cavity in the right upper lobe.

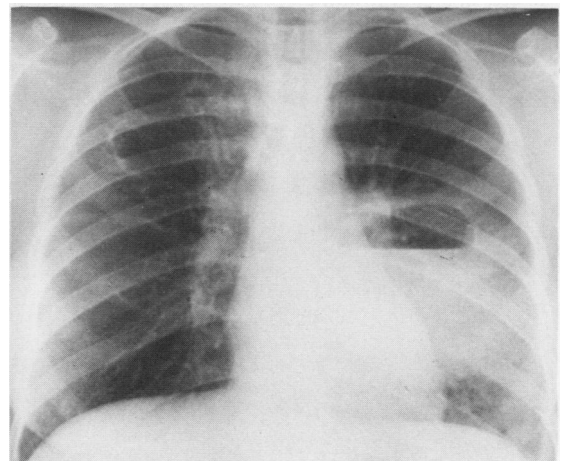


Fig 2 Chest radiograph showing the abscess cavity in the left lower lobe.

Address for reprint requests: Dr GJ Canny, Department of Paediatrics, Division of Chest Diseases, Hospital for Sick Children, Toronto, Ontario, Canada M5G 1X8.

Accepted 23 July 1985

The patient received a four week course of parenteral cloxacillin and, although some resolution in the size of the abscess cavities was achieved, large bilateral cystic lesions persisted. Immunological evaluation showed normal T and B cell function, normal neutrophil function, and normal serum C3 and C4 activity. A barium swallow showed no evidence of aspiration.

The patient was admitted to hospital for the last time with a history of fever up to 39.5°C, productive cough, and vomiting. A chest radiograph showed an air-fluid level in the left lower lobe cavity lesion. The white cell count was  $21.3 \times 10^{-9}/l$ , with 65% band forms, 25% neutrophils, 8% lymphocytes, and 2% monocytes. Despite treatment with fluids and parenteral antibiotics (tobramycin, ticarcillin, and cloxacillin) the patient developed septicaemic shock with disseminated intravascular coagulation and compromised renal function. Despite vigorous supportive treatment severe pulmonary oedema occurred, which resulted in death.

#### NECROPSY FINDINGS

A large abscess was found in the left lower lobe, from which *S aureus* and *Ps denitrificans* were cultured. A residual cavitating lesion was found in the right upper lobe. Microscopic examination of the lung showed severe pulmonary oedema with extensive alveolar damage consistent with adult respiratory distress syndrome. A localised area of bronchiectasis was noted in the left lower lobe adjacent to the abscess cavity. Other important findings included focal adrenal haemorrhage and acute renal tubular necrosis. Death was attributed to septicaemia. Blood cultures yielded *Pseudomonas denitrificans* with antibiotic sensitivity identical to that of the organism cultured from the lung abscess.

#### Discussion

Although end stage lung disease in cystic fibrosis could be described in terms of diffuse microabscess formation in bronchiectatic airways, the development of large abscess cavities is extremely uncommon in the disease. Lester *et al*<sup>1</sup> recently described the development of a large pulmonary abscess in a patient with cystic fibrosis but this was due to

anaerobic infection secondary to aspiration. Given that *S aureus* is the leading cause of lung abscess in children,<sup>2</sup> the rarity of this complication among patients with cystic fibrosis, many of whom are chronically colonised with this organism, is certainly intriguing. Pulmonary infection in patients with cystic fibrosis tends to remain localised to the respiratory tract and the development of septicaemia or metastatic infection has rarely been described in the disease.<sup>3-6</sup> Our patient's death was directly related to disseminated infection by an unusual *Pseudomonas* species also present in a lung abscess.

We were unable to identify a specific cause for recurrent lung abscess formation and the eventual development of septicaemia in our patient. As her underlying lung disease was extremely mild, abscess formation was certainly an unexpected complication. The *S aureus* was consistently sensitive to cloxacillin, which she took regularly.

There was no evidence of an underlying anatomical abnormality. The patient's immune mechanisms were found to be intact. Indeed, serum immunoglobulin concentrations were raised, a feature of cystic fibrosis<sup>7</sup> that may explain the remarkable ability of these patients to keep infection localised to the respiratory tract.

#### References

- 1 Lester LA, Egge A, Hubbard VS, Di Sant'Agnese PA. Aspiration and lung abscess in cystic fibrosis. *Am Rev Respir Dis* 1983;127:786-7.
- 2 Asher MI, Spier S, Beland M, Coates AL, Beaudry PH. Primary lung abscess in childhood. *Am J Dis Child* 1982;136:491-4.
- 3 McCarthy MM, Rourke MH, Spock A. Bacteremia in patients with cystic fibrosis. *Clin Pediatr* 1980;19:746-8.
- 4 Fischer EG, Shwachman H, Wepsic JG. Brain abscess and cystic fibrosis. *J Pediatr* 1979;95:385-8.
- 5 Duffner PK, Cohen ME. Cystic fibrosis with brain abscess. *Arch Neurol* 1979;36:27-8.
- 6 Rosenstein BJ, Hall DE. Pneumonia and septicemia due to *Pseudomonas cepacia* in a patient with cystic fibrosis. *Johns Hopkins Medical Journal* 1980;147:188-9.
- 7 Turner MW, Warner JO, Stokes CR, Norman AP. Immunological studies in cystic fibrosis. *Arch Dis Child* 1978;53:631-8.