

Bronchiectasis and oligospermia: two families

PAMELA B DAVIS, VAN S HUBBARD, A JULIAN GARVIN

From the Pediatric Metabolism Branch, National Institute of Arthritis, Metabolism, and Digestive Diseases, and the Laboratory of Pathology, National Cancer Institute, Bethesda, Maryland, USA

ABSTRACT Five patients from two families had a bronchiectasis syndrome; the men also had oligospermia with poor progressive sperm motility. None of the patients had cystic fibrosis, α_1 antitrypsin deficiency, immunoglobulin deficiency, structural abnormalities of the bronchi, or abnormalities of ciliary ultrastructure. Onset of pulmonary symptoms was in the neonatal period or infancy, and bronchitis and bronchiectasis were most severe in the middle and lower lobes. Two patients had sinusitis and two otitis. The two men old enough to be studied had $2-10 \times 10^6$ sperm/ml of ejaculate with less than 10% progressively motile. There were no other associated anomalies. These patients probably had a distinct genetic error predisposing to pulmonary infection leading to bronchiectasis and, in men, oligospermia with poor progressive motility.

Bronchiectasis is associated with male infertility in cystic fibrosis,¹ the ciliary dyskinesia syndrome,² and Young's syndrome.³⁻⁵ We report on five patients from two families in whom bronchiectasis is associated with oligospermia.

Methods

The two families were identified after referral of one member (IC and IIB) for sweat testing. Clinical studies were performed as described below.

Four patients underwent fibreoptic bronchoscopy and biopsy of the bronchial mucosa near the carina. Bronchial biopsies were orientated on filter paper and fixed in 2.5% glutaraldehyde in 0.1M sodium phosphate, pH 7.4, for 24 hours. Samples were postfixed in 1% osmium tetroxide in 0.1M sodium phosphate, dehydrated in graded ethanol solutions, and flat embedded in Epon 812 to ensure orientation of the epithelium. Sections were cut on an American Optical ultramicrotome and stained with acetate lead citrate. Sections were viewed on a Philips EM210 electron microscope at 60 kV.

Results

FAMILY HISTORY

No consanguinity was reported, and both families were of northern European and British extraction.

Address for reprint requests: Dr PB Davis, Pulmonary Division, VAMC, Cleveland, Ohio 44106, USA.

Accepted 26 November 1984

In family I three of seven siblings (IA, IB, and IC) had identified pulmonary abnormalities. One sister (ID) denied pulmonary disease or sinusitis but had attended a fertility clinic for two years after two years of unsuccessful attempts at conception. No cause for infertility was found, and ultimately two children were born to her. No other family member, including parents, uncles, aunts, and cousins, was known to have had bronchitis, sinusitis, infertility, or perinatal death.

In family II two of three siblings had bronchitis. The third sibling was apparently unaffected. The father of family II had had recurrent sinusitis, which had required surgical drainage, but denied having a cough and had a normal chest radiograph. He had four siblings, one of whom, a smoker, had been diagnosed as having chronic bronchitis. No other family members, including grandparents, aunts, uncles, and cousins, was known to have bronchitis, sinusitis, infertility, or perinatal death.

LABORATORY DATA

All patients had a normal sweat chloride concentration (<55 mmol(mEq)/l) and normal serum concentrations of carotene and IgA, IgM, and IgG including subclasses one to four. Four patients (IA, IB, IIA, and IIB) had normal serum concentrations of α_1 antitrypsin (200-300 mg/dl); patient IC was not tested. Three patients (IA, IB, and IIB) showed delayed hypersensitivity to mumps, candida, or streptokinase/streptodornase antigens but not to tuberculin; patients IC and IIA were not tested. Leukocyte counts were in the range of 5.4 to $9.2 \times$

Results of pulmonary function tests

Test	Case No					
	IA	IB	IC	IIA	IIB	
TLC (l)*	7.5 (104)	4.1 (82)	7.4 (118)	6.6 (94)	4.3 (76)	
VC (l)*	5.9 (110)	3.3 (89)	5.9 (123)	4.8 (93)	2.9 (73)	
FEV ₁ (l)*	4.3 (102)	2.7 (91)	4.4 (118)	3.8 (93)	2.1 (64)	
FEV ₁ /FVC (%)	76	82	75	72	72	
MMEF (l/s)*	4.0 (88)	2.7 (91)	3.6 (81)	4.2 (96)	1.5 (41)	
D _L CO (ml)*	48.1 (123)	21.5 (88)	32.1 (116)	51.6 (143)	27.6 (111)	
RV/TLC (%)	21.1	20.4	20.0	27.0	32.1	

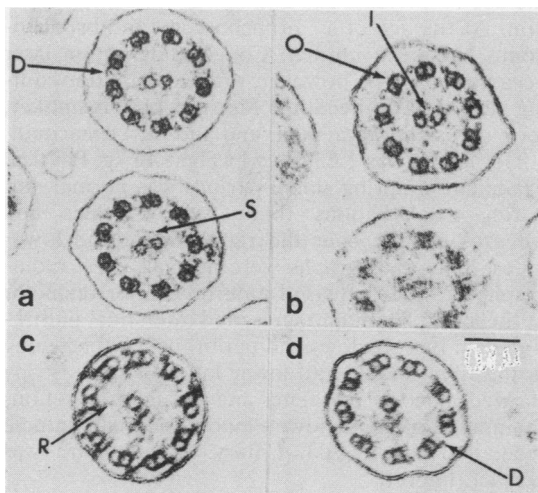
*Percentage predicted.

TLC = total lung capacity; VC = vital capacity; FEV₁ = forced expiratory volume in one second; FVC = forced vital capacity; MMEF = maximal mid-expiratory flow rate; D_LCO = diffusing capacity for carbon monoxide corrected for age and alveolar volume; RV = residual volume.

10⁹/l with normal differential counts on several occasions for each patient. Serum concentrations of haemolytic complement were not determined in one patient (IA) but were normal in the others. Acid fast bacilli or fungi were never recovered from the sputum or bronchial washings. In three patients (IA, IC, and IIA) only normal oral flora grew from sputum cultures. Patient IB had *Haemophilus influenzae* in her sputum during exacerbations but not at other times. *Streptococcus pneumoniae* and *Haemophilus influenzae* were recovered from the sputum of patient IIB on several occasions. The table shows the results of pulmonary function tests.

ULTRASTRUCTURE OF THE CILIA

The structure of the cilia was examined in four



Cross section of cilia from patients IA(a), IB(b), IIA(c), and IIB(d), showing normal ultrastructure. The microtubules are arranged with nine outer pairs (O) around an inner (I) pair. Each outer doublet has two dynein arms (D) and is attached to a central sheath (S) by radial spokes (R). (All photos $\times 6500$.)

patients (IA, IB, IIA, and IIB) and found to be normal on cross section, with the typical microtubular arrangement of nine outer doublet tubules and a central pair. The outer doublet tubules were connected to adjacent doublets by nexin links. Each outer doublet had two dynein arms. The inner doublet was surrounded by a sheath and was connected to the outer pairs of radial spokes (figure). Longitudinal sections through the cilia showed basal bodies with normal structure.

Case reports

CASE IA

A 29 year old man had been kept in hospital for several weeks after birth because of "pulmonary disease of unknown aetiology". He had had recurrent pneumonia and had undergone resection of the right middle lobe at 3 years. The resected lobe had shown naked eye features of bronchiectasis; microscopic examination had shown dilated inflamed bronchioles but no inclusion bodies. Cartilage had been present appropriately.

Pneumonia had recurred several times each year for several years after surgery. Productive cough had become persistent from the age of 17. He had smoked 10 to 20 cigarettes daily from the age of 18. His activity was not limited. Two marriages had been childless.

His height was 1.77 m and weight 66 kg. Physical examination showed no abnormality apart from a thoracotomy scar. Testicular size was estimated at 15 ml bilaterally; the epididymes were palpable and not enlarged. Sinus radiographs were normal; chest radiographs showed postsurgical changes alone. At bronchoscopy mild erythema of the right upper lobe orifice with clear secretions was noted. Bronchial ciliated cells that excluded trypan blue were examined and found to have a beat pattern similar to that of normal controls. The ultrastructure of the cilia was normal (figure). A sperm count (after two days' abstinence) was 2×10^6 /ml with less than 10%

progressive motility.

CASE IB

The 24 year old sister of patient IA had been delivered at term by caesarean section because of placenta praevia and kept in hospital for several weeks after birth because of "neonatal pneumonia." At the age of 7 years a right middle lobe pneumonia had resolved with oral antibiotics. At the age of 9 years a right middle lobe pneumonia had failed to resolve completely after antibiotic treatment. Because of recurrent otitis media she had undergone myringotomy with tube placement. Episodes of dyspnoea on exertion and productive cough had begun at the age of 12 years and had recurred five or six times a year. At the age of 14 bronchograms had shown saccular bronchiectasis of the right middle lobe and cylindrical bronchiectasis of the right lower lobe. From the age of 17 she had smoked 10 to 20 cigarettes daily and had had a chronic productive cough. After five years of unprotected intercourse with two husbands pregnancy had not occurred.

Her height was 1.58 m and weight 46 kg. Her fingers were clubbed, and on auscultation there were crackles and wheezes over the right lower and middle lobes. Chest radiography showed increased interstitial markings and peribronchial thickening in the right middle lobe and both lower lobes. Sinus radiographs were normal. Cilia were examined and found to have normal ultrastructure (figure).

CASE IC

The 17 year old brother of patients IA and IB had remained in hospital for the first two months of life because of an undiagnosed pulmonary condition. Subsequently, pneumonia had recurred once or twice a year. From early childhood until aged 14 years he had had four to six episodes of otitis media a year, and had been treated by myringotomy and tube placement.

His height was 1.75 m and weight 65 kg. Physical examination showed no abnormality apart from bilateral basal wheezes and crackles over the right middle lobe. Testicular size was estimated at 12 ml bilaterally; the epididymes were palpable. Sinus radiographs showed clouded maxillary antra and maldevelopment of the frontal sinuses. Chest radiography showed collapse of the right middle lobe and ring shadows. Semen analysis was not possible; bronchoscopy was not performed.

CASE IIA

A 30 year old man had had frequent colds and "bronchitis" in childhood but had never been admitted to hospital or had impaired regular activity. From the age of 20 years he had smoked 10 to 20

cigarettes daily and had had morning cough productive of white to yellow sputum. While in hospital at the age of 27 for nephrolithiasis a horseshoe kidney had been discovered. He was taking diazepam 5–20 mg daily. He had never married.

His height was 1.75 m and weight 81 kg. Physical examination showed no abnormalities. Testicular size was estimated at 15 ml, and the epididymes were palpable and not enlarged. Sinus radiographs showed maxillary clouding and chest radiographs increased interstitial markings and ring shadows in the right middle lobe, right lower lobe, and lingula. A bronchogram showed cylindrical and saccular bronchiectasis of the right middle lobe. Bronchoscopy showed mucosal erythema and oedema. Bronchial cells that excluded trypan blue had ciliary beating indistinguishable from normal, and ciliary ultrastructure was normal (figure). A sperm count showed 4–10 × 10⁶/ml with 10% progressively motile (obtained on three separate occasions after two days' abstinence). Serum testosterone concentration was 273 ng/dl (normal 200–1000 ng/dl), luteinising hormone concentration 10 mIU/ml (normal 6–26 mIU/l), and follicle stimulating hormone concentration 7.5 mIU/ml (normal 5–25 mIU/l).

CASE IIB

The 25 year old sister of patient IIA had had frequent, severe infections of the upper and lower respiratory tract beginning in the first year of life. By the age of 14 years she had had dyspnoea on exertion. At the age of 17 bronchoscopy and bronchograms had been normal. Cough and sputum later became persistent, however, with exacerbations during respiratory infections. She was a non-smoker, took occasional diazepam, and had never married.

Her height was 1.65 m and weight 46 kg. Physical examination during stable periods was normal, but during exacerbations there were crackles and wheezes audible over the right middle and lower lobes. Sinus radiographs were normal; chest radiographs showed increased anteroposterior diameter of the chest, flat diaphragms, and interstitial infiltration with ring shadows and peribronchial thickening in the right middle and lower lobes. Bronchoscopy showed mucosal erythema and purulent secretions draining from both lower lobes, the right middle lobe, and the lingula. Ciliary ultrastructure was normal (figure).

Discussion

The association of bronchiectasis and male infertility is present in cystic fibrosis, the ciliary dyskinesia syndrome, and Young's syndrome.^{1–5} Our patients

may represent yet another variation on this theme. They had a familial disorder characterised by: (1) onset of pulmonary symptoms in infancy or the neonatal period; (2) middle and lower lobe infections leading eventually to bronchiectasis; and (3) oligospermia with poor progressive sperm motility. There was no consistently associated disease of other organs and no situs inversus. In family I three out of seven siblings were affected and in family II two out of three. In patient IA a diagnosis of bronchiectasis was confirmed by surgical pathology and in patients IB and IIA by bronchography; the others clearly met clinical and radiographic criteria for this diagnosis.^{6,7} Despite this obvious pulmonary pathology the patients had normal or near normal pulmonary function (table).

These patients did not have cystic fibrosis as their sweat chloride concentrations were normal and they lacked the usual cystic fibrosis sputum flora; they had no pancreatic disease, and the men had oligospermia, not azoospermia as occurs in cystic fibrosis. They differed from patients with the ciliary dyskinesia syndrome, for none of our five patients had situs inversus (compared with the expected 50%), only two of the five had sinusitis and otitis (compared with 100% in one series⁸), and the men had oligospermia (most, but not all, previously reported patients with the ciliary dyskinesia syndrome have normal sperm counts^{8,9}). Bronchial ciliated cells from two patients had motion indistinguishable from controls, and the ultrastructure of the cilia was normal. Thus our patients did not meet the criteria of Afzelius and Mossberg for diagnosis of the ciliary dyskinesia syndrome.¹⁰ A single patient with normal ciliary ultrastructure and classic Kartagener's triad has been reported,¹¹ however, so our patients may represent a clinical and structural variant of the ciliary dyskinesia syndrome.

In Young's syndrome bronchiectasis, chronic bronchitis, or sinusitis is associated with obstructive azoospermia.^{3,4} Ciliary ultrastructure is normal, and situs inversus is not observed. Familial clustering has not been reported. Our patients were similar, except that our male patients had some sperm in the ejaculate and the disorder was clearly familial. Young's patients were, however, selected for azoospermia; if this is an inconstant feature of the syndrome our patients' disease may be closely related. Indeed, despite normal motility of sperm aspirated from epididymal heads¹² when the vas was opened surgi-

cally in patients with Young's syndrome only a few, poorly motile sperm appeared in the ejaculate.⁵

Alternatively, our patients may represent a distinct subgroup of patients with an inherited disorder predisposing to chronic bronchitis and bronchiectasis and also associated with few, poorly motile sperm in the ejaculate. Further studies of families such as these may elucidate the interesting relation between recurrent pulmonary infections and male fertility.

This work was conducted with the technical help of Charles Poore. We gratefully acknowledge the support of Paul A di Sant'Agnese and thank Dr Suk Hee Kymn and Dr Byron Cooper for referring these patients and Dr Peter Schur for IgG subclass determinations.

References

- 1 di Sant'Agnese PA, Davis PB. Cystic fibrosis in adults: 75 cases and a review of 232 cases in the literature. *Am J Med* 1979;**66**:121-32.
- 2 Afzelius BA. A human syndrome caused by immotile cilia. *Science* 1976;**193**:317-9.
- 3 Neville E, Brewis RAL, Yeates WK, Burridge A. Respiratory tract disease and obstructive azoospermia. *Thorax* 1983;**38**:929-33.
- 4 Hendry WF, Knight RK, Whitfield HN, *et al.* Obstructive azoospermia: respiratory function tests, electron microscopy, and the results of surgery. *Br J Urol* 1978;**50**:598-604.
- 5 Young D. Surgical treatment of male infertility. *J Reprod Fertil* 1970;**23**:541-2.
- 6 Hilton AM, Doyle L. Immunological abnormalities in bronchiectasis with chronic bronchial suppuration. *Br J Dis Chest* 1978;**72**:207-16.
- 7 Wynn-Williams N. Bronchiectasis: a study centred on Bedford and its environs. *Br Med J* 1953;*i*:1194-9.
- 8 Turner JAP, Corkey CWB, Lee JYC, *et al.* Clinical expressions of immotile cilia syndrome. *Pediatrics* 1981;**67**:805-10.
- 9 Eliasson R, Mossberg B, Camner P, *et al.* The immotile cilia syndrome. A congenital ciliary abnormality as an etiologic factor in chronic airway infections and male sterility. *N Engl J Med* 1977;**297**:1-6.
- 10 Afzelius BA, Mossberg B. Immotile cilia. *Thorax* 1980;**35**:401-5.
- 11 Herzon FS, Murphy S. Normal ciliary ultrastructure in children with Kartagener's syndrome. *Ann Otol Rhinol Laryngol* 1980;**89**:81-3.
- 12 Yeates WK. Azoospermia 1980. *Acta Chir Iugosl* 1981;suppl 2:603-8.