

EXTRAPLEURAL PNEUMONECTOMY AND PLEURECTOMY IN PULMONARY TUBERCULOSIS *

BY

IRVING ARTHUR SAROT

From the Sea View Hospital, New York

For the greater part of the past century, the possibility of the excision of pulmonary tuberculosis has intrigued the imaginations of phthisiologists and surgeons in many lands. Isolated instances of successful excisions of tuberculous portions of the lung were reported many decades ago, but the overwhelming difficulties encountered discouraged general acceptance and systematic application of such procedures.

During the past decade there has been a resurgence of interest in excisional surgery for pulmonary tuberculosis. Because of the clearer definition of the limitations of collapse therapy, the investigation of the value of excision has been encouraged by phthisiologists and thoracic surgeons alike. This renaissance has been stimulated and aided by a number of factors: advances in anaesthesia, blood banks, the introduction of antibiotics to clinical use, and the general improvement in the surgical techniques of pulmonary resection. The works particularly of Freedlander (1935), Jones and Dolley (1939), Churchill and Klopstock (1943), Maier (1945), Overholt and Wilson (1945), Sweet (1946), and Bailey (1947) constitute most valuable pioneer efforts.

The present trend toward more frequent excisions is evident from the statistics (Table I) recently presented by Herben (1949).

Since 1946, under the stimulation and guidance of Dr. George G. Ornstein, excisional procedures have been applied with increasing frequency in a wide variety of cases of pulmonary tuberculosis at Sea View Hospital (Selikoff and Tchertkoff, unpublished data). Collapse measures had been attempted unsuccessfully on many of these patients before excision was recommended, and all but a few were considered unsuitable for thoracoplasty. Table II is a review of the surgical procedures performed during the past five years on patients in the care of Dr. Ornstein (personal communication, 1948). The general increase in the number of cases operated upon may be due, at least in part, to the effect of streptomycin in bringing more patients into the operable group. But the increasing scope of excision in pulmonary tuberculosis has made it possible to treat successfully many patients who, because of the severe type of their disease, could not be treated adequately in any other way.

TABLE I
PRESENT STATUS (UTILIZATION) OF PHRENIC, THORACOPLASTY, AND RESECTION IN METROPOLITAN NEW YORK
TUBERCULOSIS HOSPITAL SERVICES (HERBEN, 1949)

Cases and Procedures	1943	1944	1945	1946	1947	Total 1943-7
Total number of patients treated†	24,884	23,150	21,580	22,145	23,196	82,859
Total phrenic interruptions	142	159	189	188	158	836
Percentage of patients receiving phrenic interruptions	0.6%	0.7%	0.9%	0.8%	0.7%	1.0%
Total thoracoplasties—all stages	922	784	872	1,146	1,509	5,233
Percentage having thoracoplasty—all stages	3.7%	3.4%	4.0%	5.2%	6.5%	6.3%
Total resections (total and subtotal)	—	—	47	64	180	291
Percentage receiving resection	—	—	0.21%	0.28%	0.77%	0.56%‡
Pneumoperitoneums—initials and refills ...	468	320	1,108	1,525	2,432	5,853

† Includes carry-over on first of year plus admissions and readmissions for individual years; for five-year period, carry-over on January 1, 1943, only, and all subsequent admissions.
‡ Based on number of patients on January 1, 1945, plus all admissions to December 31, 1947.

* Paper read by invitation at the annual conference of the British Tuberculosis Association, April 7, 1949, at Cambridge.

TABLE II
ANALYSIS OF YEARLY INCIDENCE OF SELECTED SURGICAL
PROCEDURES (ORNSTEIN, 1944-8)

	1944	1945	1946	1947	1948
Pneumonectomy ...	8	4	12	42	91
Lobectomy ...	2	1	5	11	15
Segmental resection ...	0	0	2	4	2
Lung resections (all types) ...	10	5	19	57	108
Operative mortality (%)	30	20	15.8	1.7	5.5
Thoracoplasty ...	27	25	31	12	17
Schede thoracoplasty ...	8	3	3	0	0
Cavernostomy ...	2	13	2	0	4

Thoracoplasty is still performed upon suitable cases, but cavernostomy is reserved for those patients who, because of insufficient respiratory capacity or some other reason, are considered unsuitable for further surgical collapse measures or excision.

INDICATIONS FOR RESECTION IN PULMONARY TUBERCULOSIS

Until recently the indications for excision have been limited principally to cases of thoracoplasty failure and bronchostenosis. As experience has accumulated and confidence has increased, these indications have broadened rapidly.

Chamberlain (unpublished data) has presented a classification of the indications for resection in pulmonary tuberculosis which is a useful guide in the selection of cases. His classification is as follows:

- Thoracoplasty failure.
- Thoracoplasty failure anticipated.
 - (a) Disease predominantly pulmonary.
 - (b) Disease predominantly bronchial.
 - (c) Disease predominantly pleural.
 - (d) Disease unfavourably located.
- Emergency resection.
 - (a) Uncontrollable haemorrhage.
 - (b) Acute cavity rupture.

Table III summarizes a survey by Selikoff and Tchertkoff (1949) of the indications for which pulmonary resection was performed upon 125 consecutive cases (1946-8) of pulmonary tuberculosis from Dr. Ornstein's medical service.

Such indications can best be illustrated by the presentation and discussion of cases.

THORACOPLASTY FAILURES

Inability to achieve cavity closure and sputum conversion constitutes a thoracoplasty failure. The results of treatment of residual cavities by revision

operations (Hochberg and others, 1946; Murphy and others, 1948) have been disappointing. The success achieved by resection of the diseased lung in these cases is, therefore, particularly gratifying. The antecedent thoracoplasty may render the excision more difficult technically, but the post-operative course of these cases is notably benign. If the extent of the disease permits, partial excision of the lung is possible. One should not attempt to estimate from pre-thoracoplasty films the extent of the resection required. It must be kept in mind that spread of the disease to adjacent segments may occur during and after thoracoplasty, and careful search must be made for such spreads before and at operation before undertaking a limited excision.

Usually, the scar of the previous thoracoplasty is excised and the chest cage exposed. The uppermost intact rib below the thoracoplasty is resected paravertebrally and the extrapleural plane entered through its bed. The bony plate above is cut paravertebrally and lifted away by a rib-spreader as the underlying lung is stripped from it extrapleurally to lessen the risk of opening into a cavity or diseased parenchyma.

The extrapleural dissection is continued over the mediastinal aspect of the lung to the hilum. In a pneumonectomy the main bronchus is freed, clamped, and cut at the carina, and the proximal

TABLE III
INDICATIONS FOR PULMONARY RESECTION FOR TUBERCULOSIS: 125 CONSECUTIVE CASES (1946-8)

Classification of Cases	No.
Thoracoplasty failure ...	12
Thoracoplasty and Schede failure ...	3
Thoracoplasty failure anticipated—	
Disease predominantly pulmonary:	
Destroyed lung ...	46
Destroyed lobe ...	19
Giant cavity ...	7
Partial lobar destruction with cavity ...	10
Rapidly progressive caseous-pneumonic disease	1
Tuberculoma ...	1
Disease predominantly bronchial:	
Tension cavity ...	5
Bronchostenosis and destroyed lung ...	1
Disease predominantly pleural:	
Destroyed lung and tuberculous empyema ...	10
Destroyed lung, bronchopleural fistula, and empyema ...	4
Disease unfavourably located ...	5
Emergency resection—	
Acute cavity rupture ...	1
Total ...	125

end closed. After the pulmonary artery and veins have been individually ligated, transfixed, and divided, the entire lung is freed extrapleurally and the lung and the pleura are removed from the chest together. An intercostal drainage tube is inserted, the bony plate is fixed by sutures, and the chest wall is closed in layers.

If a lobectomy is to be performed the lobar bronchus and vessels are isolated and divided extrapleurally at the hilum. It may be difficult to identify the fissures on the outer aspect of the lung because of dense pleural adhesions under the thoracoplasty. In such instances the interlobar fissures are usually entered more easily from the mediastinal or diaphragmatic aspects after these parts of the lung have been freed. The interlobar cleavage plane is also more easily delineated if, after the bronchus to the involved lobe has been clamped or cut, the anaesthetist inflates the remaining lung.

In a segmental resection the portion of the lung to be removed is separated from the adjacent structures by dissection in a peripheral direction without the use of clamps on the lung. After the bronchus to an involved segment has been isolated, divided, and the proximal end closed, the arteries are ligated and the veins which accompany the bronchus are ligated and divided. But the intersegmental veins which are to remain *in situ* are used as a guide to the cleavage plane for the separation of the segments. When the separation is done in this way only tiny air leaks from the parenchyma are encountered and they close rapidly. Likewise, the bleeding points from the intersegmental veins are easily controlled. It is not too difficult in this manner to remove the apico-posterior segment of the left upper lobe, leaving the anterior segment and the lingula, or to remove the anterior segment with the apical, leaving the lingula.

In lobectomy or segmental resection the parietal pleura which is intimately adherent to the diseased area is removed with it, but after the upper lobe or segment has been mobilized an incision is made through the less adherent pleura adjacent. The pleura which is to remain is put back in place (with a suture, if necessary) because its gliding and absorptive functions aid in prompt re-expansion of the remaining lung.

The remaining lung is freed completely by division of all adhesions; including

those on the under-surface of the lower lobe which may under-curl the edges of the lobe and actively constrict it even after the lobe has been otherwise freed. The pulmonary ligament is cut up to the level of the inferior pulmonary vein to permit the lower lobe to swing upwards to obliterate the pleural space. Anterior and posterior intercostal drainage tubes are placed and the chest wall closed.

Case 1 (Pneumonectomy after Failure of Thoracoplasty).—J.D., a man aged 30, had undergone a two-stage thoracoplasty for left upper lobe cavitory disease. A spread to the left lower lobe had occurred after the first stage and positive sputum persisted. Tomography finally revealed a new cavity in the left lower lobe, and pneumonectomy was performed uneventfully. The patient is completely well two years later.

Case 2 (Lobectomy after Failure of Thoracoplasty).—D.S., a woman aged 25, had undergone a right upper thoracoplasty for an apical cavity. Positive sputum persisted, and tomography revealed a residual cavity in the paravertebral gutter. Right upper lobectomy was performed uneventfully, and the patient is well two years later.

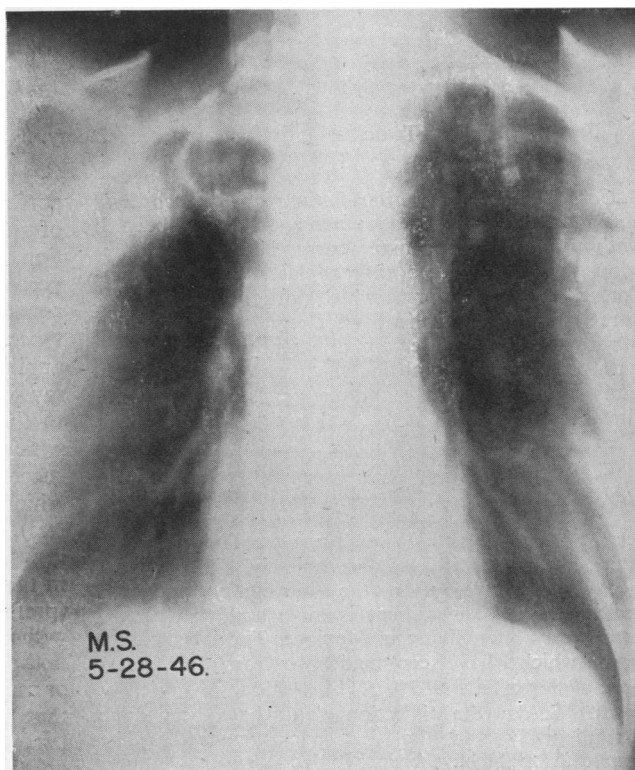


FIG. 1a (Case 3).—One year after right upper thoracoplasty and wax plombage. The fourth rib was not resected and the residual cavity is visible on tomography.

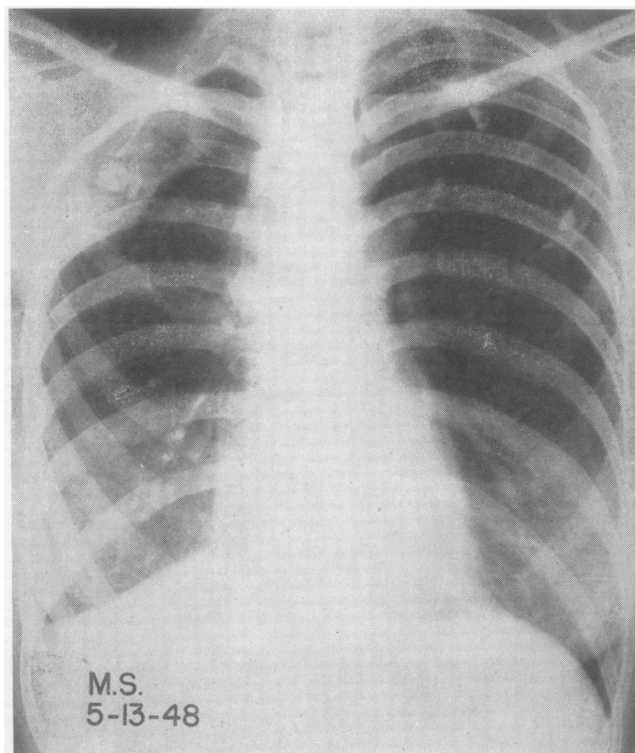


FIG. 1b (Case 3).—Two years after right upper lobectomy.

Case 3 (Lobectomy after Failure of Thoracoplasty and Plombage).—M.S., a woman aged 28, had been ill with tuberculosis for nine years. Nine months previously an inadequate thoracoplasty had been performed elsewhere, during which portions of the upper three ribs and the fifth rib were resected. The fourth rib was permitted to remain, apparently to support the extrapleural wax plombage which was placed apically and laterally. Positive sputum persisted. When I first saw her in 1946 a residual cavity was present in the right upper lobe (Fig. 1a). A right upper lobectomy was performed intrapleurally and the wax pack was not disturbed. The cavity was ruptured during the operation. A localized staphylococcus empyema resulted, but no fistula was present. The empyema was drained and it healed completely. The sputum became negative after the lobectomy and has remained so. The patient is alive and well almost three years later, living in Mexico. The latest radiograph which I have seen, made two years after operation, is shown in Fig. 1b. (This was one of my early cases. To-day the dissection would have been done extrapleurally and the wax pack removed. The empyema might have been avoided.)

Case 4 (Segmental Resection after Failure of Thoracoplasty).—F.R., a man aged 45, had had a left upper thoracoplasty in 1936. Ten years later his

sputum became positive again, and tomography revealed a small residual cavity under the thoracoplasty. A segmental resection of the left upper lobe, leaving the lingula, was performed in February, 1947. The sputum became negative at once. He is well and working full-time as a building engineer two years later.

I no longer perform Schede thoracoplasties for empyema complicating uncontrolled pulmonary tuberculosis, since this procedure has been rendered unnecessary by the extrapleural pneumonectomy and total pleurectomy. There are in tuberculosis institutions a number of cases of failures of cavity closure and chest-wall healing after Schede thoracoplasties. For these cases I proposed extrapleural pneumonectomy with resection of the residual pleura, excision of the chest-wall wound, and primary chest-wall closure (Sarot and Gilbert, 1947). This operation has been performed successfully and should be applied to salvage these patients.

THORACOPLASTY FAILURE ANTICIPATED

Until recently, because of the lack of alternative procedures, thoracoplasty was performed upon patients in whom the probability of success was considered poor before the operation. This was justifiable only because a small percentage of otherwise unobtainable good results was achieved. With the advent of several types of excisional procedures which may be applied safely, the indications for thoracoplasty must be more sharply defined. I have come to the point of reserving thoracoplasty for cases which seem to offer a strong likelihood of success: cold, chronic cases with a single cavity which is relatively small (diameter, 5 cm. or less), relatively thin-walled, with good surrounding parenchyma, not paravertebrally placed, and in the upper part of the lung away from the hilum (preferably in the outer two-thirds of the lung), without significant disease in the lower lobe and without residual apical pneumothorax or empyema or marked pleural thickening. It has been suggested that in almost all cases thoracoplasty should be performed first to achieve whatever successes may be obtainable with that procedure and subsequent excision performed to salvage the failures. While this may be good judgment in patients with disease largely limited to the upper lobe who might be

candidates for lobectomy, I cannot subscribe to this in patients with destroyed lungs. In general, in patients unsuitable for thoracoplasty, according to the already mentioned criteria, it seems unwise to incur the considerable risk of mortality, spread of the disease, or the not infrequent incidental extensive collapse of healthy and functioning lung. There are also a number of social, economic, and psychological factors which militate against thoracoplasty in cases in which there is little likelihood of success.

In the categories of cases outlined below, primary excision is to be preferred to thoracoplasty.

DISEASE PREDOMINANTLY PULMONARY

Case 5 (Destroyed Lung).—A.B., a man aged 44, had been ill with tuberculosis for one year. His right lung had been destroyed by caseous-pneumonic tuberculosis (Fig. 2a). Pneumonectomy was considered preferable to thoracoplasty because of the extensive destruction of the diseased lung; no contralateral cavitation was found on tomographic study. Function tests showed the pulmonary function to be adequate, and an intrapleural pneumonectomy (Fig. 2c) was performed on February 11, 1947. Some difficulty was encountered in the dissection due to matted hilar lymph nodes. Thoracoplasty was performed one month later. His sputum became negative immediately after pneumonectomy. The patient has remained well (Fig. 2b) and has returned to his home in Canada and his occupation of farmer.

Case 6 (Destroyed Lobe with Multiple Cavitation without Good Surrounding Lung).—V.R., a woman aged 20, when seen in September, 1946, was suffering from frequent haemoptyses and had been known, for one month, to have pulmonary tuberculosis. She was febrile on admission, but became afebrile soon after induction of a right pneumothorax one month later. Closed pneumonolysis in November and December, 1946, did not substantially improve an unsatisfactory collapse; the cavity in the right upper lobe became larger and the sputum remained highly positive. Pulmonary function tests showed adequate respiratory capacity. After a short course of streptomycin, which diminished the volume of the sputum considerably, a pneumonectomy was performed on June 17, 1947. Her sputum became negative at once, and she has remained well and is leading a fully active life.

Case 7 (Giant Cavity).—W.V., a man aged 23, had been ill with tuberculosis for six years; an ineffective right pneumothorax

had been abandoned after a short time in 1942. When seen in 1947 he had a giant cavity in the right lung. Extrapleural pneumonectomy was performed, followed by one-stage thoracoplasty of the second to seventh ribs, inclusive, two weeks later. The sputum became negative promptly after pneumonectomy. The patient is alive and well one year later and is employed as a ship's purser.

In cases where there is partial lobar destruction and a persistent cavity it is difficult to decide between thoracoplasty and lobectomy because most of these cases are reasonably suitable for either operation. The presence of multiple cavitations, apical pleural thickening, extensive pericavitary fibrosis, or low paravertebral location of the cavity should influence the decision toward excision.

If an extensive thoracoplasty, which will incidentally collapse much healthy lung, is considered necessary for an unfavourably placed or possibly poorly collapsible lesion, lobectomy is preferable as a means of conserving lung function (Churchill and Klopstock, 1943). This principle is particu-

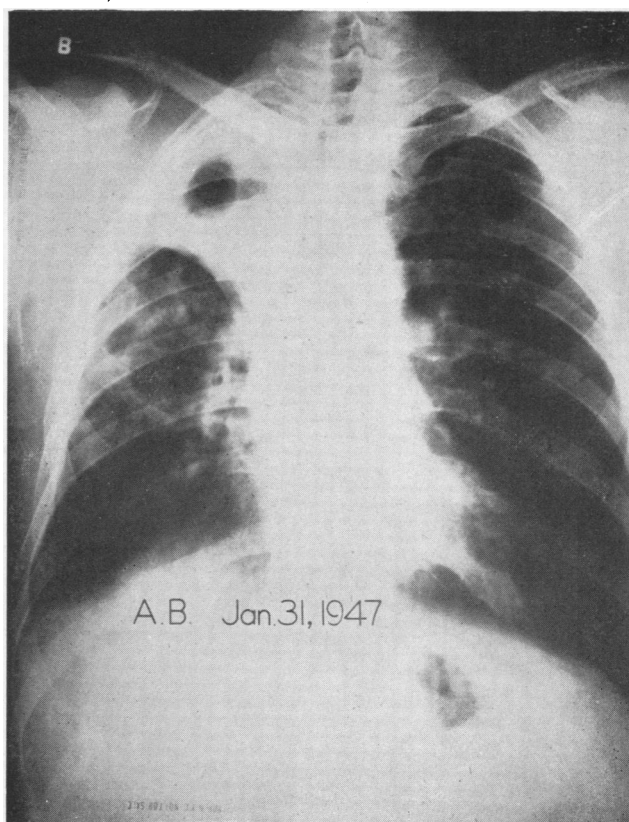


FIG. 2a (Case 5).—Right lung destroyed by tuberculosis.

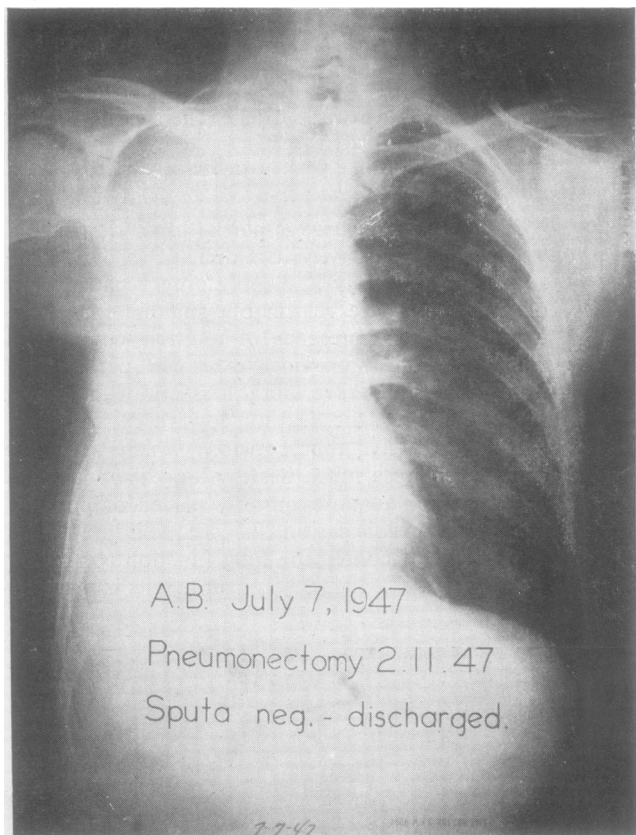


FIG. 2b (Case 5).—At discharge from the hospital six months after right pneumonectomy.

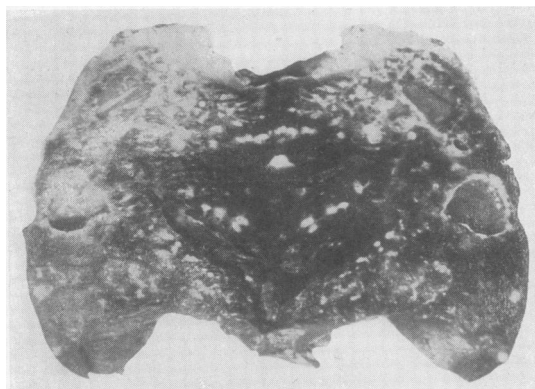


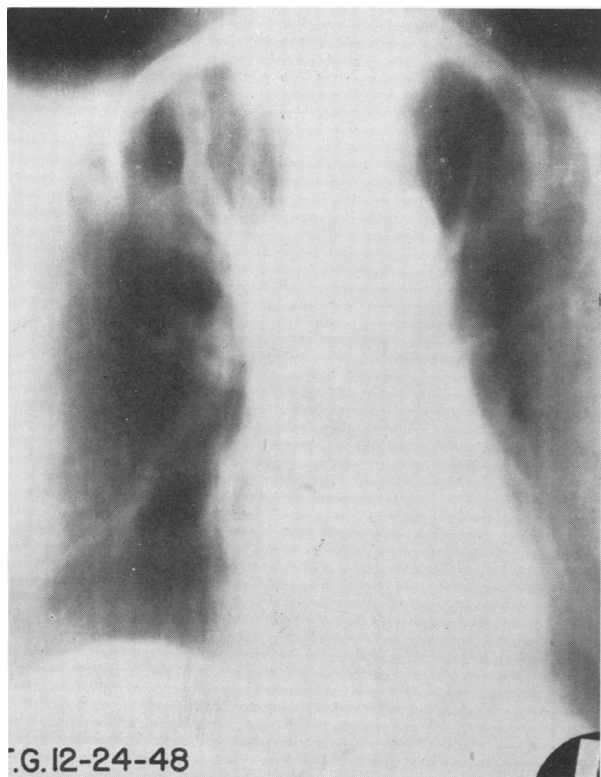
FIG. 2c (Case 5).—Cut surface of the resected lung showing the extensive destruction.

larly applicable to cases in which impairment of respiratory function is evident. Thoracoplasty, by its fixation of the chest wall, tends to diminish ventilation.

Case 8 (Partial Lobar Destruction with Fibrosis and Cavity).—T.G., 41 years old and the wife of a physician, had a left pulmonary lesion, apparently non-cavernous, discovered following a haemoptysis at the age of 16 years. Healing took place after a period of bed rest. A cavity appeared in the left upper lobe when she was 23 years old and pneumothorax was induced in Switzerland. The pneumothorax obliterated spontaneously after two years, and the patient had only an occasional positive sputum, the last in 1935. She remained under the care of a most competent phthisiologist in the United States, married, and was permitted to bear a child in 1943. Repeated radiographs of the chest were considered negative and only rare sputum examinations were made, all negative. In September, 1948, a respiratory illness appeared, first diagnosed as a "virus" infection because no localizing signs were found and radiographs of the chest showed no change. However, the sputum was found to contain tubercle bacilli, and lordotic and tomographic films (Fig. 3a) showed a multilocular (or multiple) cavity in the right upper lobe. Careful tomographic examination of the previously collapsed left lung failed to reveal any cavitary foci. Lateral tomography revealed a circumscribed dense focus in the apical segment of the right lower lobe. A curved line in the lateral tomogram (Fig. 3b) was interpreted as the short fissure which was drawn apically by the shrinkage of the fibrous and cavitary right upper lobe.

Because of the character of the lesion in the upper lobe and because of the associated fairly large focus in the apical segment of the lower lobe, lobectomy and segmental resection was preferred to an extensive thoracoplasty, especially in view of the old, controlled disease in the left lung. Conservation of healthy functioning lung was deemed to be particularly important in this case. Thoracotomy was undertaken with the agreement of all concerned that if, when the chest was opened, any unusual technical difficulties were encountered which might render the resection hazardous, it would be closed and the patient subjected to thoracoplasty at a later date. However, no difficulties arose, and an upper lobectomy and lower lobe apical segmental resection were performed in January, 1949 (Fig. 3d). The post-operative course was uneventful and the sputum became negative at once. The middle lobe and the remainder of the lower lobe expanded rapidly to fill most of the thoracic space. The residual pocket of bloody fluid at the apex has slowly been absorbed in the past few months (Fig. 3c).

In contrast, in other cases the coexistence of moderately extensive infiltrative disease in the



3a (Case 8).—Tomograph demonstrating multilocular or multiple cavitations in right upper lobe.

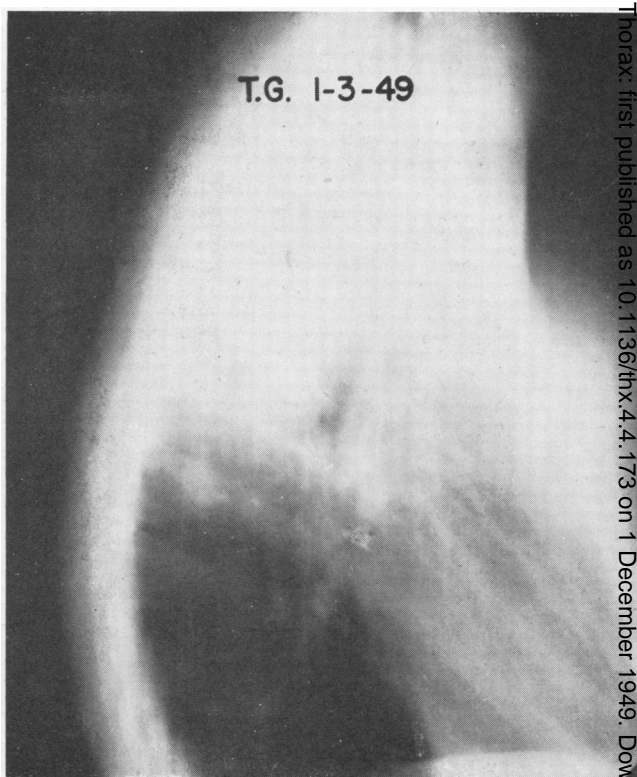
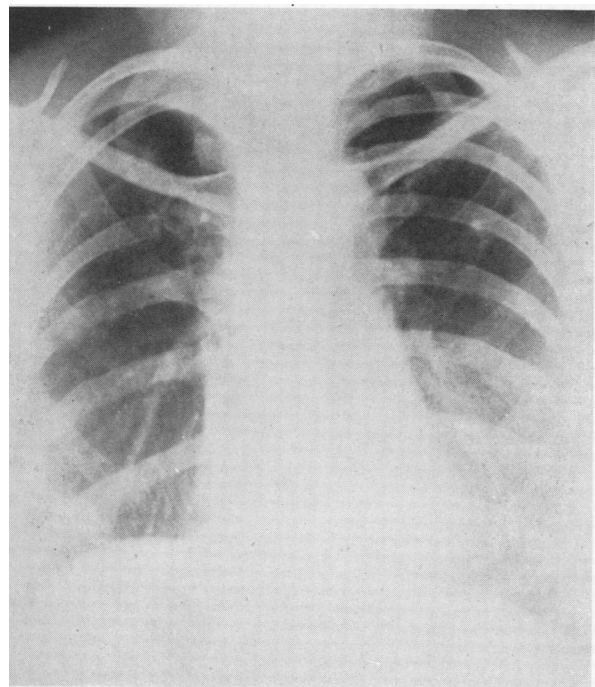


FIG. 3b (Case 8).—Lateral tomograph demonstrating apical cavitation, retraction of the upper lobe, and the focus of disease in the apical segment of the lower lobe.



3c (Case 8).—Approximately four months after resection of right upper lobe and superior (apical) segment of right lower lobe.

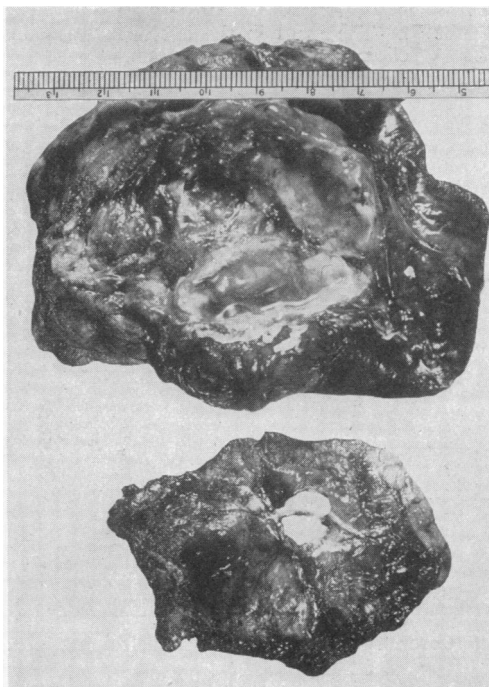


FIG. 3d (Case 8).—Right upper lobe is fibrotic and shrunken and contains a multilocular cavity. The smaller specimen is the apical segment of lower lobe, shown to contain an area of caseous tuberculosis.

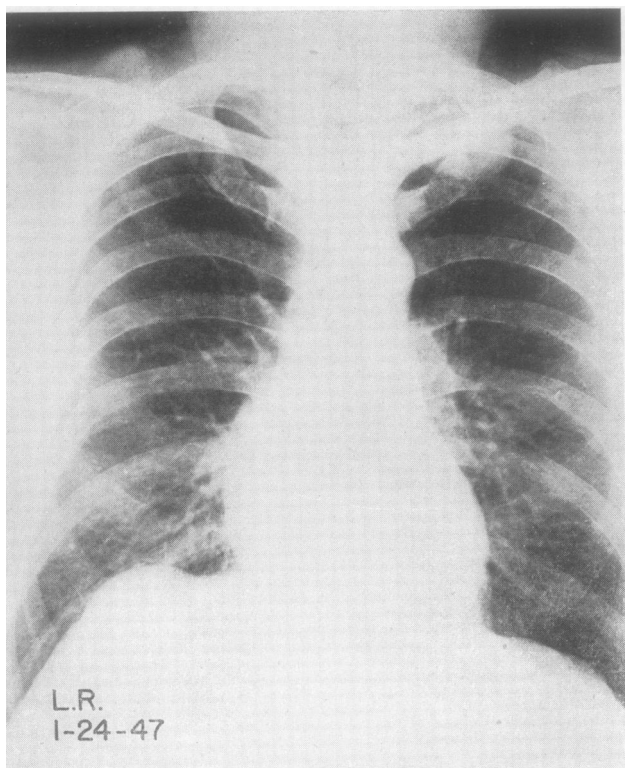


FIG. 4a (Case 9).—The mass in the left apex was considered clinically to be a neoplasm.

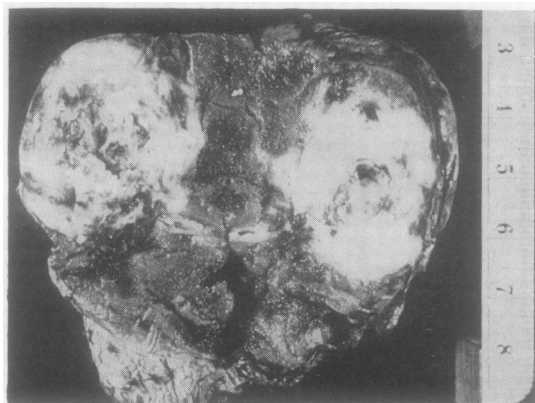

FIG. 4b (Case 9).—Tuberculoma of the left upper lobe.

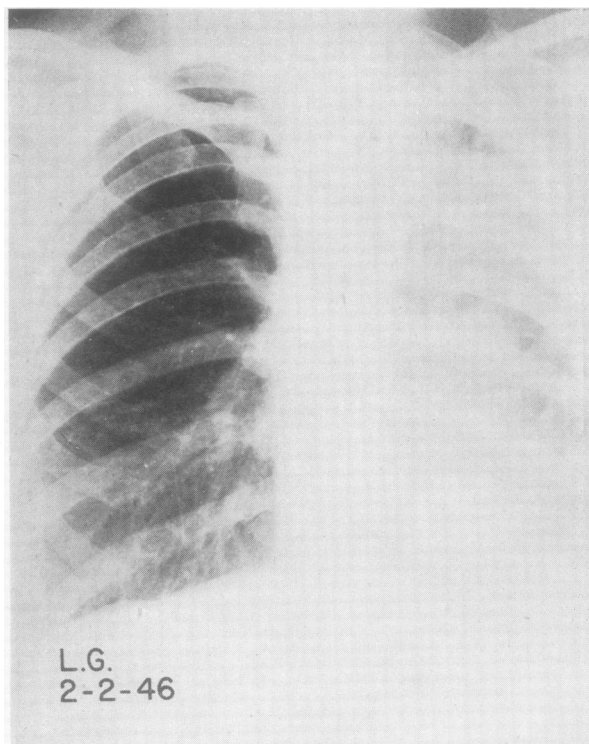


FIG. 5a (Case 10).—Re-expanded left lung with rounded shadow visible in mid-field.

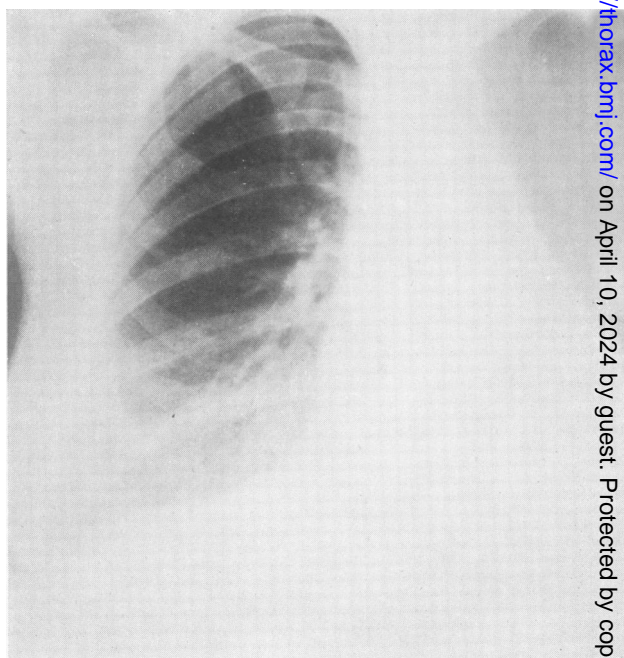


FIG. 5b (Case 10).—Two years following left pneumonectomy.

lower lobe may make thoracoplasty preferable to the pneumonectomy which would be required.

Rapidly progressive caseous disease, including progressive primaries and caseous lobar pneumonia, should, in my opinion, frequently offer indications for excision. I can remember such cases before the present period of excisions when I wished I were able to remove such disease before the fatal termination from extensive spreads and toxæmia. Recently Bailey (personal communication) successfully performed a pneumonectomy on a 2-year-old child for a caseous lobar pneumonia following the perforation of a caseous node into a bronchus.

Tuberculomas, or masses of conglomerate tubercle, frequently are difficult to differentiate from neoplasms and may require removal for this reason. The presence of calcification in the centre of the nodular shadow indicates that we are dealing with a tuberculoma rather than a neoplasm. The calcification may not be visible on ordinary radiographs or even those made with the aid of the Bucky diaphragm but can be demonstrated by means of tomography (Rabin, 1947). Lobectomy or segmental resection is to be preferred for these lesions at the time of exploration. If examination of the specimen reveals a neoplasm, more complete pulmonary resection with hilar dissection may be performed at the same operation after the pathologist has given his report.

Rabin (personal communication) believes that the tuberculomas which show central calcification or lamellation may safely be permitted to remain, especially when not too large, since, in his extensive experience, they rarely, if ever, break down. However, inspissated cavities, which are frequently mis-called tuberculomas, are an indication for resection because of their tendency to reopen.

Case 9 (Tuberculoma).—L.R., a man aged 42, shortly after his business partner had suffered an acute coronary thrombosis, became conscious of pain in the right arm. This symptom proved to be unimportant, but physical examination did reveal one enlarged left cervical lymph node, and on radiography (Fig. 4a) a sharply circumscribed mass about 5 cm. in diameter was found in the left upper lobe. The sputum was negative for tubercle bacilli. The cervical node was removed and showed no evidence of disease. In February, 1947, a left upper lobectomy was performed and the lesion was reported to be a tuberculoma (Fig. 4b). The patient is well two years later.

Case 10 (Inspissated Cavity and Bronchiectasis).—L.G., a woman aged 35, two years following re-expansion of a pneumothorax which had been instituted for a mid-zone cavity and maintained for three years,

began to suffer from occasional small haemoptyses. Sputum was negative for tubercle bacilli, but radiographic examination revealed a circumscribed dense shadow in the region of the previous cavity (Fig. 5a). Bronchoscopy revealed some narrowing and shortening of the left main bronchus, but no gross endobronchial lesion. Left extrapleural pneumonectomy and subsequent thoracoplasty were performed in September, 1946, and the patient has remained well (Fig. 5b).

The resected lung (Fig. 5c) showed slight bronchiectasis of the left upper lobe and a circumscribed mass containing inspissated caseous material in the sub-apical portion of the lower lobe. A small bronchus leading to the mass was occluded, and the microscopist found evidence of tuberculosis in its wall.

DISEASE PREDOMINANTLY BRONCHIAL

Inspissated cavities, such as in Case 10, may belong to this category because of the involvement of the small bronchus. Tension cavities are the product of a valvular mechanism in a diseased bronchus. Treatment by pneumothorax, supplemented if necessary by pneumonolysis, may control many of them, but when this is not possible thoracoplasty, even according to the most favourable reports (Maier, 1949), does not control more than about 60%. In addition, the very extensive thoracoplasty which may be required to close a small cavity collapses a large amount of undiseased and functioning lung, and operative spreads following thoracoplasty are frequent in this type of case.

If a small, round, "blinking" cavity is present in the apical or lateral portion of the upper lobe, a localized thoracoplasty may suffice. For larger cavities and those disadvantageously placed, excision is preferred.

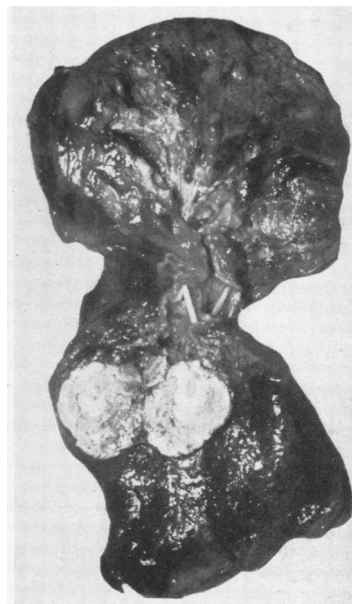


FIG. 5c (Case 10).—Lower lobe contains a cavity filled with inspissated tuberculous material. Bronchiectasis of upper lobe branches is present.

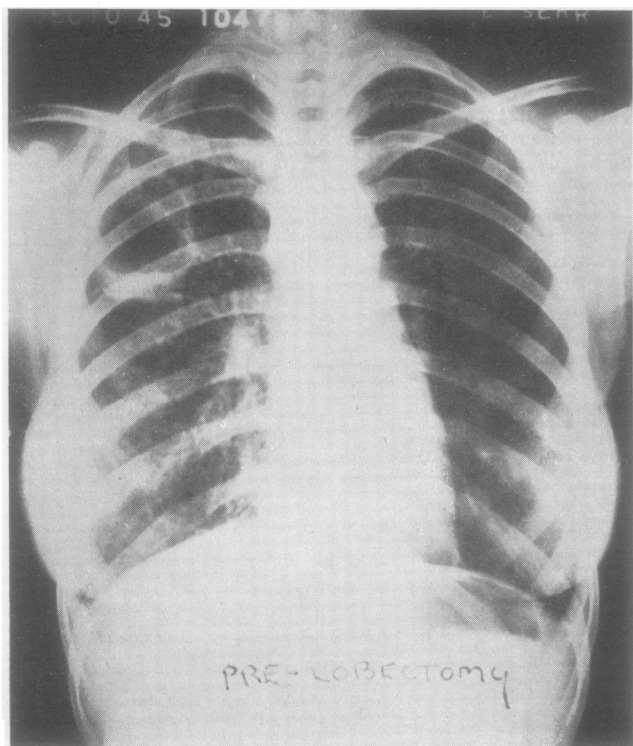


FIG. 6a (Case 11).—Tension cavity in right upper lobe; nodular disease in remainder of right lung.

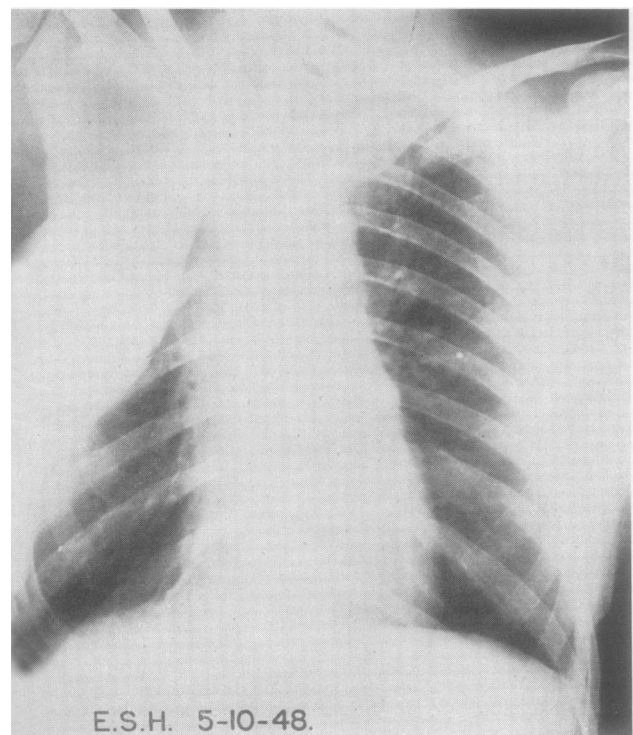


FIG. 6c (Case 11).—Two years later: right side has healed, but round cavity is visible in left upper lobe under anterior end of first rib.

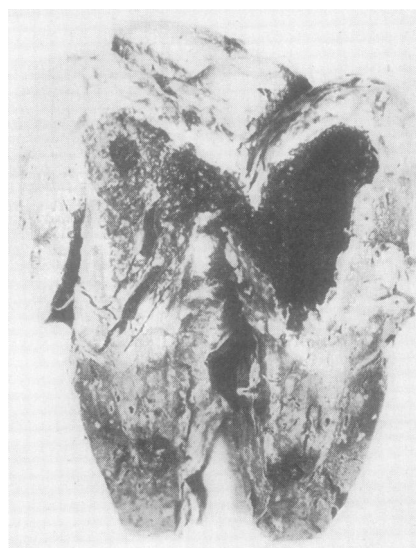


FIG. 6b (Case 11).—Resected right upper lobe exhibiting a large cavity.

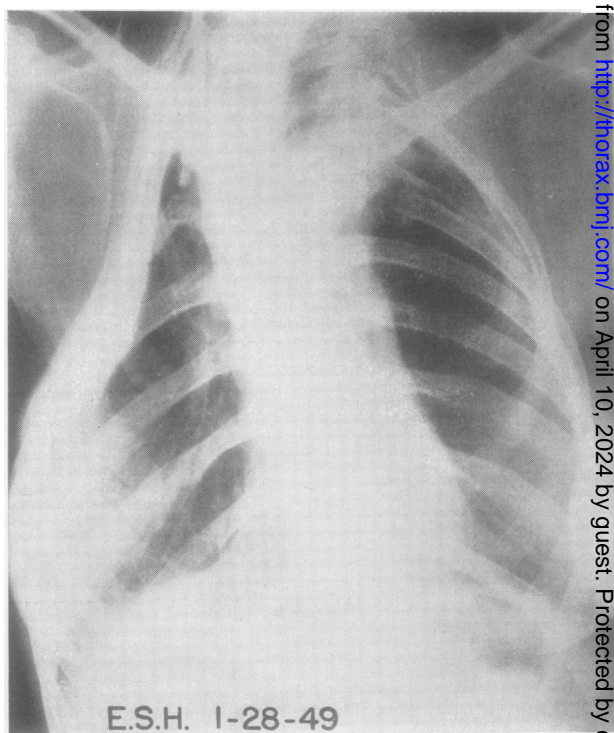


FIG. 6e (Case 11).—Approximately six months following apico-posterior segmental resection.

Case 11 (Large Tension Cavity).—E.S.H., a girl aged 17, had been ill with tuberculosis for 18 months. A left pneumothorax had been present previously but had been abandoned, and when I first saw her the left lung contained only small, non-cavitary, nodular foci. A right pneumothorax had been induced, but collapse was unsatisfactory and could not be improved by closed pneumonolysis. A large tension cavity was present in this lung (Fig. 6a). Intracavitary pressures were measured and found to be +4 cm. of water on inspiration and +6 on expiration. A right upper lobectomy was performed (Fig. 6b) on April 2, 1946, followed by an upper thoracoplasty on May 14, 1946. Early in 1948, after her sputum had been negative almost two years, the patient developed a small localized wound infection in the scar. No bronchopleural fistula could be demonstrated and the wound healed slowly, but she was found to have a positive sputum and a cavity, *also of tension type, in the left upper lobe* (Fig. 6c). Attempts at pneumothorax were unsuccessful, and on November 2, 1948, the cavity-bearing segment of the left upper lobe was excised; the lingula and anterior segment were permitted to remain (Fig. 6d). The patient's sputum has become negative and she is soon to be discharged from hospital (Fig. 6e).

Stenosis of moderate degree of a main or lobar bronchus unaccompanied by symptoms of pulmonary suppuration is not an indication for resection, and the parenchymal tuberculosis of the lung may be treated by thoracoplasty if the case is otherwise suitable. Suppuration in the lung beyond a blocked bronchus, as evidenced by repeated pneumonic episodes or haemorrhages, is an indication for excision. If a lung collapsed by pneumothorax and unexpandable because of bronchostenosis is secondarily involved by a suppurative process, resection is indicated. If the

pleura has become involved, extrapleural pneumonectomy and total pleurectomy are indicated.

If an endobronchial active tuberculous lesion is present, the excision should be planned at the time of maximal benefit from the streptomycin.

The demonstration of bronchiectasis by bronchography, especially in the upper lobe after thoracoplasty, is not *per se* an indication for resection if the only symptoms are cough and the production of a small or moderate amount of negative sputum. If the sputum is positive for tubercle bacilli or if haemoptysis is troublesome or severe, resection of all or part of the lung is indicated.

DISEASE PREDOMINANTLY PLEURAL

The disappointing results obtained by all forms of surgical collapse therapy for uncontrolled pulmonary tuberculosis complicated by tuberculous empyema (with or without bronchopleural fistula) are part of the experience of every thoracic surgeon. One cannot fail to be impressed, even in the successful cases, by the long period of surgical treatment that these patients undergo, yielding only meagre results with much misery and great skeletal deformity.

The occurrence of a bronchopleural fistula and the subsequent mixed-infection empyema is an immediate threat to the life of the patient. Most surgeons have shown their awareness of the gravity of this complication in their repeatedly stressed admonitions to proceed as quickly as possible from simple drainage to thoracoplasty. If the treatment is not rapid and complete, the swift deterioration of the physical condition of such patients is well known. Drainage of the infected pleural space, by itself, is useless since the pulmonary disease remains uncontrolled and the caseous infected pleura remains *in situ*.

An analysis of the experience at Sea View Hospital (Davidson, 1941) revealed that of 125 cases of pulmonary tuberculosis with mixed-infection empyema treated surgically, 79, or 63.2%, died. Of the surviving 46 patients, only 14 were cured; 31 remained with draining chest-wall sinuses, broncho-pleuro-cutaneous fistulae, and granulating wounds. The skeletal deformities which resulted even in the healed cases were usually severe and frequently appalling. Berry (1932) reported 74 cases and noted a mortality of 56%. Woodruff (1938) mentioned a mortality rate of 59.5% in a series of 42 cases. These figures are not unusual; results would seem to be similar in all clinics. Any treatment in the course of which two of every three patients die is inadequate, to say the least.

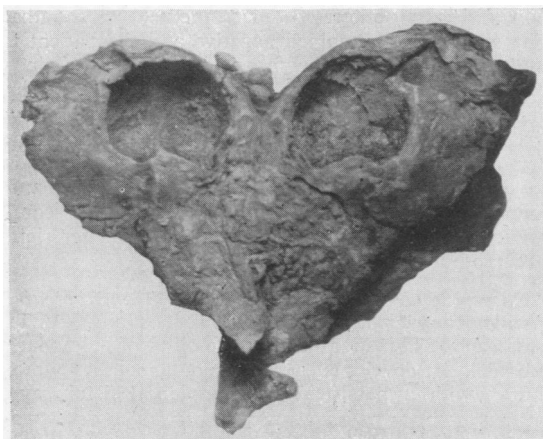


FIG. 6d (Case 11).—Resected apico-posterior segment of left upper lobe containing a large cavity.

Furthermore, these figures present an optimistic picture since many patients die of toxæmia and exhaustion or generalized amyloidosis before surgical treatment has been attempted. Frequently, spreads of the tuberculosis to the contralateral lung obviate surgical therapy. In other cases, although the disease is unilateral, cavitation in the diseased lung is so complete that thoracoplasty is withheld because of its probable failure.

Throughout the long, painful, and crippling surgical treatment the patient is always liable to spread of the disease into hitherto healthy lung and to persistent toxæmia and exhaustion. In the Sea View Hospital series 30 patients died during the various stages of thoracoplasty. Of the 56 patients who survived the thoracoplasty to reach the stage of pleural resection, 10 died thereafter. This extreme form of surgical therapy has seemed justified until the present time because it offered patients the only small remaining possibility of cure.

The results mentioned above were the final products of drainage, subsequent complete thoracoplasty, Schede or Keller resection of the infected parietal pleura, and, where necessary, plastic operations, such as muscle-flap transplants to close the persistent bronchopleural fistula. The disaster which followed so frequently was inherent in each case by virtue of the underlying disease which remained to contaminate the surgical field and to destroy the transplanted tissues. Even if the bronchopleural fistula heals, caseating infected pleura (both parietal and visceral) remains after Schede thoracoplasty and is a frequent cause of the dissolution and ultimate non-healing of the wounds.

Analysis of all available experience with thoracoplasty in the treatment of uncontrolled pulmonary tuberculosis complicated by empyema indicates that the failure of this approach is due to several unavoidable deficiencies: (1) multiple operative procedures with increased opportunity for operative mortality; (2) prolonged duration of treatment inviting mortality from tuberculous spreads, toxæmia and exhaustion, and amyloidosis; (3) failure to control the underlying lung disease; (4) the deleterious effect on wound-healing of the residuum of infected caseating pleura; (5) the frequent inability to control the bronchopleural fistula. Therefore, any procedure designed to meet the problem of uncontrolled pulmonary tuberculosis and empyema must be (a) single stage, (b) of short overall duration, and (c) must control the underlying lung disease, the infected

caseous pleura, and the bronchopleural fistula (if one is present).

It thus becomes apparent that in order to cure a patient with uncontrolled pulmonary tuberculosis and a tuberculous or mixed-infection empyema, one must accomplish the removal, *en masse*, of the underlying diseased lung, the bronchopleural fistula, if one is present, and the entire infected, caseating parietal and visceral pleura. The operation required is an extrapleural pneumonectomy and total pleurectomy (Sarot and Gilbert, 1947). I had been considering the possibility of such a planned procedure for some time before the following case presented itself. It was only after the successful result in this case that I was able to proceed with the planned operations in Cases 13 and 14. I now have had favourable experience with this procedure for several years.

Case 12 (Destroyed Lung with Tuberculous Empyema).—C.A., a woman aged 26, had been treated by a pneumothorax for tuberculosis of her left lung from 1937 to 1939. The disease recurred in 1943, and an avulsion of the left phrenic nerve was done in 1944, without subsequent improvement. When she was first seen at Sea View Hospital in 1946, radiographs revealed a destroyed left lung and a cavity in the right lung (Fig. 7a). A right pneumothorax was induced and an adhesion cut to establish an adequate pneumothorax. One year later (Fig. 7b), pulmonary function having been tested and found adequate, left pneumonectomy was advised in preference to thoracoplasty. At operation on April 1, 1947, an unsuspected tuberculous empyema was entered. Extrapleural pneumonectomy and total pleurectomy were performed (Fig. 7c) and seven weeks later a one-stage resection of the upper five ribs with vertical division of the intercostal structures. The entire post-operative course was uneventful, but the right pneumothorax slowly became obliterated during the next six months. The sputum has remained negative and the patient is well two years after pneumonectomy. She has since been married and has been pregnant three times. The first two pregnancies were interrupted, but she is now six months pregnant and it is for this reason that her right diaphragm is high (Fig. 7d).^{*} There is no clinical evidence of pulmonary insufficiency, and function tests show practically no change in comparison with the results before induction of her right pneumothorax.

Case 13 (Destroyed Lung with Bronchopleural Fistula, Empyema, and Open Thoracostomy).—A.T., a man aged 23, six months after the onset of pulmonary tuberculosis, developed a right spontaneous pneumothorax with a persistent bronchopleural fistula and

^{*}On July 15, 1949, this patient was delivered of an 8 lb. 6 oz. baby girl by caesarean section under spinal anaesthesia, and then sterilized, by Dr. Emanuel E. Klempner. Mother and daughter are well.

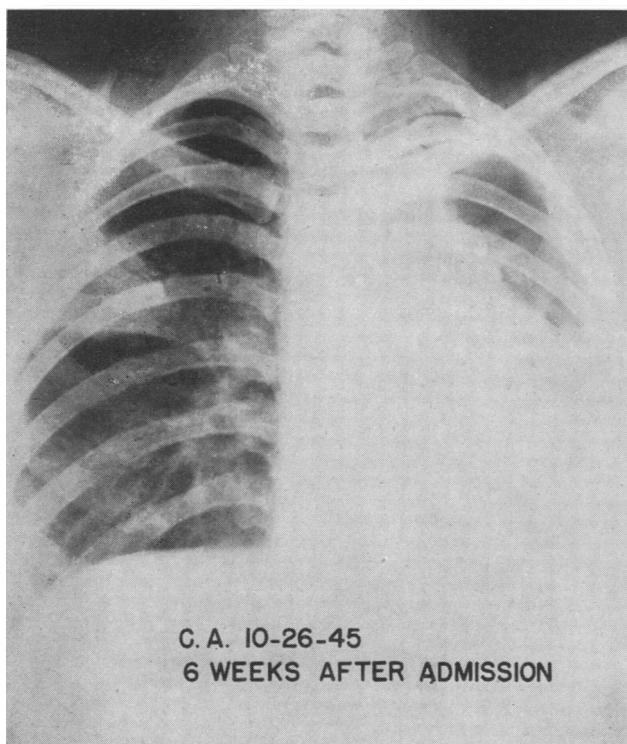


FIG. 7a (Case 12).—Destroyed left lung; contralateral active cavitory disease.

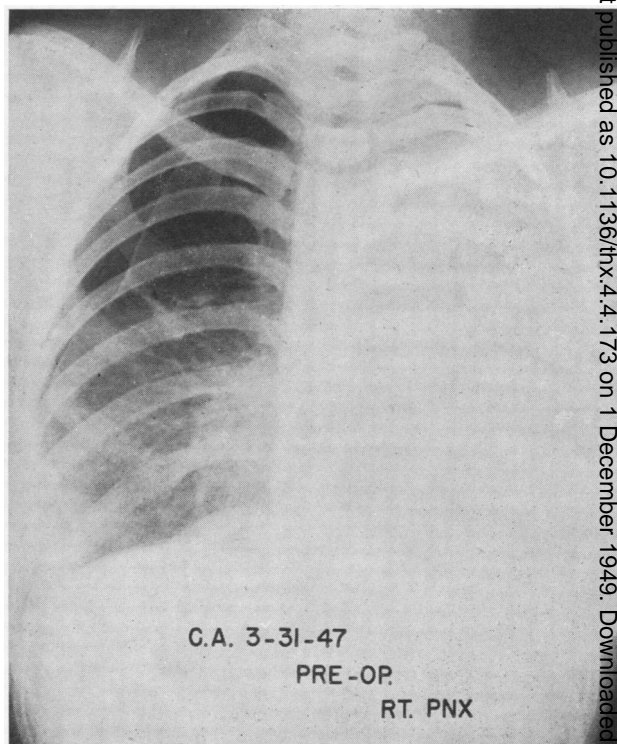


FIG. 7b (Case 12).—Approximately one year after induction of right pneumothorax and performance of a closed pneumonolysis.

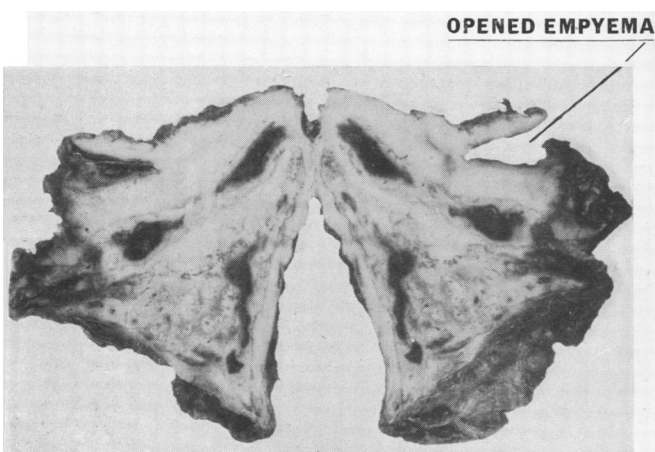


FIG. 7c (Case 12).—Resected specimen demonstrating the destroyed lung and empyema.

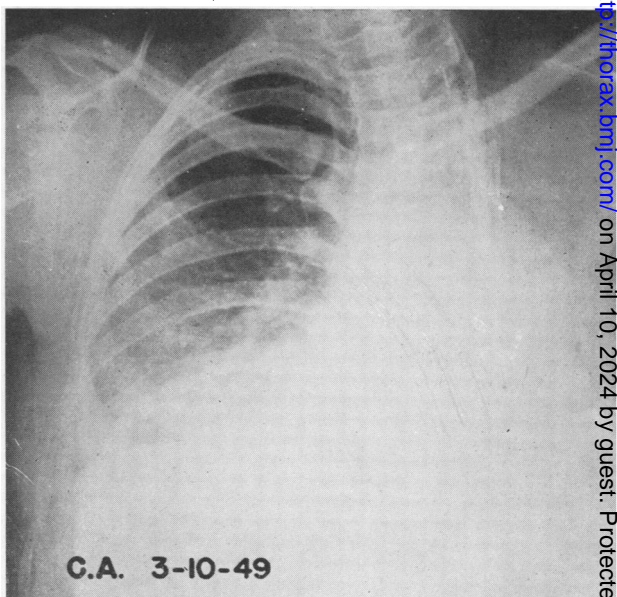


FIG. 7d (Case 12).—Two years after left pneumonectomy, pleurectomy, and thoracoplasty for destroyed lung and empyema, presence of contralateral pneumothorax. Right diaphragm is high because patient is six months gravid.

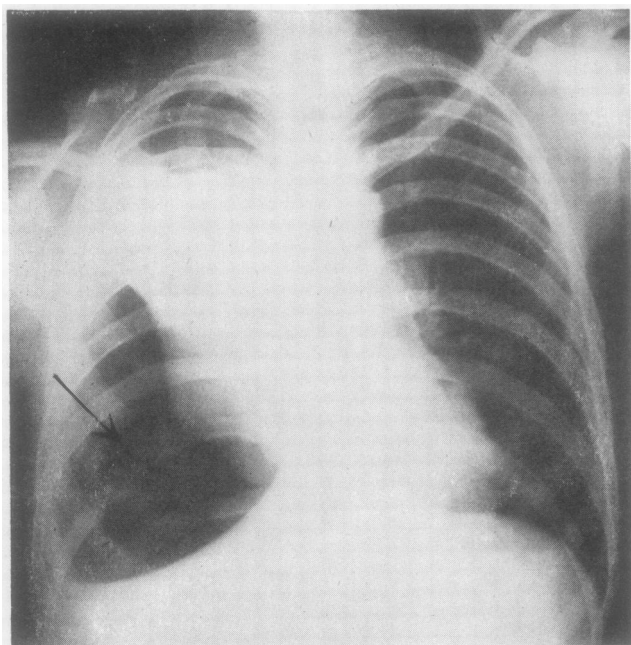


FIG. 8a (Case 13).—After thoracostomy for bronchopleural fistula and mixed-infection empyema.

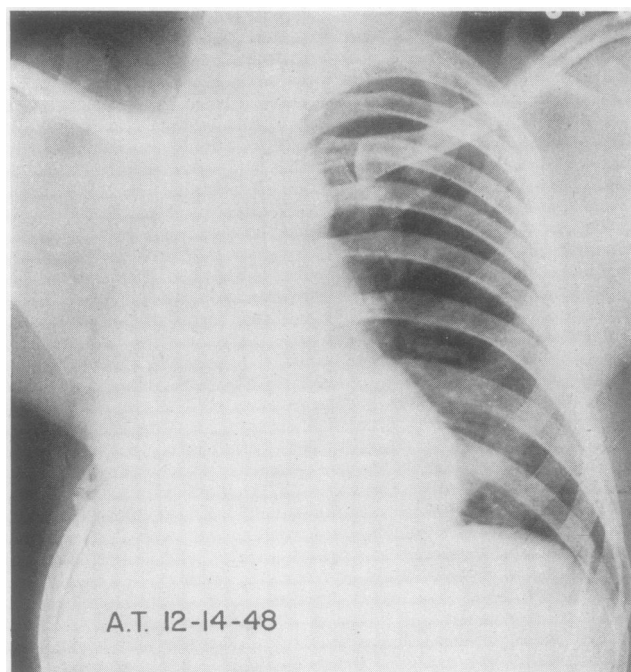


FIG. 8d (Case 13).—Almost two years after right pneumonectomy, total pleurectomy, and thoracoplasty for pulmonary tuberculosis, bronchopleural fistula, and mixed-infection empyema.

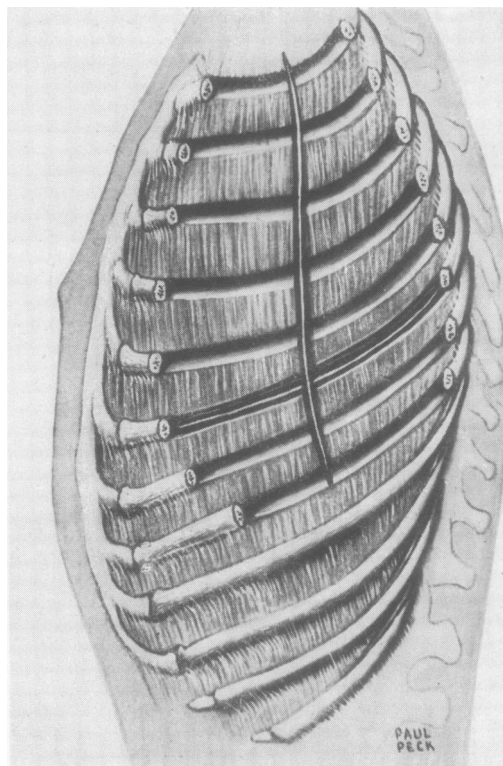


FIG. 8b (Case 13).—Sketch illustrating incisions for extrapleural and intercostal tissues to permit flaps to obliterate the thoracic space.

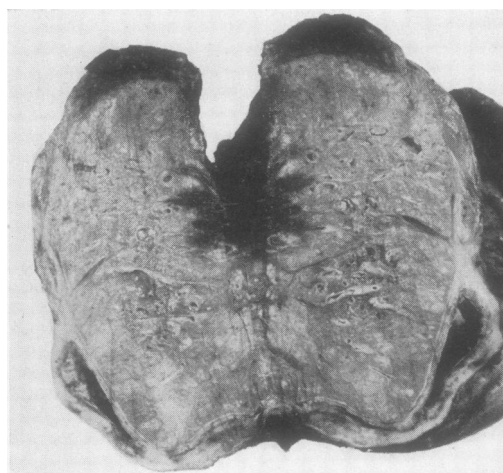


FIG. 8c (Case 13).—The lung, empyema cavity, and parietal pleura have been removed by extrapleural pneumonectomy and total pleurectomy.

mixed-infection empyema. After rib resection and thoracotomy for drainage (Fig. 8a), parenteral and local treatment with penicillin and streptomycin were instituted and seven weeks later, on May 8, 1947, right extrapleural pneumonectomy and total pleurectomy were performed. The thoracotomy wound was excised and the space closed by suture of the surrounding tissues. The patient's sputum became negative at once. Despite the fact that small bits of infected pleura remained on the diaphragm, no empyema developed. Penicillin and streptomycin (in buffered phosphate solution, pH 7.35, to enhance the effect of the streptomycin) were injected "intrapleurally," daily. At intervals of four weeks a posterior and then an anterior thoracoplasty of the upper eight ribs was performed. In the posterior thoracoplasty a vertical incision was made through the intercostal structures to allow two flaps to fall in as an aid in obliteration of the space (Fig. 8b). Specimens of the tissue lining the "pleural" cavity taken at the time of the thoracoplasty were described as "fibrous tissue containing tubercle-like structures with no caseation or organisms."

Fig. 8c shows the lung and thickened visceral and parietal pleural walls of the empyema. In some areas the pleural layers measure as much as 1 cm. in thickness.

A small localized wound infection, residual from the chest wall infection coincident with the pre-operative thoracostomy, healed after incision and drainage. The patient was discharged from the hospital six months after thoracoplasty and has remained well two years since operation (Fig. 8d). His wounds have remained healed and his sputum has been negative.

The next case was done without preliminary thoracostomy. The thoracoplasty stages were performed at shorter intervals to facilitate the collapse by minimizing the degree of fibrosis of the extrapleural tissues.

Case 14 (Destroyed Lung, Bronchopleural Fistula, and Mixed Infection Empyema).—G.H., a man aged 24, had been ill with pulmonary tuberculosis for one year. For five months he had had an unsuccessful pneumothorax complicated by a tuberculous empyema. Oxygen lavages of the pleura had been performed to help to re-expand the lung. The patient suddenly developed an acute perforation of the lung with a persistent bronchopleural fistula and mixed-infection empyema (Fig. 9a). An extrapleural pneumonectomy and total pleurectomy were performed on June 13, 1947, and Fig. 9c shows the removed lung and pleural sac. Parenteral and "intrapleural" antibiotic treatment was instituted, and at two-week intervals a posterior and then an anterior thoracoplasty were performed with vertical division of the intercostal tissues. The wounds healed *per primam*. Sputum has been persistently negative since the pneumonectomy. The patient was discharged from the hospital six months after thoracoplasty and

has remained well (Fig. 9b) one and one-half years since operation, with negative sputum and a well-healed wound (Fig. 9d).

Tchertkoff and Selikoff (1947) have collected 14 consecutive cases of extrapleural pneumonectomy and total pleurectomy for uncontrolled pulmonary tuberculosis and mixed-infection or tuberculous empyema which were operated on at Sea View Hospital in the past one and one-half years. With four additional cases upon which I have operated since, *the series totals 18 consecutive cases in which there was no operative mortality*. No empyemas developed post-operatively, despite the fact that the empyema was entered and the extrapleural space contaminated during operation in 16 cases. No post-operative bronchial fistulae developed. In two cases slight temporary bronchial stump openings were suspected clinically, but no empyema developed and both patients became well, with negative sputa. All 18 patients have had persistently negative sputa from the time of pneumonectomy and have remained well. Only one wound infection occurred (Case 13, above) and that patient had had a previous thoracostomy which had resulted in widespread infection of the tissue planes of the thoracic wall. This continued after operation in a localized fashion but ultimately healed. All wounds have remained healed.

The sooner the thoracoplasty is performed after the pneumonectomy, the less thickening of the tissues can occur and the more prompt is the closure of the space. The posterior thoracoplasty has usually been performed about two weeks after the pneumonectomy, and at this stage the extrapleural and intercostal tissues are usually incised in the mid-axilla vertically to form two flaps which fall in and help to obliterate the space (Fig. 8b). The anterior thoracoplasty follows two weeks later. Large stages of thoracoplasty may be performed without any great danger in these cases because the thickening of the extrapleural tissues which occurs in the period following the pneumonectomy is sufficient to stabilize the mediastinum and prevent mediastinal flutter. In several recent cases the entire thoracoplasty has been performed in one stage; however, I do not advocate this as a routine.

In the past two years I have not treated any case of destroyed lung and empyema by Schede thoracoplasty. Extrapleural pneumonectomy and total pleurectomy has been preferred and has proved most satisfactory.

The pathologist's examination of several of the lungs which had been removed revealed a surprisingly localized and limited amount of active

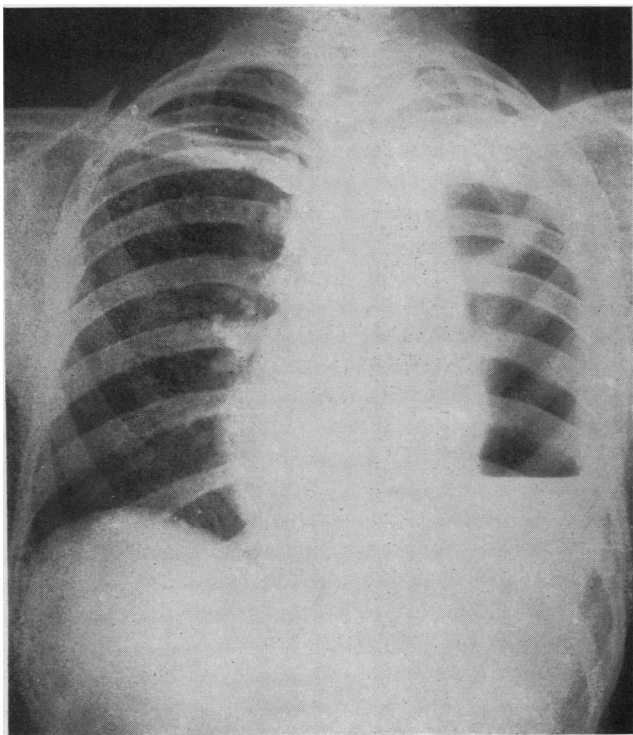


FIG. 9a (Case 14).—Uncontrolled left pulmonary tuberculosis with bronchopleural fistula and mixed-infection empyema.

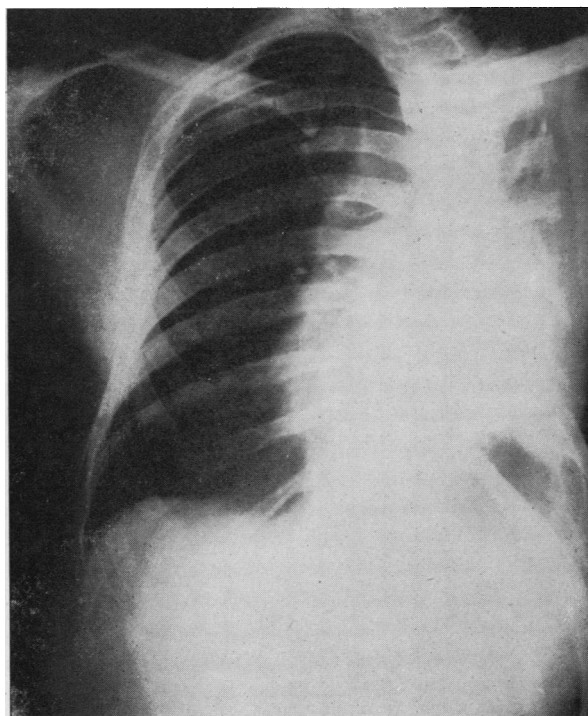


FIG. 9b (Case 14).—Six months after extrapleural pneumonectomy, total pleurectomy, and thoracoplasty.

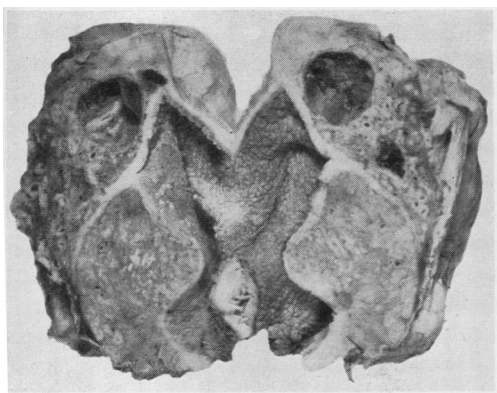


FIG. 9c (Case 14).—Lung, empyema, and parietal pleura have been removed *en bloc*.

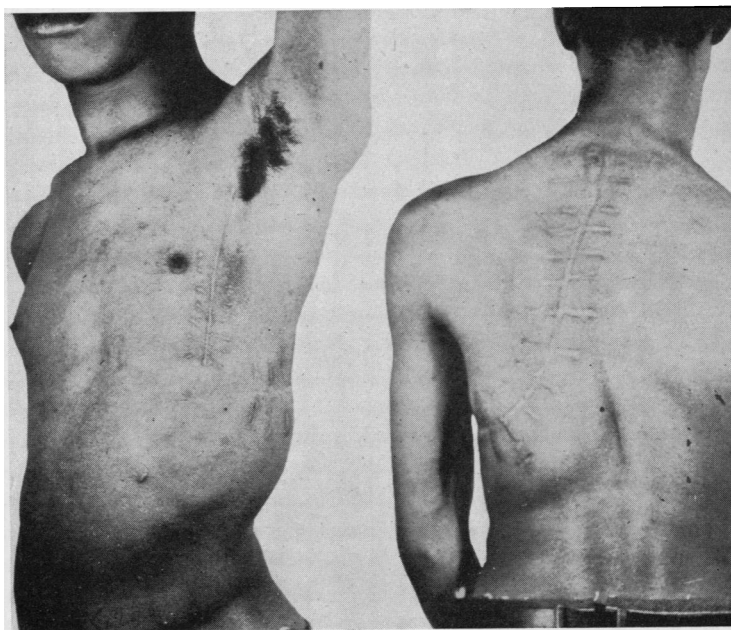


FIG. 9d (Case 14).—The chest wall has healed.

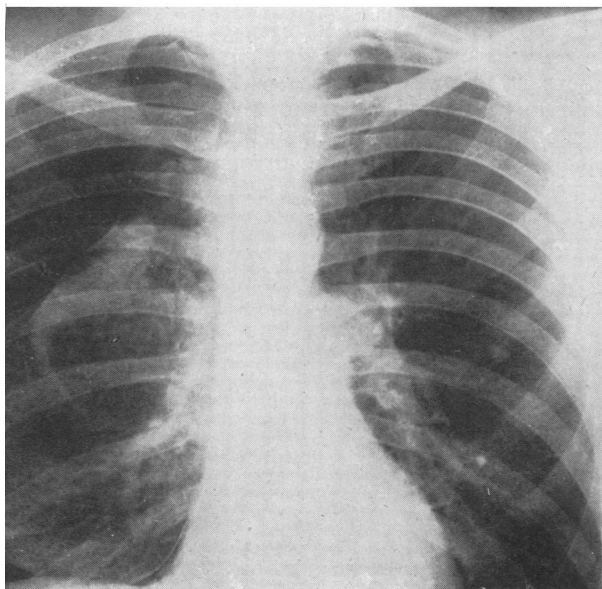


FIG. 10a

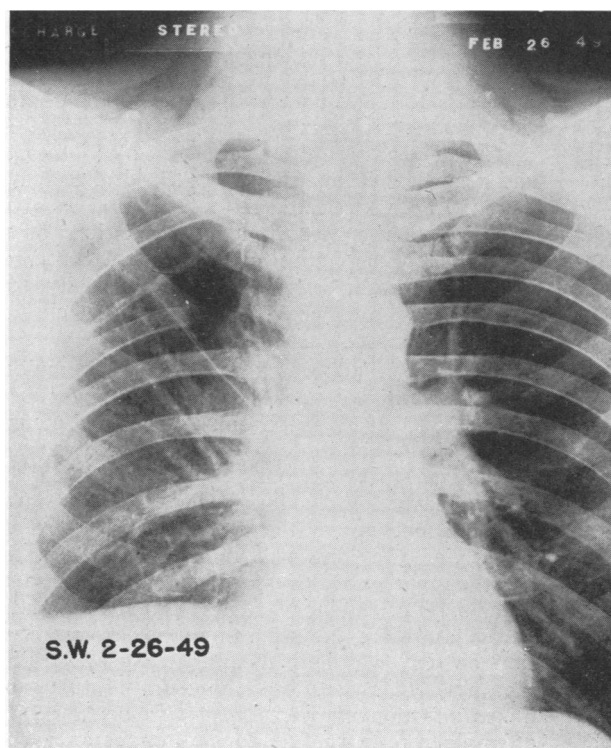


FIG. 10b.

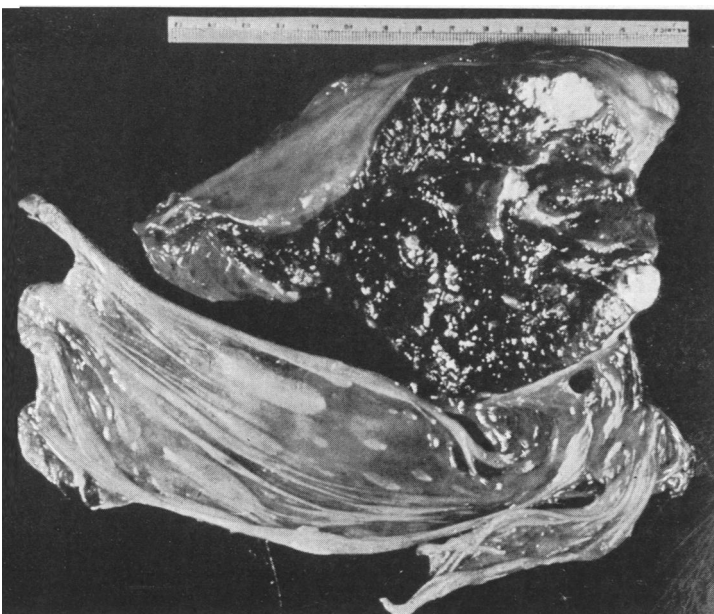


FIG. 10c.

FIG. 10a (Case 15).—A small residual cavity is visible in right upper lobe, also early pleural thickening.

FIG. 10b (Case 15).—Three months after right upper lobectomy and decortication of middle and lower lobes.

FIG. 10c (Case 15).—Resected lobe showing fibrous membrane on its surface and also attached sheet part of that which was decorticated from the middle and lower lobes.

tuberculous lung disease in spite of an extensive and long-standing chronic empyema and suggested the possibility of salvaging part of the lung and of restoring it to function after excision of the empyema. It had already been shown (Sarot, 1948) that good results could be obtained by lobectomy and decortication in cases of limited localized cavitary disease complicated by mild pleural involvement (unexpandable postpneumothorax lung or an early mild tuberculous empyema). Such cases with the diseased pulmonary area partially collapsed had shown poor results in cavity closure following thoracoplasty.

It has been advocated that early tuberculous empyema complicating localized cavitary tuberculosis be treated by aspirations of pus and pleural lavages with antiseptic solutions as the lung is encouraged to re-expand for later treatment by thoracoplasty. Particularly during this period of re-expansion, unless the empyema is of recent origin and the lung will re-expand rapidly, the great danger exists of spreads of the disease to other parts of the lungs. These spreads may later necessitate more extensive thoracoplasty or resection or may eliminate the possibility of surgical therapy. Likewise, bronchopleural fistula and mixed-infection empyema may also occur during attempts to re-expand the lung. For these reasons, prolonged attempts at re-expansion of the lung should not be made, but lobectomy or segmental resection and decortication should be undertaken at once.

Cases 15 and 16 illustrate partial pulmonary resection with decortication in limited lung tuberculosis complicated by mild pleural involvement. Bronchoscopic examination should be made in all cases. A serious endobronchial obstruction may prevent satisfactory re-expansion of the lung after an adequate decortication and may be an indication for resection instead.

It may be difficult in such cases to make certain that the disease is limited to one lobe since the thickened pleura may make radiographic evaluation of the extent of the disease uncertain. One should consider leaving a lobe only if exhaustive pre-operative study by postero-anterior and lateral tomography, Bucky films, and multiple views can give assurance that the lung disease is limited to one lobe. Decisions by the surgeon on the basis of his palpatory findings, even when facilitated by the extrapleural approach (see below), may be faulty. He may not be able to feel all the disease or to ascertain whether or not cavities are present. The surgeon, therefore, must be prepared to err on the side of safety and to remove more rather

than less tissue. It should also be noted that he may discover by palpation more evidence of disease than was predicted from radiographic studies.

Furthermore, if the condition of a lower lobe is questionable and, after it has been decorticated, the anaesthetist cannot by positive pressure cause it to expand to a markedly greater degree, it may be safer to perform a pneumonectomy. The expansion of a lobe which is to remain must be facilitated in every case by complete division of all adhesions and, when a lower lobe is being freed, division of the pulmonary ligament up to the inferior pulmonary vein.

Case 15 (Lobar Cavitary Disease with Mild Tuberculous Empyema).—S.W., a man aged 34, had a right pneumothorax induced for a large apical cavity in December, 1947. After two stages of pneumonolysis, mediastinal adhesions remained and a small cavity persisted despite extensive apical collapse (Fig. 10a). The pleural fluid became turbid and contained tubercle bacilli and the pleura became thickened. It was felt that thoracoplasty would not yield a more adequate collapse, and in October, 1948, the right upper lobe was resected and the thickened membrane over the lower and middle lobes was stripped away (Fig. 10c). The remaining lobes re-expanded and filled the hemithorax promptly. The sputum has remained negative and the patient is well six months later (Fig. 10b).

Fig. 11 is a photomicrograph of a section of the removed lobe and its overlying membrane. The overlying organizing fibrous sheet is separated from the lung by the thin, narrow layer of looser fibrous tissue

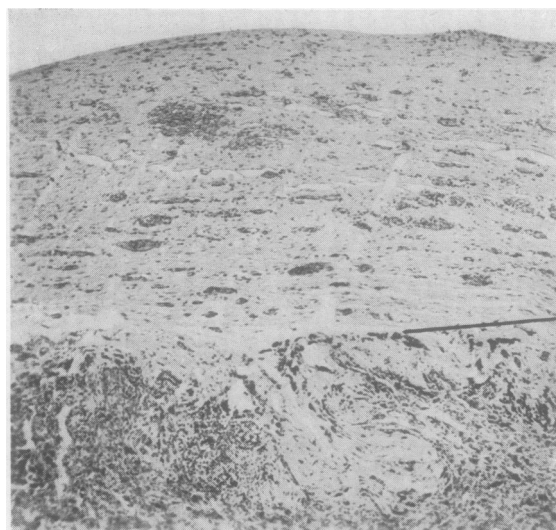


FIG. 11.—Photomicrograph of section of the removed lobe and its overlying membrane. Subjacent lung is collapsed (B). Mesothelial cells of the visceral pleura are intact (A).

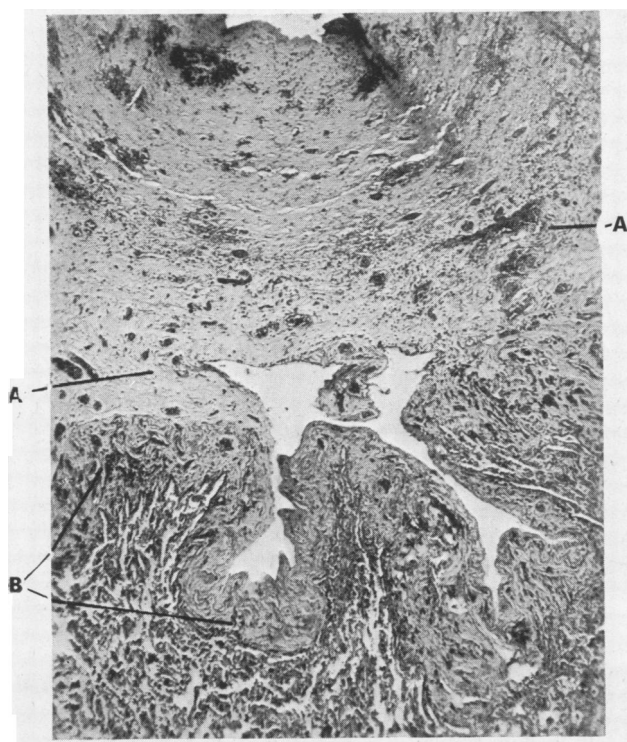


FIG. 12.—Photomicrograph demonstrating constrictive action of the fibrous membrane on the lung. Visceral pleura is folded and convoluted (B), and layer of looser fibrous tissue adjacent to pleura is seen at (A).

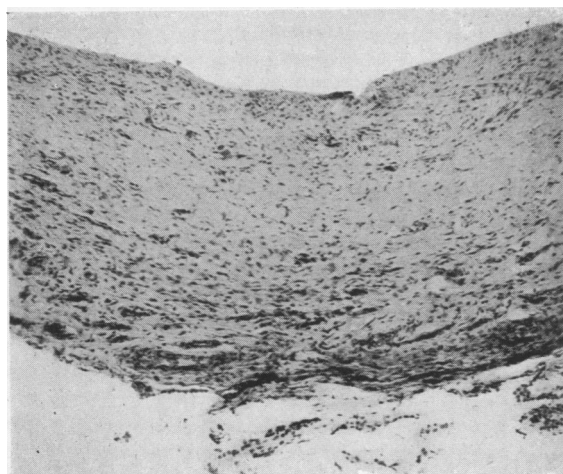


FIG. 13.—Section through the decorticated sheet of fibrous tissue shows separation to have taken place through the layer of looser fibrous tissue adjacent to the pleura.

(Fig. 12). When the fibrous membrane is stripped from the lung the convoluted folded pleura is freed and permitted to straighten out as the lung expands. The folded, drawn-together pleural surface visible in this section (Fig. 12) is a dramatic representation of the active constrictive as well as restrictive action of the fibrous membrane. The sheet decorticated from the lower lobes (Fig. 13) can be seen to have been separated in that plane of loose fibrous tissue just outside the visceral pleura (Fig. 12). The mesothelial cells of the pleura remain on the lung, and this accounts for the normal appearance of the decorticated visceral pleura.

Case 16 (Bilobar Cavitory Disease with Thickened Pleura in a Pneumothorax).—M.G., a woman aged 23, after one year of seemingly adequate collapse of the right lung by pneumothorax, continued to have a positive sputum. Tomographs (Fig. 14a) revealed a persistent cavity in the collapsed right upper lobe and an infiltration in the right middle lobe. It was considered that, inasmuch as there was an adequate collapse of the right upper lobe which did not re-expand readily, a thoracoplasty would have little effect if it were done over this pneumothorax. At operation on April 16, 1948, the lower lobe was palpated and only a few small discrete nodules were felt. The upper and middle lobes were removed and the thickened membrane was decorticated (Fig. 14b) from the lower lobe which expanded at once. The phrenic nerve was pinched, and four weeks later a one-stage, five-rib, upper thoracoplasty was performed to close the residual space (Fig. 14c). The patient's sputum became negative at once and has remained so for one year. Pulmonary function tests reveal that the remaining right lower lobe accepts one-half of the tidal air and accomplishes one-fifth of the total oxygen absorption. I now consider that the phrenic nerve paralysis was unnecessary and the thoracoplasty too extensive in this case, both contributing to diminished function of the right lower lobe.

The development of decortication and pleurectomy in conjunction with pulmonary resection poses the problems of indications, especially in cases of empyema without bronchial fistula in which the sputum is negative and pulmonary disease apparently controlled. If the empyema is small, of relatively short duration, and apparently amenable (with or without drainage) to closure by a limited thoracoplasty, such a procedure may very occasionally be preferable. I have in mind also the case of a 30-year-old woman who, two years after an extensive thoracoplasty performed elsewhere for a large tuberculous empyema (subsequent to a bronchopleural fistula which had closed), had developed an empyema necessitatis. She was in very poor condition and her chest had been so completely collapsed that it was not deemed worth

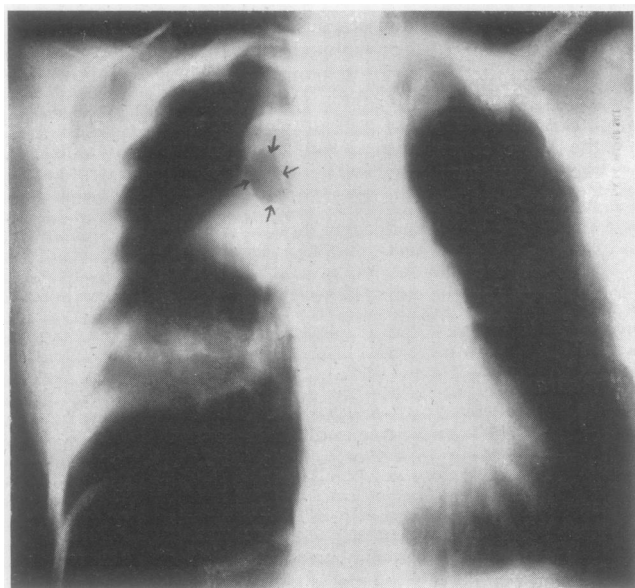


FIG. 14a.

FIG. 14a.—Tomograph demonstrating a persistent cavity in the collapsed right upper lobe and infiltration in the middle lobe.

FIG. 14b.—Section through the resected right upper and middle lobes showing also, above, part of parietal pleura removed in the extrapleural dissection and below, part of the decorticated visceral membrane.

FIG. 14c.—After maximum re-expansion of the lower lobe the remaining pleural space has been obliterated by an upper thoracoplasty.




FIG. 14b.

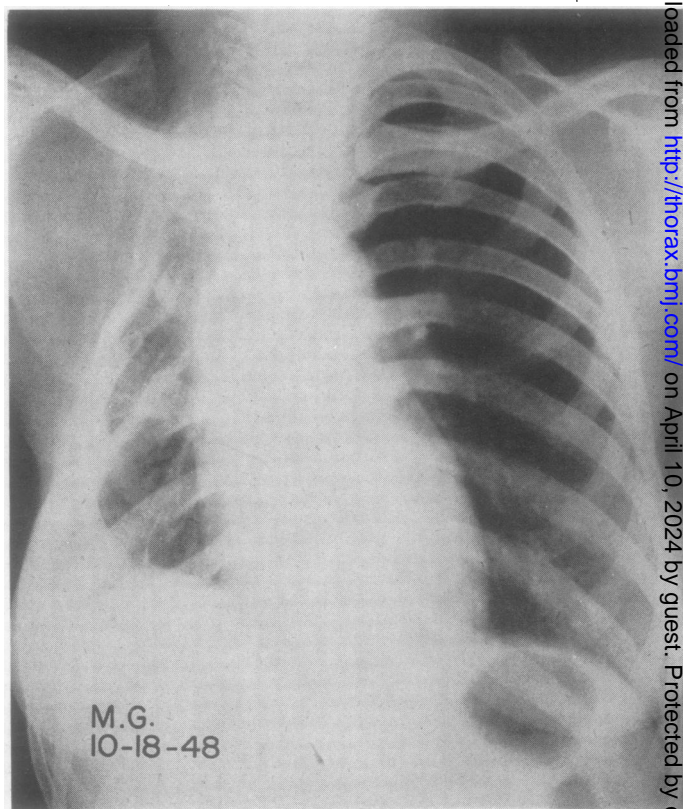


FIG. 14c.

while to attempt to re-expand her lung. Fortunately she had never had streptomycin and the empyema was lateral and basal; a multi-stage Schede operation was performed, and the chest wall healed readily. The usual subsequent deformity was, as always, a source of annoyance to the patient.

Thoracoplasty has also been reasonably successful in cases of uncontrolled pulmonary tuberculosis and empyema without bronchial fistula in which an active pulmonary lesion suitable for thoracoplasty collapse has been located in the upper portion of the lung, this portion of the lung being adherent to the chest wall with the empyema below. But if the lung is partially collapsed at the apex, thoracoplasty is notoriously poor as a means of obtaining cavity closure, since the thickened empyema walls prevent adequate collapse. In addition, the active disease focus remains a constant source of spreads of the infection during and after the period of surgical treatment. In such cases and in all cases with a bronchopleural fistula I believe that pulmonary resection (of required extent) and pleurectomy with excision of the empyema is the preferable procedure.

The problem is to determine the extent of the active tuberculous process in the lung. Because of the pleural thickening, interpretation of the radiographs is usually difficult and those made before the empyema may be misleading since spreads may have occurred in the lung under the empyema. All available information having been obtained by exhaustive radiography, sputum examinations and bronchoscopy, it may still be doubtful whether the condition of the lung warrants its re-expansion and finally whether it will re-expand. If an upper lobectomy is contemplated it must be ascertained that the lower, or lower and middle lobes, if permitted to remain, will expand enough to cover the upper lobe bronchial stump.

The cases of unexpandable postpneumothorax lung or mild tuberculous empyema demonstrated that it may be safe, in such instances, to approach the lung transpleurally to perform the decortication and to leave the parietal pleura. But in cases of more severe pleural involvement it was found more difficult to find the proper cleavage plane for the decortication. In cases of chronic tuberculous or mixed empyemas an approach through the empyema also exposes the field to massive contamination; in such cases, likewise, the parietal pleural wall of the empyema should be removed since, if permitted to remain, it will be a source of continued infection and it will continue to hinder the expansile movements of the chest wall.

I have found the extrapleural mediastinal approach to be of paramount importance in overcoming all these problems in decortication and pleurectomy. The usual extrapleural approach is made posteriorly by an incision through the bed of the fifth or sixth rib, and the thickened pleura and adherent lung are freed in the extrapleural plane to the mediastinum. The mediastinal pleura will be found to be thin and relatively loosely adherent to the lung in every case. This mediastinal pleura is incised and the lung is stripped from it (Fig. 15). As one proceeds

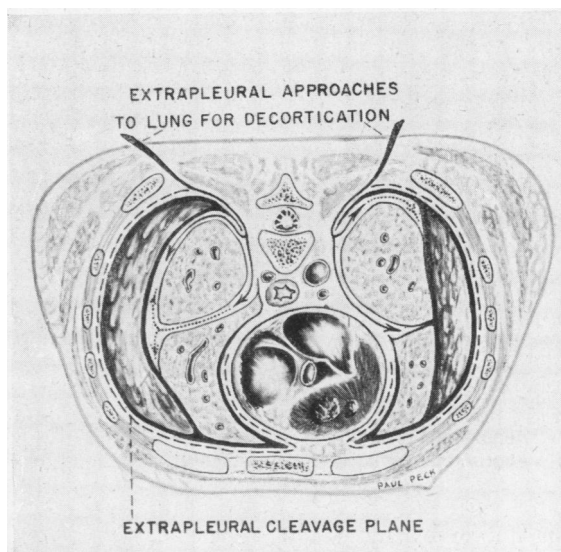


FIG. 15.

laterally and the line of fusion of the visceral pyogenic membrane (or thickened pleura in clean cases) and the parietal pleura is reached, since the proper cleavage plane has already been established, the lung can be freed from the visceral wall of the empyema with far greater ease and more completely than when a cleavage plane is established by incision of the pyogenic membrane through the empyema.

When the lower or lower and middle lobes have been freed from the empyema wall it may frequently be found easier to enter the fissures from their mediastinal aspects (Fig. 15) where there is less inflammatory reaction. As the lobes are freed they may be thoroughly palpated to determine the extent of the nodular disease within and then inflated by the anaesthetist to determine the capacity of the lobe to re-expand. If the freed lobe (or lobes) is found to be extensively diseased,

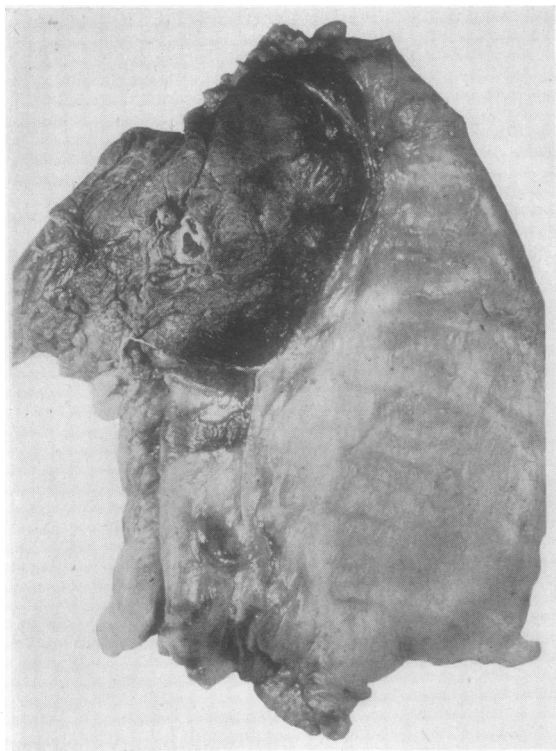


FIG. 16a.—In a case of bronchopleural fistula and empyema right upper lobe has been removed with entire empyema sac by extrapleural dissection.

or not to expand readily, one can proceed with extrapleural pneumonectomy and total pleurectomy.

If, however, the lower or lower and middle lobes are to be permitted to remain and the pre-operative study has indicated the need for upper lobe excision, one can proceed at once with amputation of the upper lobe and extrapleural excision of the empyema. Frequently the entire empyema sac may be excised intact, or almost so. Figs. 16a and 16b illustrate the upper lobe and the empyema sac removed in a case of chronic mixed empyema in which a bronchial fistula had previously been present although it could not be found in the specimen.

If doubt remains as to whether the entire upper lobe must be removed, it can be stripped from the empyema membrane with relative ease except perhaps over diseased areas in which difficulty may be encountered. After the lobe has been freed in this way one may determine that the residue of the previous disease is well localized, as in Case 17, and the localized area of disease may be removed by segmental resection. In some cases of empyema with negative sputum, the radiographic and palpable evidence of the remnants of the disease may be so minimal that it may be wise to permit the entire lung to re-expand. Should the lung fail to expand sufficiently to fill the pleural space, a small thoracoplasty may suffice to obliterate the residual space. There may be some fear that a closed cavitory focus may reopen, but one can always proceed at a later date with a thoracoplasty or a resection, if it should be required, especially since the empyema will have been excised. As yet we do not know a great deal about what happens to previously encapsulated foci after the lung has been re-expanded after decortication.

The extrapleural mediastinal approach is, therefore, a method which aids materially in the assessment of the indications and in the treatment of cases of pulmonary tuberculosis and empyema or unexpandable lung. Its advantages may be thus summarized to be, first, easier entry into the proper cleavage plane for the decortication of the lung; second, a lobe or lung which may possibly be

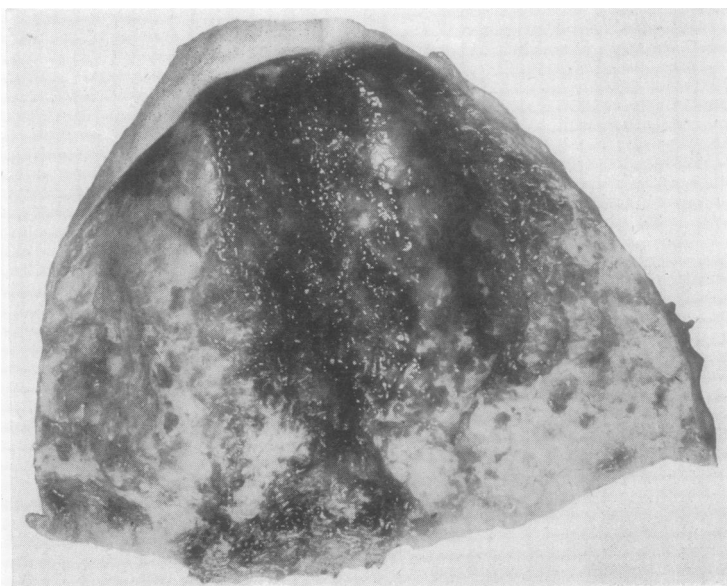


FIG. 16b.—Empyema sac opened.

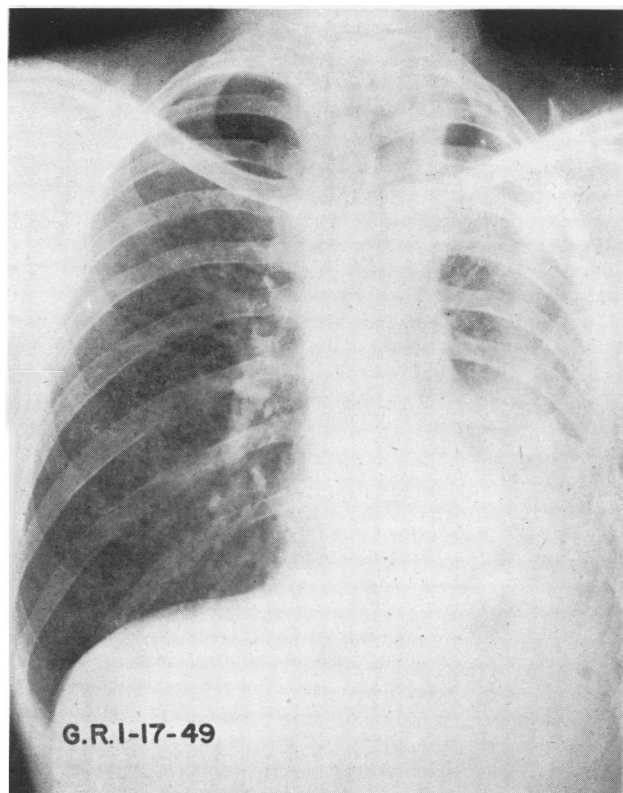


FIG. 17a.




FIG. 17b.

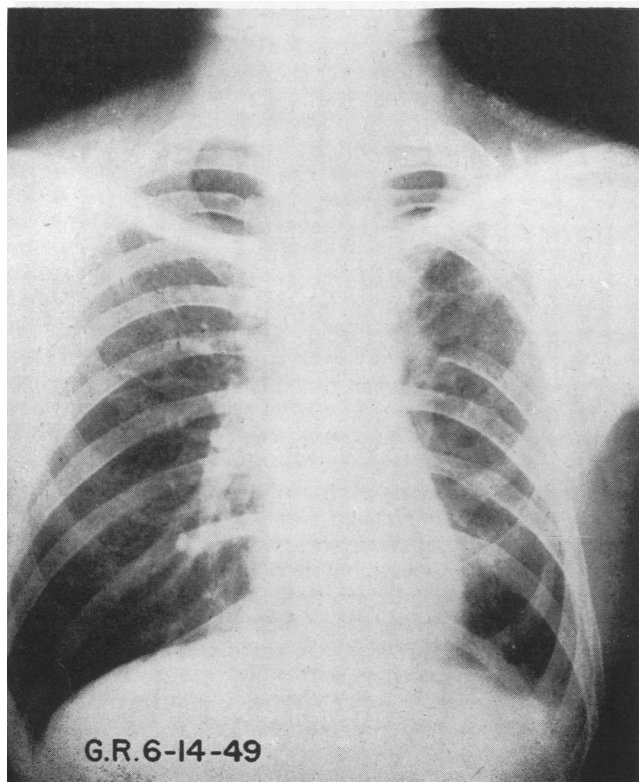


FIG. 17c.

FIG. 17a (Case 17).—Apparent left fibrothorax in patient with a re-expanded lung after spontaneous closure of a bronchopleural fistula and empyema "healed" by aspiration.

FIG. 17b (Case 17).—The resected segment opened shows the inspissated cavitory foci. The walls of the empyema are at least $\frac{1}{2}$ in. thick throughout.

FIG. 17c (Case 17).—Four months after segmental resection of lung and excision of the tuberculous empyema. The left lung has re-expanded to fill almost the entire hemithorax. There is less tracheal deviation than before operation.

permitted to remain may be freed, palpated, and expanded. If the disease is sufficiently localized, a lobectomy or a segmental resection may be performed and much of the lung preserved; third, if examination of the lower or middle lobes reveals that it is unsafe or unwise to leave these lobes one may proceed at once with extrapleural pneumonectomy and total pleurectomy; and, fourth, all these procedures are performed in a clean field which is not contaminated to any great degree by pus from the empyema, and at the completion of the operation the chronically caseating parietal pleura will have been removed with the pyogenic visceral membrane and with a lung that has been destroyed, or with a lobe or segment if that degree of resection is all that is required.

The next case illustrates a problem which is frequently met with. After re-expansion of the lung to obliterate an empyema complicating pneumothorax, a residual encapsulated tuberculous empyema is suspected but not found. The sputum is persistently negative on all examinations and no disease foci can be detected in the lung radiologically through the thickened pleura, but the patient becomes dyspnoeic on moderate exertion, is weak and cannot work, and has an intermittent low-grade fever.

Case 17 (Fibrothorax and Localized Chronic Tuberculous Empyema with Inspissated Cavitory Focus in Lung).—G.R., a man aged 36, had a left pneumothorax induced for a small apical cavity in March, 1947. In June, 1947, several string adhesions were cut but a broad apical band was not freed. Sputum became negative before the pneumolysis and has remained so since. One year later a spontaneous pneumothorax occurred with subsequent mixed-infection empyema. The bronchopleural fistula healed after a short time and the tuberculous empyema was aspirated frequently. The lung re-expanded and the pleural space obliterated (Fig. 17a). The sputum was negative and no disease focus could be found in the lung. It was suggested that a fibrothorax might be present with some undetected empyema pocket to explain the intermittent low-grade fever and weakness. I advised exploratory thoracotomy to find and to excise the empyema, and I hoped to decorticate and return to function the lung which was bound down.

At operation on January 17, 1949, a fairly large posterior basal, chronic tuberculous empyema was found. The visceral inflammatory membrane was at least $\frac{1}{2}$ in. in thickness, and beyond the empyema pocket the parietal pleura was equally thick and adherent to the lung. The entire parietal pleura was freed extrapleurally, and after incision of the mediastinal pleura the lung was gently stripped away from the thick, fibrous parietal pleura and the visceral wall of the empyema. The lung surface was smooth and

glistening with only a few tears. An indurated area was palpated in the apical segment of the left upper lobe, and, for fear of leaving an inspissated focus which might reopen after re-expansion of the lung, an apico-posterior segmental resection was performed. When this segment was opened it was found to contain two cavitory foci (Fig. 17b) containing thick, tuberculous pus. The thickened parietal pleura and the visceral diaphragmatic and parietal walls of the empyema were excised. The diaphragm was seen to begin functioning again as the empyema membrane was cut from it and now can be seen, on fluoroscopic examination, to be functioning normally. The wound healed by primary union. The post-operative course was uneventful and the lung has expanded gradually to fill almost the entire hemithorax (Fig. 17c). If the lung does not expand completely I shall do a limited upper thoracoplasty to close the residual space.

In this case the residual focus of the parenchymal disease and the empyema sac were removed and the healthy lung and the diaphragm were restored to function. This is a far more physiologically and generally desirable state of affairs than could have resulted, at best, from a thoracoplasty with Schede resection of the chest wall for the chronic empyema. There is no deformity and the entire period in hospital was less than three weeks.

DISEASE UNFAVOURABLY LOCATED

Cavities located in the paravertebral segments of the upper lobe, the lingula of the left upper lobe, the middle lobe, or the lower lobe are unsuitable for thoracoplasty. Even the most complete thoracoplasty may not effect cavity closure. Meanwhile, however, there will have been extensive collapse of healthy, functioning lung. Occasionally pneumonectomy will be necessary for technical reasons (Figs. 18a and 18b), but more frequently a lobectomy will suffice (Figs. 19a and 19b).

If pneumothorax has not been possible, cavities in the lower lobes and in the anterior portion of the lung may be given a trial of treatment by pneumoperitoneum and phrenic nerve paralysis. If this fails, resection is indicated rather than thoracoplasty.

EMERGENCY RESECTION

If, in a case anatomically suitable for resection, severe haemorrhages occur and a pneumothorax cannot be induced because of adhesions, or, after induction of a pneumothorax the haemorrhages continue, immediate resection of a lobe or lung is to be preferred to the multiple stages of a thoracoplasty. The prompt clamping of the bronchus of the involved lobe or lung may be a life-saving measure. Chamberlain (personal communication) has recently reported such a case.

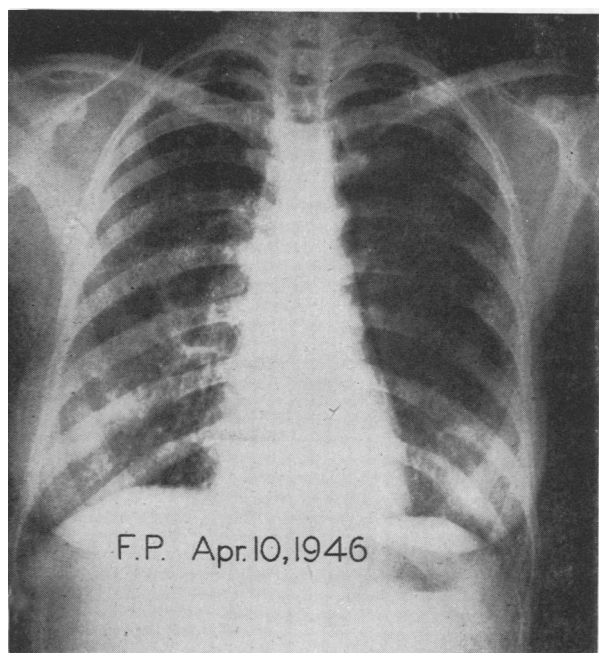


FIG. 18a.—Large paravertebral cavity.

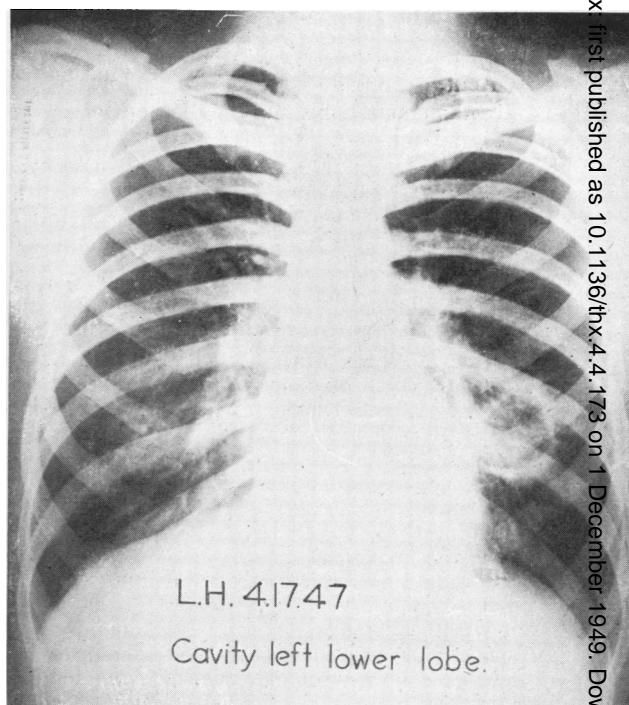


FIG. 19a.—Large cavity in the left lower lobe.

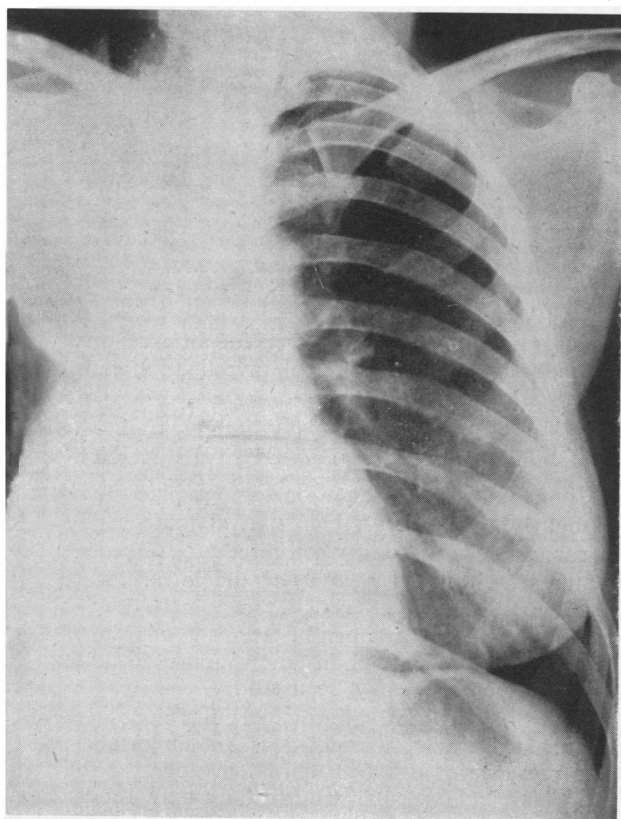


FIG. 18b.—Approximately two and one-half years after right pneumonectomy.

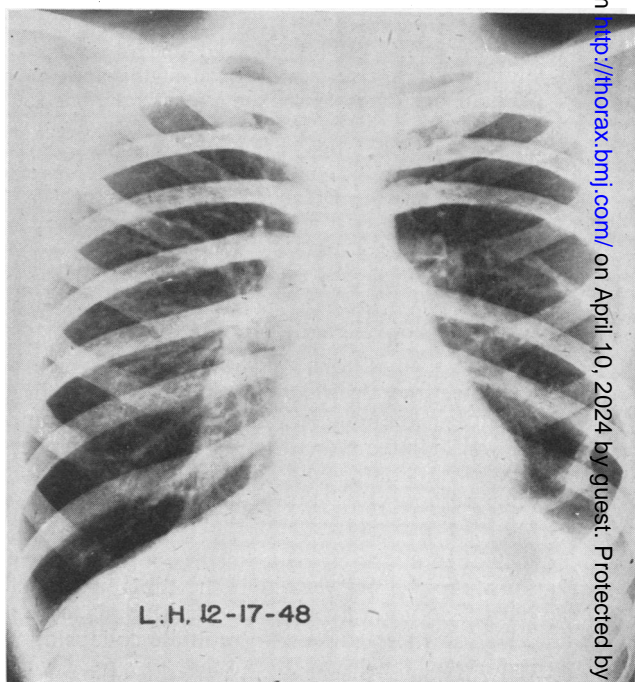


FIG. 19b.—One year after left lower lobectomy.

Acute rupture of a cavity following closed pneumonolysis or in the course of pneumothorax therapy is, fortunately, a rather uncommon complication. It may be catastrophic; at the least, it leads to a severe empyema. Resection of a lobe which contains a ruptured cavity, with decortication and rapid re-expansion of the remaining lobe to obliterate the pleural space, is a logical emergency procedure.

Case 18 (Acute Cavity Rupture).—M.R., a woman aged 26, was admitted on December 4, 1946, with a short history of tuberculous disease. A right pneumothorax was induced in January, 1947, with temporary success, but the cavity could not be closed, and closed pneumonolysis was recommended. This was performed on September 2, 1947, but was followed in several days by evidence of a bronchopleural fistula, temperature of 103° F., and a rapidly developing empyema (Fig. 20a). It was thought that the cavity had ruptured, and it was decided that excision should be attempted in view of the usual unfavourable prognosis of such cases. This decision was taken despite the presence in the contralateral lung of the scar of a previously observed cavity which had closed spontaneously and which was shown by tomography to have remained closed. The pleural fluid contained tubercle bacilli. An emergency right upper lobectomy was performed by Dr. C. Bailey on September 16, 1947. At operation a bronchopleural fistula was found at the apex of the upper lobe. A pyogenic membrane one-fourth of an inch in thickness was present over the middle and lower lobes; this was removed and these lobes re-expanded to fill the thoracic space. A thoracoplasty was performed on October 3, 1947. Her post-operative course was uneventful and she has remained well (Fig. 20b) with a negative sputum 18 months since operation.

SPECIAL INDICATIONS

Special conditions may be present which will influence the decision toward excisional surgery in a case anatomically suitable for thoracoplasty as well. Patients with mental disease, epilepsy, alcoholism, or drug addiction are unsuitable for pneumothorax or thoracoplasty because of the multiple procedures and the long restriction.

Diabetics who are difficult to control frequently show rapid improvement if the tuberculosis is excised. Excision of the tuberculous lung is to be preferred in these patients to multiple collapsing procedures which leave the disease *in situ*. Overholt (personal communication) stated recently that he had come to the same conclusion.

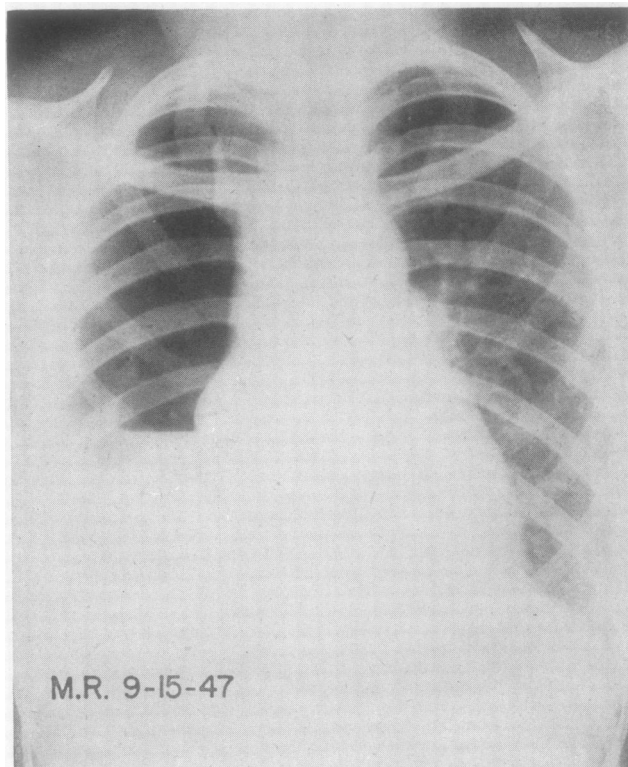


FIG. 20a (Case 18).—Bronchopleural fistula and empyema have developed immediately after pneumonolysis.

PROCEDURES AND CONSIDERATIONS IN SELECTION OF CASES

Before a case is finally chosen for an excisional procedure a complete clinical investigation must be undertaken.

RADIOGRAPHIC STUDY OF THE LUNGS

Complete posterior-anterior tomographic study of both lungs is imperative. Lateral tomography is particularly indicated when disease is suspected in the paravertebral regions of the lower lobes. Radiographs made with the Potter-Bucky diaphragm not infrequently furnish additional information. In special instances apical lordotic and oblique views may be useful.

Evidence that the peribronchial hilar nodes are unduly enlarged or calcified is of importance. The presence of calcified or matted nodes at the bronchial and vascular bifurcations may render any lesser procedure than total pneumonectomy unfeasible because of the occasionally insurmount-

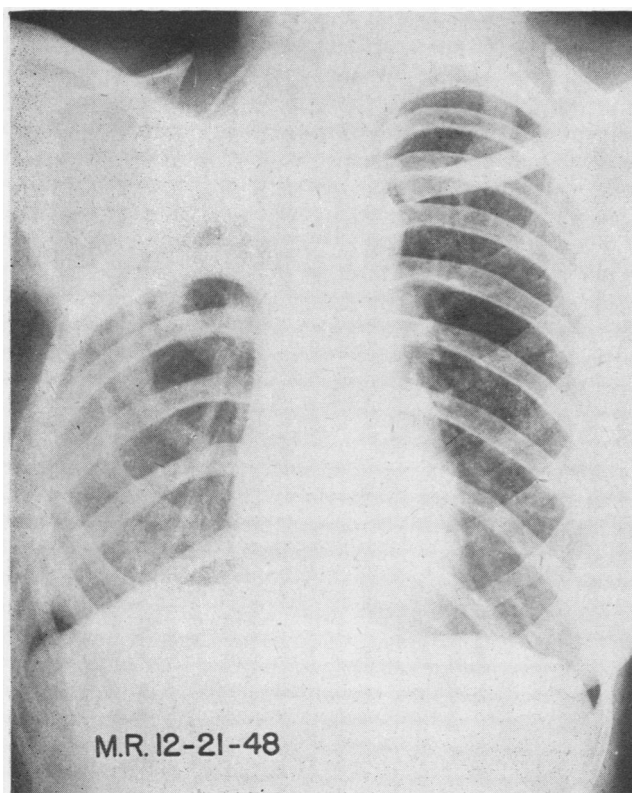


FIG. 20b (Case 18).—One year after emergency right upper lobectomy with decortication and subsequent thoracoplasty.

disease in the contralateral lung at the time of operation. Although the ultimate outcome in these cases may be questioned, until now a one to three-year follow-up has not shown more contralateral reactivation in these patients than in those who had no demonstrable disease in the contralateral lung at the time of operation. This is especially true of cases in whom the contralateral infiltration is the result of spread after haemoptysis; lesions in these patients have shown an almost uniform tendency to clear and remain quiescent in the rather limited post-operative follow-up period as yet available (Robitzek and Selikoff, personal communication).

Experience so far indicates that contralateral disease which had cleared before the resections has remained quiescent afterwards. In addition where contralateral disease was present at the time of operation, productive in most cases but even exudative in others, this disease frequently showed a marked tendency to clear after resection. One may anticipate that a small percentage of these cases (about 10%) will show progressive cavitory disease in the remaining lung. This is similar to the experience after thoracoplasty. Since without surgical therapy these cases have a very poor prognosis, excision should be recommended with the foreknowledge that

an occasional one will unfortunately turn out badly. The greater number will be salvaged.

able technical difficulties in removing only one lobe or segment. This is of particular importance if, because of insufficient respiratory functional reserve, only lobectomy is indicated and pneumonectomy is considered hazardous. Such a finding in radiographs is of less importance when pneumonectomy is definitely contemplated, especially since the development of the posterior extrapleural approach to the hilum (Sarot, *in press*) which enables the surgeon to approach the hilar structures through relatively uninvolved tissues proximal to the interbronchial and more distal peribronchial nodes.

The extent, anatomical location, and type of disease must be determined as completely as possible. Particular search is made for evidence of contralateral cavitation. However, the evidence of contralateral cavitation must be definite to be considered a contraindication.

The existence of a moderate amount of non-cavitory contralateral disease is not a contraindication to excisional surgery. In my experience, approximately one-half of the patients have had some

Previously existent contralateral cavitory disease, spontaneously healed or controlled by collapse therapy, is not a contraindication to excisional surgery. Of 11 cases with contralateral cavitory disease which had either healed spontaneously or had been controlled by collapse procedures before resection, only one previously controlled cavity has reopened. In seven, resection was done in the presence of a contralateral therapeutic pneumothorax. Two had had partial thoracoplasties previously and two had healed spontaneously. The previously controlled cavity which had reopened occurred in a patient whose cavity was thought to have healed spontaneously (Robitzek and Selikoff).

Contralateral disease under control by pneumothorax is not a contraindication to excisional surgery. Since we reported (Sarot and Gilbert, 1947), the first successful pneumonectomy performed in the presence of contralateral therapeutic pneumothorax, a number of these cases have been

operated upon. Among the cases reported by Selikoff and Tchertkoff (to be published), there were seven cases of resection (six pneumonectomies and one lobectomy) in the presence of contralateral pneumothorax. All the patients did well. In five of the seven, the pneumothorax has already been abandoned and they have remained well.

The combination of thoracoplasty and contralateral pneumothorax has been for a long time an accepted technique of management of bilateral cases. In my opinion, the combination of excisional surgery with a contralateral therapeutic pneumothorax should be added as an accepted routine of treatment in suitable cases. In fact, where the preservation of vital capacity and pulmonary functional reserve is important in bilateral disease with contralateral pneumothorax, lobectomy is preferable to an extensive thoracoplasty.

Uncontrolled contralateral cavitory disease remains a contraindication to excisional surgery. Very extensive contralateral infiltration, especially if of an exudative nature, is at least a temporary contraindication. Some of these cases may be operated upon at a later date if the infiltration in the contralateral lung remains con-cavitory and shows evidence of resorption upon treatment by bed rest and possibly by streptomycin. Where cavitation may be suspected from physical signs and questionable radiographs, thorough tomographic studies should be made. If the cavity still cannot be demonstrated and the infiltration is not too extensive, it is my opinion that the patient should be considered for excisional surgery.

Should contralateral cavitation occur after a lobectomy, then not only may collapse therapy be instituted where indicated but limited excisions may be performed. Overholt and others have reported planned bilateral excisional procedures. In one case in which I performed a right upper lobectomy for tension cavity, a similar cavity later appeared in the left upper lobe and a segmental resection was successful (see Case 11). When contralateral cavitation occurs after pneumonectomy, pneumothorax therapy, including pneumonolysis, has been applied.

The preceding discussion applies almost as well in general to the question of lobectomy in the presence of a homolateral lobe in which there is or has been disease. If the lobe contains no cavity or large conglomerate caseous foci, I would tend to leave it. When performing an upper lobectomy one must make certain of the condition of the apical segment of the lower lobe. This segment is most commonly the zone of homo-

lateral bronchogenic spread during the long period of bed rest in the supine position (see Case 8).

Previously existent extensive disease which has healed in a homolateral lobe may not be a contraindication to upper lobectomy. It will require observation of many cases, such as Case 19, to elucidate this point.

Case 19 (Upper Lobectomy after Healed Lower Lobe Disease).—E.J., a woman aged 32, had been ill with pulmonary tuberculosis in 1939, but the lesions healed with bed rest. In March, 1946, following several haemoptyses, extensive acute disease was found in the right upper and lower lobes, with some infiltration of the left apex (Fig. 21a). Attempts at induction of a right pneumothorax were unsuccessful. During prolonged bed rest it was noted that the post-haemoptoic spread to the right lower lobe cleared progressively, until in 1948 there was practically no evidence of disease radiologically (Fig. 21b). Cavities, however, were present in the right upper lobe (Fig. 21c). After function tests showed adequate respiratory capacity, a right upper lobectomy was performed on May 18, 1948. The right lower lobe expanded rapidly and filled the hemithorax within 48 hours. Thoracoplasty was not performed. Despite this and the moderate overexpansion of the lower lobe, which had been the site of considerable infiltration two years previously, thus far there has been no reappearance of the disease (Fig. 21d). At present the patient is well and leading an active life one year following operation.

ESTIMATION OF RESPIRATORY FUNCTION

Estimation of the respiratory function is an important but all too frequently neglected aspect of the study of a case before operation. Just as radiography aids in determining the anatomical suitability of a case for operation, so do the respiratory function tests aid in determining the physiological suitability.

It has been found that the estimation of vital capacity may be dangerously misleading as the sole means of estimating the respiratory capacity of a patient before operation. The pulmonary ventilation and diffusion must be studied. I employ the techniques described by Ornstein (1949). In the analysis of ventilation, both the resting minute ventilation and the maximum minute ventilation are measured. These are not, in themselves, of importance, but the relationship between them, expressed as the "Ornstein" or ventilatory factor, is an estimate of the ventilatory reserve of the patient.

Utilization (diffusion) of the air has always been a difficult thing to estimate. The diffusion test described by Ornstein is employed for this purpose. The patient rebreathes one litre of air for

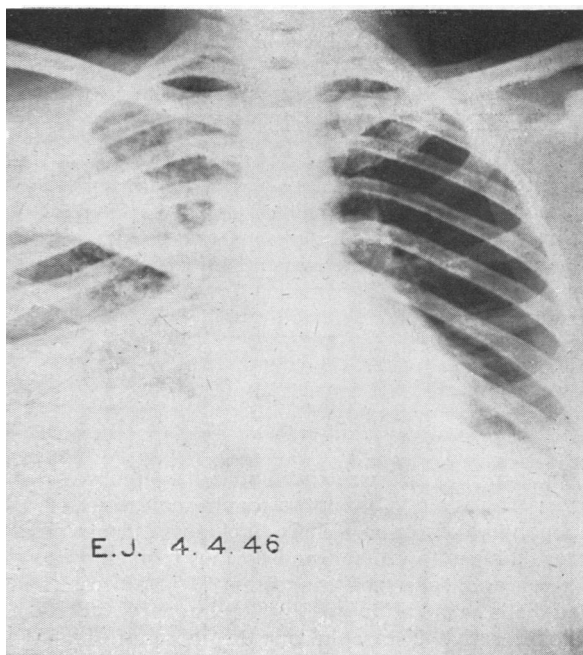


FIG. 21a (Case 19).—Extensive disease throughout the right lung; infiltration in the left upper lobe.

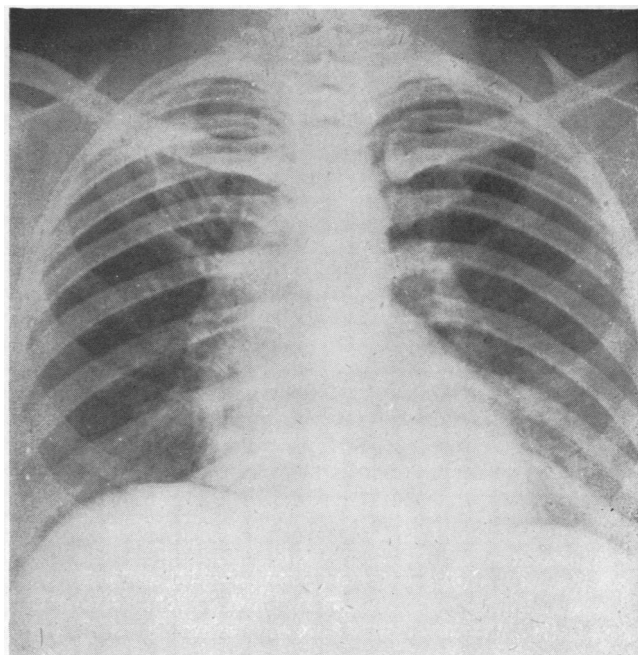


FIG. 21b (Case 19).—Marked clearing of the right lower lobe and the left upper lobe apparent two years later.

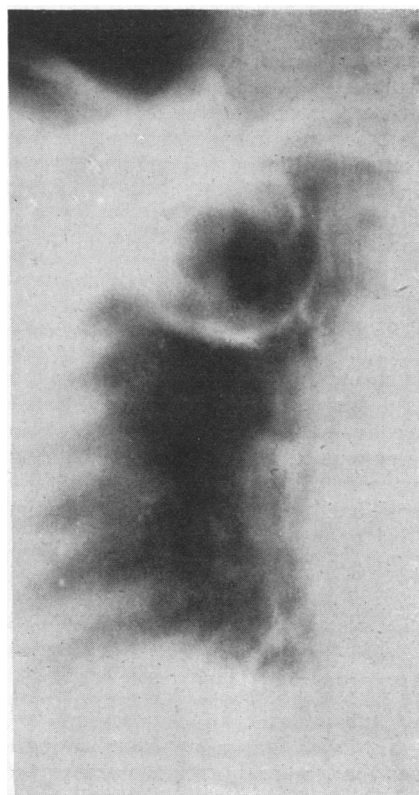


FIG. 21c (Case 19).—Tomographic demonstration of large cavity in the right upper lobe.

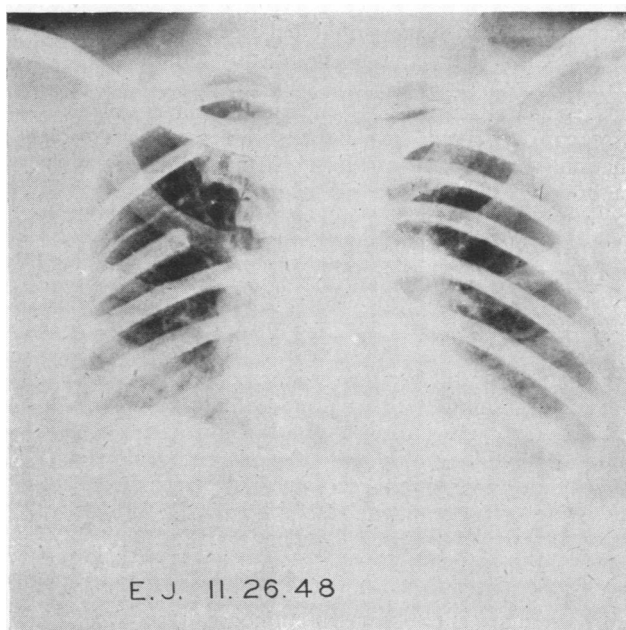


FIG. 21d (Case 19).—Approximately six months after right upper lobectomy.

20 seconds while exercising (step test) and the total absorption of oxygen is estimated by analysis of the gas in the rebreathing bag. It has been found that persons with good pulmonary function will leave less than 10 vols. % of oxygen in the bag, since most of the oxygen will have been absorbed. On the other hand, with poor gaseous diffusion, the oxygen will not be well absorbed and more than 10 vols. % will remain in the bag.

It has been my experience that when the diffusion and ventilatory function tests of Ornstein have indicated adequate pulmonary function there has been no unusual respiratory difficulty during or after the operative procedure and no "respiratory cripples" have resulted. In contrast, in two cases in which these tests indicated poor respiratory function, pneumonectomies were successfully performed and the sputa converted, but both patients experienced great post-operative difficulties in respiration and one died of respiratory insufficiency.

However, a number of cases have shown either poor diffusion or poor ventilation, with the other function adequate, and these have done well. The discovery of diminished ventilation with good diffusion should influence the choice of surgery in cases suitable for either lobectomy or thoracoplasty. Thoracoplasty would be especially detrimental inasmuch as it often sharply diminishes ventilation by causing a rigid thorax. Lobectomy or segmental resection without post-operative thoracoplasty might then be preferable since ventilation would be less affected. If function is poor in both ventilation and diffusion one may have to resort to cavernostomy.

When evidence of impaired pulmonary function has been obtained, as little lung tissue as possible must be resected and measures which tend to preserve functioning parenchyma must be adopted. Lobectomy and resection of an adjacent diseased segment, or multiple segmental resections, are, if possible, preferable to pneumonectomy in such cases but not, of course, at the expense of transecting or leaving behind significantly tuberculous lung tissue in order to accomplish the segmental resections. Post-resection thoracoplasty is often better omitted in patients with poor function, since it further diminishes the ventilation by mechanical fixation of the chest wall.

In summary, the study of pulmonary function is valuable for the determination of physiological suitability for operation, the choice of excisional or collapse surgery, the extent of pulmonary resection permissible, and the advisability of post-resection thoracoplasty.

PRESENCE OF EXTRAPULMONARY TUBERCULOSIS

Systematic search should be made for extrapulmonary tuberculosis, particularly of the genito-urinary tract, the osseous system, and the larynx. Twenty-four-hour urine specimens are examined in every case and a complete urologic study is undertaken if tubercle bacilli are found. Spine radiographs are frequently taken, especially where there is any evidence of haematogenous dissemination in lung or serous membranes (Cohen and Taylor, 1939; Ornstein and Ulmar, 1935). The larynx is examined in every case.

In general, the existence of extrapulmonary organ tuberculosis is not a contraindication to pulmonary resection. This includes laryngeal, intestinal, genito-urinary, and osseous tuberculosis. Selikoff and Tchertkoff found that 23 of 125 cases had had, in addition to their pulmonary tuberculosis, active disease in one or more of these systems. In all cases, however, by the time these particular patients came to operation, the extrapulmonary disease had been brought under control by streptomycin and previous surgical treatment where indicated. Of these, six had laryngeal tuberculosis, four had lymphadenitis, two had otitic tuberculosis, and four had tubercle bacilluria with negative cystoscopic and radiographic findings. In no case was the operation or the post-operative course significantly complicated by the extrapulmonary disease.

I believe that in most cases resection of the diseased lung tissue should take precedence over the treatment of the extrapulmonary foci, because bronchial spread is the greatest danger to the patient. After control of the pulmonary disease, the patient is able to undergo the necessary operative treatment for the extrapulmonary disease under general anaesthesia if necessary. Possible exceptions to this may be found in Pott's disease, because the patient may not be able to withstand the vigorous physical strain associated with the operative positioning and the post-operative care. In cases with laryngeal and intestinal tuberculosis, removal of the source of the positive sputum will frequently do more towards the control of these foci than will general and local medication and rest.

ENDOBONCHIAL TUBERCULOSIS

Bronchial tuberculosis in association with pulmonary disease is not a contraindication to excision, even though the tuberculous process may involve the region through which the bronchus may have to be resected. Overholt and his

co-workers (1946) have found gross evidence of tuberculosis at the line of bronchial resection in approximately 20% of their cases. Ehrenreich and Stern (data to be published) at Sea View Hospital have found gross tuberculosis at the line of bronchial resection in 13 of 127 resected specimens, about 10%. However, about 34% of all specimens showed microscopic evidence of tuberculosis at the line of resection. Division of the bronchus through a diseased area does not seem to increase the incidence of post-operative empyema or bronchopleural fistula. Overholt has described late ulceration of the stump, and suggests periodic bronchoscopy in the months following resection for its detection and treatment.

It should be noted that a resection of the bronchus at the carina, such as may be attained readily by use of the posterior extrapleural approach, will in most cases enable the bronchial resection to be carried out through healthy tissue proximal to the region of bronchial disease.

PLEURAL INFECTION

The existence of pleural infection (tuberculous pleuritis and tuberculous or mixed empyema, with or without bronchopleural fistula) has until recently been considered an absolute contraindication to pulmonary resection. The appreciable incidence of these complications of pulmonary tuberculosis, especially during the course of pneumothorax therapy, indicates therefore that many otherwise suitable candidates for excisional surgery were not considered for it. Inasmuch as the results of collapse therapy with or without coincident surgical drainage of the empyema have been disappointing, the recent demonstration of the feasibility of pulmonary resection in the presence of empyema is particularly important. The introduction of extrapleural pneumonectomy and total pleurectomy (Sarot and Gilbert, 1947) and the development of the technique of extrapleural pulmonary resection (Sarot, in press) have solved this problem.

Tuberculous pleuritis may persist after complete expansion of the lung in patients who developed a tuberculous empyema in a pneumothorax. If intrapleural pneumonectomy is performed in such cases, residual caseous pleura may lead to a post-pneumonectomy empyema. Extrapleural pneumonectomy, therefore, is indicated when tubercle bacilli have been present in pneumothorax fluid before the lung was re-expanded.

CHEST WALL WOUNDS AND INFECTIONS

Infected and open wounds of the chest wall such as empyema sinuses, unhealed Schede wounds, and cavernostomy openings tend to complicate a

thoracoplasty. But excisions of such wounds with primary closure of the chest wall have been performed successfully at the time of extrapleural pneumonectomy or lobectomy, and their presence need not be considered a contraindication.

FEVER, TOXICITY, AND PROGRESSIVE DISEASE

Evidences of activity such as fever, loss of weight, and other constitutional symptoms of toxicity were considered to be contraindications to thoracoplasty. This view does not apply to excisional surgery. Febrile and toxic patients tolerate the excisional procedure well, and, after excision, fever and evidences of toxicity disappear rapidly unless suppurative complications or spread of disease occur post-operatively.

It is my impression that in patients whose disease is suitable anatomically either for an excision or for surgical collapse, and who are running a toxic and febrile course, early excision is to be preferred to collapse therapy.

COEXISTENT NON-TUBERCULOUS DISEASE

Inactive rheumatic cardiovalvular disease, syphilis, and chronic alcoholism have been encountered and have not interfered with pulmonary resection for tuberculosis. Diabetes which is difficult to control often seems to improve rapidly after resection of the tuberculous lung.

A careful study of the cardiac condition is made in every case and also general metabolic and haematological studies.

AMYLOIDOSIS

Generalized amyloidosis is found in cases of pulmonary tuberculosis considered for excisional surgery far more frequently than is commonly realized. Selikoff (1947) estimates that 10% of all patients possibly suitable for excisional surgery have generalized amyloidosis. The presence of generalized amyloidosis without an Addisonian syndrome, severe renal or hepatic insufficiency does not constitute a contraindication to excisional surgery. In fact, such surgery may offer these patients their only chance for removal of that disease focus which is the main aetiological factor of the amyloidosis.

Selikoff and Tchertkoff (data to be published) studied six cases of pulmonary excisions in the presence of amyloidosis. All but one did well. One died from bronchopleural fistula, empyema, and contralateral spread. It will be of great interest to observe the future course of these

patients. Possibly the amyloidosis will not progress or it may even regress.

The investigation of a patient for amyloidosis should begin with a Congo red test. Only 100% retention of the injected dye, preferably confirmed by a repeat examination, can be accepted as conclusive evidence of generalized amyloidosis (Selikoff, 1947). If amyloidosis is suspected on clinical grounds but the Congo red test is negative (false negative result), a gingival biopsy should be done (Selikoff and Robitzek, 1947).

The presence of constant proteinuria in a patient with active pulmonary tuberculosis should lead to suspicion of amyloidosis, especially if fractionation shows a high globulin content. If amyloid is found, adrenal, hepatic, and renal function are tested. Severe impairment of these functions is usually considered a contraindication to surgery.

If patients with amyloidosis are subjected to surgery, it is of the utmost importance to avoid contamination of the operative field since these patients tolerate post-operative infections very poorly. For this reason extrapleural procedures are to be preferred.

AGE

I am aware of patients from the age of 2 years to the seventh decade of life who have successfully undergone pulmonary resection for tuberculosis (Bailey, personal communication). I have performed pneumonectomies for tuberculosis upon several patients in the fifth decade of life, and all have done well. In fact, when the case is suitable and respiratory function is adequate, I would usually prefer a single definitive excisional procedure in an older person. The deleterious effect in older people of multiple-stage procedures with their attendant increased risks from anaesthesia, respiratory and cardiac difficulties, and post-operative embolism is as apparent in the treatment of pulmonary tuberculosis as in other major surgery.

Resection is preferable to thoracoplasty in children and adolescents because of the severe deformity which results from thoracoplasty. Youth is no contraindication to resection; in fact, children and adolescents tolerate the extensive surgery quite well.

CONTRAINDICATIONS TO EXCISIONAL SURGERY

The contraindications to pulmonary resection for tuberculosis may be summarized as follows:

(1) *Uncontrolled Disease in the Contralateral Lung.*—Cavitary or extensive pneumonic disease

or an active, fresh spread in the contralateral lung rule out the possibility of excisional surgery until such time as the disease can be controlled by bed rest, streptomycin, or collapse therapy by pneumothorax or a localized thoracoplasty.

(2) *Tracheal Tuberculosis.*—This is a contraindication in cases which do not respond to streptomycin.

(3) *Respiratory Inadequacy of the Contralateral Lung.*—This is a contraindication whether due to a tuberculous or a non-tuberculous process. Emphysema, extensive pulmonary fibrosis, and bronchiectasis may be among the causative conditions. A contralateral extensive thoracoplasty may so impair pulmonary function as to render further excisional surgery impossible.

Occasionally the lung which is the more diseased and for which excision is contemplated proves on bronchspirometric studies to be of greater functional value than that which seems less diseased. For this reason, when bronchspirometry is available, separate function studies should be made of each lung.

(4) *Extensive Debilitating Extrapulmonary Disease.*—The coexistence of extensive tuberculous renal, adrenal, meningeal, or cerebral lesions or tuberculous pericarditis contraindicates excisional surgery.

An impaired cardiac condition, chronic glomerulo-nephritis, or severe hypertension detected in a case of pulmonary tuberculosis under consideration for excisional surgery contraindicates such treatment.

(5) *Extensive Amyloidosis.*—This, without evidence of renal insufficiency, may be considered only a relative contraindication to excisional surgery. Its presence, *per se*, is not a contraindication.

After the data have been amassed they must be considered by the physicians and surgeons in conference when the recommendation for excision may be made. However, only at the time of operation can the surgeon make the final decision as to the extent of resection necessary, and the final responsibility rests solely upon him.

THE USE OF STREPTOMYCIN IN EXCISIONAL SURGERY

At present very few patients are proposed for excisional surgery who have not already received one or more courses of streptomycin. Nevertheless, all patients receive 1 g. of streptomycin daily for one to three weeks before and about three weeks after the operation. Clinically, its action is evidenced by rapid diminution of the

amount of sputum, which is important in the avoidance of bronchogenic spreads of the disease during operation.

The administration of streptomycin for the treatment of extrapulmonary lesions should be co-ordinated with the treatment of the pulmonary disease. Gilbert (1948) has recommended that its use for laryngeal or endobronchial tuberculosis should be so timed that the maximum effect on the larynx will occur at about the time of the contemplated operation upon the lung. If draining sinuses are present, the streptomycin may be given for a somewhat longer period before operation. The amount of purulent drainage usually decreases markedly and a sinus may heal.

Streptomycin is administered intrapleurally before operation in cases of tuberculous and mixed-infection empyemas and is instilled locally in thoracostomy and Schede wounds. Buffered phosphate solution is used as a vehicle to maintain the pH of 7.35 for the optimal effect of the streptomycin. Post-operative administration is prolonged if spreads, wound infections, empyemas, or contralateral reactivations occur. In addition, in such cases, the dosage may be doubled or tripled with dihydrostreptomycin since eighth nerve complications are less.

PRE-OPERATIVE CARE

Once the decision has been reached to proceed with resection of the lung for pulmonary tuberculosis, a long period of preparation is usually unwise. Prolonged bed rest seems only to weaken the patient and renders early post-operative ambulation more difficult. In cases which are febrile and toxic nothing is to be gained from waiting for the fever to subside; indeed, further rapid progression of the disease is to be feared in such cases. In my experience, febrile patients withstand excisional surgery well.

Efforts to improve the general condition, and particularly the nutritional balance, are usually unavailing because of the ravaging effects of the disease. Blood studies may show a normal total protein level, but the albumin fraction is usually reduced. It is very difficult and usually impossible to raise the blood albumin value in spite of intensive administration of whole blood, plasma, concentrated serum albumin, and amino-acids. This is probably due to the negative nitrogen balance so often encountered in active tuberculous disease. I have found it preferable to be guided by the blood haemoglobin count in the administration of blood before and after operations, rather than to spend a prolonged period in the

attempt to "build up" a patient. Large amounts of blood are necessary.

Many patients are considered for pulmonary resection during the course of an inadequate pneumothorax which cannot be improved. It is my opinion that, in contrast to preparation for thoracoplasty, the lung should not be allowed to re-expand before operation since extensions of the disease and pleural complications may occur during this period in which the cavitory disease remains uncontrolled.

A contralateral pneumothorax should be maintained at a marginal degree of collapse to ensure maximum respiratory function during the operative period.

Other routine pre-operative measures include attention to dental hygiene, administration of vitamins, and an adequate diet.

OPERATIVE TECHNIQUE

ANAESTHESIA

Ordinarily I prefer general anaesthesia of nitrous-oxide-ether-oxygen administered through an endotracheal tube. In the more precarious cases with bronchopleural fistulae or unusually copious sputum, the endotracheal tube is inserted under topical anaesthesia and the general anaesthesia is begun only after the patient has been placed in the prone position, with the diseased side dependent. In rare instances of most profuse sputum and in cases of bronchopleural fistula without preceding thoracotomy, I open the chest under local anaesthesia and promptly expose extrapleurally and clamp the main bronchus, following which the general anaesthesia is begun.

The accumulating secretions must be aspirated constantly and the anaesthesia must be of sufficient depth to prevent coughing when the bronchus is handled. Adequate oxygenation is imperative. The oximeter (Millikan, 1942) is a useful instrument in the detection of anoxia during operations. It should be used as a routine when available since the anaesthetist cannot estimate the degree of oxygenation as accurately. Anoxia increases the strain on the already burdened heart, and may precipitate sudden failure.

POSITION DURING OPERATION

The prone position described by Overholt (1946) is used as a routine. It prevents, to a great extent, the spilling of secretions into the healthy portions of the lung and is a major factor in preventing bronchogenic spread. It is an excellent position for the posterior extrapleural approach and permits prompt exposure of the bronchus.

After the bronchus is clamped the problems of anaesthesia and dissemination of secretions are minimized. The lung falls forward and away from the mediastinum of its own weight and need not be retracted or manipulated.

The only real disadvantage of this position lies in the greater difficulty for the anaesthetist in proper observation of the patient, but experience overcomes this. The disadvantages formerly encountered of pressure effects on the brachial plexus and temporary swelling of the arms, hands, and dependent breasts have lately been avoided by modified position supports.

BLOOD TRANSFUSIONS

Liberal amounts of blood must be administered during the operation, through multiple intravenous cannulae if necessary. The average pneumonectomy requires about 2,000 ml. to 2,500 ml. of blood during and immediately after the operation. A difficult extrapleural resection may require two to three times as much, but this disadvantage of greater blood loss is more than compensated for by the other advantages of the extrapleural approach.

THE EXTRAPLEURAL APPROACH

In performing pneumonectomy or lobectomy for pulmonary carcinoma or suppuration which is primary (bronchiectasis or lung abscess) or secondary to neoplastic bronchial obstruction, I have for the past ten years preferred, when the

lung is widely adherent to the costal pleura, to free the lung by a complete extrapleural dissection and to remove the adherent pleura with the lung. In October, 1947, I described to the staff conference of the Brompton Hospital, London, this technique of extrapleural pneumonectomy and pleurectomy applied to pulmonary tuberculosis, which has made it possible to perform the operation successfully in many cases in which the operation might have been abandoned without removing the lung because a cleavage plane could not be established through the pleural adhesions. To have forced the dissection intrapleurally might also have led to damage to diseased lung with subsequent empyema.

In the past, surgeons who have attempted the removal of tuberculous lungs have reported that their greatest difficulties arose from the frequently extensive, dense pleural adhesions and the presence of enlarged matted tuberculous nodes at the hilum. These difficulties have at times led to the abandonment of the operative procedure or to the substitution of mass ligatures for individual treatment of the hilar vessels and the bronchus. Mass ligation, necessitating as it does transection of tuberculous tissue about a long bronchial stump, is frequently followed by bronchopleural fistula and empyema.

It has been my experience that the connective tissues about the bronchus near the carina and the adjacent vessels are not usually involved to any great degree in tuberculosis by the inflammatory processes of the lung and the pleura. In addition, the greatest degree of lymph node involvement has been at the region of the bifurcation of the main bronchus. Even in the most advanced cases of pulmonary tuberculosis, the infratracheal nodes and the peribronchial nodes of the main bronchus have usually separated from the bronchus quite easily if the peribronchial connective tissue sheath was incised and the bronchus freed within it.

Colour Plate I is a view of the mediastinal aspect of a lung removed extrapleurally in a case of empyema. It is of great importance and interest because it illustrates the abrupt linear end of the pleural thickening in the

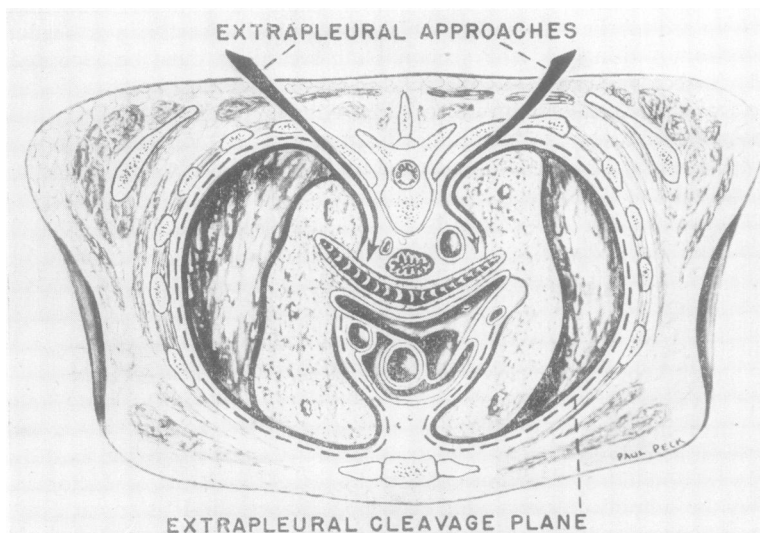
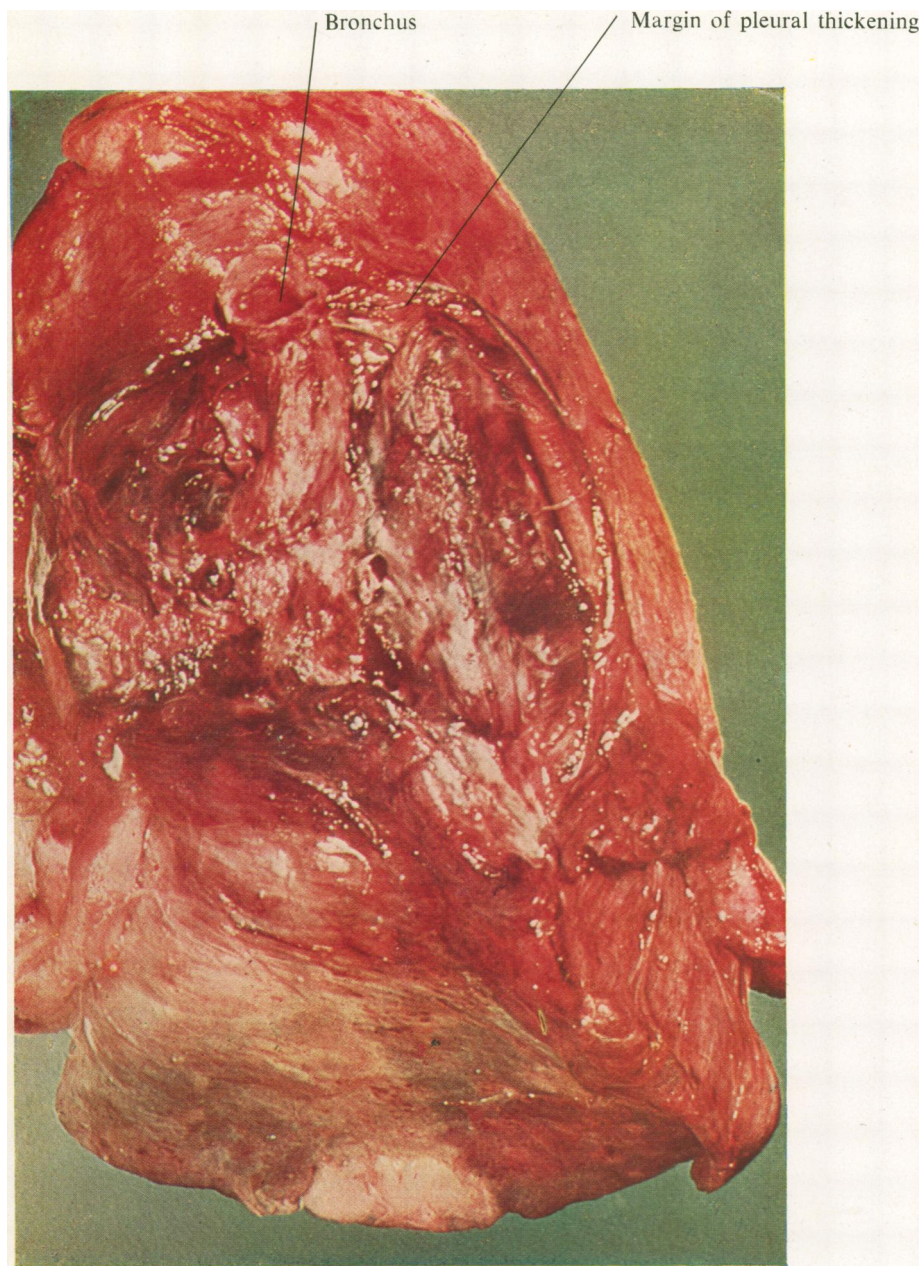


FIG. 22.—Diagrammatic sketch illustrating posterior extrapleural approach.



COLOUR PLATE I.—Mediastinal aspect of a lung which has been removed with the empyema by extrapleural pneumonectomy and total pleurectomy. The empyema is seen not to extend mediastinally nor, in this particular case, to the base of the lower lobe, nor to the diaphragm. This photograph shows the line of fusion between the parietal pleura and the visceral membrane of the empyema as an almost circular line extending about the mediastinal aspect above the hilus. The freedom of the mediastinal aspect from severe pleural adhesions is characteristic.

region where the parietal and visceral pleurae were fused. But whether a generalized or localized empyema is present, or just severe pleural thickening and adhesions, this process is perforce limited in extent by the boundaries of the pleural sac. The hilar pleura, joining the mediastinal and the visceral pleura, invests the hilar structures like a cuff. When the hilar area is approached extrapleurally (Fig. 22), the pleura with its adhesions is by-passed and the main bronchus is approached in a region proximal to the matted nodes at the distal portion of the main bronchus at its bifurcation. Once the posterior bronchial vessels and the pulmonary branches of the vagus have been divided and drawn medially, the bronchus at the carina is usually quite easily dissected free inside its fascial envelope. The division of the bronchus and the suturing of the proximal end and the ligation of the vessels is achieved in an unobstructed and clean field.

Extrapleural pneumonectomy, therefore, is especially applicable in tuberculosis and I believe it is preferable to intrapleural resections in all cases because, first, dense pleural adhesions which might otherwise prevent completion of the operation are circumvented; second, the bronchus can be more easily and rapidly reached, freed, and clamped than if a difficult, tedious transpleural dissection is done. This rapid approach to the bronchus, permitting it to be clamped early in the operation, is important in preventing spread especially if a bronchial fistula is present or if there is bleeding; third, the dissection is always easier and safer than when it is done transpleurally, and there is lessened danger of damage to cavity walls and diseased lung; and, fourth, this procedure removes the parietal pleura. This membrane has no useful function after pneumonectomy and its removal eliminates its great secretory and reactive power and any foci of pleural tuberculosis. Its function as a so-called "limiting membrane," preventing the spread of infection to the mediastinum, can apparently be dispensed with since the source of infection has been removed. The extrapleural tissues seem to be more resistant to infection and do not react with troublesome exudation and caseation but rather with productive changes.

Usually a long segment of the sixth rib is resected subperiosteally posteriorly, and the fifth and seventh ribs are divided paravertebrally by resecting very short segments. The extrapleural dissection is begun as for an extrapleural pneumothorax and, at first, is directed paravertebrally toward the hilum of the lung. The pleural thick-

ening ends, usually, on the left as the mid-portion of the lateral surface of the aorta is reached and on the right at a level just anterior to the paravertebral trunk of the azygos vein (Fig. 22). The oesophagus may be exposed from either side at this level and care must be taken to avoid damaging it. The azygos vein is ligated and divided during all right pneumonectomies or upper lobectomies to facilitate the exposure of the right upper lobe bronchus at its origin and the right main bronchus at the carina. The vagus nerve is freed and lifted medially, at which point one or several of the bronchial arteries or veins may be demonstrated and then ligated and divided. The pulmonary branches of the vagus are divided and the adventitial fascia (which is usually only slightly thickened) about the main bronchus is incised so that the bronchus may be freed in a plane in which it separates quite easily from the adherent tuberculous nodes.

On the left side, one must be particularly careful to free the bronchus from the surrounding fibrous and connective tissues under the aortic arch to avoid leaving a long bronchial stump which cannot retract into the mediastinal tissues.

As the dissection proceeds, the infratracheal and peribronchial nodes may be excised or delivered and drawn laterally toward the lung and later removed with it. The carina is identified and the bronchus is clamped just distal to it with a right-angle toothed clamp to prevent the spilling of secretions from the lung as the bronchus is cut, and to facilitate traction on the bronchus. No clamps or caustics are applied to that part of the bronchus which is to remain. One guide suture of silk is placed at each side in the bronchial wall at the proposed line of section. The bronchus is cut across for a short distance and then the proximal cut end is closed by an interrupted fine silk end suture. This procedure is repeated in alternation until the bronchus has been completely divided and sewn over by one row of interrupted sutures approximating the membranous wall to the cartilaginous wall close to the carina. The bronchus is thus the first structure to be divided and the anaesthetist's difficulties and the danger of spread are thereby lessened.

The apex is then freed extrapleurally, usually with ease, even though the underlying cavitory lung may be densely adherent to the parietal pleura. This ease of dissection is in contrast to the great difficulty often experienced in intrapleural dissection in such cases. In addition, the danger of rupture into a cavity or adjacent diseased lung is much less during an extrapleural

dissection. Bleeding points must be secured by suture ligatures, and care must be taken to avoid injury to the sympathetic trunk, the phrenic, vagus, and recurrent laryngeal nerves. After the hilar and apical dissection is finished and the exposed areas have been protected by moist pads, the extrapleural freeing of lung, and, if present, empyema wall is continued. The older the empyema and the thicker its wall, the less

between the empyema wall and the diaphragm is ordinarily difficult to identify and enter from its lateral margin since this usually lies in the zone of great thickening at the costo-phrenic sulcus. I begin this phase of the dissection from the mediastinum. As the lung is dissected from the diaphragm, the medial margin of the diaphragmatic portion of the empyema wall becomes apparent and the proper cleavage plane is entered more easily. Great care must be taken to avoid severe damage to the diaphragm during this difficult phase of the dissection. Division of the phrenic nerve to paralyse the diaphragm may facilitate the identification of the diaphragm for the dissection. If the diaphragm is injured it should be repaired by sutures at once. On the several occasions in which this has been observed, no infection supervened below the diaphragm. At times the pleura and the empyema membrane cannot be dissected completely from the diaphragm and small bits of infected tissue may be left. This residuum of infection and even associated operative contamination due to rupture of an empyema or cavity does not seem to lead to empyema after the entire pleura (visceral and parietal) has been removed.

At the end of the operation, the hemithorax is usually washed with warm saline to reduce mechanically the degree of contamination. The wound is closed in layers by interrupted silk sutures after an intercostal drainage tube has been placed. When, in extrapleural pneumonectomy, the thickened pleura has been removed, the pre-existent mediastinal fixation is no longer present, and one must anticipate difficulties from the mobile mediastinum if proper drainage is not instituted or if an extensive thoracoplasty is performed at the same time. It has been shown by the animal experiments and clinical experience of Reinhoff and others, and confirmed in my own clinical experience, that a high resection of the main bronchus which permits the stump to retract into the mediastinum and to be covered promptly by adjacent structures is more important than complicated closures which leave longer stumps. In addition, a high resection is more likely to be performed through a healthy bronchial wall. The cut end of the bronchus

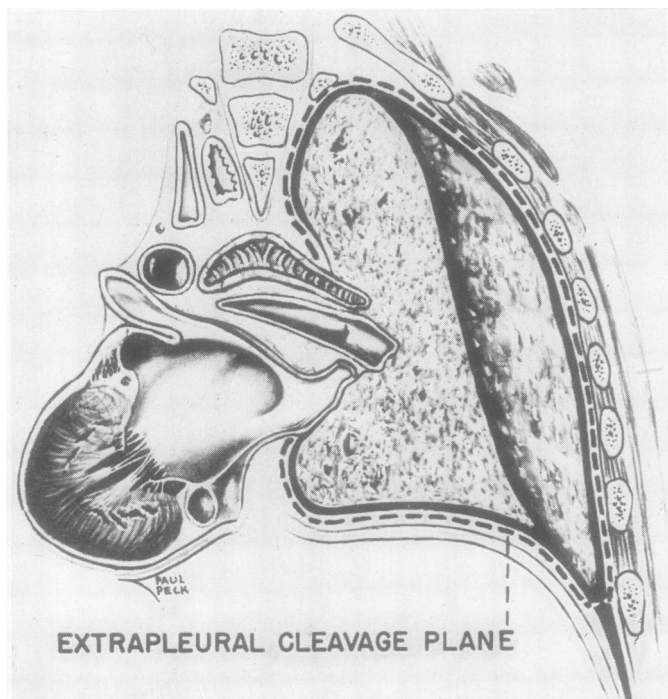
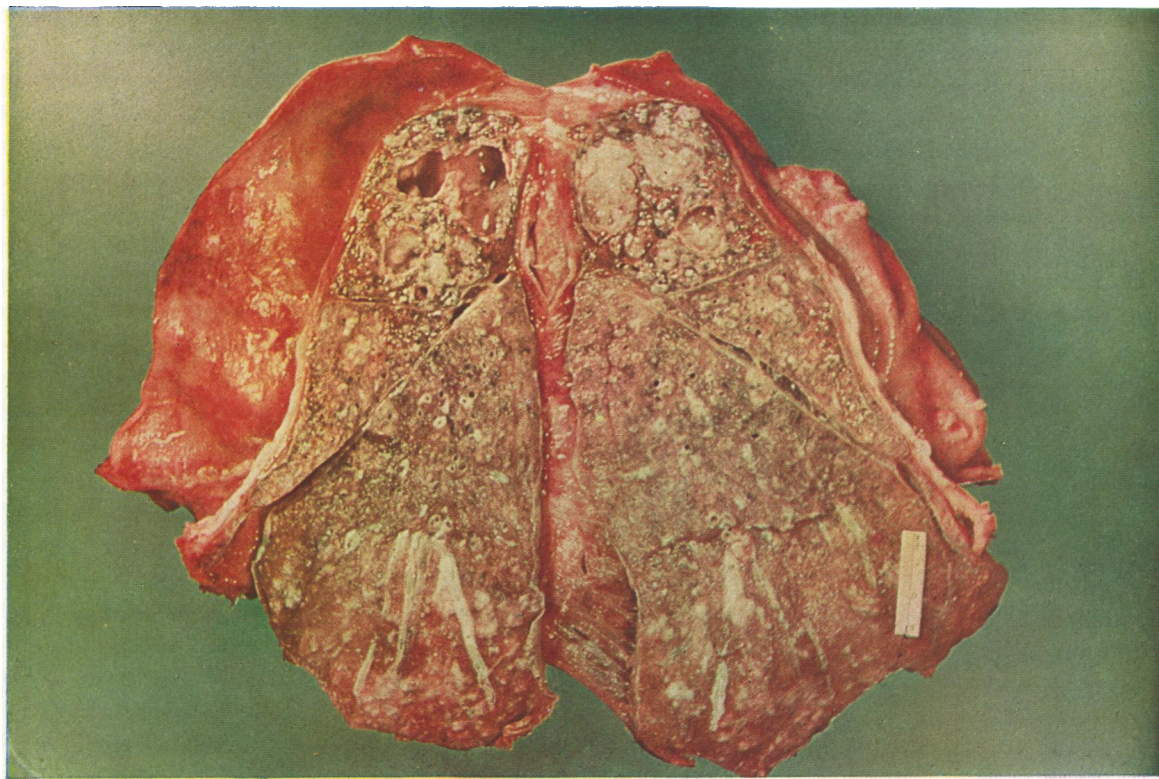


FIG. 23.—Sketch illustrating the extrapleural cleavage plane and the small diaphragmatic representation of an empyema.

danger there is of perforating into the empyema during dissection (Colour Plate II). Most frequently the lung is adherent over a large part of the diaphragm and the empyema has only a relatively small diaphragmatic representation (Fig. 23 and Colour Plate III). Inasmuch as the greatest danger of contamination of the field may be expected during the dissection of the empyema wall from the diaphragm, this part of the operation is left for the last and the wound is packed with moist pads before proceeding. One can minimize the extent of contamination by completing the hilar, mediastinal, and apical dissection and then dissecting down to the diaphragm or to the thoracostomy or sinus opening, if one exists. The cleavage plane



COLOUR PLATE II.—Parietal aspect of the empyema which has been removed intact with the lung by extrapleural dissection.

plays little part in its healing. The bronchial stump is sealed by the overgrowth of granulation tissue. Consequently, a long stump which is prevented from retracting into the mediastinum by adhesions to the pleura and to the extrapleural and peribronchial connective tissues is an invitation to a fistula. It is my practice to transect the bronchus just far enough from the carina to permit of a firm base for the single row of interrupted silk end sutures. Pleuralization of a long stump is no safeguard against subsequent bronchopleural fistula. In extrapleural pneumonectomies, pleura is not available to cover the very short stump which retreats freely into the mediastinum, the structures of which frequently cover it at once; however, I do cover the hilar area with a sheet of "gelfoam."

It is possible that the lesser incidence of clinically evident bronchopleural fistula after extrapleural dissection in contrast to intrapleural pneumonectomies is due, at least partly, to the greater ease with which one can free the bronchus to the carina through the soft, clean tissues of the extrapleural approach in contrast to the frequently difficult, tedious dissection through the matted hilar structures transpleurally.

Tchertkoff and Selikoff (1947), studying the results of excisional surgery at Sea View Hospital, have investigated 77 consecutive pneumonectomies, of which 25 were done extrapleurally and 52 intrapleurally. In the series of 52 intrapleural pneumonectomies, 21.2% developed bronchopleural fistula, empyema, or both, and 9.6% suffered spread of the disease. Of this group of 52 intrapleural pneumonectomies, there were 9 deaths (17.3%). In the 25 cases in which extrapleural pneumonectomy was performed because of empyema or pleural symphysis, there were no deaths, no empyemas, no spreads, and no failures.

Contamination of the operation field from rupture into a pulmonary cavity or from incision through densely adherent tuberculous tissue is largely eliminated in extrapleural dissection, but rupture into an empyema (when present) occurs frequently. However, such contamination is less likely to be followed by empyema after the pleura has been removed. Tchertkoff and Selikoff studied 23 consecutive pneumonectomies in which a cavity or empyema was entered at the time of operation. Of 12 intrapleural pneumonectomies, 6 developed empyemas. Of the 11 extrapleural pneumonectomies with operative contamination (from empyema), none developed post-operative empyemas.

In their theoretical analysis, Tchertkoff and Selikoff noted that the pleura is sensitive to infection, responding to contamination with exudation and caseation and resulting empyema. In contrast, the extrapleural tissues which line the thoracic cavity after the parietal pleura has been removed are relatively resistant to infection and respond to contamination with productive changes and no empyema. This description of the role of the pleura in resection for pulmonary tuberculosis and the observations of these workers form a theoretical basis for many of the recent advances in extrapleural excisional surgery for pulmonary tuberculosis.

Much more work remains to be done in the elucidation of these observations. One important clinical-surgical point which I have learned is that if a pneumonectomy is to be performed in a case in which an effusion containing tubercle bacilli has been present intrapleurally during a preceding period of pneumothorax therapy, the pneumonectomy should be performed extrapleurally since it is likely that a caseous pleura will be found over the expanded lung.

When thoracostomy and cavernostomy openings and empyema necessitatis and other sinus tracts are cut across during an intrapleural pneumonectomy, an empyema or wound infection is usually invited. It is my impression from as yet limited experience that when, however, they are removed *en bloc* with an extrapleural pneumonectomy, they seem less likely to lead to empyema or prolonged wound infection.

EXTRAPLEURAL APPROACH TO UPPER LOBECTOMY

Densely adherent upper lobes, especially those containing large cavities close to the surface, may be freed more easily and with lessened incidence of cavity rupture if the dissection is done extrapleurally. The closely adherent pleura should be removed with the lobe, but the less adherent and adjacent pleura may be permitted to remain to retain its absorptive and gliding functions to aid in the prompt re-expansion of the remaining lung.

The hilar structures are approached extrapleurally and treated as usual by individual ligation and division. Routine division of the azygos vein, on the right, is of great usefulness in exposing the right upper lobe bronchus and the apical branch of the pulmonary artery.

TRANSECTION OF TUBERCULOUS TISSUE

The transection of tuberculous tissue at the time of pulmonary resection may be a source of complications. These complications include pulmonary spread of disease, empyema, bronchopleural fistula, and wound infection. In general, it is my practice not to resect through tuberculous lung but rather to increase the extent of the resection to avoid such a contingency. For example, where the natural interlobar fissure cannot be developed surgically because of severe adhesions, the resection is carried through the healthy tissue of the adherent lobe or, when necessary, the adherent lobe or segment is also removed. If, during an upper lobectomy, the apical segment of the lower lobe is found to contain extensive nodular disease, a segmental resection is performed with the lobectomy.

The matting of tuberculous nodes at the interbronchial and peribronchial areas may, unless the dissection is performed extrapleurally, render difficult or impossible the individual ligation of the pulmonary vessels and the bronchus. If the surgeon resorts to mass ligation, of necessity transecting tuberculous nodes and pulmonary parenchyma, the incidence of bronchopleural fistula and empyema is greater. It was because of this technical difficulty and subsequent calamity that the resection of tuberculous lungs was for so long deemed too hazardous.

If the involvement of the interbronchial nodes and connective tissues renders lobectomy hazardous technically and requires transection of tuberculous tissue, I prefer to proceed with pneumonectomy.

DRAINAGE

Every case should be drained to aid in the prompt re-establishment and maintenance of relatively normal intrathoracic pressures. Controlled suction drainage is especially important in cases of partial excision to assist the rapid re-expansion of the remaining lung. In upper lobectomies or segmental resection, anterior and posterior intercostal drainage tubes are inserted as an additional safety measure to prevent anterior collections of fluid and air. The anterior tube is led up to the apex and loosely fixed to the chest wall by a stitch.

Simple underwater drainage after pneumonectomy may lead to abnormally low intrapleural pressures and thus controlled suction drainage with a pressure of -10 or -15 cm. of water is preferable.

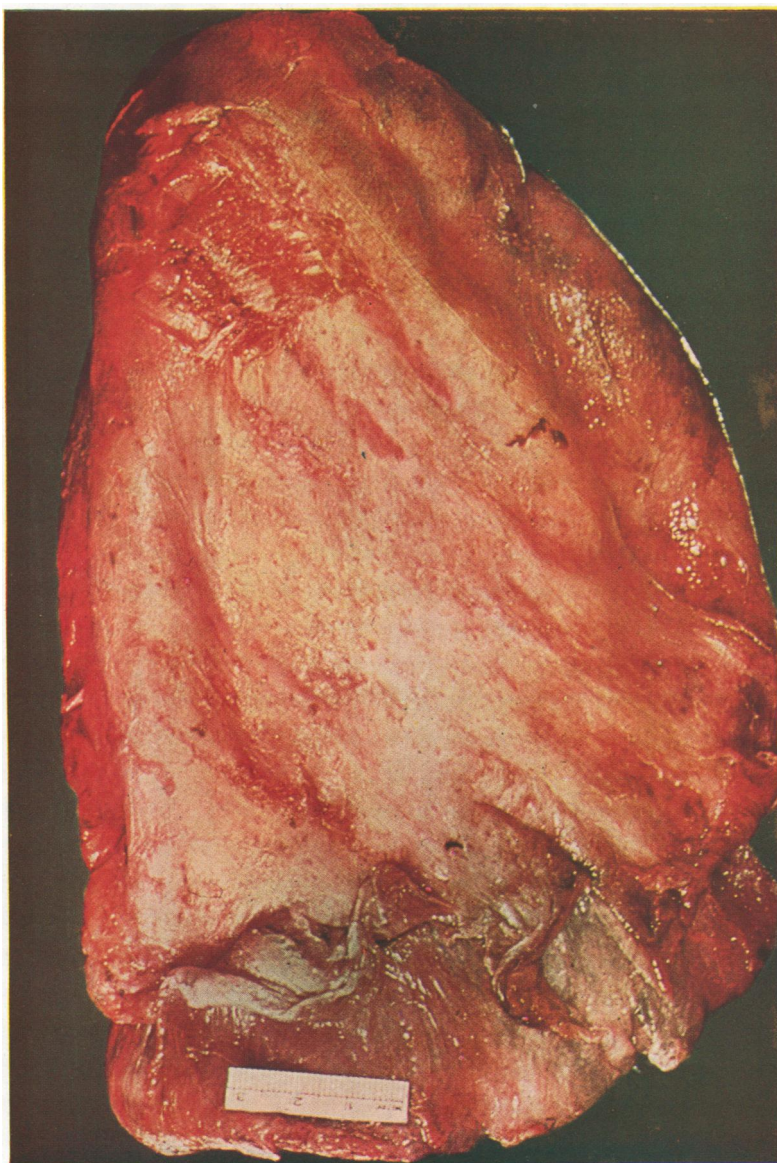
CONDUCT OF CONTRALATERAL PNEUMOTHORAX DURING AND AFTER THE OPERATION

The presence of a contralateral pneumothorax presents a special problem. The contralateral pneumothorax should be partially re-expanded and maintained at a marginal degree before operation. This is essential if pneumonectomy is contemplated, and one must realize that any case in which a lobectomy has been planned may result in a pneumonectomy for technical reasons or because unsuspectedly extensive disease is found. Therefore, marginal re-expansion is desirable in all cases regardless of the extent of the resection planned.

Difficulties due to the contralateral pneumothorax arising during the operation have been uncommon in my cases hitherto. The early clamping of the bronchus decreases at once the difficulty of the anaesthetist who can thenceforth, without trouble from secretions, manage the lung which is under pneumothorax. In only one case has it been noted that the clamping of the bronchus to the diseased lung reduced the ventilatory capacity sufficiently to cause dyspnoea. In this case, as soon as the anaesthetist noted the diminution in exchange and the difficulty in breathing, an assistant removed 100 ml. of air from the pneumothorax. This was sufficient to relieve the difficulty in breathing and the operation proceeded without incident. I might add that this patient also had well-compensated mitral stenosis.

Case 20 (Pneumonectomy with Contralateral Pneumothorax).—In 1943 T.J., a man aged 28, developed a right pleural effusion, which cleared. In 1946 a cavity was detected in the left upper lobe. A pneumothorax was induced and, after pneumonolysis, the cavity closed and the sputum became negative. Early in 1947 after recurrence of positive sputum, a cavity was found at the right apex. Haemoptyses occurred, but a right pneumothorax could not be induced. The left lung was permitted to re-expand almost completely and pulmonary function tests showed adequate function. It was decided that the patient could undergo excisional surgery despite a long history of rheumatic heart disease with attacks of rheumatic carditis in 1934 and 1939. Apical diastolic and systolic murmurs were present, and the cardiologists confirmed the diagnosis of mitral stenosis. However, no active carditis was present.

Extrapleural pneumonectomy was performed on May 25, 1948. When the bronchus was clamped some difficulty in his breathing was noted. The bronchus clamp was removed and the operation halted while 100 ml. of air was removed from the left pneumothorax. The operation was resumed, and this time when the bronchus was clamped there was no dyspnoea and the extrapleural pneumonectomy was



COLOUR PLATE III.—Cut section of lung and empyema sac. The thickness of the empyema walls in a chronic case is well shown. The limited representation of the empyema on the diaphragmatic aspect in this case is illustrated.

completed. The sputum became negative at once. The patient's left pneumothorax is still being continued and he is well one year later (Fig. 24). He has no dyspnoea on exertion.

In the post-operative period, pneumothorax refills should be small and frequent with extreme care to avoid traumatic pneumothorax. Small-calibre needles should be employed so that if accidental lung puncture occurs the degree of perforation is minimized. I am aware of several instances of traumatic pneumothorax during the post-excisional management of the contralateral pneumothorax, and all were successfully controlled by deflation, without loss of the pneumothorax. After each refill the patient should be observed carefully for evidence of traumatic pneumothorax. If this is observed, deflation—either intermittent or continuous—should be instituted early and oxygen therapy given promptly to avoid cerebral or cardiac anoxia. The insertion of a soft rubber catheter in an anterior intercostal space may be preferable to the use of a large needle for continuous deflation, especially if suction is to be employed.

SPECIAL MANAGEMENT OF CASES WITH EMPYEMA BEFORE EXCISIONAL PROCEDURES

When it has been decided that an excisional procedure is necessary, it is wise to proceed with it as quickly as possible. Antibiotic therapy will, of course, have been instituted in all these cases. The presence of fever and toxicity is not a contraindication to operation but rather an indication for prompt intervention.

Every effort should be made to prevent bronchogenic spreads through patent bronchopleural fistulae in the time before the excisional procedure. One of the best measures is to perform the excision as soon as possible. In general, I believe that if a thoracostomy can be avoided, the operative procedure is simplified. If thoracostomy drainage is not undertaken, it is important to attempt to prevent spreads by repeated aspirations of the infected pleural contents and by maintaining the patient on the diseased side and avoiding medications that suppress cough.

Although it is possible to avoid thoracostomy in many cases with small bronchopleural fistulae, if the bronchopleural fistula is large it may be necessary to perform a preliminary thoracostomy

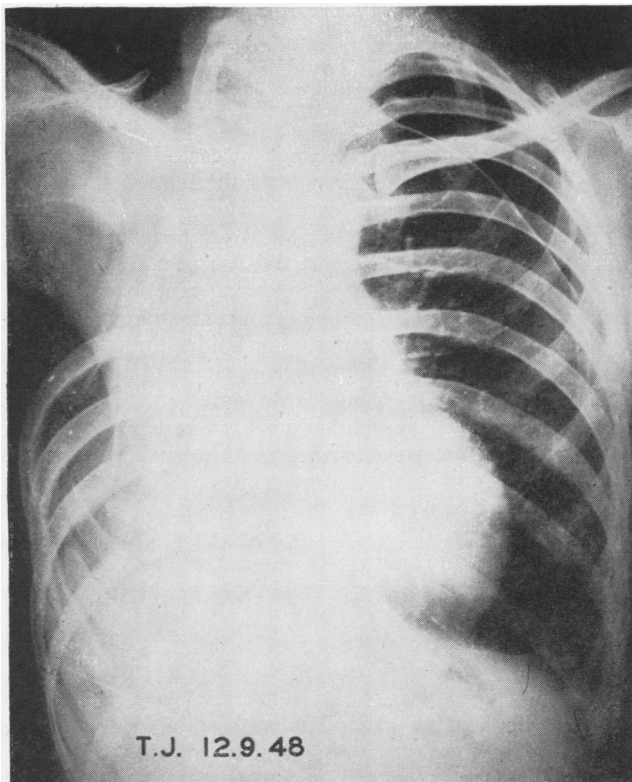


FIG. 24 (Case 20).—Six months after pneumonectomy performed in presence of a contralateral pneumothorax.

for relief of a tension pneumothorax and rapidly reaccumulating empyema fluid. Excision should not be delayed after thoracostomy, just as it was formerly considered that thoracoplasty should follow promptly to avoid the rapid deterioration of the patient's general condition during a prolonged attempt to minimize toxicity and "build him up." Spreading infections of the chest wall, continually rekindled by the discharges from the empyema, may complicate prolonged periods of drainage.

The application of antibiotics and other preparations locally may encourage a cleaner appearance of the wound, but does not seem to influence fever and toxicity. Simple sinus and empyema necessitatis tracts may shrink or even close with local and parenteral antibiotic therapy; but in my experience this has not occurred in thoracostomy wounds as long as the infected fistulous lung is present.

Cases of empyema without bronchopleural fistula present no unusual respiratory difficulties at operation. But the induction of general anaes-

thesia by a closed system may cause a patient with a bronchopleural fistula and without a thoracostomy to manifest a tension pneumothorax as the gases under pressure enter the pleural cavity and cannot escape.

This situation occurred in the first case of this kind that I attempted. Shortly after the induction of anaesthesia, respiration ceased. My experiences with chest wounds during the war were suddenly recalled to me, and I inserted a large-calibre needle into the pleural space, releasing much gas under great tension. The patient recovered, and one week later, after tracheal intubation under topical anaesthesia, the chest was opened posteriorly and the hilum was approached extrapleurally under local anaesthesia. The main bronchus was ligated by a heavy silk tie, and then a general anaesthesia was induced and carried on with no difficulty during the remainder of the operation. This procedure, which I use as a routine in cases of bronchiectasis with unusually large amounts of sputum, may be the procedure of choice in the type of case described above. An alternative measure may be the insertion of a large needle or cannula through the chest wall or a small intercostal incision under local anaesthesia before the induction of the general anaesthesia.

Streptomycin and penicillin are injected into the "pleural" space frequently in the post-operative course. In my earlier cases, buffered phosphate solution at pH 7.35 was used as a vehicle; latterly I have omitted this.

POST-OPERATIVE MANAGEMENT

In the closing half-hour of the operation it is wise to have the extreme Trendelenburg position slowly corrected until the patient is lying horizontally. Sudden collapse and even death has been observed when a patient has been moved suddenly on to his back from the extreme position necessary during the operation. The explanation for this phenomenon remains obscure. Efforts to avoid sudden mediastinal shift by avoiding rapid changes of position, and to prevent tension pneumothorax by attachment of the underwater sealed drainage before turning the patient, certainly seem to be required.

The patient's bed is brought to the operating room to avoid an intermediate journey on a stretcher. The anaesthetic having been continued to this point, bronchoscopy is performed after the patient has been transferred to the bed. I believe that routine post-operative bronchoscopic removal of the accumulated secretions is of great importance. No matter how carefully aspirations with

a catheter are done, much secretion pools around the endotracheal tube.

Trans-nasal tracheal suction by a Levine tube is performed every three or four hours until the patient can expectorate freely, usually after two to three days. Assiduous attention must be paid to this procedure for prevention of post-operative spread, atelectasis, and pneumonia. The introduction of the rubber tube into the trachea stimulates violent coughing with subsequent expectoration, which is as important as the actual suction used. One need have no fear that the violent cough or the application of the catheter may damage the bronchial closure.

An intercostal nerve block of several nerves above and below the incision with procaine in oil is performed before the chest wall is closed to minimize post-operative pain and permit easier coughing. Medications which suppress cough should be used sparingly, but sufficient sedative given to reduce pain so that the patient will cough. Support of the chest wall by attendants is helpful when the patient has difficulty in expectorating the sputum. Dr. Coleman B. Rabin recently pointed out to me the helpful use of bronchodilators, such as adrenaline or aminophyllin, when a cough is ineffective because bronchial spasm prevents ingress of air and diminishes the expulsive power of the cough. In asthmatic patients, antihistaminics, such as pyribenzamine, may be useful.

In rare cases with profuse and viscid secretions which cannot be controlled except by continuous aspirations and bronchoscopy, removal of the secretions may best be accomplished through a tracheotomy performed for this purpose. I have seen this to be a life-saving measure in one case.

Oxygen is administered for a varying period after operation—usually no longer than 24 hours. Several blood transfusions are usually given in the days following operation, and the blood haemoglobin level is used as a guide.

Penicillin and streptomycin are given parenterally for three weeks following operation. Usually 1 g. of streptomycin is injected into the pleural cavity at each intrapleural pressure adjustment in the post-operative period.

Drainage tubes after pneumonectomies are removed when the drainage becomes insignificant or ceases, usually 24 to 48 hours after operation. Drainage of bloody fluid is usually more profuse and prolonged after an extrapleural than after an intrapleural pneumonectomy. This greater loss of sanguineous fluid, requiring more replacement, is counterbalanced by the greater ease and safety

during the operation and the lesser incidence of other post-operative complications.

Drainage tubes are removed after lobectomy when they cease to drain, and fluid and air are thenceforth removed by aspiration until the remaining lung has re-expanded as completely as possible. Difficulties in drainage can be minimized by using large (26–28 French gauge) soft rubber catheters with numerous openings and large-calibre glass connexions. Irrigation of blocked tubes is to be deprecated. If tubes cease to function as drains they should be removed and drainage continued by aspirations as frequently as necessary.

Patients are encouraged to sit up over the side of the bed as soon as they react and are allowed out of bed within 24 hours. Drainage tubes are, if necessary, clamped off while the patient is out of bed.

THORACOPLASTY FOLLOWING PNEUMONECTOMY OR LOBECTOMY

The need for a routine thoracoplasty following pneumonectomy or lobectomy is not yet definitely established. Those who favour routine post-excision thoracoplasty stress the necessity of preventing over-expansion of the remaining lung and of obliterating the potential empyema space.

Clinical observations and function tests by Ornstein (1949) and others failed to reveal definite evidence of lung damage due to over-expansion. Cournand and others (1947), and Birath, Crafoord, and Rudstrom (1947), have noted some compensatory emphysema with increased residual air in patients after pneumonectomy. They state, however, that the functional capacity of the patients examined is not abnormal under ordinary conditions.

Clinically we now have many patients who have undergone pneumonectomies and lobectomies for tumours and suppurative conditions of the lung, and there is no evidence in my personal experience that a patient's functional capacity is damaged by the amount of over-expansion which ordinarily takes place. Davis (1947) reports the case of an aircraft pilot aged 42 who, following pneumonectomy for carcinoma, presented no evidence of abnormal pulmonary function compared with a healthy control until an altitude of 18,000 feet was attained in a test chamber. However, the problem in tuberculosis is somewhat different. Tuberculosis is a disease in which there may have been a more or less generalized dissemination through the lung, and the question has been raised whether or not these non-cavitary pulmonary foci may be encouraged to break down by the over-expansion of the lung. The question

concerns the possibility of reactivation of encapsulated caseous foci and diminution in the degree of encapsulation by the perifocal reaction if the lung is over-expanded. It is probably safer to withhold thoracoplasty in cases of old healed foci than in cases of more recently healed disease. It is certainly more important in all cases by most careful study to rule out the presence of homolateral lobar or contralateral active and cavitary disease before the resection than to be concerned unduly about post-resection thoracoplasty.

Until recently, I routinely performed a limited thoracoplasty—usually in one stage—about two weeks after each lobectomy or pneumonectomy. If more than one stage was required, they were spaced at two-week intervals. Following Overholt's suggestion, in an attempt to minimize the deformity, transverse processes and the first rib were not removed. The thoracoplasty is thus of much smaller extent than the operation performed to collapse a cavitated lung.

At present, because I doubt the necessity for routine post-excision thoracoplasty, and in an attempt to find out for myself what will happen, I do not perform a thoracoplasty after lobectomy if the remaining apparently healthy lung has filled the pleural cavity, nor after simple extrapleural pneumonectomy. A partial thoracoplasty seems indicated to close a residual pleural space after an upper or upper and middle lobectomy. Until the present I have considered a thoracoplasty to be essential following extrapleural pneumonectomy and total pleurectomy for pulmonary tuberculosis with empyema; but one of my latest cases is in excellent health five months after pneumonectomy and pleurectomy, during which the operative field was contaminated from the empyema and in whom no subsequent thoracoplasty was performed. Of course it is too soon to be certain of the result.

In children or adolescents, thoracoplasty following excision would seem particularly to be contraindicated, to avoid deformity. In exceptional cases in children in whom thoracoplasty may be required, it may be wise to consider a fusion of the spine before the thoracoplasty to prevent extensive deformity.

Thoracoplasty is contraindicated in patients who have diminished or borderline pulmonary functional capacity (especially ventilation) before the pneumonectomy. Ornstein (1949) has pointed out the further reduction in ventilatory capacity which occurs in such patients if a thoracoplasty is added.

The performance of an adequate thoracoplasty is no insurance against the occurrence of a late bronchopleural fistula and empyema, but it is

TABLE IV
COMPLICATIONS AFTER PULMONARY RESECTION FOR TUBERCULOSIS IN 125 CONSECUTIVE CASES, 1946-8
(SELIKOFF AND TCHERTKOFF*)

	Intrapleural Pneumonectomy	Extrapleural Pneumonectomy	Lobectomy	Segmental Resection	Total
	(65)	(33)	(21)	(6)	(125)
Empyema and bronchopleural fistula ..	10	—	1	—	11
Tuberculous empyema	2	—	—	—	2
Patent lobar bronchus	—	—	1	—	1
Wound infection without post-operative empyema	3	1	1	—	5
Fatal operative spreads	2	—	1	—	3
Fatal operative shock	1	1	1	—	3
Thoracoplasty death	—	—	—	1	1
Failure of sputum conversion (all causes)	4	2	6	1	13

*Data to be published

true that the empyema space has then already been markedly reduced in size. Deaths and spreads of disease in the remaining lung have occasionally followed thoracoplasty.

The phrenic nerve is not interrupted after lobectomy but is permanently interrupted during pneumonectomy. I have had no experience with the use of pneumoperitoneum nor of intrathoracic prostheses after pneumonectomy.

COMPLICATIONS AND CAUSES OF FAILURE

The incidence of complications after excisional procedures for pulmonary tuberculosis, as well as the mortality rate, has been steadily reduced. Table IV is an analysis of the total complications in 125 consecutive cases (Selikoff and Tchertkoff, data to be published).

EMPYEMA AND BRONCHOPLEURAL FISTULA

Bronchopleural fistula, empyema, and severe wound infection, usually occurring together, remain the most frequent and dangerous complications. Of 125 cases, such complications occurred in ten following intrapleural pneumonectomy, in one following lobectomy, and in none after extrapleural pneumonectomy.

Tuberculous empyema without bronchopleural fistula occurred after pneumonectomy in two cases. If not due to contamination at operation, this is probably due to caseous pleura or lung tissue remaining after an intrapleural or an incomplete extrapleural dissection. Extrapleural pneumonectomy circumvents the areas of greatest operative difficulty, and pleurectomy minimizes the effects of contamination by removing the membrane which reacts most vigorously and caseates. It is uncommon for empyema

to occur following extrapleural pneumonectomy. Should an empyema occur if some caseous pleura has been permitted to remain, the resulting infection is quite different in clinical behaviour. Toxicity is absent and the empyema appears benign. The reason for this may be the absence of most of the pleura with its tremendous absorptive capacity.

Empyemas which occur in post-thoracoplasty failure resections do not seem to be very severe clinically even after an intrapleural resection. This may be because of the reduced size of the space and the reduced absorptive capacity of the pleura from the reduction in its surface area and the scarring following thoracoplasty.

Tuberculous empyema which occurs soon after the resection is usually associated with extensive wound infection, dissolution, and sinus formation. Especially if a bronchopleural fistula is the basis for the empyema, the patient's course is rapidly and progressively downhill even if the complication has occurred at rather a long time after the resection. If death does not occur from toxæmia or bronchogenic spread of the disease, amyloidosis supervenes rapidly even in patients who showed no evidences of it before operation. Therefore, when an empyema and a bronchopleural fistula become evident, treatment should be prompt while the patient is still in a condition to withstand surgery.

The management of post-pneumonectomy empyema and of empyema with bronchopleural fistula has until the present been very unsatisfactory. The conventional treatment by drainage and thoracoplasty, even when combined with bronchoplasty, continues to yield uniformly bad results. I believe that this plan of treatment will continue to fail because the core of the problem—the caseous and infected pleura—is permitted to remain to perpetuate the disease. As complete a

pleurectomy as possible is required with the addition of a bronchoplasty when a bronchopleural fistula is present. This must be done early since total pleurectomy becomes exceedingly difficult if the pleural involvement is of long duration.

The removal of the thickened pleura renders it feasible to obliterate the "pleural" space by a subsequent thoracoplasty without excision of the intercostal tissues and periosteum. The absence of the infected pleura permits the wound to heal even if sinuses and chest-wall infection have been present previously, and the entire procedure may obviate failures of empyema closure and wound healing, and the deformity, excessive chest-wall mobility, and prolonged healing period of even an ultimately successful Schede thoracoplasty. This operation was suggested by Tchertkoff and Selikoff (1947) and was accomplished successfully on a cadaver by Levine and Stern (personal communication).

Recently, two cases suffering from empyema following pneumonectomy for tuberculosis were transferred to my care. One had a tuberculous empyema, a grossly infected wound, and several large sinuses but no demonstrable bronchopleural fistula. The other had a large bronchopleural fistula with mixed-infection empyema and was particularly toxic and ill. I performed a pleurectomy on each, thereby almost completely excising the seat of the disease. On the second patient I re-amputated the bronchus at the carina, removing a bronchus stump 1.5 cm. in length. It was most spectacular, as the adherent pleura and extrapleural tissues were cut from the fistulous bronchial end, to see the bronchus retract and practically disappear into the mediastinum whence it had to be retrieved for the re-amputation at the carina through clean tissues. This was a dramatic illustration of the manner in which a lengthy bronchus stump is retained at the pleural margin, following an intrapleural pneumonectomy, by the extrapleural and peribronchial tissues adherent to it which prevent it from retracting. After the extrapleural and peribronchial fibrous tissues have been separated from the bronchus in an extrapleural dissection and the bronchus is cut close to or at the carina, the stump can retract freely into the mediastinum. Although the extrapleural space was contaminated in both these cases, the post-operative course was benign.

*Case 21 (Tuberculous Empyema with Wound Infection and Sinuses).—*W.M.N., a woman aged 26, underwent a left pneumonectomy in the presence of a contralateral pneumothorax on December 14, 1948. Immediately thereafter her course was febrile (temperature 101° F. to 105° F.); her wound was found to be infected and a sinus appeared within a few days. The pleural fluid became purulent and accumulated rapidly. No bronchopleural fistula could be demonstrated (Fig. 25a). A course of dihydrostreptomycin was begun and, after the patient had been transferred to my care, operation was performed on February 8, 1949. Under general anaesthesia, the wound and sinus openings were excised. The chest wall was extensively involved by tuberculosis and the pleura was about 1 cm. in thickness. As complete a parietal, diaphragmatic, and mediastinal pleurectomy as possible was performed. The greatest difficulty was encountered over the aorta and below the arch over the oesophagus so that a portion of the caseous wall (probably only partly pleura in this region) about 4 cm. in width and 20 cm. in length was permitted to remain *in situ*. Practically all the rest was removed and the wound was closed primarily, over an intercostal drainage tube, after subperiosteal resection of all but the first and second ribs, at which time her condition began to change for the worse and the operation was terminated.

The drainage tube was removed two days later and dihydrostreptomycin was injected into the chest on several occasions. Despite the fact that tuberculous granulations appeared in the wound, the pleural fluid remained clear and only small superficial areas of the wound broke down. The patient became afebrile and appeared generally improved.

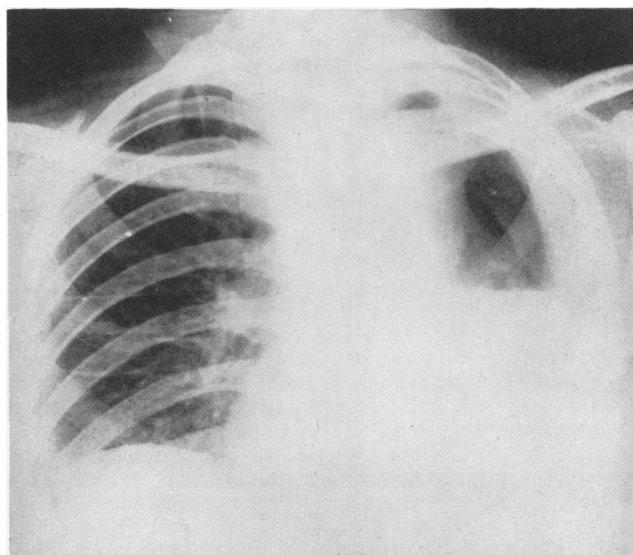


FIG. 25a (Case 21).—Tuberculous empyema after pneumonectomy.

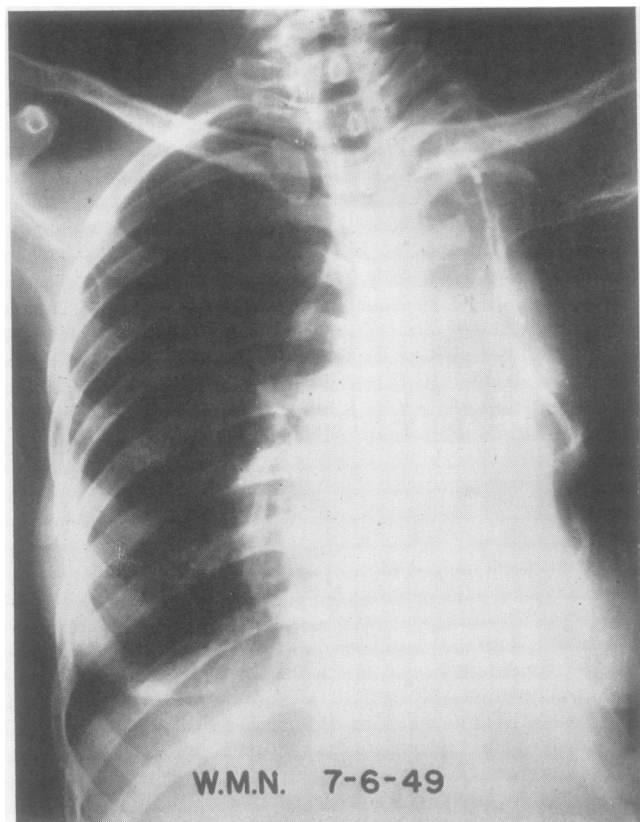


FIG. 25b (Case 21).—Five months after pleurectomy and thoracoplasty. Chest wall has healed completely and rib regeneration is evident.

Three weeks later, on March 1, 1949, the wound was excised again and the first and second ribs were removed subperiosteally. The lower portion of the chest had become practically obliterated and the small space under the upper two ribs contained some clear fluid only. The extrapleural tissues were greyish and smooth, but somewhat thickened.

The wound healed well and there was no fluid accumulation. Her sputum has remained negative (Fig. 25b). Although the case is just recent, the immediate result is good.

*Case 22 (Bronchopleural Fistula and Empyema).—*J.B., a man aged 34, was subjected to a right pneumonectomy for tuberculosis on December 28, 1948. Except for a mild thrombophlebitis of both legs, he did well until February 7, 1949, at which time he began to expectorate much bloody sputum and his temperature rose to 103° F. He became progressively worse with dyspnoea and higher fever, and on February 9 an intercostal tube was inserted for drainage (Fig. 26a). Culture of the purulent pleural fluid yielded streptococci, but no tubercle bacilli were found in the fluid or sputum. The patient was then transferred to my care, and on February 22, 1949, I performed

a bronchoplasty and pleurectomy under general anaesthesia administered through an endotracheal tube which had been placed under topical anaesthesia. The scar of the previous operation was excised and the fifth and seventh ribs were resected subperiosteally, the sixth having been resected at the pneumonectomy. An extrapleural cleavage plane was entered beneath each rib bed and mediastinally. The sac was stripped from the mediastinum and chest wall completely, but was entered in two places, somewhat soiling the extrapleural space. At the diaphragm it was impossible to find a cleavage plane so that the sac was entered and its wall cut at the diaphragmatic attachment. This remaining sheet of tissue (about 4 mm. in thickness and of about the area of one-half the palm of a hand) was incised and a cleavage plane was found beneath it, and then it was stripped from the diaphragm in two portions.

As the thickened pleural wall was cut from the region of the fistulous right main bronchus, the bronchus stump at once retracted into the mediastinum. A bronchus clamp was applied and the bronchus was drawn out of the mediastinum. A fistula opening, of pencil width, was seen in its inferior angle. The carina area was freed easily and the surrounding tissues were found to be as soft and healthy as normally, despite the intense inflammatory reaction in the nearby pleura. The bronchus was freed within its adventitial sheath and amputated at the carina; the proximal end was closed in the usual manner by one row of interrupted fine silk end-sutures. The

bronchus which was amputated measured 1.5 cm. in length, and huge conglomerate tubercles could be seen grossly in the resected pleura (Fig. 26b). The pleural cavity was thoroughly washed out and all small remnants of the pleura were removed. Several pericostal subperiosteal silk sutures were placed to stabilize the fourth and eighth ribs, and then the chest wall was closed in layers over an intercostal stab drainage tube placed through a new opening. The tract of the old drainage tube was excised and the skin wound was closed by several interrupted silk sutures.

The post-operative condition of the patient was remarkably different from that which had existed previously. He became ambulatory the following day, was afebrile within three days with practically no cough or sputum. The wound healed *per primam* and the pleural fluid remained sterile after several weeks (Fig. 26c). Thoracoplasty is contemplated in the near future.*

*Since this paper was presented, I have been informed that on March 29, 1949, a thoracoplasty was performed in which the entire first to fourth ribs, inclusive, and the eighth rib were resected, but afterwards the patient developed cardiac failure and died in pulmonary oedema on the fourth post-operative day.

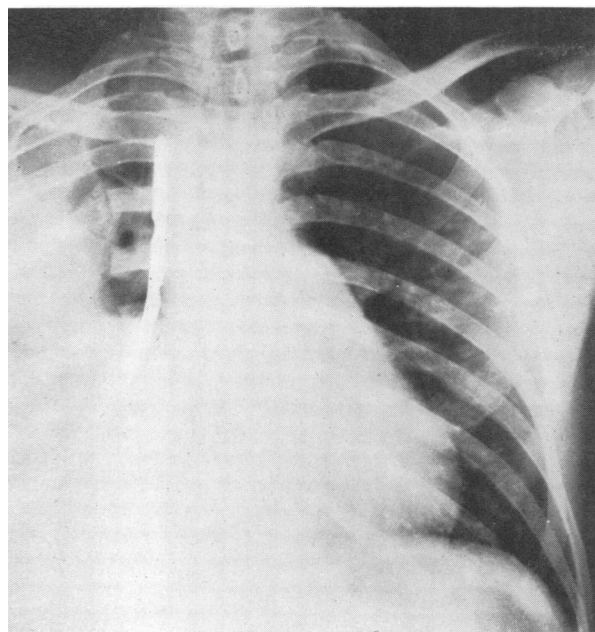


FIG. 26a.

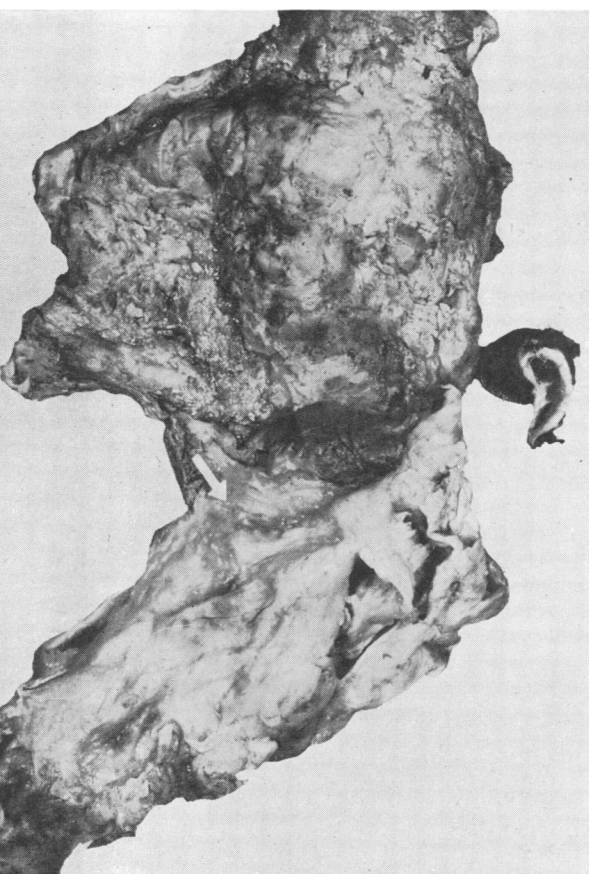


FIG. 26b.

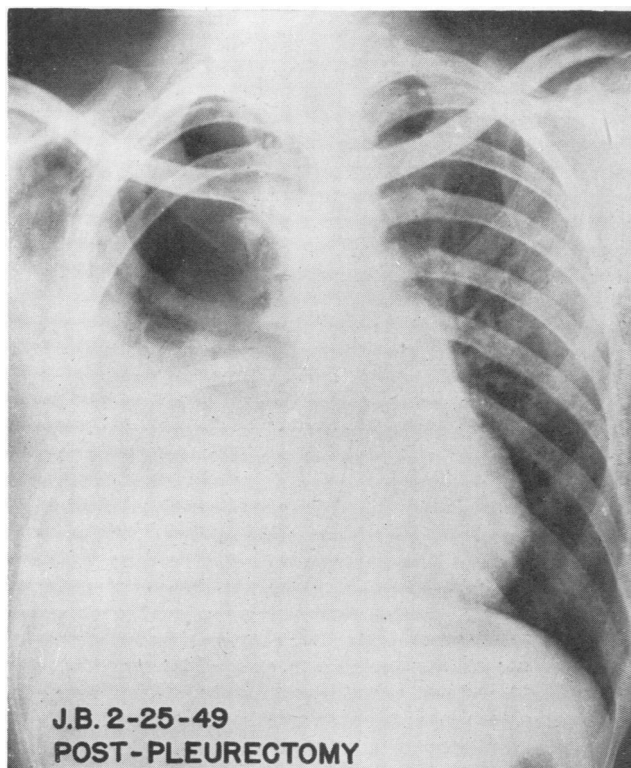


FIG. 26c.

FIG. 26a (Case 22).—Empyema subsequent to broncho-pleural fistula, after pneumonectomy, has been drained by an intercostal catheter.

FIG. 26b (Case 22).—The thickened parietal pleura contains grossly visible conglomerate tubercles (arrow). To the right may be seen that portion of the bronchus which was resected at the time of broncho-plasty.

FIG. 26c (Case 22).—After pleurectomy and broncho-plasty.

In these two cases the essential feature of the treatment was the excision of the caseous pleura as completely as possible and the addition of a thoracoplasty to obliterate the space. The bronchopleural fistula was treated by resection at the carina of the long bronchus stump and careful suture of the proximal end in a clean field. If the patient is very ill, the thoracoplasty should be done at a later date. This is now to be the manner of treatment of all such cases which are transferred to my care. The procedure seems logical, but further experience is required for its evaluation.

In lobectomy one should avoid cutting through grossly tuberculous tissue, the transection of which is frequently followed by persistent, troublesome, small bronchial fistulae and failure of the lung to re-expand despite adequate drainage because of the resultant positive pleural pressures. Even if the chest is opened secondarily, the openings on the cut surface sutured, and the lung re-expanded, empyema and wound infection usually follow.

Because in lobectomy a more peripheral bronchus is resected, gross tuberculous bronchial disease seems to be found more frequently at the site of resection. Consequently, even if the lung re-expands promptly and completely the bronchus stump may caseate and a small localized empyema may result which produces a persistent positive sputum without demonstrable lung disease. In one case of secondary lower lobectomy for cavitary disease several months after a previous upper lobectomy, the upper lobe bronchus was found to be held closed only by the silk sutures; when these were removed the bronchus opened completely, it had not healed at all.

A small localized empyema, occurring late, may perhaps be treated successfully by drainage, localized thoracoplasty, and the insertion of a muscle-flap into the bronchial fistula. Overholt (1945) has reported such a case.

However, the early opening of a lobar bronchus after lobectomy and before expansion and adherence of the lung is a severe complication which results in a generalized empyema. Poor results have been obtained from secondary closure of the bronchus and from thoracoplasty. It seems likely that better results will be obtained by removing the remainder of the lung and performing a pleurectomy as soon as possible, followed in a few weeks by a thoracoplasty. Delay, with or without thoracostomy, is likely to prove fatal since bronchogenic spreads occur

rapidly. In addition, pleurectomy becomes progressively more difficult.

Some time ago I did a secondary pneumonectomy without pleurectomy, following an upper lobectomy, and the young woman later developed a tuberculous empyema. In a more recent similar case which was transferred to my care after the development of a bronchopleural fistula following a left upper lobectomy, I added pleurectomy to the secondary pneumonectomy, and the patient is well with a healed chest wall and sterile pleural fluid a short time after operation. When he first developed the bronchopleural fistula, an upper thoracoplasty was performed which did nothing in this case but add the burden of paradoxical movement of the chest wall to the already struggling patient. After the thoracoplasty he developed auricular fibrillation, but this was controlled, and the patient underwent the secondary excisional procedure without too much difficulty, while fibrillating. A further thoracoplasty is to be performed in the near future.

Case 23 (Early Bronchopleural Fistula and Generalized Empyema).—A.H., a man aged 50, underwent a left upper lobectomy on February 4, 1949. Within the following weeks he began to cough up large amounts of bloody sputum and his temperature became elevated. The lung was not completely re-expanded (Fig. 27a) and methylene blue injected into the left pleural space was not expectorated. On February 18, 1949, the upper four ribs were removed, and during the operation he expectorated blue-stained secretions. After this operation he developed auricular fibrillation which was controlled by quinidine. Although the chest fluid and sputum were negative for tubercle bacilli and the chest fluid was sterile on culture, the patient was exceedingly ill, dyspnoeic, and febrile (Fig. 27b). He was transferred to my care, and on February 22, 1949, under general anaesthesia administered through an endotracheal tube, a secondary left pneumonectomy and a pleurectomy were performed (Fig. 27c). The patient was ambulant the following day, and within four days his temperature was normal and it has so remained. Cough and sputum have disappeared, the wound has healed, and the pleural fluid is sterile and clear (Fig. 27d). A further thoracoplasty will be performed later to obliterate the space.

The three cases reported above indicate the value of prompt treatment while the patient can still tolerate surgery and while pleurectomy can be performed easily. The importance of pleurectomy in the eradication of the empyema which complicates excisional procedures in tuberculosis has become more apparent to me with each case in which I have performed it.

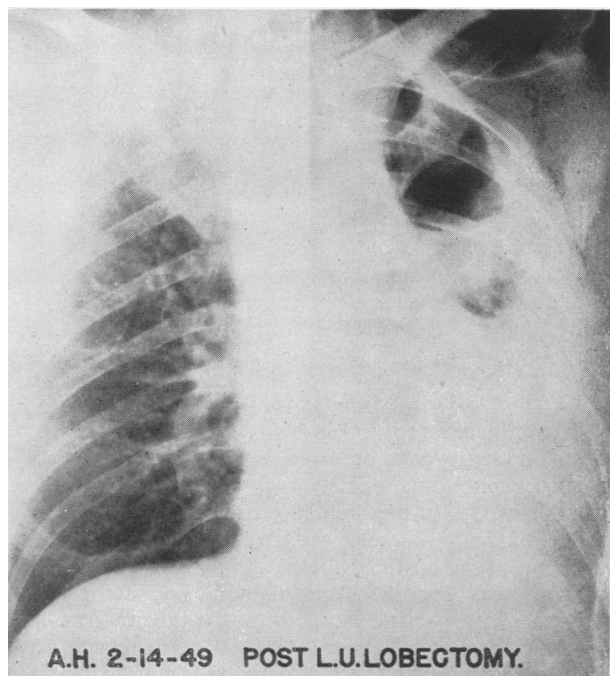


FIG. 27a.

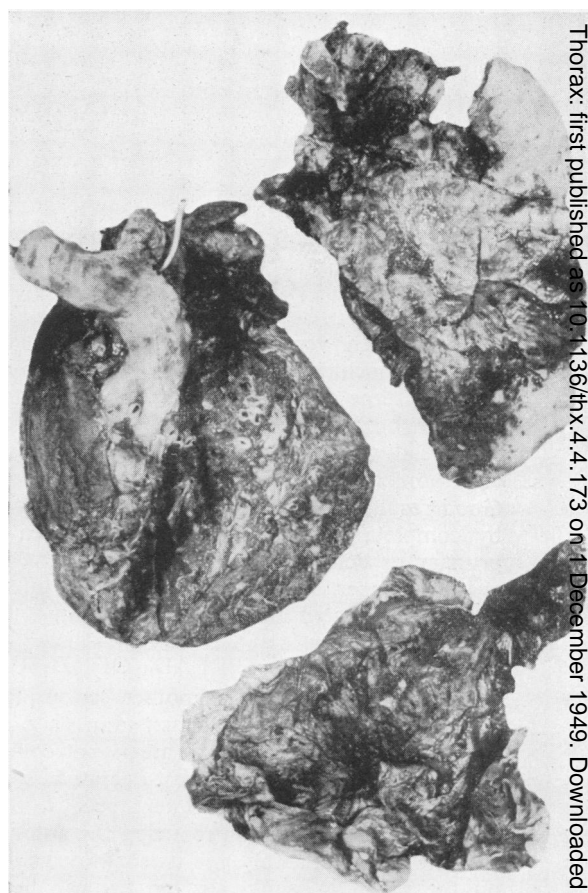


FIG. 27c.

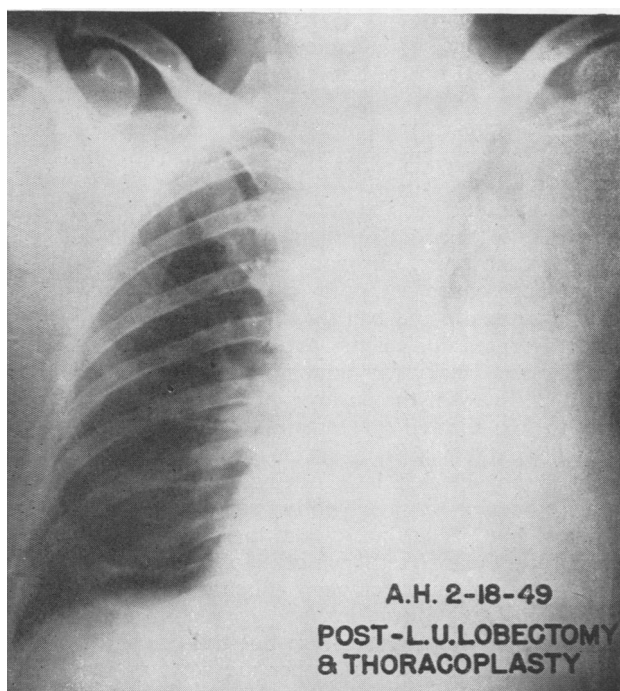


FIG. 27b.

FIG. 27a (Case 23).—Following left upper lobectomy. The lobar bronchial stump has opened and the lower lobe has failed to expand sufficiently to cover it.

FIG. 27b (Case 23).—Thoracoplasty has failed to control the bronchopleural fistula.

FIG. 27c (Case 23).—Remainder of the left lung has been resected secondarily, and a probe inserted into the main bronchus is seen to emerge through the patent upper lobe bronchus stump. Two large sheets of resected parietal pleura are shown.

FIG. 27d (Case 23).—Shortly following secondary lobectomy and pleurectomy.

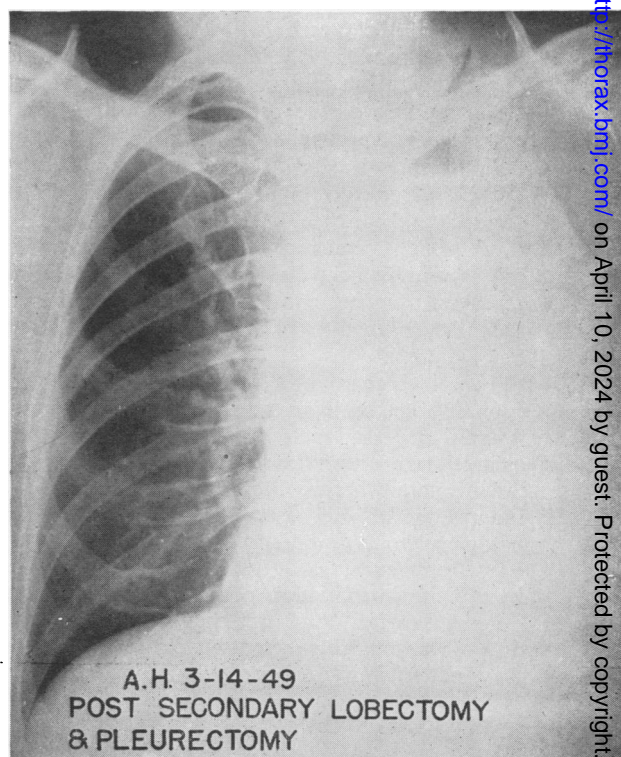


FIG. 27d.

WOUND INFECTION UNRELATED TO EMPYEMA

Wound infection unrelated to empyema occurred five times in the series of 125 cases. Undoubtedly this complication can be avoided by more scrupulous technique, although it is fair to say that even very minor wound involvements have been included, as well as small infected areas which became evident near the wound as long as one year after operation. Forcible probing of superficial wounds should be avoided since the endothoracic cavity can be contaminated easily. Good results have been obtained in several cases by complete excision of the infected area with primary or delayed closure. In every case, however, a deeper source for the wound infection must be suspected and carefully sought.

BRONCHOGENIC SPREAD OF DISEASE

Bronchogenic spread is another serious immediate complication. In contrast, immediate flare-up of previously existing disease is not common. Fortunately bronchogenic post-operative spreads have become much less frequent because of the action of streptomycin in reducing the amount of sputum post-operatively and its suppressive action on the tubercle bacillus in the tissues; because of the greater attention being paid to frequent clearance of infected secretions from the tracheo-bronchial tree during and after operations; and because of the Overholt position, which tends to prevent bronchial dissemination of secretions during operation and facilitates a rapid exposure and clamping of the bronchus, especially by the extrapleural approach.

Fatal spread of disease occurred in three of the 125 operations and progressive uncontrolled contralateral disease in one. Transient infiltrations which occurred after operation (in three cases) and which cleared completely within a few days were not considered tuberculous spreads. Spreads following bronchopleural fistulae are not included.

This incidence of spreads of only 3.2% can probably be diminished further if more attention is paid to the factors of proper anaesthesia, aspiration of secretions, and early clamping of the bronchus before too much palpation of the lung. Careful analysis of the charts of the four patients who suffered spreads of the disease after operation reveals that two were operated upon before the introduction of streptomycin, and the other two after long treatment by streptomycin and were probably streptomycin-resistant. Also two patients were operated upon before the

adoption of the Overholt position. In one of these, a very early case, the lung was palpated extensively before the bronchus was clamped. In the second, a case of bronchostenosis and bronchiectasis also treated before streptomycin was available, the profuse sputum caused great difficulty under anaesthesia and the operation was very long.

THORACOPLASTY COMPLICATIONS

The difficulties of haemorrhage, wound infection, and empyema occasionally attendant upon a subsequent thoracoplasty may result in failure of the primary excisional procedure. Further reduction in ventilatory capacity may disable or even cause the death of the patient. Also, I know of two cases in which unexplainable, apparently bronchogenic, persistent spreads of the tuberculosis to the contralateral lung followed thoracoplasty, in patients who had had negative sputa after excisions.

FAILURE OF SPUTUM CONVERSION

The persistence of tubercle bacilli in the sputum after excisional operations may be due to residual and undetected pre-existent disease with cavitation, operative spread, reactivation after operation of previously quiescent nodular foci, or the appearance of late new disease.

Reactivations and the appearance of apparently new disease remain significant causes of failure. Ornstein, however, questions reports of the frequent appearance of homo- or contralateral new cavitory disease, and has repeatedly demonstrated at conferences that unless routine complete tomographic and Bucky radiographic studies are made pre-operatively of the portions of the lungs which are to be allowed to remain, cavities already present in these areas may be easily overlooked only to be detected later during the search for the source of a persistently positive sputum. Selikoff and Tchertkoff (data to be published) have recently analysed such cases of reactivations and apparent new cavitory disease appearing after excisional operations, and have shown that an appreciable percentage are not truly new disease or reactivations but rather are cavitory foci which were present but unrecognized before operation.

Table V is an analysis of 13 cases in which the sputum was not converted to negative. No conclusions can be drawn from so small a series, but the general indication seems to be that still greater care must be exercised in the selection of cases, especially for lobectomy and segmental resection. The paravertebral segments must be

TABLE V

CAUSES OF FAILURE OF SPUTUM CONVERSION AFTER PULMONARY RESECTION FOR TUBERCULOSIS IN 125 CONSECUTIVE CASES, 1946-8* (SELIKOFF AND TCHERTKOFF†)

	Pneumonectomy	Lobectomy	Segmental Resection	Total
Residual cavitory disease	1	1	1	3
Operative spread	1	—	—	1
Reactivation:				
Homolateral	—	—	—	—
Contralateral	3	1	—	4
Late new disease:				
Homolateral	—	2	—	2
Contralateral	1	1	—	2
Residual empyema and bronchopleural fistula ..	1	—	—	1
				13

* Three died (2 following re-operation); 1 converted by contralateral segmental excision; 9 persistent failures of sputum conversion.

studied with particular care, tomographically, before a partial resection is undertaken. Too much dependence upon the decisions of the surgeon as a result of his palpatory findings is very apt to lead to trouble. If a large conglomerate focus is palpated one should not leave it behind and depend upon streptomycin to take care of it later.

We must expect some reactivations if we accept cases with contralateral disease for pneumonectomy or cases of healed or quiescent homolateral disease for lobectomy. But most of these cases, which would otherwise be lost, will remain well, and this is pure gain.

Of the 13 cases with persistent positive sputum, three have died, one of progressive disease and two following secondary excisional procedures to remove the active foci. One patient has successfully undergone contralateral segmental resection

and her sputum is now negative. There are nine cases whose sputum remains positive. Of these, five are suitable for secondary excisional operations. Such operations are contemplated in three, but the other two patients have refused further surgery.

CONTRALATERAL PLEURAL EFFUSION

Contralateral pleural effusion has occurred in three cases at varying times after pneumonectomy for tuberculosis. Tubercle bacilli were present in one of the fluids. However, there was spontaneous healing in each case and the cause is not known.

CAUSES OF DEATH

Twenty patients have died of the series of 125 cases studied by Robitzek and Selikoff (Table VI). It is of particular interest that of 33 extrapleural

TABLE VI

CAUSES OF DEATH AFTER PULMONARY RESECTION FOR TUBERCULOSIS IN 125 CONSECUTIVE CASES, 1946-8 (ROBITZEK AND SELIKOFF†)

	Intrapleural Pneumonectomy	Extrapleural Pneumonectomy	Lobectomy	Segmental Resection	Total
	(65)	(33)	(21)	(6)	(125)
Operative "shock"	1	1	1	—	3
Post-operative spread	2	—	1	—	3
Post-excisional thoracoplasty	—	—	—	1	1
Subsequent excisional procedure	—	—	1	1	2
Bronchopleural fistula and empyema ..	7	—	—	—	7
Respiratory insufficiency	1	—	—	—	1
Uncontrolled reactivation	1	—	—	—	1
Non-tuberculous pulmonary infections ..	2	—	—	—	2
Total	14	1	3	2	20

†Data to be published

TABLE VII

THREE-YEAR ANALYSIS OF RESULTS OF PULMONARY RESECTION FOR TUBERCULOSIS IN 125 CONSECUTIVE CASES, 1946-8 (ROBITZEK AND SELIKOFF*)

	Pneumonectomy	Lobectomy	Segmental Resection	Total
<i>Alive and well (negative sputum):</i>				
2-3 years	7	1	—	8
1-2 years	37	8	2	47
1 year	35	5	1	41
Total	79	14	3	96 (or 77%)
<i>Alive (sputum still positive)</i>	4	4	1	9
<i>Dead</i>	15	3	2	20
Total	98	21	6	125

*Data to be published

pneumonectomies, only one has died and that of operative shock. It is possible that all the deaths but the one from uncontrolled reactivation and the two from non-tuberculous acute pulmonary infections unrelated to the operations might have been prevented, but these were the early cases and the future work will be based on this experience. It is of interest that these cases were operated upon by approximately a dozen surgeons of greatly varied experience, some of whom were residents doing their first work.

RESULTS

Robitzek and Selikoff (personal communication) have recently assembled the results of excisional surgery in 150 consecutive cases at Sea View Hospital from 1946 to 1948, inclusive. They have informed me of the results of the first 125 consecutive cases, this particular number being chosen so that at the time of this report each surviving patient would have been alive at least one year and some patients as long as three years after operation. Careful study, including complete tomography, was made of each patient at the time of discharge from the hospital, usually six months after operation. Periodic examinations were made in the follow-up clinic, and the social service department of the hospital co-operated by advice concerning the home conditions to which the patient had been or was to be discharged. The social service and the record departments kept contact through the various city welfare departments with those patients who refused to report to the follow-up clinic, and thus assured the accuracy of the study. The analysis of these cases is shown in Table VII.

Of 125 patients, 96, or 77%, are alive and well one to three years after operation. Nine are alive, but with persistently positive sputum, and 20 are dead. Inasmuch as all but perhaps 12 of the 125 cases were beyond treatment by thoracoplasty, a large group of patients has been salvaged by excisional surgery.

SUMMARY

The indications for and contraindications to resection of the lung for pulmonary tuberculosis are discussed.

The methods used in selecting cases for these procedures are described. Thorough radiographic study of both lungs and adequate studies of pulmonary function before operation are essential.

The indications for, the advantages of, and the technique of extrapleural pneumonectomy are described. In cases with chronic empyema the extrapleural approach is helpful in facilitating decortication, in determining the indications for resection, and in minimizing contamination of the operation field during operation. Pleurectomy is an important aid in the prevention and treatment of post-operative bronchopleural fistula and empyema.

It is concluded that excisional procedures offer a potent means of salvaging advanced cases of pulmonary tuberculosis not amenable to treatment by non-surgical collapse methods or by thoracoplasty; that in certain cases of localized disease lobectomy or segmental resection is preferable to thoracoplasty; and that extrapleural procedures extend the range of excisional surgery, making possible the safe performance of lung resection in the presence of empyema and pleural symphysis.

BIBLIOGRAPHY

- Bailey, C. P. (1947). *J. thorac. Surg.*, **16**, 328.
 — Personal communication.
- Berry, F. B. (1932). *J. thorac. Surg.*, **2**, 139.
- Birath, G., Crafoord, C., and Rudström, P. (1947). *Ibid.*, **16**, 492.
- Chamberlain, J. M. Personal communication.
- *Pulmonary Resection for Tuberculosis*. To be published.
- Churchill, E. D., and Klopstock, R. (1943). *Ann. Surg.*, **117**, 641.
- Cohen, W., and Taylor, H. K. (1939). *Quart. Bull. Sea View Hosp.*, **5**, 3.
- Cournand, A., Himmelstein, A., Riley, R. L., and Lester, C. W. (1947). *J. thorac. Surg.*, **16**, 30.
- Davidson, L. R. (1941). *Quart. Bull. Sea View Hosp.*, **6**, 382.
- Davis, E. W. (1947). *J. thorac. Surg.*, **16**, 48.
- Editorial (1947). *Post-Grad. med. J.*, **23**, 506.
- Ehrenreich, T., and Stern, S. *Quart. Bull. Sea View Hosp.* (to be published).
- Freedlander, S. O. (1935). *J. thorac. Surg.*, **5**, 132.
- Gilbert, J. G., Aronoff, J. S., and Rosen, D. M. (1948). *Quart. Bull. Sea View Hosp.*, **10**, 3.
- Herben, G. F. (1949). Personal communication to New York State Chapter of American College of Chest Physicians.
- Hochberg, L. A., Fink, I., and Denize, A. (1946). *Quart. Bull. Sea View Hosp.*, **8**, 205.
- Jones, John C., and Dolley, Frank S. (1939). *J. thorac. Surg.*, **8**, 351.
- Levine, N., and Stern, S. Personal communication.
- Maier, H. C. (1949). Personal communication to New York State Chapter of American College of Chest Physicians.
- and Klopstock, R. (1945). *J. thorac. Surg.*, **14**, 20.
- Millikan, G. A. (1942). *Rev. Scientific Instruments*, **13**, 434.
- Murphy, J. D., Elrod, P. D., Walkup, H. E., and Koontz, E. R. (1948). *Dis. Chest*, **14**, 694.
- Ornstein, George G. (1949). *J. Amer. med. Ass.*, **139**, 638.
- (1949). *Dis. Chest*, **15**, 280.
- Personal communication.
- and Ulmar, D. (1935). *Quart. Bull. Sea View Hosp.*, **1**, 3.
- Overholt, R. H. Personal communication.
- and Wilson, N. J. (1945). *Amer. Rev. Tuberc.*, **51**, Case W.K., Page 27.
- Langer, L., Szypulski, J. T., and Wilson, N. J. (1946). *J. thorac. Surg.*, **15**, 384.
- Rabin, C. B. Personal communication.
- (1947). *Radiology of the Chest in Diagnostic Roentgenology*, **1**, 196. Thos. Nelson and Sons, New York.
- Robitzek, E., and Selikoff, I. J. Personal communication.
- Sarot, Irving A. *Clinical Tuberculosis*. Sixth Revised Ed. F. A. Davis and Co. Philadelphia, Penn. (in press).
- (1948). *Quart. Bull. Sea View Hosp.*, **10**, 47.
- and Gilbert, Lawrence (1947a). *Ibid.*, **9**, 183.
- (1947b). *Ibid.*, **9**, 234.
- Selikoff, I. J. (1947). *Amer. J. med. Sci.*, **213**, 719.
- and Robitzek, E. H. (1947). *Amer. J. Path.*, **23**, 1099.
- and Tchertkoff, I. G. *Quart. Bull. Sea View Hosp.* (to be published).
- Sweet, R. H. (1946). *J. thorac. Surg.*, **15**, 373.
- Tchertkoff, I. G., and Selikoff, I. J. (1947). *Quart. Bull. Sea View Hosp.*, **9**, 277.
- Woodruff, W. (1938). *J. thorac. Surg.*, **7**, 420.