

PERFORATIONS FOLLOWING DILATATION OF OESOPHAGEAL STRICTURES

A REPORT OF THREE CASES WITH RECOVERY

BY

C. A. WELLS, J. HOWELL HUGHES, R. EDWARDS, AND R. MARCUS

From the University of Liverpool and the Liverpool Royal Infirmary

Perforation of the oesophagus is an occasional tragic complication of endoscopy. It is most liable to occur when a carcinoma is present in the oesophagus. The three cases of perforation following dilatation of oesophageal strictures which we are reporting are of interest as the mechanism of rupture and surgical pathology was different in each case. The result of surgical intervention was gratifying.

CASE REPORTS

CASE 1.—This is a case demonstrating the danger of possible rupture of the oesophagus by a mercury-weighted bougie in a patient suffering from cardiospasm.

History.—A married woman aged 60 complained of vomiting of solid food over a period of five years. During this time she had lost 1 stone 6 lb. The vomiting occurred about ten minutes after eating, was gradually getting worse, and she felt that her food was “sticking” in the upper part of the abdomen. At times she had the sensation of “something opening and then the food passed through.” For a few months before admission she could only swallow liquids, and the regurgitated food contained a large amount of mucus. There was no pain or acid eructation. She was admitted into the Liverpool Royal Infirmary on July 22, 1946, and a radiological examination revealed cardiospasm with considerable oesophageal dilatation (Plate 1*a*).

Nine days after admission a Hurst's mercury weighted bougie passed easily down, the patient guiding it herself, and there was no complaint of discomfort. After removal of the bougie, she vomited about half a cupful of fluid which did not contain any blood. Eight hours later it was noticed that she was looking ill, her temperature being 100.4° F. and the pulse 90 per minute. She complained of generalized abdominal discomfort, most marked in the epigastrium, but there was no further vomiting and no definite pain felt. She was then seen by us and it was noticed that there was diminished respiratory movement of the abdomen with some guarding of the muscles, maximum in the epigastrium. There was no real rigidity, no tenderness in the lower abdomen, and nothing abnormal on rectal examination. A diag-

nosis of rupture of the oesophagus was made, and operation was undertaken nine hours after the passage of the bougie.

Operation.—Under gas, oxygen, and ether anaesthesia the abdomen was opened through a left supra-umbilical paramedian incision. There was a fair amount of blood-stained free fluid present between the stomach and liver. It was noticed that the tissues in the region of the cardia were extremely oedematous. The cardio-oesophageal junction was exposed by gentle dissection, and it was seen that the lower end of the oesophagus was oedematous, haemorrhagic, and extremely friable, its consistency being that of blotting paper. There were several bleeding points and one main longitudinal tear with two smaller tears on either side. Interrupted sutures with 0-0 thirty-day chromicized catgut on a small, fully curved needle were inserted through the oesophageal wall, penetration of the lumen being avoided, the suture emerging through the wall just beyond the tear. This was difficult, owing to the deep position of the oesophagus and the friability of the wall. The tears stopped just short of the cardio-oesophageal junction. Complete haemostasis was obtained after closure of the oesophagus. A Kader-Senn's gastrostomy was performed and a split rubber drain was inserted down to the cardio-oesophageal junction.

Intravenous glucose saline was given, followed by blood, and at the end of the operation the condition was satisfactory. Transfusion was continued until two pints of blood had been given. Intramuscular penicillin, three hundred thousand units over a period of twenty-four hours in divided doses at three-hourly intervals, was continued for ten days. The day after operation the general condition was satisfactory and fluids were administered through the gastrostomy tube.

The drainage tube was gradually shortened and was completely removed on the fourth day. The gastrostomy feeds of glucose and citrated milk were supplemented by casydol. On the tenth day after operation she was allowed fluids by mouth and it was found that she could swallow semi-solids two days later. The diet was gradually supplemented, and three weeks after the operation the gastrostomy was allowed to close.

A barium swallow (Plate 1*b*) taken a few days later still showed cardiospasm. The dilated oesophagus

narrowed smoothly to a point at the cardia, at the same level as before. Barium trickled into the stomach in a thin stream. The oesophagus emptied slowly, and still contained about a third of the barium fifteen minutes after it was given. There was no extravasation of barium.

On Jan. 21, 1947, the patient wrote, "I am feeling stronger and I am eating solid foods. I got myself weighed yesterday and my weight was 7 stone 7 lb., so that I have gained 7 lb. since discharge."

When examined by us on Feb. 6, 1948, she was able to swallow solids and her nutrition had improved. She had no dysphagia. Radiographs (Plate 1c) showed further improvement. She had had no further treatment for the cardiospasm.

CASE 2.—This is a case demonstrating the danger of Mikulicz's operation.

History.—A man aged 45 complained of vomiting of solids and liquids for eight months. He had epigastric pain three hours after food. The pain radiated to the back and was relieved by alkalis and food. Swallowing was difficult and was only possible after vomiting.

Two months before admission to our care a posterior gastro-enterostomy had been performed for a duodenal ulcer and the presence of cardiospasm confirmed and treated by Mikulicz's operation. After a stormy convalescence he was referred to one of us, as neither the operation nor repeated dilatation of the stricture had given relief.

When first seen he was emaciated, apyrexial, and in poor condition. Radiological examination confirmed the presence of cardiospasm.

Operation 1.—Under cyclopropane anaesthesia the abdomen was opened through the previous epigastric scar. The anterior wall of the stomach was incised and the cardiac orifice explored. Owing to dense stricture formation it was not possible to insert the tip of the little finger into the cardiac orifice. The abdominal oesophagus was then mobilized with difficulty. Because of insufficient ease of access Heller's operation was not considered practicable and a Kader-Senn's gastrostomy was performed.

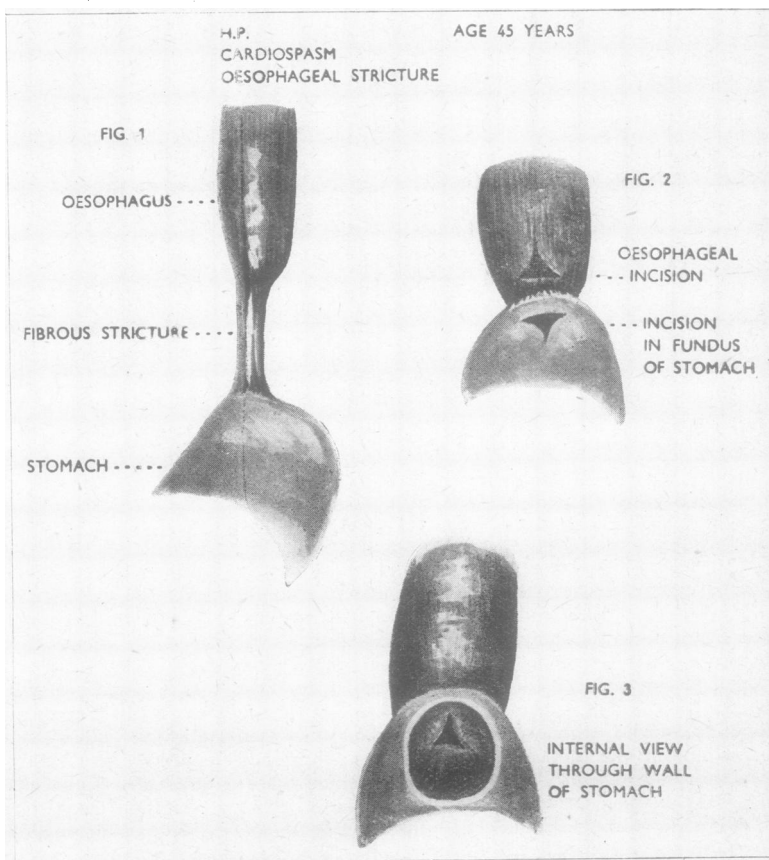
Operation 2.—Ten days later his condition had improved enough to justify exploration of the oesophagus through a large thoracotomy incision made with resection of the eighth left rib. Mobilization of the oesophagus

was difficult owing to old mediastinitis. The lower three inches of the oesophagus showed a fibrous stricture which did not allow the passage of a Ryle's tube. An oesophago-gastrostomy was performed (Figs. 1, 2, 3) and the chest closed. An intercostal drain was inserted through the ninth space.

Convalescence was uneventful and on discharge a month later he was able to swallow solids without difficulty. A radiograph taken then showed the stoma functioning well and no evidence of delay in the passage of the barium. Four months later he had gained 1 stone 7 lb. in weight. When reviewed on March 10, 1948, his weight had remained stationary and there was no recurrence of the vomiting or dysphagia. Radiographs showed no evidence of cardiospasm, and there was no delay in the passage of the barium through the stoma (Plate 1d).

CASE 3.—This is a case demonstrating the danger of possible rupture of an intra-thoracic stomach after dilatation of a stricture at the cardio-oesophageal junction.

History.—A man aged 53 had a transthoracic gastro-oesophagectomy performed in February, 1948, for



carcinoma of the lower end of the oesophagus which had invaded the cardiac end of the stomach. He was readmitted in May, 1948, with recurrence of the dysphagia and a left-sided empyema. An oesophagoscope passed easily down the oesophagus into the stomach. There was no sign of stricture, and the anastomosis appeared good. When the position was reviewed on July 21 he complained of progressive difficulty on swallowing. The passage of a mercury-weighted bougie was attempted. On July 27 an oesophagoscope passed freely to 37 cm. There was a dense stricture at the oesophago-gastric anastomosis. It was not possible to say whether this was simple or malignant. A biopsy was taken and was later found to consist of smooth muscle and fibrous tissue. The stricture was dilated up to a No. 21 bougie, but further on, in the stomach, there still appeared to be some constriction.

The next day the patient complained of severe abdominal pain which had begun during the night. Generalized abdominal rigidity was present and liver dullness absent. A direct radiograph of the upper abdomen and chest revealed the presence of free air below the diaphragm. An immediate laparotomy was performed. There was gross generalized peritonitis, and turbid fluid appeared to be entering the peritoneal cavity behind the hiatus in the diaphragm through which the stump of the stomach was passing. No perforation could be found in the subdiaphragmatic portion of the stomach even after reflecting the left lobe of the liver. A drainage tube was inserted alongside the stomach into the mediastinum, and a jejunostomy was performed. No evidence of recurrence of the growth was found. The patient recovered from the operation and the jejunostomy was allowed to close.

DISCUSSION

Treatment of cardiospasm by the use of mercury-weighted bougies is stated by some to be a safe procedure, and because of this, together with hydrostatic dilators, it is probably the method in most common use. After initiation into the method of passing the bougies, patients usually use them themselves, passing one before meals with amelioration of their symptoms.

We have not been able to find a reference in the literature to rupture of the oesophagus by a mercury-weighted bougie. In Case 1 the symptoms did not present any dramatic picture, and they were so few that but for the fact that the patient was in hospital the serious catastrophe might have been overlooked. Rupture of the oesophagus is a recognized and usually fatal complication of Mikulicz's operation, which is therefore rarely practised now.

The mechanism of the rupture in each case is shown in Figs. 4, 5, and 6. Case 1 was ruptured by a stretching force through the constricting oesophagus below the diaphragm, producing small longitudinal tears. Case 2 resulted from a stretching

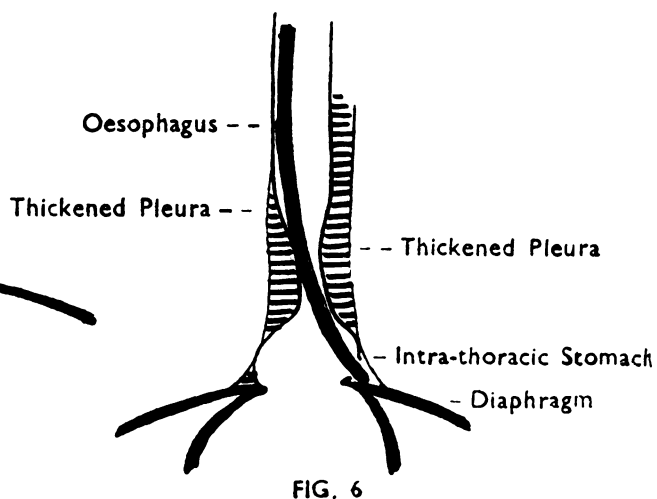
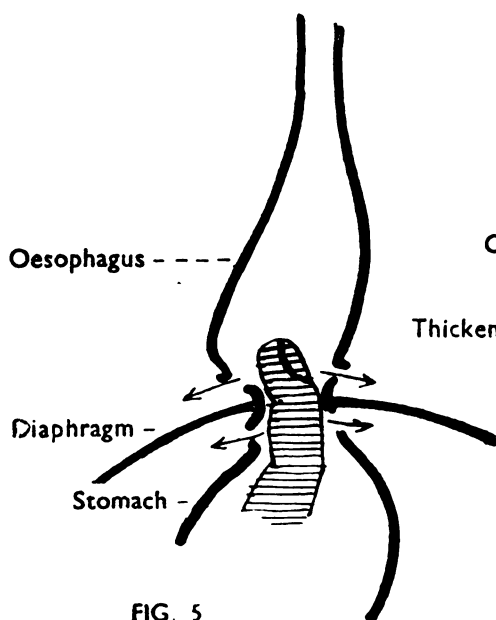
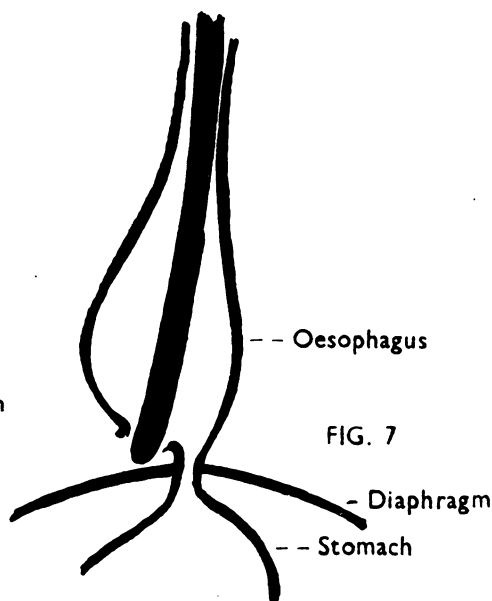
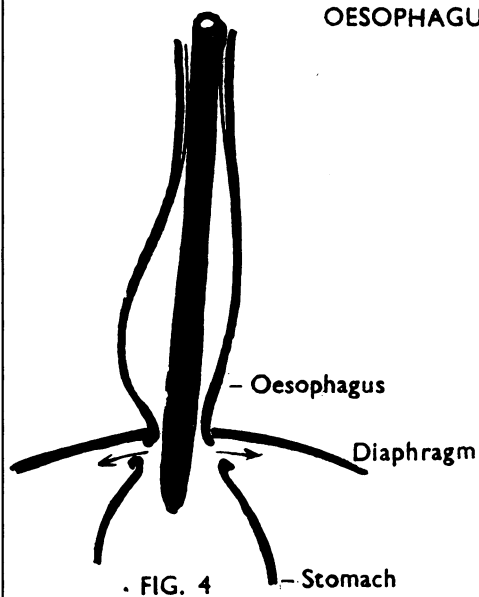
force directed from the stomach through the cardio-oesophageal junction, tearing the infra- and supra-diaphragmatic portion of the oesophagus. In Case 3 the oesophagoscope was manipulated successfully through the cardio-oesophageal anastomosis. The pulsion force during bouginage passed beyond the anastomosis through the wall of the supra-diaphragmatic wall of the stomach. The adhesions of the previous operation had sealed off this region from the pleural cavity, producing a gutter in the posterior mediastinum along which the gastric contents escaped from the perforation in the supra-diaphragmatic portion of the stomach into the peritoneal cavity.

The usual method of perforating the oesophagus in a case of cardiospasm (Fig. 7) is by pulsion. The instrument perforates the pouch of dilated oesophagus, on one side or the other of the narrowed cardio-oesophageal opening.

It is probable that slight injuries of the oesophagus, occurring after instrumentation, can recover spontaneously and in some of these cases peri-oesophagitis is a possible complication. This was seen recently by one of us in a case not reported here in which there had been treatment by dilatation. Peri-oesophagitis was a striking feature in Case 2 of this note and caused some embarrassment in the operation for oesophago-gastrostomy. This case is also of interest in that the peri-oesophagitis which resulted from the rupture had been localized by chemotherapy.

The mortality from oesophageal perforation despite the advances made in recent years is still very high. Wagner (1939) states: "The tragic fate (oesophageal perforation) can almost never be averted by surgical intervention even if surgery is carried out by the most skilful surgeon." Barrett (1946) reviewed fifty undoubted cases of spontaneous perforation of the oesophagus recorded in the literature, and amongst these no patient survived the catastrophe. Culver and Clark (1947) reported four cases, two of which were traumatic perforations of the oesophagus, recovery occurring in one. In the latter case, subcutaneous emphysema involved the neck following oesophagoscopy; radiographs of the chest showed diffuse widening of the mediastinum apparently resulting from a diffuse mediastinitis; the patient recovered after symptomatic treatment. Barrett (1947) reported the first case we have traced of spontaneous perforation of the oesophagus successfully treated by operation. Allison (1948) favours early suture of the perforated oesophagus following instrumentation. The cases he has treated in this way have survived. They have not been published.

DIAGRAMS ILLUSTRATING VARIOUS METHODS OF RUPTURING
DURING TREATMENT OF STRICTURES OF LOWER END OF
OESOPHAGUS



BARBARA
DUCKWORTH.
1948 —

The prognosis of perforation of the oesophagus is dependent on its site. Perforations high in the oesophagus have a better prognosis than those in the lower oesophagus. Mörl (1933) gave several reasons for this. In perforations of the cervical portion of the oesophagus, the tendency is for the resultant inflammatory process in the mediastinum to spread upwards, where it is more accessible to surgical intervention. The inflammatory process in the superior mediastinum is localized by the intact pleura. Perforations of the lower oesophagus commonly rupture into the pleural cavity because of the close apposition of the oesophagus and the mediastinal pleura immediately above the diaphragm. Weiss and Mallory (quoted by Eliason and Welty, 1946) have shown, experimentally, that this portion of the oesophagus is the weakest, and it is here that, under increased pressure from vomiting or coughing, spontaneous perforation occurs and the pleura is most often torn. Either pleural sac may be involved. In Culver and Clark's three cases the left pleural cavity was involved. Radiography is of value in the presence of mediastinitis or hydropneumothorax in

confirming the diagnosis and giving an indication for surgical approach.

SUMMARY

Three cases of rupture of the oesophagus with recovery, the first following the passage of a Hurst's mercury-weighted bougie, the second after Mikulicz's operation, and the third after oesophagoscopy, are reported.

The mechanism of the rupture in each case is illustrated.

We wish to thank Miss B. Duckworth, artist to the Department of Surgery, University of Liverpool, for the illustrations, and Mr. Lee for the prints.

REFERENCES

- Allison, P. R. (1948). Personal communication.
- Barrett, N. R. (1946). *Thorax*, **1**, 48.
- Barrett, N. R. (1947). *Brit. J. Surg.*, **35**, 216.
- Culver, G. J., and Clark, S. B. (1947). *Surgery*, **22**, 458.
- Eliason, E. L., and Welty, R. F. (1946). *Surg. Gynec. Obstet.*, **83**, 234.
- Mörl, F. (1933). *Beitr. Klin. Chir.*, **158**, 487.
- Wagner, W. (1939). *Arch. Klin. Chir.*, **195**, 161.

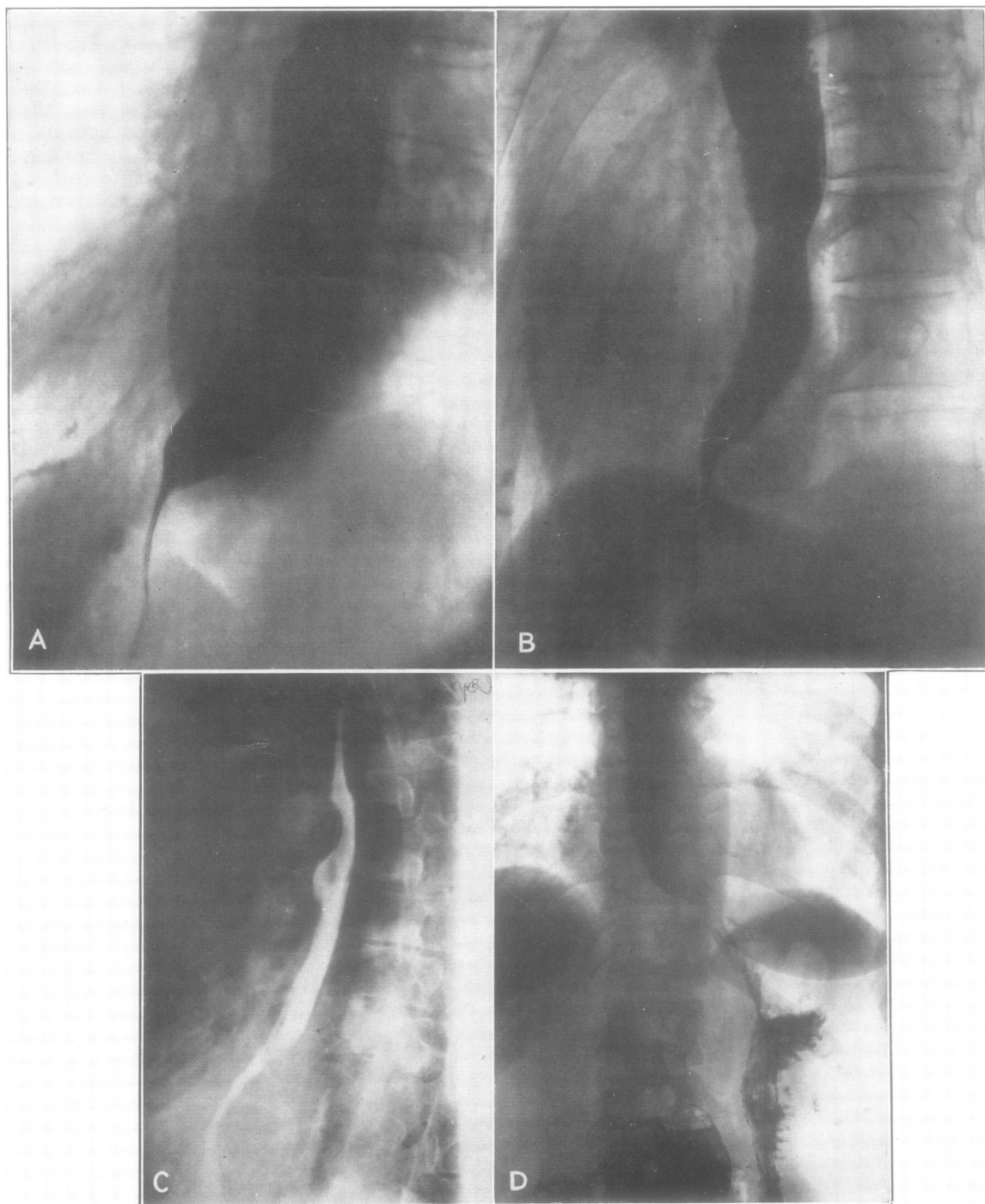


PLATE I