

¹ Williams AJ, Cayton RM, Harding LK, Mostafa AB, Matthews HR. Quantitative lung scintigrams and lung function in the selection of patients for pneumonectomy. *Br J Dis Chest* 1984;78:105-12.

**This letter was sent to the authors, who reply below.

Details of seven patients with technically resectable bronchial carcinomas

Patient No	% perfusion	Tumour size (cm)	Surgical outcome	Reason for inoperability
1	14	3	Resected	
2	26	9	Resected	
3	14	4.5	Resected	
4	4	5	Resected	
5	6	8	Not resected	Pulmonary artery and pericardial disease
6	24	Not assessed	Not resected	Invasion of aorta; subaortic lymph node disease
7	8	7	Not resected	Cardiac invasion and pleural effusion

SIR,—We are grateful for the opportunity of replying to the points made by Dr Williams and his colleagues. As we pointed out in our paper, the interpretation of any data used to predict resectability of bronchial carcinoma depends critically on the criteria used by individual surgeons to decide whether or not potentially curative surgery is technically possible. For this reason it is difficult to compare our results with theirs. The best index of successful resection would be information on survival, which they do not give. We pointed out that in our series only one of 10 patients in whom the preoperative perfusion of the affected lung was less than 25% of the total survived two years and we suggest that this supports the use of scanning in the assessment of operability. As with most investigations, the additional information given by scanning has to be interpreted in the light of other clinical, radiological, pathological, and functional data and whether or not a thoracotomy is performed will not be determined by the scan in isolation from other information. Our suggestions on the quantitative use of scanning in assessment of operability were in fact more conservative than the recommendations in some earlier studies.¹

We would agree entirely with Dr Williams and his colleagues on the value of scans in prediction of postoperative lung function² and exercise performance.³

DA ELLIS
T HAWKINS
GJ GIBSON
S NARIMAN

Freeman Hospital
Newcastle upon Tyne NE7 7DN

¹ Secker Walker RH, Alderson PO, Wilhelm J, *et al.* Ventilation-perfusion scanning in carcinoma of the bronchus. *Chest* 1974;65:660-3.

² Ellis DA, Hawkins T, Gibson GJ, Nariman S. Prediction of lung function after pneumonectomy for bronchial carcinoma. *Thorax* 1982;37:786-7.

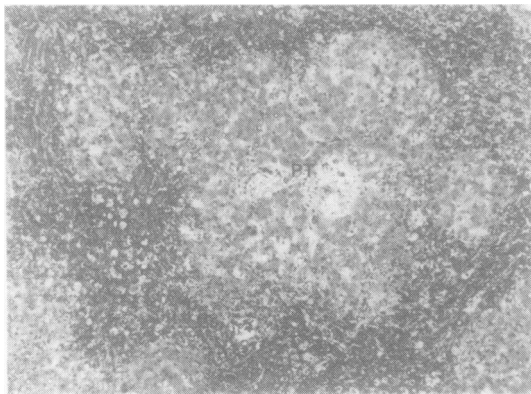
³ Corris PA, Ellis DA, Nariman S, Gibson GJ. Use of preoperative perfusion scanning to predict exercise performance after pneumonectomy for carcinoma of the bronchus. *Clin Sci* 1983;65:39P (abstract).

Jaundice after open heart surgery: a prospective study

SIR—The article by Dr C-M Chu and others (January 1984;39:52-6) has prompted us to draw attention to the histological changes in the liver, and the medical counterpart, of the condition they describe following cardiac surgery. Undoubtedly their patients had "ischaemic hepatitis," a recognised cause of jaundice,¹ but one which we feel is underdiagnosed in the United Kingdom. We have seen four medical patients who have developed this entity. Three were associated with cardiogenic shock due to myocardial infarction and one with shock lung due to renal failure following repair of a ruptured abdominal aortic aneurysm. Invasive manometry in these cases revealed the following pathophysiological mechanisms to be involved: (1) a high right atrial pressure, which causes hepatic congestion due to impaired venous drainage; (2) prolonged hypotension leading to underperfusion of the liver; and (3) hypoxaemia despite supplementary oxygen. These findings are similar to those of Dr Chu and his colleagues.

Our patients survived from three to nine days after hospital admission and developed premortem bilirubin levels ranging from 135 to 475 $\mu\text{mol/l}$ (7.9 to 27.8 mg/100 ml) and AST levels ranging from 350 to 2360 IU/l. All the patients succumbed to their myocardial or pulmonary disease. At necropsy the livers showed marked venous congestion. The capsules were smooth and stretched. Microscopically the specimens revealed changes caused by ischaemia (fig). Owing to their location hepatocytes at the periphery of the liver acinus receive blood at a lower oxygen tension than those cells close to the hepatic artery. They are thus more susceptible to damage when hypoxia and hypotension are present, and when in addition there is failure of venous drainage extensive cell necrosis at the periphery of the acinus may occur. As bile flow is dependent on arterial oxygen tension hypoxia may lead to slowing of bile secretion and even cholestasis.² All of these changes were seen in our patients.

The elevated serum bilirubin and AST levels may lead the clinician to consider a diagnosis of viral hepatitis. Awareness of the possibility of ischaemic hepatitis should,



Severe congestion at the periphery of a hepatic acinus in case 1. The portal tract (PT) is intact. (Haematoxylin and eosin, $\times 33$.)

however, lead to intensive efforts to reduce right atrial pressure, improve oxygenation, and maintain an adequate blood pressure. Reversal of these factors may protect the liver from further injury.³

If the diagnosis is still in doubt a liver biopsy should, if possible, be performed as the histological features of ischaemic hepatitis are characteristic and quite dissimilar to those of viral hepatitis.

NY HABOUBI
JD EDWARDS
HH ALI
MS HENDY

*Departments of Pathology and Medicine
University Hospital of South Manchester
Manchester M20 8LR*

¹ Bynum TE, Boitnott JK, Maddrey WC. Ischaemic hepatitis. *Dig Dis Sci* 1979;24:129-35.

² Sherlock S. *Disease of the liver and biliary system*. Oxford: Blackwell Scientific Publications, 1982.

³ Kisloff B, Schaffer G. Fulminant hepatic failure secondary to congestive heart failure. *Dig Dis Sci* 1976;21:895-900.

* * This letter was sent to the authors, and Dr Liaw replies below.

SIR,—Thank you for allowing us to see the comments of Dr Haboubi and others on our paper. We agree that hypoxaemia and hypotension may cause ischaemic hepatitis, and our patients with late peaked jaundice after open heart surgery did have higher frequencies of postoperative

hypoxaemia and hypotension and higher alanine aminotransferase levels. These patients may have had ischaemic hepatitis as suggested by Dr Haboubi and his colleagues, but previous work by us suggests that ischaemic hepatitis usually develops in acute heart failure with low cardiac output and has a grave prognosis.¹ If ischaemic hepatitis was the cause of the jaundice in our patients after open heart surgery, then we feel that it must be of a relatively mild form.

YUN-FAN LIAW

Liver Unit

Chang Gung Memorial Hospital

199 Tung Hwa North Road

Taipei, Taiwan 105

Republic of China

¹ Sheen IS, Liaw YF, Chiang CW, Chen TJ. Ischaemic hepatitis. *J Formosan Med Assoc* 1982;81:712-6.

Notices

Can we have safer cigarettes?

A one day conference entitled "Can We Have Safer Cigarettes?" will be held under the auspices of the Chest, Heart and Stroke Association at the Bloomsbury Crest Hotel, London WC1, on Thursday 8 November 1984. The conference will be chaired by Professor Geoffrey Rose and should be of interest to those concerned with the formation of policy on the health effects of smoking, clinicians, community physicians, epidemiologists, health educators, and concerned lay groups. Subjects include: the market—its patterns and changes (Mr PN Lee); smoke constitution and respiratory disease (Dr TW Higgenbottom); smoke constitution and coronary heart disease (Professor NJ Wald); nicotine and smoking behaviour (Dr MAH Russell); advice to patients (Dr SG Spiro); national policy—a personal view (Mr R Peto). There will be periods for panel discussion and general discussion. Full details are available from the Chest, Heart and Stroke Association, Tavistock House North, Tavistock Square, London WC1H 9HE.

British Thoracic Society: future meetings

6-7 December 1984	Kensington Town Hall, London (NB Abstracts required by mid September)
3-5 July 1985	University of York
5-6 December 1985	Metropole Hotel, Birmingham
18-20 June 1986	Cheltenham