

Chylothorax and tuberculosis

MARIA C VENNERRA, RAFAEL MORENO, JAVIER COT, ALBERT MARIN, JUAN SANCHEZ-LLORET, CESAR PICADO, ALBERT AGUSTI-VIDAL

From the Respiratory Department, University of Barcelona, and Hospital Clinic i Provincial de Barcelona, Spain

Chylothorax occurs when chyle, characterised by high triglyceride and low cholesterol concentrations, is found in the pleural space. It is an uncommon clinical entity, first recognised about 70 years ago and caused most frequently by chest trauma. We describe a case of chylothorax caused by pulmonary, pleural, and glandular tuberculosis—a very rare cause indeed.

Case report

A 49 year old woman was referred to hospital complaining of right sided chest pain, fever, non-productive cough, listlessness, and weight loss of 5 kg over the preceding three weeks. She had had pulmonary tuberculosis 35 years ago, which had been treated by pneumothorax, and during the previous year had complained of recurrent urinary tract infections.

On admission she was pale and obviously severely ill. A right sided pleural effusion was present and there were bilateral small nodes palpable in the axillas. The erythrocyte sedimentation rate was 80 mm in the first hour. There was no other significant haematological abnormality. Urine culture was negative for mycobacteria and other organisms, but on microscopy showed no more than 500 white cells per field. The chest radiograph showed multiple calcified lesions in both lung fields, a non-homogeneous opacity in the right upper lobe, and a right sided pleural effusion. The pleural aspirate was milky in appearance, and contained glucose 130 mg/100 ml (7.2 mmol/l), protein 52 g/l, cholesterol 37 mg/l, triglycerides 598 mg/l, and lipids 787 mg/l. White cells (98% lymphocytes) were present in the fluid, but culture was negative for mycobacteria and other organisms. Pleural biopsy showed chronic non-specific inflammation. Intravenous urography showed irregularity of the left calyceal system and distal obstruction of the left ureter with megaureter, the changes being characteristic of tuberculosis. The right kidney and ureter were normal.

Lymphography showed in the injection phase a very large paravertebral glandular mass as well as a lymph node producing complete left ureteric obstruction at its distal

end. The cisterna chyli was not visualised. In the second phase communication in the lumbar and thoracic systems was observed principally through diaphragmatic, vertebral, and pleural anastomoses. The thoracic duct was obstructed at the level of T10. Eventually the thoracic duct became visible when pleural, vertebral, and internal mammary collaterals filled it at its proximal end (fig).

Thoracotomy was performed at the level of the sixth intercostal space without rib resection. The pleura showed micronodular foci on both visceral and pleural surfaces. Microscopically, granulomas were found in the pleura and lung, but no acid or alcohol fast organisms were seen. Cessation was seen in the pleural and lung biopsy specimens. Treatment with three antituberculosis drugs was given for 12 months and the clinical and radiographic progress was very satisfactory. There was no reaccumulation of pleural fluid. Reinvestigation by intravenous urography showed a destroyed left kidney and this was resected. At operation two large paravertebral gland masses were removed. The kidney and nodes showed granulomas.

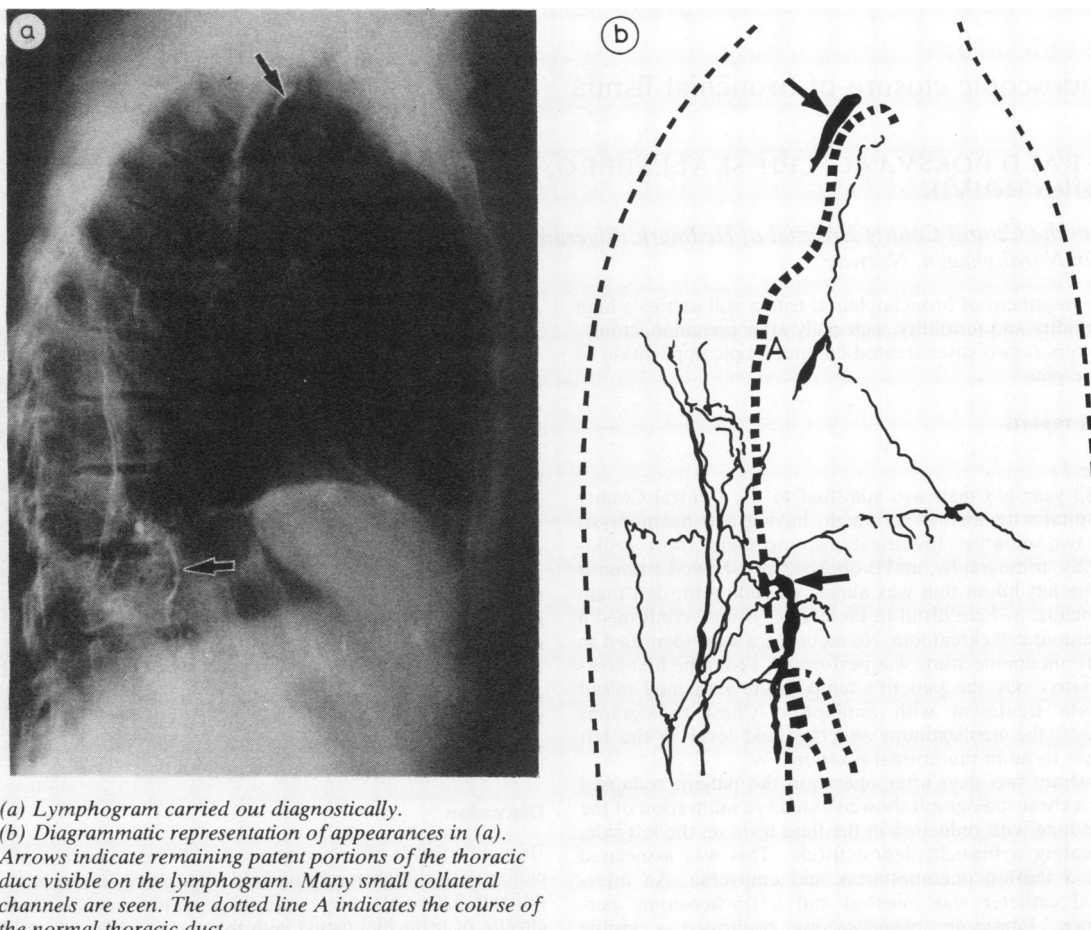
Discussion

Chylothorax may be caused by malignant neoplasms, infections,¹ aneurysms,² lymphangiomyomatosis,³ and cirrhosis of the liver⁴ but these are relatively uncommon, the most common cause being trauma such as penetrating wounds, crushing injuries, surgical procedures, and thoracic cage hyperextension.⁵ Chylothorax may also occur as a result of congenital thoracic duct system anomalies.⁶ Tuberculosis is described as a possible cause of chylous effusion,⁷ but only a single case, described by Brandt in 1917,⁸ appears to have been recorded.

The probable explanation of the chylothorax in this patient is as follows. The enlarged lumbar and iliac lymph nodes produced obstruction of the cisterna chyli and thoracic duct, as a result of which there was dilatation of the lumbar channels; this was followed by the opening up of collateral anastomoses, many lymphaticovenous anastomoses existing between the thoracic duct system and the azygos, intercostal, and lumbar veins. The increased pressure in the system resulted in transudation of chyle into the right pleural space. After removal of the obstructing lymph nodes the effusion did not recur. It would have been interesting to observe the state of the thoracic duct after treatment, but a second lymphogram was not performed. Lymphography is considered an important advance in the diagnosis and management of chylothorax^{1,4} and it was a valuable diagnostic method in this case.

Address for reprint requests: Dr María del Carmen Vennerra, Servei de Pneumologia, Hospital Clínic i Provincial de Barcelona, Casanovas, 143. Barcelona-36, Spain.

Accepted 19 January 1983



(a) Lymphogram carried out diagnostically.

(b) Diagrammatic representation of appearances in (a). Arrows indicate remaining patent portions of the thoracic duct visible on the lymphogram. Many small collateral channels are seen. The dotted line A indicates the course of the normal thoracic duct.

References

- ¹ Fraser RG, Paré JAP. Diseases of the pleura. In: Fraser RG, Paré JAP. *Diagnosis of diseases of the chest*. Philadelphia, WB. Saunders Co, 1979:1769-70.
- ² Williams KR, Burford TH. The management of chylothorax. *Ann Surg* 1964;**160**:131-40.
- ³ Corrin B, Liebow AA, Friedman PJ. Pulmonary lymphangiomyomatosis. *Ann J Pathol* 1975;**79**:348-51.
- ⁴ Yunis EJ, Moran TJ. Chylothorax and portal cirrhosis. *JAMA* 1965;**192**:250-51.
- ⁵ Herzog KA, Brauscom JJ. Spontaneous chylothorax. *Chest* 1974;**65**:346-47.
- ⁶ Roy PH, Carr DT, Payne WS. The problem of chylothorax. *Mayo Clin Proc* 1967;**42**:457-67.
- ⁷ Johnston RF, Dovnasky JH. Pleural diseases. In: Fishman AP. *Pulmonary diseases and disorders*. New York: McGraw-Hill Co, 1980: 1370.
- ⁸ Brandt M. *Ein Beitrag zur Kasuistik der Ductus thoracicus-Tuberkulose und des Chylothorax*. Inaug. Diss. Heidelberg. Universitäts-Buchdruckerei von J Hörning, 1917.