

Distribution of pulmonary cholinergic nerves in the rabbit

AL-WI EL-BERMANI, EI BLOOMQUIST, JA MONTVILO

From the Departments of Anatomy and Cellular Biology and Physiology, Tufts University School of Medicine, Boston, Massachusetts

ABSTRACT Investigations of the nerves of the rabbit lung, by light and electron microscopy, showed a dense acetylcholinesterase-positive innervation of the bronchi through the bronchiolar level. Large nerve bundles were found to decrease in size as they progressed from extrachondral to subchondral connective tissue, forming complex networks of mostly terminal fibres in the muscle layer. In several instances single fibres penetrated the submucosal layer and approached the mucosa. Gangliocytes, which also reacted positively for cholinesterase, were visible in the vicinity of the large peribronchial bundles. Gangliocytes rarely were seen in association with the vasculature. Blood vessels received a much less dense cholinesterase-positive nerve supply than the bronchi. Single, non-terminal fibres were noted at the adventitiomedial junction of the pulmonary artery and vein. In addition, segments of nerve fibres (networks) were observed in the arterial and venous smooth muscle layers. Cholinesterase-positive innervation was even less extensive in the veins than in the arteries.

The mammalian pulmonary innervation is derived from sympathetic fibres and vagal rami.¹ Various histochemical and histological techniques have been utilised to study the pattern and type of innervation of the lung in different species, such as the rat, dog, cat, and monkey.²⁻⁶ Pulmonary reactions in human lungs may be similar to those found in rabbits. For example, vagotomy has been found to decrease the ventilatory response to severe hypercapnia in both rabbits and man.^{7,8} By contrast, variable responses to hypercapnia occur in cats and dogs.⁹⁻¹²

A thorough understanding of pulmonary reactions requires a complete anatomical mapping of the innervation of the lung and its vessels. Only limited studies of this type have been carried out on the rabbit. These studies have concentrated on showing the presence of catecholamines in the lung, particularly in the vasculature,^{13,14} with less emphasis on cholinergic innervation.^{14,15}

The purpose of this study was to delineate the distribution of acetylcholinesterase-positive nerves as an indication of cholinergic innervation throughout the rabbit lung.

Methods

LIGHT MICROSCOPY

Albino rabbits, weighing an average of 3 kg, were injected intraperitoneally with sodium pentobarbital. The lungs, judged to be free of disease on macroscopic examination, were placed on aluminium foil and frozen on dry ice (-70°C).

Serial frozen sections of 20–30 μm were collected on coverslips, air-dried for a few minutes, and fixed in 4% neutral formal-saline solution for 15 minutes. The sections were incubated at 37°C for 90 minutes, according to the procedure of Karnovsky and Roots¹⁶ as modified by El-Badawi and Schenk.¹⁷ The substrate for the specific cholinesterase reaction was acetylthiocholine iodide; tetraisopropylpyrophosphoramidate (iso-OMPA) at a concentration of 80 mmol/l was used to inhibit non-specific cholinesterase.

ELECTRON MICROSCOPY

A modification of the procedure described by Kokko *et al*¹⁸ was used to demonstrate acetylcholinesterase for electron microscopy. After a saline washout of the pulmonary circulation the left lung was perfused with a solution of 3% formaldehyde and 1% glutaraldehyde in Sorensen's phosphate buffer (pH 7.0) through the pulmonary artery

Address for reprint requests: Dr Al-Walid I El-Bermani, Department of Anatomy and Cellular Biology, Tufts University School of Medicine, 136 Harrison Avenue, Boston, Massachusetts 02111, USA.

and trachea. The excised lung was cut into 2-mm³ pieces and placed in the same fixative for four hours. After an overnight rinse in 0.1 mol/l phosphate buffer (pH 7.0) the tissue pieces were preincubated for 30 minutes at room temperature in a solution of 4 mmol/l iso-OMPA in maleate buffer (pH 6.8). They were then incubated in a medium containing 50 mmol/l maleate buffer, 2 mmol/l acetyl- β methylthiocholine bromide, 3 mmol/l cupric sulphate, 0.5 mmol/l potassium ferricyanide, and 60 mmol/l sodium tartrate for two hours at 4°C. The tissue was rinsed in maleate buffer for two hours, rinsed in phosphate buffer, then post-fixed in 1% osmium tetroxide in phosphate buffer for one hour. The lung pieces were dehydrated in a graded series of ethanol solutions and embedded in Epon.

Thin sections were placed on formvar-coated copper slot grids (1 × 2 mm), stained with uranyl acetate and lead citrate, and observed on a Philips 200 electron microscope.

Results

Bundles of nerves, forming the pulmonary plexus, can be found at the hilum both anteriorly and posteriorly to the entering bronchi and pulmonary blood vessels. The plexus is organised into small bundles that diverge in many directions, coursing through hilar connective tissue towards the bronchi, pulmonary blood vessels, and bronchial blood vessels. Large, heavily stained, acetylcholinesterase-positive nerve bundles are mainly associated with the bronchial tree. They are located in the extrachondral connective tissue of the bronchial wall, and are of mixed fibre types. Thick (myelinated) fibres are more prevalent in hilar bundles; thin (non-myelinated) fibres are abundant deeper in the lung. Small bundles, stained positively for acetylcholinesterase, are found in the subchondral connective tissue of the bronchial wall (fig 1).

Round or ovoid gangliocytes, either single or accumulated in ganglia, are present in peribronchial connective tissue. In the hilar area these cells are located near the large peribronchial nerve bundles. Fibres appear to arise from the gangliocytes and to contribute to the bundles. Ganglia also are present deeper in the lung, again in association with bronchial fasciculi (fig 1). Very few gangliocytes were detected in relation to the pulmonary vessels.

Dense networks of randomly distributed fibres, which stained positively for acetylcholinesterase, were found in and around the bronchial muscle layer (fig 2). By light microscopy these fibres are characteristically delicate and thin, with a beaded appearance. Some of these varicose perimuscular nerves can be traced to subchondrial nerve bundles (figs 1

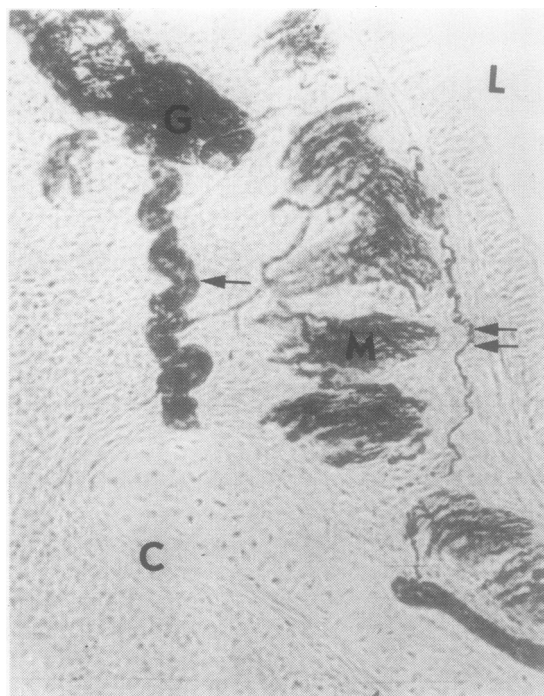


Fig 1 Cross-section of a small bronchiole with a subchondral nerve bundle (single arrow) and a single submucosal nerve fibre (double arrow) stained positively for acetylcholinesterase. C – chondral plate; G – acetylcholinesterase-positive ganglion cells; L – lumen; M – muscularis with acetylcholinesterase-positive nerve plexus. (Original magnification × 220.)

and 2). With the electron microscope most of these fibres are seen to be composed of about three to six neurones surrounded by a Schwann cell (fig 3). Where the neurone approaches the muscle cell, the Schwann cell no longer covers the neurone completely and there is usually an accumulation of clear vesicles (approximately 38 nm in diameter) at this site. Commonly a single terminal of one neurone may contact two or more muscle cells with synaptic specialisations occurring in both muscle and nerve at each site of contact (fig 4). The neuromuscular cleft averages about 40 nm wide. In most cases a very fine precipitate indicative of the presence of acetylcholinesterase can be seen within and around the neuromuscular cleft and at the perimuscular borders. No precipitate is seen intracellularly. It is also evident that more than one neurone in a bundle may have a synaptic connection with a single muscle cell (fig 3).

The submucosa shows two types of fibres. One type travels from the muscle plexus into the submucosal layer and appears to terminate at the base

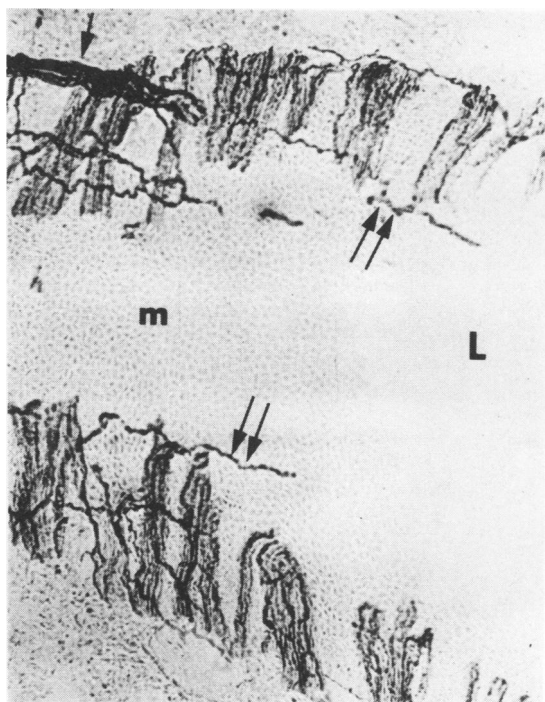


Fig 2 Oblique section of a bronchiole showing an acetylcholinesterase-positive network of fibres between muscular bundles. This network extends from the perimuscular bundle (single arrow) running parallel to the lumen in the submucosal area (double arrow). L – lumen; m – mucosa. (Original magnification $\times 220$.)

of the mucosa (figs 2 and 5). The other follows a partially circumferential path around the bronchial lumen before ending (fig 1). Both types appear beaded and react positively for acetylcholinesterase.

Isolated myelinated neurones are found in the submucosa (fig 6). These neurones contain many mitochondria, neurotubules, and neurofilaments. There is an absence of any type of vesicle. The myelin sheath, which is some 20–25 layers thick, ends abruptly at some distance from the mucosa, and the neurone presumably continues on, to end on or near the mucosa. A search of about 200 sections of this area produced no evidence of nearby ganglion cells. These neurones showed no reaction for acetylcholinesterase.

At the bronchiolar level, acetylcholinesterase-positive fibre bundles were present in the adventitial layer. Contributions to the perimuscular and submucosal fibres originate from these bundles (fig 2). Innervation of the bronchi continues uninterrupted to the terminal bronchiolar level, as well as extending throughout the layers of bronchial wall; bronchial innervation appears completely interwoven.

Acetylcholinesterase-positive nerves associated with blood vessels are less dense than the bronchial innervation. No fasciculi have been found in direct relation to the vasculature, but a few unbeaded, single, acetylcholinesterase-positive fibres can be found in the adventitiomedial junction of pulmonary arteries and veins.

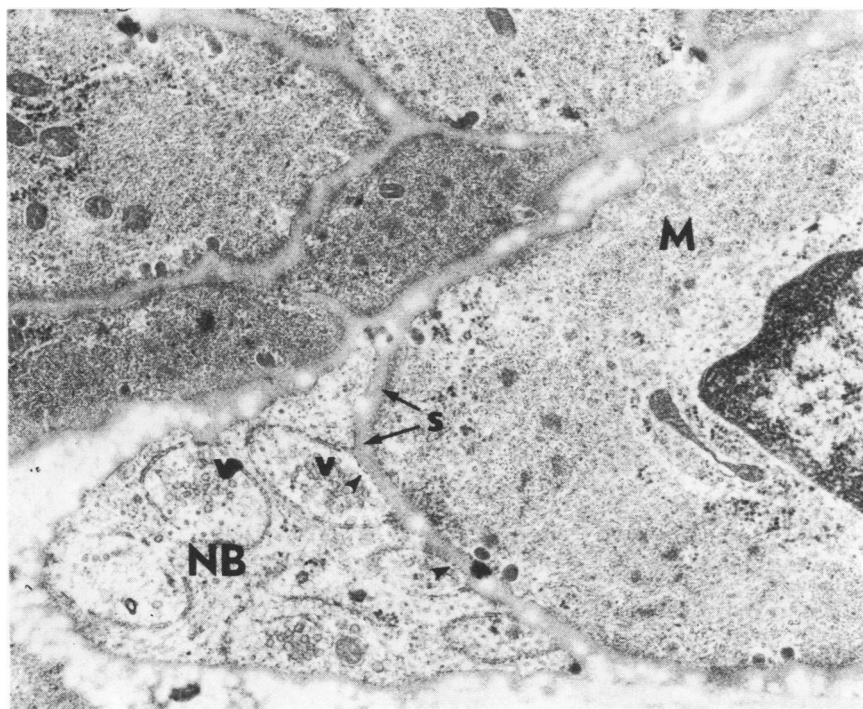


Fig 3 A single muscle cell showing neuromuscular contacts with two neurones from a varicose perimuscular nerve bundle. The fine precipitate indicates the presence of acetylcholinesterase (arrow head). V – clear vesicles; M – muscle cell; NB – nerve bundle; S – synaptic specialisations. (Original magnification $\times 19\,570$.)

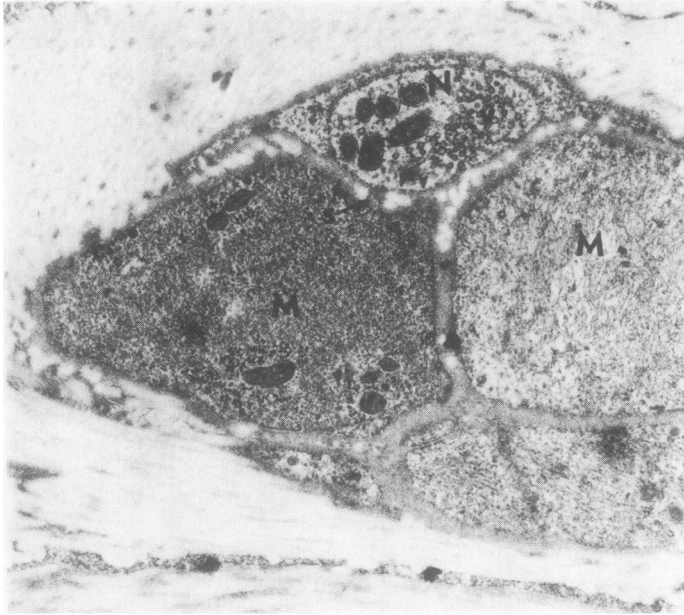

Fig 4 A terminal neurone contacting two muscle cells in the muscularis of a terminal bronchiole. The fine precipitate indicates the presence of acetylcholinesterase (arrow heads). M – muscle cell; N – nerve bundle; S – synaptic specialisations; V – clear vesicles. (Original magnification $\times 29\,500$.)

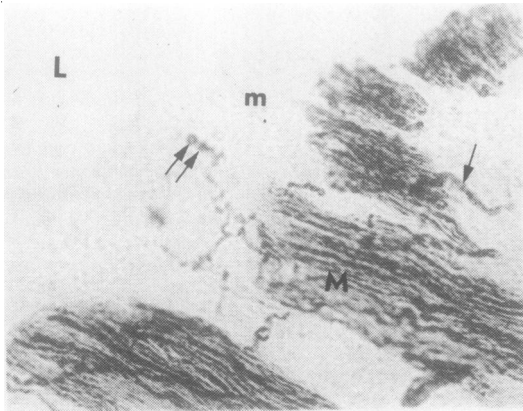


Fig 5 Cross-section of a bronchiole showing a submucosal nerve fibre terminating at the base of the mucosa (double arrow) and a perimuscular nerve (single arrow). L – lumen; M – muscularis with acetylcholinesterase-positive nerve plexus; m – mucosa. (Original magnification $\times 430$.)

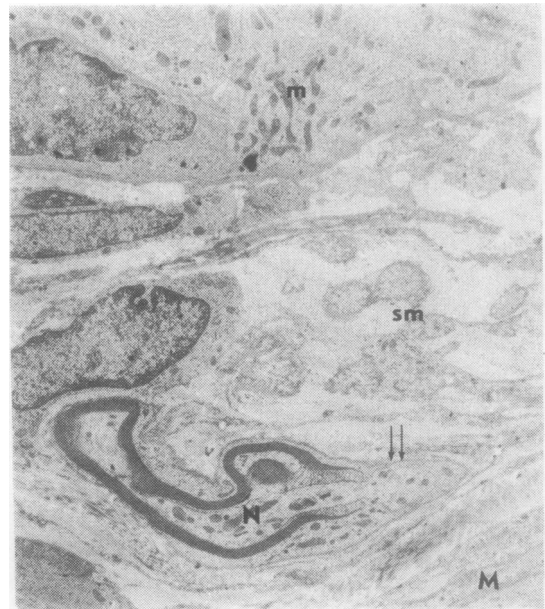


Fig 6 An isolated myelinated neurone in the submucosa. Note the absence of vesicles and the large number of mitochondria and microtubules, as well as the absence of Schwann cell and myelin at dendritic terminal (double arrow). N – myelinated neurone; sm – submucosa; M – muscularis; m – mucosa. (Original magnification $\times 10\,500$.)

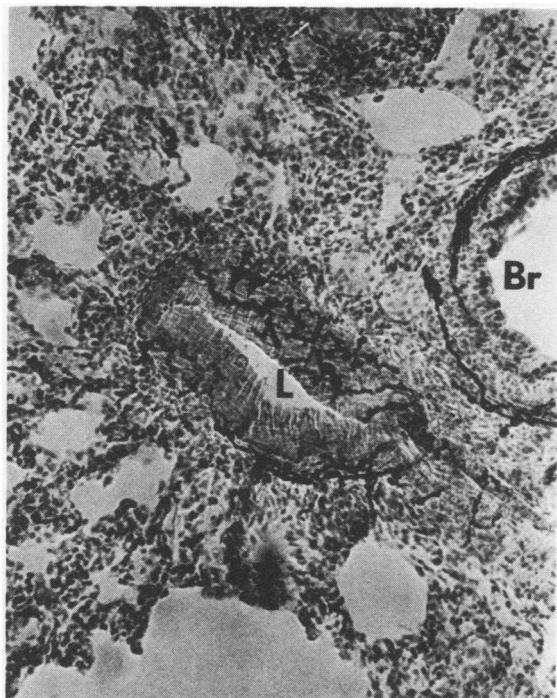


Fig 7 Tangential section of the medial layer of a medium-size pulmonary artery with networks of acetylcholinesterase-positive beaded nerve fibres (double arrow). L – lumen of pulmonary artery; Br – adjacent bronchiole. (Original magnification $\times 210$.)

A relatively dense acetylcholinesterase-containing nerve population is evident along the wall of the pulmonary artery. Intermeshed networks of beaded fibres are visible in tangential section in the periphery of the medial layer of the artery (fig 7). These networks are reminiscent of their counterparts in the bronchial muscle layer, but are less extensive and more loosely interconnected. Fibres in the media occasionally seem directed toward the tunica intima but none were observed in this layer.

Large pulmonary veins show less dense intermeshed networks of beaded fibres positive for acetylcholinesterase. The venous networks often appear segmented (fig 8). Innervation is concentrated in areas of venous bifurcation.

Discussion

Acetylcholinesterase-positive staining has often been taken as an indication of the presence of cholinergic neurones.^{19,20} Although problems of non-specificity have been noted,^{21,22} we consider the cholinesterase staining method to be the most prac-

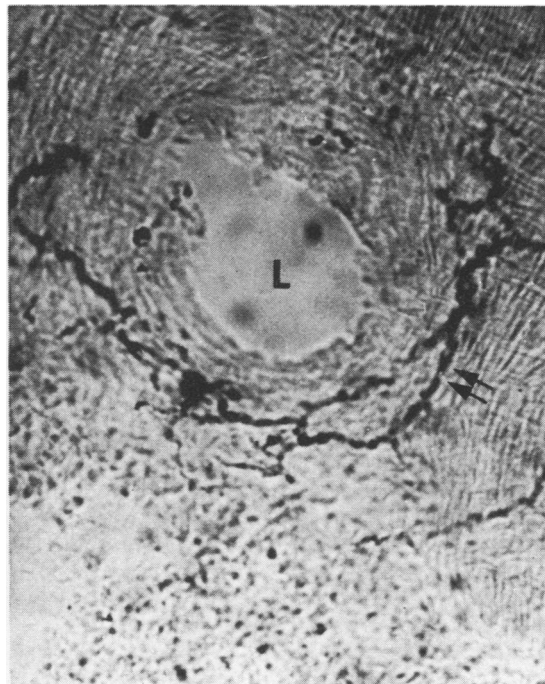


Fig 8 Cross-section of a large pulmonary vein showing varicose networks of acetylcholinesterase-positive nerve fibres (double arrow). L – lumen. (Original magnification $\times 430$.)

ticable and reliable means of identifying cholinergic nerves in the peripheral nervous system, particularly in the lungs. Catecholamine fluorescence was not demonstrable in alternate sections of the nerves that stained positively for acetylcholinesterase. We believe therefore that an acetylcholinesterase-positive reaction in neurones examined in these experiments indicates that these neurones are cholinergic. Since pulmonary nerves originate in either the sympathetic chain or the vagus,¹ the acetylcholinesterase-positive fibres are probably in vagal rami.

Cholinergic hilar bundles in the rabbit lung are concentrated in the connective tissue around the bronchi, and contain myelinated and unmyelinated nerves. Studies of the rat lung showed similar peribronchial as well as perivascular bundles,^{4,23} while investigation of the monkey lung showed nerve bundles that were not associated with any pulmonary structures until deep in the lung.⁶

The cholinergic nerve supply of the bronchi through the level of the bronchioles is dense; acetylcholinesterase-positive bundles appear in the adventitia and form an elaborate plexus in the tunica

muscularis. This finding is in agreement with results reported by Mann.¹⁵ The non-varicose fibres found in the bundles in the connective tissue and in the periphery of pulmonary structures are probably axons of a non-terminal type. The nerves forming the plexuses in the muscular coat are often characterised by varicosities. Varicose fibres described in the bronchial muscle and submucosal layers are most likely to represent nerve terminals. This concept of terminals has been well accepted, and was used in studies of the rabbit, rat, and cat by Honjin,^{24,25} Spencer and Leof,²⁶ and El-Bermani *et al.*⁴ Knight *et al.*²⁷ described nerve terminals of cholinergic nature in the bronchial smooth muscle of dogs, monkeys, and baboons.

It is clear from the present study that each muscle cell may be innervated by more than one cholinergic neurone; it is also clear that each neurone may innervate more than one muscle cell. This may have some physiological importance in view of the amount of control the nerves exert on the degree of muscular contraction, and may be an important factor determining whether smooth muscle cells in various locations have differential excitability.

The cholinergic perimuscular fibres are important in that they represent the efferent pathways for bronchoconstriction caused by the hypoxic reflex.^{28,29} In studies of circadian rhythms in asthmatic patients, these nerves have been shown to be responsible for the control of airway calibre.³⁰ They also appear to exert some control over the antigenic response in asthmatics.^{31,32} This innervation is also important in relation to the severe decrease in vital capacity, attributed to microatelectasis, of patients with neuromuscular diseases.³³

Some single varicose fibres are present in the submucosa of the bronchi. Some were observed approaching the epithelial layer. This conflicts with Mann's¹⁵ report that no acetylcholinesterase-positive fibres are present in rabbit mucosa. The perimuscular fibres of the rabbit are comparable to those found in association with the bronchial epithelium of the rat,⁴ cat,³⁴ and mouse.^{35,36} These fibres are less extensive than those seen in the submucosa of the monkey.

The perimuscular nerves of the rabbit may have either a sensory or a motor function. Since the paths of these fibres were not traced to their terminations, we cannot determine whether they possess endings characteristic of sensory fibres. In addition, we are dealing exclusively with cholinesterase-containing nerves; yet it has not been established that sensory fibres contain cholinesterase. Sensory receptors in the lungs have been characterised physiologically by many investigators,^{37,38} but few anatomical descriptions are available.

If the perimuscular nerves are efferent they could be either preganglionic or postganglionic vagal rami, since both preganglionic and postganglionic parasympathetic nerves show acetylcholinesterase. If they are preganglionic, they may be related in some way to the neuroepithelial bodies or amine precursor uptake and decarboxylation (APUD) cells of the mucosa.^{39,40} The neuroepithelial bodies show a decreased intensity of fluorescence and increased secretion and fragmentation of dense-core vesicles under the influence of hypercapnia,⁴¹ and vagotomy in rabbits depresses the ventilatory response to severe hypercapnia. Since acetylcholinesterase-positive fibres were noted in the mucosal area of the rabbit, the site of the neuroepithelial bodies and APUD cells, possibly these cells are innervated by the mucosal fibres. If the nerves are postganglionic parasympathetic, the fibres may innervate the mucosal glands, and have a secretomotor function.⁴⁰ Further investigation is needed for definitely establishing the contacts and function of these fibres.

The extrachondral gangliocytes noted in this study are definitely cholinergic. They are similar to the gangliocytes described in the peribronchial connective tissue of the rat and monkey.⁴⁶ Acetylcholinesterase-positive ganglia also may be present between the bronchi and arteries of cats and dogs.⁴² Scattered gangliocytes were seen in association with arteries in the rabbit in the present studies.

Cholinergic innervation of the pulmonary blood vessels in the rabbit is less dense than bronchial cholinergic innervation, although more extensive than the vascular innervation noted in the rat.²³ The pulmonary innervation of the dog⁴³ seems comparable to that of the rabbit. In both species nerves supplying the bronchial tissue show greater cholinesterase activity than those supplying the arteries. In the dog, however, no enzyme activity has been observed in the pulmonary vein, while in the rabbit a positive reaction was seen.

Varicose terminal fibres form a loosely interconnected plexus in the muscle layer of the pulmonary artery of the rabbit. This plexus is present in the peripheral half of the muscle, and may extend throughout the entire layer. Čech¹⁴ reported that it penetrates only the outer half. Venous innervation consists of beaded, discontinuous plexuses. These plexuses are most apparent on the surface of the tunica media, and penetrate the wall less than do arterial plexuses. This finding differs from the results obtained from the studies on the rat, which showed that cholinergic venous innervation is heavier than the arterial innervation.⁴ No nerves were observed in the intimal layer of the pulmonary vein of the rabbit. Such nerves have been found in the mouse, and are thought to have a motor function.^{44,45}

We wish to thank Ms EA Cohen and Mr TD Bonney for their technical assistance and Ms Patricia Itri for expert typing of the manuscript. This work was supported by grant number HL20548 from the National Heart, Lung and Blood Institute.

References

- ¹ Karsner H. Nerve fibrillae in the pulmonary artery of the dog. *J Exp Med* 1911;**14**:322–5.
- ² Altenahr E. Studies on the microstructure of the autonomic innervation of the rat lung. *Z Mikrosk Anat Forsch* 1965;**72**:439–518.
- ³ Fisher A. The intrinsic innervation of the pulmonary vessels. *Acta Anat (Basel)* 1965;**60**:481–96.
- ⁴ El-Bermani Al-W, McNary W, Bradley D. The distribution of acetylcholinesterase and catecholamine containing nerves in the rat lung. *Anat Rec* 1970;**167**:205–12.
- ⁵ Grande N, Cohen D. New aspects of cholinergic innervation of the canine lung. *Arch Anat Histol Embrol (Strasb)* 1972;**55**:399–401.
- ⁶ El-Bermani Al-W, Grant M. Acetylcholinesterase-positive nerves of the rhesus monkey bronchial tree. *Thorax* 1975;**30**:162–70.
- ⁷ Wiemer W, Kiwull P. Die Bedeutung der Nn. Vagi für die chemische Atmungssteuerung des Kaninchens. *Pflügers Arch ges Physiol* 1965;**283**:R46.
- ⁸ Guz A, Noble M, Widdicombe J. The role of vagal and glossopharyngeal afferent nerves in respiratory sensation, control of breathing and arterial pressure regulation in conscious man. *Clin Sci Mol Med* 1966;**30**:161–70.
- ⁹ Honda Y, Nomura H, Minoguchi M. Effects of vagotomy on the excitability of the respiration center to blood CO₂. *Jpn J Physiol* 1957;**7**:137–46.
- ¹⁰ Woldring S. Interrelation between lung volume, arterial CO₂ tension, and respiratory activity. *J Appl Physiol* 1965;**20**:647–52.
- ¹¹ Schoener E, Frankel H. Effect of hyperthermia and P_{aco}₂ on the slowly adapting pulmonary stretch receptor. *Am J Physiol* 1972;**222**:68–72.
- ¹² Sant'Ambrogio G, Miserocchi G, Mortola J. Transient responses of pulmonary stretch receptors in the dog to inhalation of carbon dioxide. *Respir Physiol* 1974;**22**:191–7.
- ¹³ Čech S, Doležel S. Monoaminergic innervation of the pulmonary vessels in various laboratory animals (rat, rabbit, cat). *Experientia* 1967;**23**:114–5.
- ¹⁴ Čech S. Cholinesterase-containing nerve fibers on blood vessels in lungs of some laboratory animals. *Z Zellforsch Mikrosk Anat* 1973;**140**:91–100.
- ¹⁵ Mann S. The innervation of mammalian bronchial smooth muscle localisation of catecholamines. *Histochem J* 1971;**3**:319–31.
- ¹⁶ Karnovsky M, Roots L. A “direct-coloring” thiocholine method for cholinesterases. *J Histochem Cytochem* 1964;**12**:219–21.
- ¹⁷ El-Badawi A, Schenk E. A histochemical study of the distribution of cholinergic and adrenergic nerves. *Am J Anat* 1966;**119**:405–28.
- ¹⁸ Kokko A, Mautner HG, Barnett RJ. Fine structural localisation of acetylcholinesterase using acetyl-β-methylthiocholine and acetylselenocholine as substrates. *J Histochem Cytochem* 1969;**7**:625–40.
- References**
- ¹⁹ Ehninger B, Falck B, Persson H, Sporrang B. Adrenergic and cholinergic-containing neurons of the heart. *Histochemie* 1968;**16**:197–205.
- ²⁰ Graham J, Lever J, Spriggs T. An examination of adrenergic axons around pancreatic arterioles of the cat for the presence of acetylcholinesterase by high resolution autoradiographic and histochemical methods. *Br J Pharmacol* 1968;**33**:15–20.
- ²¹ Eranko O, Rechardt V, Eranko L, Cunningham A. Light and electron microscopic histochemical observations on cholinesterase-containing sympathetic nerve fibers in the pineal body of the rat. *Histochem J* 1970;**2**:479–89.
- ²² Machado A, Lemos P. Histochemical evidence for a cholinergic sympathetic innervation of the rat pineal body. *J Neuro-Visceral Rel* 1971;**32**:104–11.
- ²³ El-Bermani Al-W. *Studies on the innervation of the rat lung*. Doctoral dissertation, Boston University, 1969.
- ²⁴ Honjin R. On the nerve supply of the lung of the mouse, with special reference to the structure of the peripheral vegetative nervous system. *J Comp Neurol* 1956;**105**:587–625.
- ²⁵ Honjin R. Experimental degeneration of the vagus and its relation to the nerve supply of the lung of the mouse, with special reference to the crossing innervation of the lung by the vagi. *J Comp Neurol* 1956;**106**:1–20.
- ²⁶ Spencer H, Leof D. The innervation of the human lung. *J Anat* 1964;**98**:599–609.
- ²⁷ Knight DS, Hyman AL, Ellison JP, Kadowitz PJ. Catecholamine mechanism in the canine and feline lung. *Chest* 1977;**71**:262–3.
- ²⁸ Nadel JA, Widdicombe JG. Effect of changes in blood gas tensions and carotid sinus pressure on tracheal volume and total lung resistance to airflow. *J Physiol (Lond)* 1962;**163**:13–33.
- ²⁹ Delpierre S, Fornaris E, Fornaris M, Grimaud C. Pulmonary mechanics during hypoxia in spontaneously breathing anaesthetised rabbits. *J Auton Nerv Syst* 1980;**2**:391–440.
- ³⁰ Hetzel MR, Clark TJH. Comparison of normal and asthmatic circadian rhythms in peak expiratory flow rate. *Thorax* 1980;**35**:732–8.
- ³¹ Yu DYC, Galant SP, Gold WM. Inhibition of oxygen induced bronchoconstriction by atropine in asthmatic patients. *J Appl Physiol* 1972;**32**:823–8.
- ³² Thomson NC, Kerr JW. Effect of inhaled H₁ and H₂ receptor antagonists in normal and asthmatic subjects. *Thorax* 1980;**35**:428–34.
- ³³ DeTroyer A, Borenstein S, Cordier R. Analysis of lung volume restriction in patients with respiratory muscle weakness. *Thorax* 1980;**35**:603–10.
- ³⁴ Hung K-S. Fine structure of tracheo-bronchial epithelial nerves of the cat. *Anat Rec* 1975;**185**:85–92.
- ³⁵ Hung K-S, Hertwick M, Hardy J, Loosli C. Electron microscopic observations of nerve endings in the alveolar walls of mouse lungs. *Am Rev Respir Dis*

- 1973;**108**:328–33.
- ³⁶ Hung K-S. Innervation of the pre- and post-natal mouse tracheas and lungs. *Anat Rec* 1978;**190**:427.
- ³⁷ Korner P, Shaw J, West M, Oliver J, Hilder R. Integrative reflex control of heart rate in the rabbit during hypoxia and hyperventilation. *Circ Res* 1973;**33**:63–73.
- ³⁸ Pillsbury H, Guazzi M, Freis E. Vagal afferent depressor nerves in the rabbit. *Am J Physiol* 1969;**217**:768–70.
- ³⁹ Lauweryns J, Cokelaere M, Theunynck P. Neuroepithelial bodies in respiratory mucosa of various animals. A light histochemical and ultrastructural investigation. *Z Zellforsch* 1972;**135**:569–92.
- ⁴⁰ Lauweryns J, Cokelaere M, Theunynck P, Deleersnyder M. Neuroepithelial bodies in mammalian respiratory mucosa: light optical histochemical and ultrastructural studies. *Chest* 1974;**65**:suppl:22–9.
- ⁴¹ Lauweryns J, Cokelaere M, Deleersnyder M, Liebens M. Intra-pulmonary neuro-epithelial bodies in newborn rabbits. *Cell Tissue Res* 1977;**182**:425–40.
- ⁴² Knight D. Innervation of the pulmonary vessels in the dog and cat. *Anat Rec* 1975;**181**:397.
- ⁴³ Fillenz M. Innervation of pulmonary and bronchial vessels of the dog. *J Anat* 1970;**106**:449–61.
- ⁴⁴ Hung K-S, Loosli C. Ultrastructure and innervation of pulmonary veins of the mouse. *Anat Rec* 1974;**178**:380.
- ⁴⁵ Hung K-S, Loosli C. Electron-microscopic studies of the innervation of the pulmonary veins of the mouse. *Acta Anat (Basel)* 1977;**97**:102.