

## Progressive bronchocentric granulomatosis: case report

MARTIN D CLEE, DAVID LAMB, STANISLAW J URBANIAK, ROLAND A CLARK

From Department of Respiratory Medicine, King's Cross Hospital, Dundee; the Department of Pathology, University of Edinburgh; and Edinburgh and South-East Scotland Blood Transfusion Centre

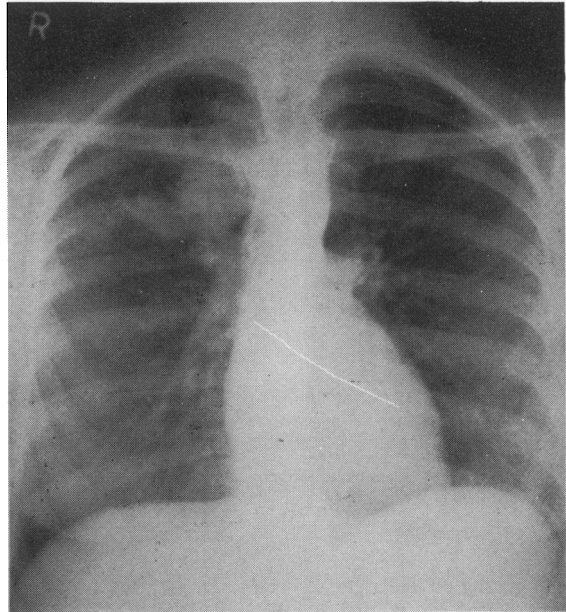
Bronchocentric granulomatosis was first described in 1973<sup>1</sup> and is characterised by a necrotising granulomatous destruction of bronchial walls, bronchioles, and adjacent lung parenchyma. The bronchial lumen is filled by debris and cells, predominantly eosinophils in asthmatic patients and polymorphonuclear leucocytes in non-asthmatic patients.<sup>2</sup> Proximal bronchi may show severe chondritis. Any vascular lesions are secondary to the bronchial disease.<sup>3</sup> The aetiology of bronchocentric granulomatosis in non-asthmatic patients is obscure; but in asthmatic patients fungi may be isolated, and Katzenstein<sup>4</sup> suggests that bronchocentric granulomatosis is one pathological expression of the clinical syndrome allergic bronchopulmonary aspergillosis.

Despite the high incidence of allergic bronchopulmonary aspergillosis in Britain the only reference to bronchocentric granulomatosis in British reports is a personal communication from Hinson.<sup>5</sup> We present a case of bronchocentric granulomatosis in a British woman who had never travelled abroad.

### Case report

In 1974 a pre-employment chest radiograph showed an irregular shadow in the right upper lobe of a 36-year-old woman (fig). She had had asthma since childhood but had been symptom free for seven years. She smoked 20 cigarettes per day. On auscultation a persistent rhonchus was audible over the right upper lobe. The results of investigations are shown in the table. Rigid bronchoscopy showed a plaque in the right-upper-lobe bronchus inaccessible to biopsy. At thoracotomy the right upper lobe was resected.

Macroscopically, the proximal airways were widely dilated and contained sausage-like masses of inspissated material. Smaller airways were dilated and surrounded by scar tissue; distally bronchopneumonia appeared to be present. Microscopically the plugs of material within bronchi consisted of aggregates of cellular debris, eosinophilic material, and large numbers of Charcot-Leyden crystals. Viable eosinophils were adjacent to the cellular debris. Stains for fungi showed scanty septate hyphae compatible with an *Aspergillus* species. The large airways were partly lined with hyperplastic epithelium and by granulation tissue. The more distal airways were lined by scar tissue, the inner aspect of which showed a fibrillary fibrinoid necrosis. Eosinophils were frequent in the walls of proximal airways and in collapsed fibrosed parenchyma around the distal airways. Occasional multinucleate giant cells and histiocytes were seen in relation to the eosinophilic necrosis of



Chest radiograph showing multilobular pattern (also seen in the lateral view), the characteristic "gloved fingers" appearance of mucoïd impaction.<sup>6</sup>

distal airways, but there was no acute inflammation. No true granulomas were seen and no tubercle bacilli identified. A pathological diagnosis of bronchocentric granulomatosis was made.

The patient was lost to follow-up, but was referred again in 1977 with increasing wheeze, dyspnoea, and productive cough. She had signs, confirmed radiologically, of collapse of the remaining right lung. Results of investigations are shown in the table. At bronchoscopy the right bronchial tree contained tenacious mucus with considerable mucosal oedema and distortion and narrowing of the lumen. The left side was normal. Bronchial biopsy specimens showed extensive infiltration by eosinophils and lymphocytes. Cytological and bacteriological investigations, including cultures for fungi, gave negative results. She later coughed up plugs, which she discarded.

There was little progress until the patient started prednisolone 20 mg daily, when rapid re-expansion of the lung occurred. The dose of prednisolone was reduced gradually. Bronchoscopy five months later showed improvement in the gross appearances of the right bronchial tree and at

Address for reprint requests: Dr MD Clee, Department of Respiratory Medicine, King's Cross Hospital, Dundee DD3 8EA.

## Results of investigations at presentation and during the late progression of bronchocentric granulomatosis

	1974	1977	1979	Immunological screen <sup>†</sup> (1979)*
White blood cells ( $\times 10^9/l$ )	8.2	6.7	6.5	White blood cells ( $\times 10^9/l$ )
Eosinophils	7%	3%	3%	Total 6.5 (4.0–11.0)
Mantoux (1/100)	Neg	Neg	Neg	Neutrophils 4.3 (2.5–7.5)
Sputum				Lymphocytes 1.3 (1.0–3.5)
<i>Aspergillus</i> culture	NA	Neg	Neg	T cells 1.1 (0.98–3.5)
Eosinophils	NA	+++	NA	B cells 0.12 (0.06–0.4)
Serum				Immunoglobulins (g/l)
<i>Aspergillus</i> precipitins	Neg	Neg	Neg	IgG 11.10 (7–19)
RAST <i>Aspergillus</i>	NA	NA	Very high (RAST score 4)	IgA 3.00 (0.9–4.5)
Skin test: <i>Aspergillus</i> sp				IgM 2.34 (0.55–2.2)
Immediate	++	++	++	IgE 2000 (20–400)
Delayed	Neg	Neg	Neg	Neutrophil chemotaxis ( $\mu$ migrated)
FEV <sub>1</sub> (predicted)	2.1 (2.5)	1.4 (2.5)	1.7 (2.5)	Unstimulated Casein " "
FVC (predicted)	3.0 (2.9)	2.7 (2.9)	2.65 (2.9)	Neutrophil <i>Candida</i> kill (% kill and % phagocytosis) "
				Lymphocyte transformation <sup>†</sup> "
				Monocyte migration "
				Serum complement (C3, C4, and CH <sub>50</sub> % normal human plasma) "

NA—not available.

\*Normal ranges in parentheses.

<sup>†</sup>Mitogens: phytohaemagglutinin, concanavalin A; antigens: mixed lymphocyte reaction, purified protein derivative.

biopsy only mild inflammatory infiltrate was seen. Bronchography on the right showed proximal bronchiectasis, but the left side was normal. FEV<sub>1</sub> had improved to 2.2 l. One month later, while taking 5 mg prednisolone daily, she developed wheeze, audible over the right lung only. A chest radiograph showed linear and nodular opacities on the right. Her FEV<sub>1</sub> had fallen to 1.7 l. When she took 10 mg prednisolone daily her symptoms and radiograph cleared.

In 1979 she was weaned off steroids. After a month her symptoms returned and a detailed immunological screen was arranged (table); the only notable result was the considerably raised IgE. For 3 years she has been taking 5 mg prednisolone daily and has remained well.

## Discussion

Inhalation of *Aspergillus* species may produce various host responses.<sup>8</sup> Katzenstein has suggested that bronchocentric granulomatosis is one of four pathological expressions of the clinical syndrome allergic bronchopulmonary aspergillosis,<sup>4</sup> the other three entities being (a) mucoid impaction of mucus plugs in proximal bronchi ("macroimpaction"); (b) allergic aspergillosis, defined pathologically as a reaction in smaller airways with mucoid "microimpaction"; and (c) eosinophilic pneumonia. Patients may present either with one or with a combination of these. Bronchocentric granulomatosis has itself two histological

variants—the eosinophil-predominant granuloma of asthmatic patients, in which fungal hyphae may be identified, when a hypersensitivity reaction to fungi is suggested;<sup>8</sup> and the polymorphonuclear-leucocyte-predominant granuloma of non-asthmatic patients, when no fungi are found and the aetiology is uncertain.<sup>2</sup> The resected specimen in our patient showed mucoid impaction and bronchocentric granulomatosis of the asthmatic type.

While bronchocentric granulomatosis has no definitive clinical, radiological, or immunological features, the diagnosis depending on the pathological findings from biopsy specimens or resected material, this does not explain the dearth of cases reported from Britain, where the incidence of allergic bronchopulmonary aspergillosis is higher than in the United States, where most cases of bronchocentric granulomatosis have been described.

The second episode of collapse and consolidation of the remaining right lung with no bronchoscopic evidence of proximal obstruction, its clearance with steroids, and the recurrence of linear and nodular opacities when steroids were reduced are compatible with the further progression of bronchocentric granulomatosis in lungs that were apparently normal at the time of resection. Usually surgical resection, with or without a short course of steroids, is curative.<sup>2,4,9</sup> In this case, however, long-term corticosteroids were required to prevent progression of the disease.

We wish to thank Mrs E Chaplin for typing the manuscript.

References

- <sup>1</sup> Liebow AA. The J Burns Amberson Lecture—pulmonary angiitis and granulomatosis. *Am Rev Respir Dis* 1973;**108**:1–18.
- <sup>2</sup> Koss MN, Robinson RG, Hochholzer L. Bronchocentric granulomatosis. *Human Pathol* 1981;**12**:632–8.
- <sup>3</sup> Edwards CW. Vasculitis and granulomatosis of the respiratory tract. *Thorax* 1982;**37**:81–7.
- <sup>4</sup> Katzenstein A-L, Liebow AA, Friedman PJ. Bronchocentric granulomatosis, mucoid impaction and hypersensitivity reactions to fungi. *Am Rev Respir Dis* 1975;**111**:497–537.
- <sup>5</sup> Spencer H. *Pathology of the lung*. 3rd ed. Oxford: Pergamon Press, 1977.
- <sup>6</sup> Fraser RG, Paré JAP. *Diagnosis of diseases of the chest*. Vol 2, 2nd ed. Philadelphia: WB Saunders, 1978:947–56.
- <sup>7</sup> Urbaniak SJ, White AG, Barclay GR, Wood SM, Kay AB. *Handbook of experimental immunology*. 3rd ed. Edinburgh: Blackwell, 1978.
- <sup>8</sup> Hinson KFW, Moon AJ, Plummer NS. Bronchopulmonary aspergillosis. A review and a report of eight new cases. *Thorax* 1952;**7**:317–33.
- <sup>9</sup> Saldana MJ. Bronchocentric granulomatosis: clinicopathologic observations in 17 patients. *Lab Invest* 1979;**40**:281–2.