

# Short reports

## Mucous gland adenoma of the bronchus

C W EDWARDS AND H R MATTHEWS

*From the Departments of Histopathology and Thoracic Surgery, East Birmingham Hospital, Birmingham*

Mucous gland adenoma, or cystadenoma, is one of the rarest epithelial neoplasms of the lung.<sup>1</sup> It arises from the mucous glands of the larger bronchi, and presents as a pedunculated polyp in the lumen. Histologically, it consists of acini lined by well-differentiated mucus-secreting cells. Unlike other so-called pulmonary adenomata, this type of tumour is unequivocally benign.

### Case report

A previously healthy man of 27 years, who smoked only occasionally, was admitted to hospital with what appeared to be lobar pneumonia. However his symptoms did not subside as expected, and on bronchoscopy he was found to have a polypoid tumour obstructing the main left lower lobe bronchus.

Six weeks later he was referred to the Thoracic Surgical Unit at East Birmingham Hospital for further treatment. By now he felt well. Nothing untoward was found on examination, and routine preoperative biochemical and haematological parameters were normal.

Subsequent thoracotomy revealed that the left lower lobe was adherent to surrounding structures and considerably damaged by obstructive pneumonitis. Hilar lymph nodes were enlarged. Although the tumour was situated very near to the origin of the lower lobe bronchus, it was possible to resect it with the lower lobe, leaving the upper lobe intact.

### Pathology

The main lower lobe bronchus was almost completely occluded by a smooth, roughly spherical, pedunculated tumour approximately 1.5 cm in diameter, which, when bisected, had a firm, cream-coloured cut surface. It was well defined, and did not extend beyond the submucosa. Distally the bronchi were dilated and contained tenacious muco-pus.

On light microscopy the tumour was composed of mucus-containing acini, the majority of which were approximately 65  $\mu$ m in diameter, although some were dilated to over 500  $\mu$ m (fig 1). The acini were lined by a single layer of cuboidal or somewhat flattened cells with a pale, rather foamy cytoplasm. Their

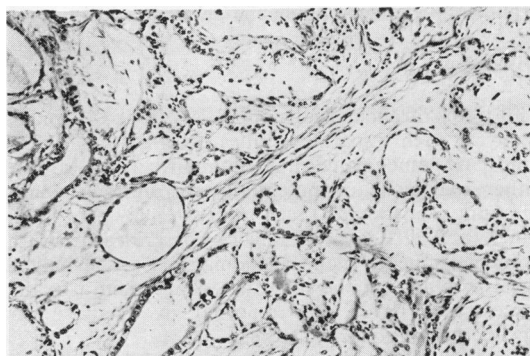


Fig 1 Part of the tumour described in the text. Acini of various sizes are lined by cuboidal or flattened epithelium and contain mucin. Haematoxylin and eosin, original magnification  $\times 110$ .

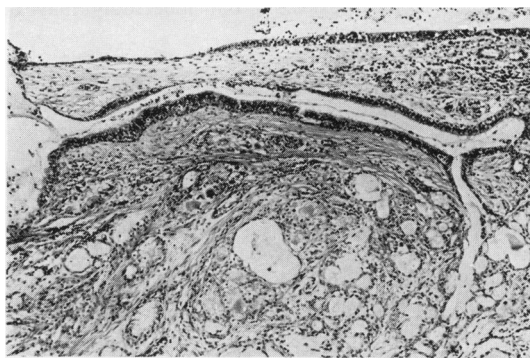

Fig 2 A ductlike structure opens into the bronchial lumen at top left, runs parallel to the surface of the tumour and terminates in acini at bottom right. Haematoxylin and eosin, original magnification  $\times 70$ .

nuclei had an open chromatin pattern and a single prominent nucleolus. No mitotic figures were observed. Occasional densely basophilic pyramidal nuclei, which closely resembled those of myoepithelial cells, were situated at the periphery of the acini.

The pedicle of the tumour was covered by ciliated columnar epithelium identical to the adjacent bronchial lining. Towards its apex there were foci of squamous metaplasia and areas of healing ulceration. Ductlike structures, lined by mucous or ciliated cells,

Address for reprint requests: Dr CW Edwards Department of Histopathology, East Birmingham Hospital, Bordesley Green East, Birmingham B9 5ST.

extended from the surface and appeared to terminate in clusters of acini (fig 2).

The stroma was composed of hyaline connective tissue which contained fibroblasts and occasional foci of plasma cells and lymphocytes. Although the tumour appeared well demarcated on gross examination, there was no histological evidence of a capsule. The neoplastic acini merged with those of the underlying bronchial mucous gland.

The tumour had been fixed en bloc in formol saline, and ultrastructural preservation was poor. Despite this it was possible to identify well-developed Golgi complexes and numerous membrane-bound secretion granules in the cells lining the acini.

### Discussion

The term "bronchial adenoma" is still applied incorrectly to such disparate entities as cylindroma, carcinoid and muco-epidermoid tumour, which are all either malignant or potentially so. In fact, benign tumours of glandular tissue are extremely rare in the lung. In 1967 Kroe and Pitcock<sup>2</sup> described a case of bronchial mucous gland adenoma, and found only 10 other examples in the literature. Since then a further three cases have been reported in detail,<sup>3-5</sup> and Spencer<sup>1</sup> mentions five others.

Mucous gland adenoma occurs in children as well as adults. The sex incidence is equal. Because it presents as a pedunculated polyp in a major bronchus, the clinical picture is one of chronic bronchial obstruction, sometimes with haemoptysis. The treatment of choice is local excision, but lobectomy may be

necessary if, as in the present case, there is irreversible damage to distal lung tissue.

The microscopic structure of this tumour is similar to that of normal bronchial glandular tissue, although serous elements are not present. Pritchett and Key<sup>5</sup> were able to confirm that the acinar lining cells secrete a mucin which is histochemically of epithelial type, and, like us, they found well-developed Golgi complexes and membrane-bound secretory granules. These features are characteristic of mucous cells of the bronchial glands. Ducts opening on the surface have not previously been described and their significance is uncertain. It is likely that they are pre-existing bronchial ducts which have become incorporated in the tumour, but a neoplastic origin cannot be ruled out. Squamous metaplasia of the overlying epithelium has been noted previously,<sup>2,3</sup> and is probably a reaction to chronic irritation.

### References

- 1 Spencer H. Bronchial mucous gland tumours. *Virchows Arch (Pathol Anat)* 1979; **383**:101-15.
- 2 Kroe DJ, Pitcock JA. Benign mucous gland adenoma of the bronchus. *Arch Pathol* 1967; **84**: 539-42.
- 3 Emory WB, Mitchell WT, Hatch HB. Mucous gland adenoma of the bronchus. *Am Rev Respir Dis* 1973; **108**:1407-10.
- 4 Allen MS, Marsh WL, Geissinger WT. Mucous gland adenoma of the bronchus. *J Thorac Cardiovasc Surg* 1974; **67**:966-8.
- 5 Pritchett PS, Key BM. Mucous gland adenoma of the bronchus: ultrastructural and histochemical studies. *Ala J Med Sci* 1978; **15**:43-8.