

Unilateral superior vena caval syndrome

JOHN W FORMAN AND KENNETH M UNGER

From Pulmonary Division, Department of Medicine, University of Texas Medical School at Houston, Houston, Texas, USA

The superior vena caval syndrome is characterised by facial oedema, plethora, puffiness of the neck and arms, and a prominent venous pattern over the upper thorax. We describe a patient who presented with these signs manifest only on the left side of his neck and upper chest. Because of clinical similarity to the superior vena caval syndrome, we have called this the unilateral superior vena caval syndrome.

Case report

A 68-year-old white man was admitted complaining of swelling of the left side of the neck and left arm. The swelling had been present for eight months, but it had become more severe in the two weeks before his admission. He had had a chronic cough and sputum for many years and dyspnoea on exertion over the previous four months. He denied weight loss, headache, vertigo, seizures, or altered consciousness. There was no history of hypertension or heart disease.

Physical examination revealed firmness and swelling over the left side of the neck, supraclavicular area, and lateral aspect of the left upper arm. The left external jugular vein was distended and there was a prominent venous pattern over the left anterior chest and left upper arm (fig 1). The right upper chest and neck appeared normal. The chest was hyper-resonant throughout, and on percussion of the chest the left diaphragm appeared not to move. Breath sounds on both the right and left were diminished. The remainder of the examination was not remarkable.

A chest radiograph showed a left periaortic density in the anterior mediastinum and an elevated left hemidiaphragm. Sputum was negative for acid-fast bacilli and fungi. An intermediate PPD skin test was negative. An aortogram was performed, and aneurysms of the aortic arch, brachiocephalic and subclavian arteries, and abdominal aorta were noted. Venograms of both upper extremities revealed complete occlusion of the left subclavian and innominate veins (fig 2). The superior vena cava and the right-sided venous structures were normal.

At operation a 5 cm long multilobulated thin-walled saccular aneurysm was seen arising from the

upper side of the aortic arch just distal to the origin of the left subclavian artery. The aneurysm was resected and a Dacron graft was placed. After operation, the patient developed thrombosis of the abdominal aorta and required emergency aorto-femoral bypass grafts. The postoperative course was complicated by gangrene of the left leg necessitating amputation, renal failure, pneumonia, hepatic failure, and myocardial infarction, which led to the patient's death after 38 days.

Discussion

Selective obstruction of an innominate vein appears to be extremely unusual. Of eight patients with primary axillary thrombosis (Paget-Schroetter syndrome), one—with left innominate vein occlusion—was later found to have an aortic aneurysm.¹ McCord *et al*² reported one case of right innominate vein occlusion thought to be caused by thrombosis associated with severe heart failure. Selective obstruction of the left innominate vein from a malignant thymoma was reported by Cayley,³ and Hinshaw and Rutledge⁴ described three patients with left innominate vein occlusion, one caused by an aortic aneurysm, and two by neoplasia (a bronchial carcinoma and a metastatic testicular carcinoma).

It is surprising that obstruction of a single innominate vein is not more common. The large mediastinal veins are thin-walled, and the blood flowing through them is under low pressure. Therefore, these vessels are susceptible to obstruction by mediastinal lesions expanding anteriorly against an unyielding bony thorax.⁴ One might expect to see obstruction more commonly on the left than on the right, as the left innominate vein is longer (mean of 7.2 cm) than the right (mean of 4.6 cm) and traverses the anterior mediastinum.⁵

References

- 1 Gould EP, Patey DH. Primary thrombosis of the axillary vein: a study of eight cases. *Br J Surg* 1928-29; **16**:208-13.
- 2 McCord MC, Edlin P, Block M. Superior vena caval system obstruction. *Dis Chest* 1951; **19**:19-27.
- 3 Cayley O. Cancer of the anterior mediastinum probably originating in the thymus gland. *Trans Pathol Soc London* 1868; **19**:53.

- 4 Hinshaw HC, Rutledge DI. Lesions in the superior mediastinum which interfere with venous circulation. *J Lab Clin Med* 1942; 27: 908-16.
- 5 Roberts DJ, Dottler DT, Steinberg I. Superior vena cava and innominate veins. *AJR* 1951; 66: 341-52.

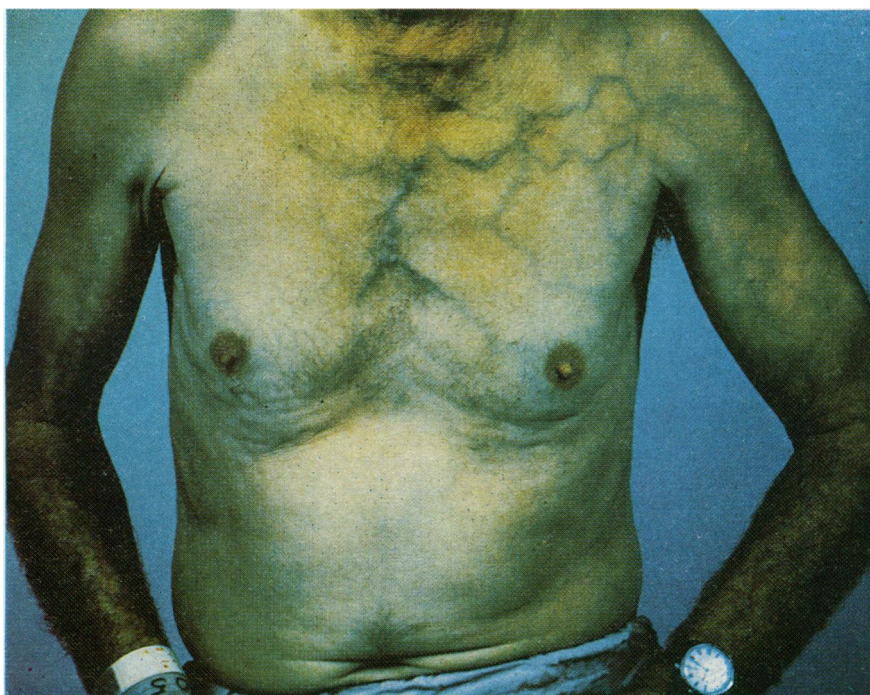

Fig 1 *Infra-red photograph demonstrating venous engorgement over the left upper thorax and arm.*

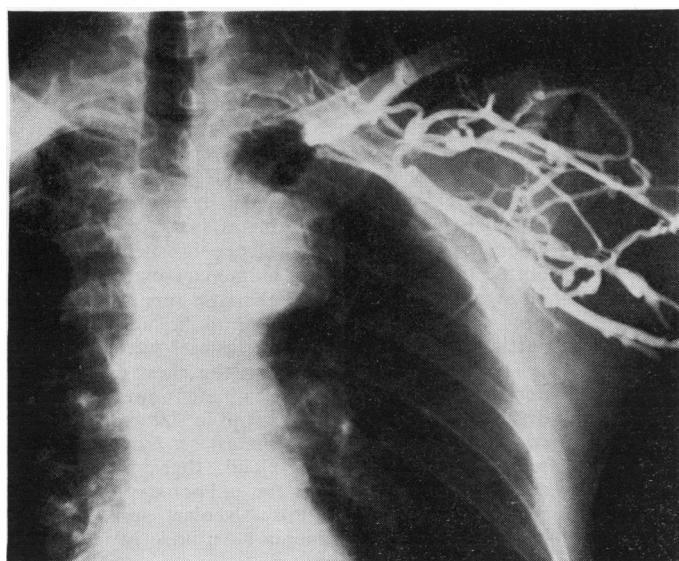


Fig 2 *Venogram, injected from the left basilic vein, showing obstruction of the left subclavian and innominate veins and the collateral circulation.*