

# Indirect arterial pulse tracings in children with coarctation of the aorta before and after operation

M OYONARTE, D F DICKINSON, D MEDICI, AND D I HAMILTON

*From the Regional Paediatric Cardiothoracic Unit, Royal Liverpool Children's Hospital, Myrtle Street, Liverpool*

**ABSTRACT** Eleven children with coarctation of the aorta were investigated before and after surgical treatment, using simultaneous indirect carotid and femoral artery pulse wave tracing. The timing of the onset of the femoral pulse in the children with coarctation, both before and after operation, did not differ significantly from normal. However, the time interval between the peak of the femoral pulse and the dicrotic notch of the carotid pulse was significantly shorter than normal in the children with coarctation before operation. After operation the peak femoral to carotid dicrotic notch time interval was restored to normal. It is suggested that this simple non-invasive test might be of value in the long-term follow-up of patients after operation for coarctation of the aorta, particularly in those undergoing operation early in childhood, to detect residual or recurrent coarctation.

The first use of synchronous indirect radial and femoral artery pulse recording in coarctation of the aorta was reported by Scheele.<sup>1</sup> Since then, further studies have shown the value of the technique.<sup>2,3</sup> However, although direct intra-arterial measurements of femoral and radial artery pulse pressure have been made before and after surgical repair of coarctation,<sup>4,5</sup> no study using indirect assessment has been reported. The potential value of a simple non-invasive technique which supplements clinical examination is considerable, particularly in the paediatric age group. We have studied a group of children undergoing surgical treatment for coarctation of the aorta in order to assess the use of indirect pulse recordings.

## Patients and methods

Eleven children with coarctation of the aorta were studied at the Royal Liverpool Children's Hospital. The diagnosis was confirmed by cardiac catheterisation and angiography as part of the routine preoperative assessment, and in nine cases direct arterial pressure gradients across the site of coarctation were recorded. Full clinical details of the cases are given in the table. Eleven normotensive children without cardiovascular abnormalities,

matched for age with the children with coarctation of the aorta, served as control subjects. Simultaneous indirect pulse recordings were obtained from the left carotid and left femoral arteries using Statham Universal Transducing Cell, model UC3, strain gauges, mounted in nylon holders (Cambridge Instruments). Records were taken in partial expiration on a Cambridge multichannel physiological recorder using a paper speed of 50 and 100 mm/second.

An ECG (lead II) and a phonocardiogram from the third intercostal space at the left sternal edge were recorded simultaneously. From these records, two measurements were made each to the nearest five milliseconds. The delay in onset of the femoral pulse (onset time) was measured from the onset of the carotid pulse. The delay in the peak of the femoral pulse was measured as the time interval between the dicrotic notch of the carotid pulse and the peak of the femoral pulse (PF-CDN time). Where the peak of the femoral pulse fell later than the carotid dicrotic notch the time interval was recorded as a negative value. The carotid dicrotic notch was chosen as a useful fixed reference point on the arterial pulse wave which can be recognised by its relationship to the aortic component of the second heart sound. In each case, five cardiac cycles were analysed, and a mean value for each measurement was obtained.

Address for reprint requests: David I Hamilton, Royal Liverpool Children's Hospital, Myrtle Street, Liverpool L7 7DG.

Table Clinical data on eleven patients with coarctations

Patient	Age at operation (yr)	Preoperative peak systolic arterial pressure (mm Hg)		Surgical correction	Postoperative sphygmomanometer pressures (mm Hg)	
		Ascending aorta	Descending aorta		Arm	Leg
1	4	125	85	Left subclavian flap aortoplasty	85	80
2	5	—	90	End-to-end anastomosis	105	110
3	5	130	100	Dacron gusset	110	110
4	7	150	95	Dacron gusset	130	—
5	6	—	90	End-to-end anastomosis	100	90
6	7	110	80	End-to-end anastomosis	105	—
7	7	110	90	End-to-end anastomosis	110	—
8	9	140	100	Dacron gusset*	115	—
9	9	120	90	Dacron gusset	105	100
10	13	140	95	Dacron tube graft	140	125
11	15	140	110	Dacron gusset*	130	110

\*Operation for residual coarctation

These measurements are illustrated on the recording from a control patient in fig 1. In the patients with coarctation of the aorta, further recordings were made six to eight weeks after operation. Student's *t* test was used for statistical analysis of the data.

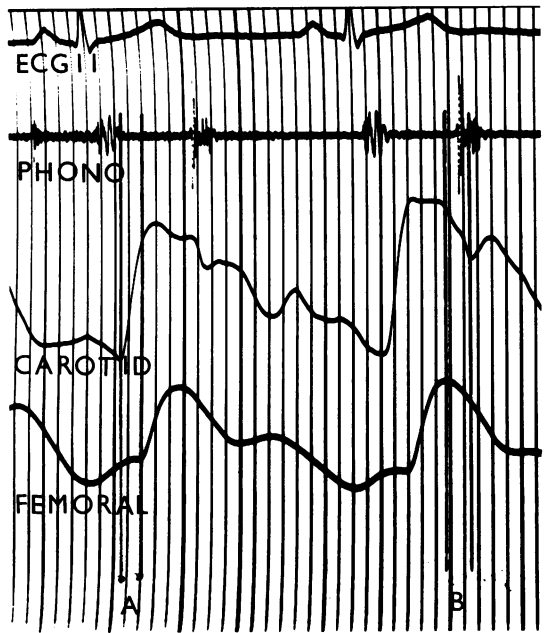


Fig 1 Simultaneous carotid and femoral pulse tracings from a normal control subject. Each vertical line indicates a time interval of 0.04 seconds. The time interval between the onset of the carotid and femoral pulses (A) is approximately 0.06 seconds. The time interval between the peak of the femoral pulse and the dicrotic notch of the carotid pulse (B) is approximately 0.07 seconds.

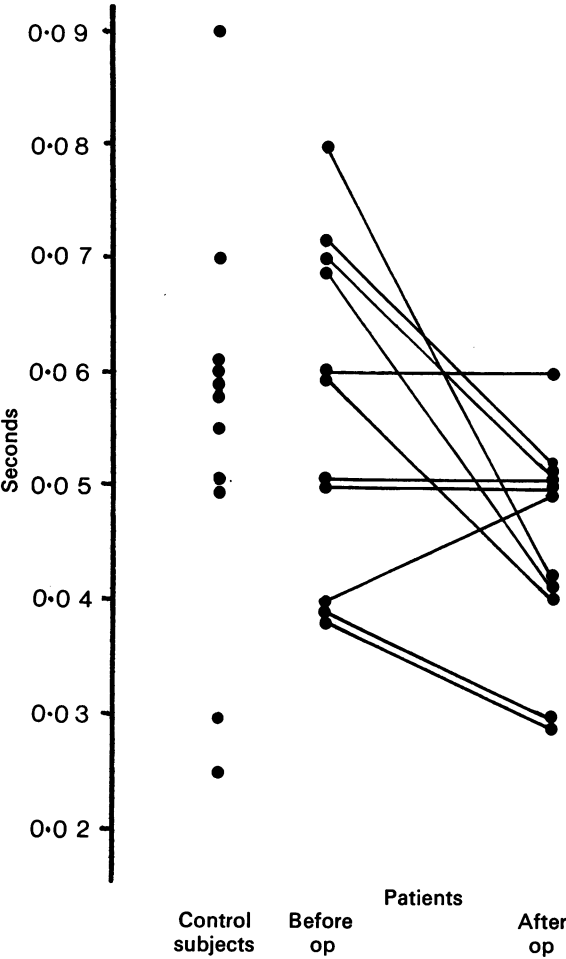


Fig 2 Time interval between the onset of the simultaneously recorded carotid and femoral pulses in normal control subjects and patients with coarctation of the aorta before and after operation.

## Results

The mean values of the measurements of onset time interval and PF-CDN time interval for each patient before and after operation, together with the results from the control subjects are given in figs 2 and 3. The mean value for the onset time interval in the patients with coarctation before operation was 0.057 seconds (SD 0.014, range 0.04 to 0.08 s). The value for the normal control sub-

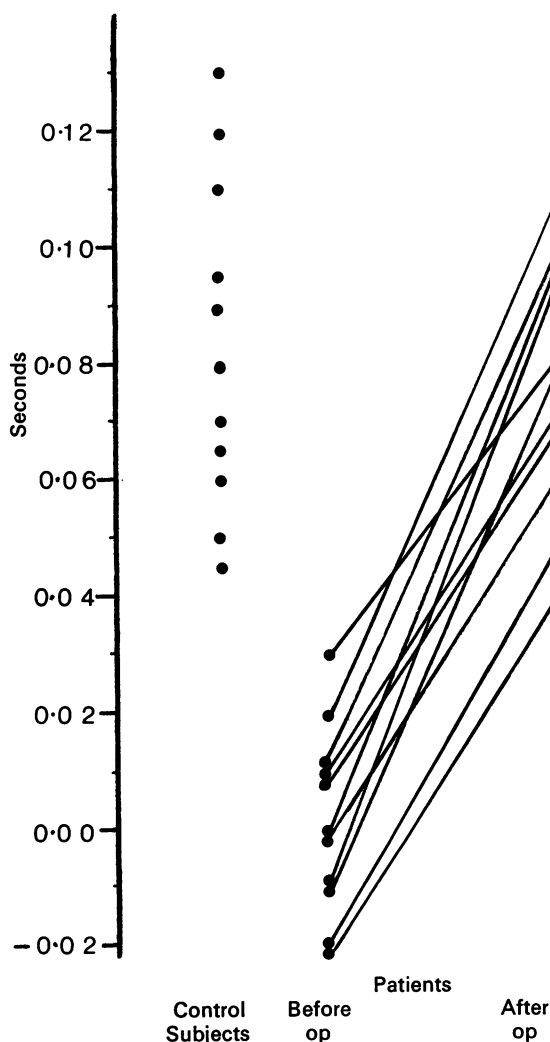


Fig 3 Time interval between the peak of the femoral pulse and the dicrotic notch of the simultaneously recorded carotid pulse in normal control subjects and patients with coarctation of the aorta before and after operation.

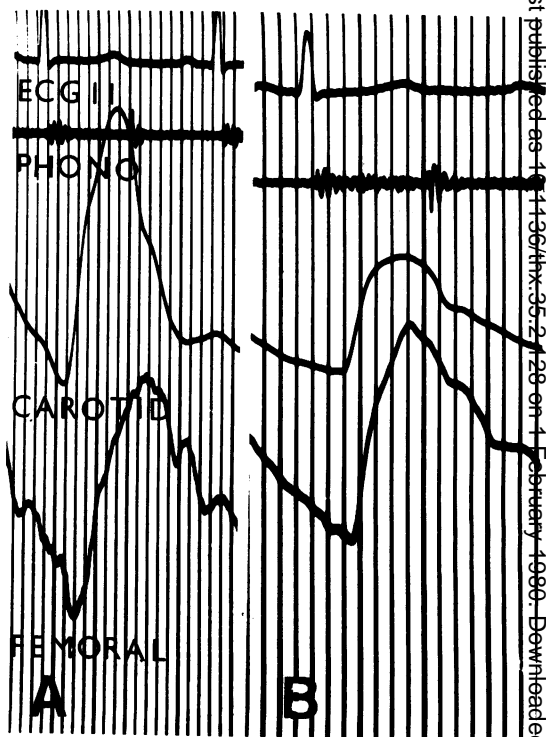


Fig 4 Simultaneous femoral and carotid artery pulse tracing from patient 8. (A) Before operation. The onset of the femoral pulse is delayed 0.04 seconds after the onset of the carotid pulse, and the peak of the femoral pulse falls 0.03 seconds after the carotid dicrotic notch. (B) After operation. The onset of the femoral pulse is 0.03 seconds after the onset of the carotid pulse and the peak of the femoral pulse falls 0.08 seconds before the carotid dicrotic notch.

jects was 0.055 seconds (SD 0.018, range 0.025 to 0.09 s). This difference is not significant. After operation, the mean onset time interval was 0.041 seconds (SD 0.01, range 0.03 to 0.06 s). This is significantly different from the preoperative value ( $p < 0.05$ ) but not from the values in control subjects ( $p < 0.05$ ).

The mean value for the PF-CDN time interval before operation in the patients with coarctation of the aorta was 0.00 seconds (SD 0.016, range -0.02 to +0.03 s), and significantly different ( $p < 0.001$ ) from the mean of the normal control subjects (0.083 seconds, SD 0.028, range 0.045 to 0.13 s). After operation, the mean PF-CDN value was 0.075 seconds (SD 0.021, range 0.04 to 0.1 s), which differed significantly ( $p < 0.001$ ) from the preoperative value, but not from that of the normal

control subjects ( $p < 0.1$ ). The pulse pressure recordings before and after operation from a patient with coarctation are illustrated in fig 4. No correlation was found between either the onset time interval or the PF-CDN time interval and the peak systolic pressure gradient across the site of the coarctation before operation.

## Discussion

Although considerable clinical importance has been given to the delay in the transmission of the arterial pulse wave to the lower extremity in coarctation of the aorta, published studies of directly or indirectly recorded femoral pulse waveform have failed to show a consistent delay in the onset of the femoral pulse as compared with upper limb pulses.<sup>4-6</sup> Thus, although there is a tendency for the onset of the femoral pulse to be delayed beyond the onset of the radial pulse in patients with coarctation of the aorta, this is also true of a significant proportion of normal individuals. Conversely, in some patients with coarctation the onset of the femoral pulse has been shown to precede the onset of the radial pulse.<sup>3</sup> Our present results confirm the wide range of values seen in normal individuals, which overlap extensively the ranges of values seen in patients with coarctation both before and after operation. Although there is a tendency for the onset time interval to shorten after operation (fig 2), in a number of cases no difference could be recorded.

Lewis<sup>6</sup> emphasised that the clinically appreciated delay in the femoral pulse in coarctation was related to the slow ascent of the femoral pulse curve to a delayed peak. Kuhn *et al.*,<sup>3</sup> using indirect arterial pulse tracings, showed that the time interval between the delayed femoral peak and the dicrotic notch of a simultaneously recorded carotid pulse discriminated clearly between patients with coarctation and normal individuals. Our results endorse their findings. Although we were unable to show a correlation between preoperative PF-CDN time interval and directly measured pressure gradients, the restoration of the PF-CDN time interval to normal suggests a satisfactory result after operation. This view is supported by the work of previous authors,<sup>4,5</sup> using directly measured pulse pressure tracings. It is of interest that although the PF-CDN time interval was significantly increased in all patients after operation, this increase was most marked in the youngest patient who underwent an angioplastic repair of the coarctation by subclavian flap aortoplasty.<sup>7</sup> Conversely, the increase in PF-CDN time

interval was least in the patient who required a complete Dacron tube graft to restore aortic continuity after resection of a hypoplastic segment 6 cm in length.

Several recent reports have shown a significant incidence of persistent hypertension after surgical repair of coarctation of the aorta.<sup>8,9</sup> There is some evidence to suggest that early operation, probably before the age of 2 years, is more likely to result in a satisfactory postoperative blood pressure than if operation is delayed until later in childhood.<sup>8,9</sup> However, end-to-end anastomosis of the aorta in early childhood is associated with a significant risk of persistent or recurrent coarctation during the growth period.<sup>10-12</sup> Left subclavian flap aortoplasty appears to offer many advantages in this respect,<sup>7,13</sup> but further evaluation over a longer period is necessary. Measurements of the PF-CDN time interval provides a simple, non-invasive investigation which discriminates clearly between normal individuals and patients with coarctation. Serial recordings performed in the years after operation may therefore be useful in detecting residual obstruction at the operation site, and give a guide to the need for direct pressure measurement and angiography.

We would like to thank Dr E Epstein and Dr JL Wilkinson for their help and advice, Mr N Clarke for his technical assistance, and Mrs Sheila Critchley for secretarial help. D Medici was supported by a grant from the National Heart Research Fund.

## References

- 1 Scheele CWL. Fall von stenose des isthmus aortae. Aus der medizinischen klinik des Professor Leyden zu Königsberg. *Berliner Klinische Wochenschrift* 1870; 7:32-8.
- 2 Björk S, Liedholm K. The femoral pulse curve in coarctation of the aorta. *Acta Med Scand* 1949; 136:97-103.
- 3 Kuhn LA, Sapin SO, Grishman A, Donoso E. The use of indirect arterial pulse tracings in the diagnosis of congenital heart disease. 1. Coarctation of the aorta. *Pediatrics* 1956; 18:193-204.
- 4 Brown GE, Clagett OT, Burchell HB, Wood EH. Pre-operative and post-operative studies of intraradial and intrafemoral pressures in patients with coarctation of the aorta. *Mayo Clin Proc* 1948; 23:352-8.
- 5 Hallenbeck GA, Wood EH, Burchell HB, Clagett OT. Coarctation of the aorta; the relationship of clinical results to cardiovascular dynamics studied before, during and after surgical treatment. *Surg Gynecol Obstet* 1951; 92:75-8.

- 6 Lewis T. Material relating to coarctation of the aorta of the adult type. *Heart* 1931; **16**:205–61.
- 7 Hamilton DI, Di Eusanio G, Sandrasagra FA, Donnelly RJ. Early and late results of aortoplasty with a left subclavian flap for coarctation of the aorta in infancy. *J Thorac Cardiovasc Surg* 1978; **75**:699–704.
- 8 Shinebourne EA, Tam ASY, Elseed AM *et al*. Coarctation of the aorta in infancy and childhood. *Br Heart J* 1976; **38**:375–80.
- 9 Nanton MA, Olley PM. Residual hypertension after coarctectomy in children. *Am J Cardiol* 1976; **37**:769–72.
- 10 Khoury GH, Hawes CR. Recurrent coarctation of the aorta in infancy and childhood. *J Pediatr* 1968; **72**:801–6.
- 11 Hartmann AF, Goldring D, Hernandez A *et al*. Recurrent coarctation of the aorta after successful repair in infancy. *Am J Cardiol* 1970; **25**:405–10.
- 12 Patel R, Singh SP, Abrams L, Roberts KD. Coarctation of the aorta with special reference to infants. Long term results of operation in 126 cases. *Br Heart J* 1977; **39**:1246–53.
- 13 Pierce WS, Waldhausen JA, Berman W, Whitman V. Late results of the subclavian flap procedure in infants with coarctation of the thoracic aorta. *Circulation* 1978; **58**:78–82.