

Postnatal lung growth after repair of diaphragmatic hernia¹

WILLIAM M THURLBECK, K KIDA, CLAIRE LANGSTON, MORTON J COWAN, J A KITTERMAN, W TOOLEY, AND HEATHER BRYAN

From the Department of Pathology, University of Manitoba, Canada, Cardiovascular Research Institute, San Francisco, USA, and Hospital for Sick Children, Toronto, Canada

ABSTRACT The lungs of two patients who died eight months and 64 months after repair of a left-sided diaphragmatic hernia on the first day of life were examined. Lung volumes were appropriate for the size of the children, and the ratio of right lung volume to left lung volume was also normal in both patients. The lungs, however, were grossly abnormal with evidence of enlargement and destruction of respiratory tissue. The left lung was affected more than the right in both subjects. In one patient the total number of alveoli in the lungs was similar to that of normal children of the same age, but this was because the right lung had more than twice as many alveoli as the left lung. It appears that alveolar multiplication is impaired after repair of diaphragmatic hernia. The number of bronchioles was reduced in the infant with very few alveoli, and there may have been too few bronchioles in the other patient.

In 1962 Dunnill (1962b) showed that most alveoli developed in infancy and early childhood. Kitagawa *et al* (1971) published the first morphometric study of the lungs of a full-term infant with a diaphragmatic hernia who died three to four hours after birth. They found extensive impairment of growth in both lungs with fewer small bronchial and bronchiolar divisions and fewer conventional and supernumerary branches of the pulmonary arteries. They considered that the number of alveoli, assessed indirectly, per acinus was normal and thus there were too few alveoli because there were too few acinar units. The ipsilateral (left) lung was considerably smaller in volume than the right lung but the alteration in airway branching was about the same in both lungs, and there were fewer supernumerary branches of the pulmonary artery on the right side. Similar alterations in the airways were noted by Areechon and Reid (1963) and by Boyden (1972), and these authors also noted greater alterations in the lower lobes. Kitigawa *et al* (1971) pleaded for functional studies in the lungs of children subsequent to repair of diaphragmatic hernias since they felt that adequate further alveolar multiplication was unlikely to occur. They stated "Perhaps the most

that would be achieved would be multiplication to give the normal alveolar number supplied by each terminal bronchiolus—an outcome that is suggested by the normal radiograph of patients some months after correction of a hernia. Since this would mean a total reduced alveolar number, emphysema must develop if and when lung volume became normal." We have been able to examine the lungs of two patients who died eight and 64 months after repair of diaphragmatic hernia, and our results substantiate their hypothesis.

Case reports

CASE 1 (University of California, San Francisco)
A 2500 g boy was born at 36 weeks gestation and developed respiratory distress shortly after birth. He was operated on at 6 hours of age and a left diaphragmatic hernia was found that contained the spleen, stomach, entire small bowel, most of the colon, and the left lobe of the liver. The left lung was bilobed and about 1 cm in diameter. The hernia was reduced and repaired using a Dacron patch.

The postoperative course was complicated by hydrocephalus of unknown aetiology and pulmonary hypertension and insufficiency. For the

¹Supported by the Medical Research Council of Canada, Grant MA-6184, and the National Foundation—March of Dimes.

first week of life he was ventilated with 100% oxygen, and high inspiratory and expiratory pressures at a respiratory frequency of 80–100 breaths/min were needed to maintain adequate oxygenation. Between 7 and 35 days of age he was ventilated with 25–30% oxygen at decreasing respiratory rates until he was able to breathe spontaneously against a continuous positive airway pressure of 3 mmHg (0.4 kPa). He was extubated at 2 months of age. A chest film at 79 days of age showed lungs that distended the thorax, and the left lung was overinflated and hyperlucent (fig 1). At 3 months of age head growth accelerated, and a ventriculoperitoneal shunt was inserted because of hydrocephalus. This became infected and was removed after nine days and a second shunt was inserted at 4 months of age, which required revision at 5½ months. At this stage he had no respiratory difficulty, and his arterial blood gases on room air were P_{O_2} 45–50 mmHg (6.1–6.8 kPa) and P_{CO_2} 45–50 mmHg (6.1–6.8 kPa). At 6 months severe respiratory distress occurred because the diaphragmatic hernia dehiscd. This was repaired, and he gradually improved and was extubated on the tenth postoperative day. He subsequently developed, however, *Escherichia coli* meningitis and ventriculitis that was resistant to treatment and he died when 8 months old.

At necropsy he was a small infant weighing 3500 g and measuring 57 cm, but when admitted he had weighed 4900 g. The left lung weighed 45 g and the right lung 54 g. The lungs were distended

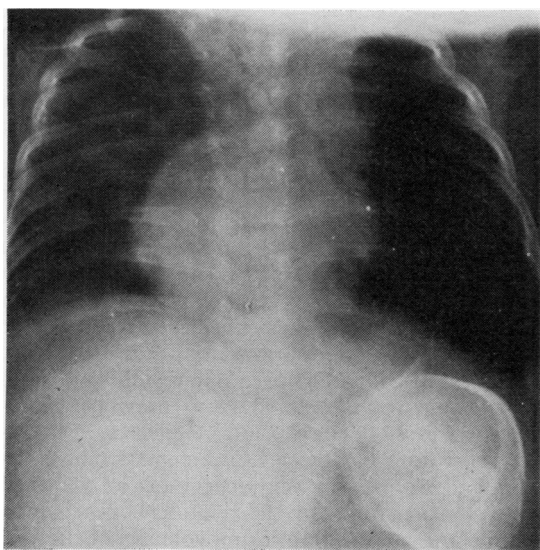


Fig 1 Patient 1. Left lung is hyperlucent and overinflated.

with 10% glutaraldehyde at a transpulmonary pressure of 25 cmH₂O (2.5 kPa) for 36 hours and were flown to Winnipeg. On arrival the left lung volume was 136 cm³ and the right lung volume was 142 cm³. The main and segmental bronchi were normal in number and arrangement on both sides as were the proximal three generations of bronchi. An attempt was made to enumerate the numbers of generations in the axial pathway of the posterior basal segment on both sides, but this was unsuccessful because priority was given to sampling of tissue for morphometry. Air spaces were variable in size in the right lung, but all were too large when compared to an infant of similar age (fig 2). The air spaces were even larger in the left lung, and several regions of enlargement and destruction of lung tissue were evident, and these comprised about 5% of the lung volume. The lungs were subjected to standard morphometric examination (Dunnill, 1962a, 1964; Weibel, 1963). The left lung contained 4.9 million alveoli and the right lung 15.7 million alveoli. Other morphometric data are shown in table 1. The number of bronchioles in the lungs were counted using method 2 as described by Matsuba and Thurlbeck (1971). The number of bronchioles in the left lung was 3557 and in the right lung 4326.

CASE 2 (Hospital for Sick Children, Toronto)

This 3420 g boy developed acute respiratory distress shortly after birth at 37 weeks gestation. The child was operated on at 2½ hours, and a left diaphragmatic hernia was found to contain stomach, spleen, small bowel, transverse colon, and left kidney and adrenal. The hernia was reduced and the diaphragm sutured with silk. The post-operative course was uneventful and assisted ventilation was not required. On the 19th post-operative day the left lung had fully expanded but the mediastinum appeared slightly shifted to the left. At age 2 months the child was readmitted for eight days for microbiologically proved pertussis infection. At this stage, and also at age 13 months, the chest radiographs were normal, as were arterial blood gases on room air. Functional residual capacity (FRC), dynamic compliance, and respiratory frequency were normal at 13 months of age.

At age 5 years 4 months he fell down two flights of stairs and was admitted to hospital deeply comatose. Bilateral acute frontal extradural haematomas and a subdural haematoma were evacuated, but the patient did not recover consciousness and died three days after admission.

At necropsy the child was well developed, weighing 17.2 kg and measuring 113 cm. The left

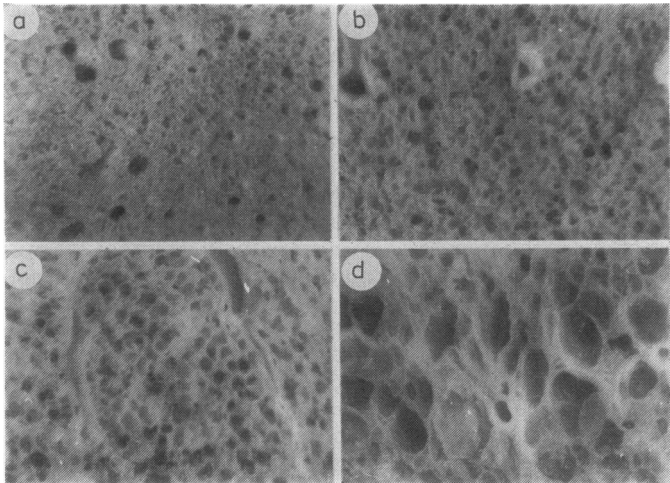


Fig 2 Patient 2. A normal lung (a) from a 9-month-old infant is compared to right lung (b) and left lung (c) in patient 1. A focus of obvious destructive emphysema is shown at (d). Barium sulphate impregnated slices, according to the method of Heard (1960) (enlarged $\times 18$).

Table 1 Morphometric data of the lungs of the two patients

Age (months)		Length (cm)	Weight (kg)	V_L Litre (dm ³)	V_L %	N_V $10^{-4}/cm^3$	N_V %	$N_{AT} \times 10^{-6}$	Lm μm	SA m^2	SA %	$V_{alv} \times 10^{-6} \mu m^3$
Patient 1	8	57	4.9	L 0.136	—	3.60	13	4.9	395	1.02	—	19.08
				R 0.142	—	10.68	38	15.7	315	1.08	—	5.12
				T 0.278	111	—	—	20.6	—	2.10	31	—
Patient 2	64	113	17.2	L 0.72	—	14.98	73	108	238	7.63	—	3.54
				R 0.79	—	30.58	149	242	185	10.27	—	1.64
				T 1.51	84	—	—	350	—	17.9	61	—

V_L =Volume of lung following inflation; V_L % = Lung volume as a percentage of predicted; N_V =Number of alveoli per cm^3 ; N_V % = Number of alveoli per cm^3 as percent of predicted; N_{AT} =Total number of alveoli; Lm =Average interalveolar wall distance; SA =Surface area of lung; SA/m =Alveolar surface area per meter of body length; SA % = Surface areas as a percentage of predicted; V_{alv} =Average alveolar volume; L=Left lung; R=Right lung; T=Total in lung.

lung weighed 107 g and the right lung 104 g. They were distended with 10% formaldehyde until apparently fully inflated and then allowed to fix for three days. The volume of the left lung was found to be 720 cm^3 and the right lung 790 cm^3 . The main, segmental, and first three orders of bronchi appeared normal in size and appearance. On both sides 14 orders of bronchi could be identified in the axial pathway to the posterior basal segment rather than the 16 orders expected in normals (Kitagawa *et al*, 1971). The number of bronchioles could not be established accurately by dissection. The general appearance of the lung was normal, but the air spaces in the left lung were larger than the right. In both lungs, but more obviously and more often in the left lung, there were subpleural areas where the airspaces were grossly enlarged and destroyed (fig 3). In the left lung about 5% of the lung showed such areas; in the right less than 1% was affected. The left lung contained 107 million alveoli and the right 242 million alveoli. Other morphometric data are

shown in table 1. The number of bronchioles in the left lung was 8856 and 19 643 in the right.

Discussion

Our results indicate that, while lung volume was restored approximately to that appropriate for body size, lung structure was abnormal after successful repair of diaphragmatic hernia in our two patients. The ipsilateral lung suffered more than the contralateral lung. As there are too few data for accurate comparison between the lungs of our cases and lungs from normal infants and children, we have chosen to compare our results to the regression equations derived from previously published cases (Thurlbeck and Angus, 1975). Unpublished lung volume measurements from 38 infants and children in Winnipeg show an identical regression equation for the relation between lung volume and body length. Lung volumes of the two patients presented here are similar to normal lungs, one being slightly larger than predicted and the

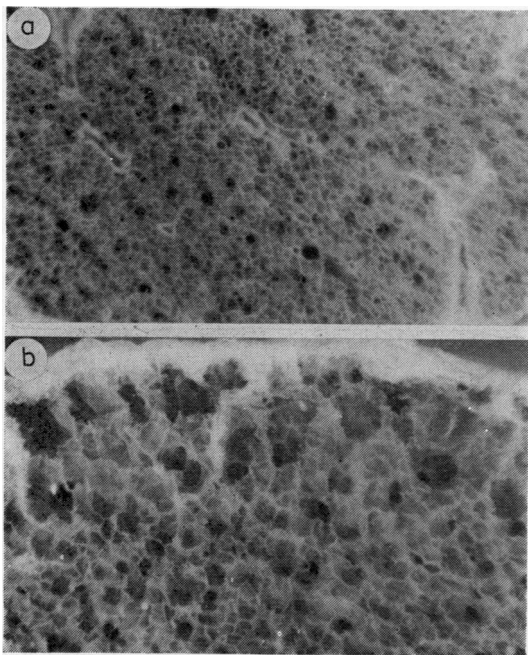


Fig 3 Patient 2. Upper part shows right lung with normal sized alveoli. Lower panel shows an area of destructive emphysema just deep to the pleura, and alveoli adjacent to obvious emphysema are too large (enlarged $\times 18$).

other slightly smaller. The method of preparation of the cases reported here (fixation by intra-bronchial distension with fixative to full inflation, removal of the distending force, and then examination of the lung some days later), however, results in lungs that are some 22–30% smaller than fixation at a standard transpulmonary pressure of 25–30 cm H₂O (2.5–3 kPa) (Heard, 1960; Thurlbeck, 1963). When allowance is made for this, it is apparent that lung volumes were restored to normal in these cases and the lungs of the first patient may have been larger than normal. Lung volume was restored equally to both lungs so that the ratio of right to left lung was normal.

In both cases there were fewer and larger alveoli on the ipsilateral side than on the contralateral side. In the first infant the total number of alveoli in the lung was grossly abnormal. Reports have indicated that the number of alveoli present at birth ranges from 10 to 70 million (Hieronymi, 1960, 1961; Dunnill, 1962b; Davies and Reid, 1970; Thurlbeck and Angus, 1975). The precise number expected at 8 months of age is uncertain but available data (Dunnill, 1962b; Davies and Reid, 1970; Thurlbeck and Angus, 1975) suggest that there should be about 80 to 100 million alveoli at this age, yet our patient had only 20 million alveoli. There were too few alveoli per unit volume, as predicted from the patient's age. In addition there was also obvious destructive enlargement in the acinus (emphysema). The situation in the second case is less clear. The sum of the number of alveoli in both lungs was normal, but there were more than twice as many alveoli in the contralateral lung than in the left lung. This raises the possibility of compensatory alveolar multiplication in the contralateral lung. Another way of expressing our results is as the number of alveoli per cm³ of lung. Under these circumstances, the second case has more alveoli per cm³ than predicted in the right lung and the left lung has fewer than predicted for the patient's age. If, however, allowance is made for the probable change in lung volume after distension, then the figures are only about 11% too high on the right side whereas there are too few on the left side. Alveolar surface area was grossly diminished, compared with that predicted from body length in the first patient, and was modestly reduced in the second patient, even allowing for lung volume changes.

The number of bronchioles in the lungs of the patients and three subjects with normal lungs is shown in table 2. Although several assumptions are made in this method of counting bronchioles, the number of bronchioles in the control subjects was within the range found in adults (Matsuba and Thurlbeck, 1971). The first patient had considerably fewer bronchioles than normal, and this change was more pronounced in the left than the

Table 2 Number of bronchioles in the two patients and three control subjects

Age	Patient 1		Patient 2		Subjects with normal lungs			
	8 months		5 years		6 months		6 years	
	L	R	L	R	L	L	R	L
No of bronchioles	3557	4326	8856	19 643	9588	20 180	14 263	10 120
Total	7883		28 499		20 400*	34 443		21 531*

*Extrapolated to both lungs by multiplying by 100/47.

right. He also had many fewer alveoli per bronchiole (1405 on the left and 3647 on the right) than normal adults, the control subjects in this study, or the second patient who had about 10 000 alveoli per bronchiole. The left lung of the second patient contained fewer bronchioles than any of the controls and adults previously studied. The right lung, by contrast, had a normal value.

The lungs in the two patients responded differently in the postnatal period with those of the first case being much more obviously abnormal. This may have been because this patient had more severely hypoplastic lungs to start with, since the degree of hypoplasia in congenital diaphragmatic hernia varies considerably (Butler and Claireaux, 1962). Alternatively, the stormy postoperative course and long period of mechanical ventilation, together with exposure to 100% oxygen for one week, may have caused further damage to the lung in this infant.

Limited functional data are available about the condition of the lungs after repair of diaphragmatic hernia, but all series indicate that abnormalities are present. The frequency of the abnormalities and their severity vary from report to report. Chatrath *et al* (1971) showed that the forced expiratory volume in one second (FEV₁) and the forced vital capacity (FVC) were significantly reduced in 14 children aged 6 to 12 years, after repair of their diaphragmatic hernias. Functional residual capacity (FRC), residual volume (RV), and total lung capacity (TLC) were not significantly different from controls, but tended to be larger. Their data are presented in full and an interesting analysis can be made. The authors provide observed FVC, RV, and TLC. The sum of FVC and RV is less than TLC in 13 of the 14 children and average 18% less. These data suggest that significant air trapping occurred during expiration in these children. It is also interesting that radiologically three of their 14 children were thought to have emphysema though the authors do not give the criteria for the radiological diagnosis of emphysema.

Reid and Hutcherson (1976) performed pulmonary function tests on nine subjects, aged 7–21 years, after repair of congenital diaphragmatic hernia and found that nearly all of them were abnormal. TLC and vital capacity were reduced, RV was increased, and the ratio of RV to TLC was increased in eight of the nine subjects. Lung perfusion scans showed diminished vascularity. Grotte *et al* (1977) studied 19 children, aged 8 to 15 years, after repair of diaphragmatic hernia and found that the mean values of FEV₁ and FEV₁/FVC were reduced. TLC and FRC were reduced,

but the ratio of RV/TLC was normal. They found that the diaphragm on the affected side moved only 60% as much as on the contralateral side.

Other reports have suggested that lung function is seldom obviously abnormal after repair of diaphragmatic hernia. Kerr (1977) studied 16 children, aged 7–18 years, and found that three had diminished peak flow rates, one a diminished forced expiratory volume in 0.75 of a second, and three had an abnormal phase III slope. FVC, thoracic gas volume (TGV), and the ratio of closing capacity to TLC were normal in all patients. Landau and others (1977) found rapid restoration of TGV and by 1 year of age TGV was normal in the 22 children they studied. Dynamic compliance was normal in all the children by age 6 months. Before this time, dynamic compliance was decreased in six infants, and in four of these TGV was increased. One child had low airway conductance. Wohl *et al* (1977) have made the most detailed study on patients aged from 6 to 18 years. They found normal conductance, maximum expiratory flow volume curves, normal points of isoflow, and normal lung volumes and diffusing capacity. FEV₁ was 89% of predicted and FVC was 80% of vital capacity. The most striking change was diminished blood flow to the affected side; ventilation per unit lung volume was also decreased but not so obviously. Radiologically, the diaphragm moved less and lung volume changed less between RV and TLC on the side of the hernia repair. The alterations in perfusion were explained on the basis of the observed anatomical deficit of vessels described by Kitagawa *et al* (1971). Several suggestions were made for the alteration in ventilation and volume change—diaphragmatic abnormality, gas trapping, or alterations in the pressure volume characteristics of the lung.

A considerable spectrum of pulmonary abnormality exists in diaphragmatic hernia and Berdon *et al* (1968) classified their patients into three groups—those with little if any pulmonary hypoplasia; severe, usually lethal pulmonary hypoplasia; and unilateral pulmonary hypoplasia with survival and later development of emphysema in the hypoplastic lung. They illustrated a case with similar radiological findings to our second case. Both our cases resemble their third category with the onset of respiratory distress immediately after birth. The first infant had grossly abnormal lung structure, and one would anticipate considerable alterations in lung function. As pointed out above, however, the role of oxygen toxicity and severe illness in the genesis of the lung lesions is uncertain. The changes in the second case were relatively mild,

and functional alterations would probably have been minimal. The difference in alveolar number and size between the sides, however, suggest that alterations in ventilation per unit volume, diaphragmatic movement, and in vital capacity on the affected side could be caused by structural alterations rather than inadequate diaphragm function.

References

- Areechon, W, and Reid, L (1963). Hypoplasia of lung with congenital diaphragmatic hernia. *British Medical Journal*, **1**, 230–233.
- Berdon, W E, Baker, D H, and Amoury, R (1968). The role of pulmonary hypoplasia in the prognosis of newborn infants with diaphragmatic hernia and eventration. *American Journal of Roentgenology and Radium Therapy*, **103**, 413–421.
- Boyden, E A (1972). The structure of compressed lungs in congenital diaphragmatic hernia. *American Journal of Anatomy*, **134**, 497–507.
- Butler, N, and Claireaux, A E (1962). Congenital diaphragmatic hernia as a cause of perinatal mortality. *Lancet*, **1**, 659–663.
- Chatrath, R R, El Shafie, M, and Jones, R S L (1971). Fate of hypoplastic lungs after repair of congenital diaphragmatic hernia. *Archives of Diseases of Childhood*, **46**, 633–635.
- Davies, G, and Reid, L (1970). Growth of the alveoli and pulmonary arteries in childhood. *Thorax*, **25**, 669–681.
- Dunnill, M S (1962a). Quantitative methods in the study of pulmonary pathology. *Thorax*, **17**, 320–328.
- Dunnill, M S (1962b). Postnatal growth of the lung. *Thorax*, **17**, 329–333.
- Dunnill, M S (1964). Evaluation of a simple method of sampling the lung for quantitative histological analysis. *Thorax*, **19**, 443–448.
- Grotte, G, Bjure, J, Bratteby, L (1977). Posterolateral diaphragmatic hernia—long term results. *Progress in Pediatric Surgery*, **10**, 35–44.
- Heard, B F (1960). Pathology of pulmonary emphysema: Methods of study. *American Review of Respiratory Disease*, **82**, 792–799.
- Hieronymi, G (1960). Veranderungen der lungenstruktur in verschiedenen lebensalteren. *Verhandlungen der Deutschen Gesellschaft für Pathologie*, **44**, 129–130.
- Hieronymi, G (1961). Über den durch das alter bedingten formwandel menschlicher lungen. *Ergebnisse der allgemeinen Pathologie und Pathologischen Anatomie*, **41**, 1–62.
- Kerr, A A (1977). Lung function in children after repair of congenital diaphragmatic hernia. *Archives of Diseases in Childhood*, **52**, 902–903.
- Kitagawa, M, Hislop, A, Boyden, E A, and Reid, L (1971). Lung hypoplasia in congenital diaphragmatic hernia. A quantitative study of airway, artery, and alveolar development. *British Journal of Surgery*, **58**, 342–346.
- Landau, L I, Phelan, P D, Gillam, G L, Coombs, E, and Noblett, H R (1977). Respiratory function after repair of congenital diaphragmatic hernia. *Archives of Disease in Childhood*, **52**, 282–286.
- Matsuba, K, and Thurlbeck, W M (1971). The number and dimensions of small airways in non-emphysematous lungs. *American Review of Respiratory Diseases*, **104**, 516–524.
- Reid, I S, and Hutcherson, R J (1976). Long-term follow-up of patients with congenital diaphragmatic hernia. *Journal of Pediatric Surgery*, **11**, 939–942.
- Thurlbeck, W M (1963). Incidence of pulmonary emphysema with observations on the relative incidence and spatial distribution of various types of emphysema. *American Review of Respiratory Diseases*, **87**, 206–215.
- Thurlbeck, W M, and Angus, E G (1975). Growth and aging of the normal human lung. *Chest*, **67**, 35–75.
- Weibel, E R (1963). *Morphometry of the Human Lung*. Academic Press, New York.
- Wohl, M E B, Griscom, N T, Strieder, D J, Schuster, S R, Treves, S, and Zwerdling, R G (1977). The lung following repair of congenital diaphragmatic hernia. *Journal of Pediatrics*, **90**, 405–414.

Requests for reprints to: Dr W M Thurlbeck, Department of Pathology, Health Sciences Centre, 700 William Avenue, Winnipeg, Manitoba, Canada.