

Bronchography in chronic bronchitis

A. G. OGILVIE

Wood Cottage, Thropton, Morpeth, Northumberland

Ogilvie, A. G. (1975). *Thorax*, 30, 631–635. **Bronchography in chronic bronchitis.** Bronchograms were made in eight men, chosen on clinical grounds as representative of three grades of severity in a series of 67 male bronchitics studied prospectively over a period of 10 years, with the object of ascertaining the anatomical condition at the end of this period.

In the stationary group the bronchograms showed only a mild mucous reaction, and peripheral filling was generally good. In the slowly progressive group, mucous obstruction was evident and fairly widespread, and organic changes were present, though not widespread or severe. In the progressive group, both mucous obstruction and organic change were widespread.

It was noted that when both mucous obstruction and organic change were observed the upper lobes were seen to be relatively normal with the exception of the progressive cases in which all changes were more severe.

The bronchographic abnormalities were found to be closely correlated with the grades of clinical severity.

The purpose of this study was to determine the anatomical state of the bronchial tree in patients with different grades of severity of chronic bronchitis.

MATERIAL AND METHODS

Diagnosis was based on the definition used in the Newcastle Survey in 1957 (Ogilvie and Newell) as follows: '... Chronic bronchitis is recognized as a long-standing condition, the essential features of which are cough with sputum, persistent throughout the winter or throughout the year, in the absence of other causative respiratory disease. A minimum duration of two years is essential for its recognition'.

The 67 men had been divided into groups prior to bronchography according to their progress during the period of observation as follows:

- A *Stationary or very slowly progressive*
 - Acute infective exacerbations mild or moderate
 - Ventilatory decline slight
 - No change in dyspnoea grade from grade 0
 - No change in occupation for reasons of health
- B *Slowly progressive*
 - Acute infective exacerbations mild or moderate
 - Ventilatory decline moderate
 - No change or moderate change in dyspnoea grade
 - No involuntary change in occupation for health reasons, though a man might change his occupation if he thought it was affecting his health
- C *Progressive*
 - Acute infective exacerbations moderate or severe,

though more usually severe
Ventilatory decline generally considerable
Dyspnoea change marked

Occupational change for reasons of health when work heavy or very active (but 10 men out of 30 are unable to work at all)

The smoking habits of the patients in these three groups are shown in Table I and the age, changes in FEV₁, sputum production, and dyspnoea grading in Table II.

All the men had been known for at least 10 years, and a number had offered to cooperate in any further investigation which might be required. It was out of this number that three patients from each clinical group were selected for bronchography. The details of the procedure were explained to each man, and all were told that the object was to determine the structural changes, if any, which had been produced by bronchitis over the years.

All the bronchograms were made in the Department of Radiology of the Royal Victoria Infirmary, Newcastle upon Tyne.

The right side only was filled. Gregg and Trapnell (1969) found that the correlation when both sides were filled was generally good enough to justify conclusions from unilateral bronchograms.

RESULTS

The bronchograms were grouped according to the clinical grading already described, and illustrations

TABLE I
SMOKING HABITS

Group	Cigarette Smoking on Entry				
	Non-Smoker	Under 25 Daily ¹	Over 25 Daily ¹	(Stopped)	Total
A Stationary	1	8	6	(3)	15
B Slowly progressive	1	20	1	(2)	32
C Progressive	2	22	6	(12)	20
Totals	4	50	13	(17)	67

Note A smoker who 'stopped' must have maintained this until the end of the 10-year period in order to be included. Minimum of 1 year recognized.
¹Greatest amount ever smoked regularly.

TABLE II

Group	Average Age on Entry	Ventilatory Capacity (FEV ₁)					Sputum Production	Dyspnoea	
		Average 1961-62	Average 1970-71	Average Decline	Range 1961-62	Range 1970-71		Grade	No.
A (15 men) Stationary or very slowly progressive	44.4	2.26 l.	1.80 l.	20%	2.68-1.61 l.	2.67-1.16 l.	All cases mucoid	0 throughout	15
B (22 men) Slowly progressive	44.3	1.63 l.	1.13 l.	30%	2.83-1.48 l.	2.63-0.61 l.	32% mucopurulent	2 throughout Moved from 1 to 2	9 13
C (30 men) Progressive	48.8	1.96 l.	1.24 l.	36%	2.66-1.23 l.	1.96-0.56 l.	40% mucopurulent	3 throughout Moved from 0 to 3 Moved from 2 to 3	9 4 17

Note¹ (1) FEV₁ figures are, for each year given, an average of five observations at intervals during that year. Each observation is the best of six attempts. Ventilatory decline was assessed by comparison of the average of the five observations made in the year 1961-62 with the average for the year 1970-71 in each case. The average decline for each group was then shown as a percentage change.

(2) All cases with less than 20% of sputum specimens mucopurulent were labelled mucoid; those with more than 20% were labelled mucopurulent.

from each group, together with a normal bronchogram for comparison, are shown (Figs 1-9).

STATIONARY GROUP (JB, JH, JF) In these cases the bronchogram was almost normal, with generally good and even filling to the millimetre pattern, except

that in the case of JB, a considerable excess of mucus caused some bronchial blockage, no doubt due to suction.

There were also a few 'broken boughs', indicating mucous obstruction of an occasional branch.

The absence of a few side branches of the medial

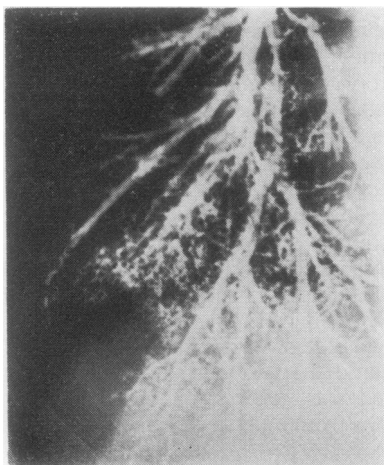


FIG. 1. (JB) Filling to millimetre pattern in most areas but a considerable area laterally not filled. No structural change shown, so this is probably due to suction of mucus downwards.

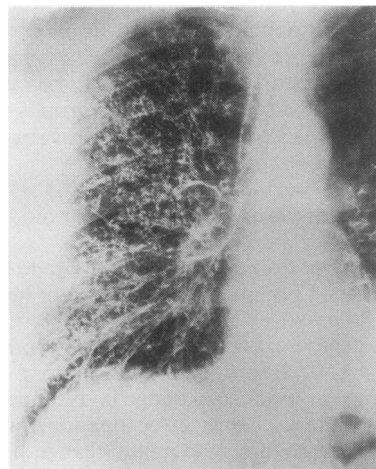


FIG. 2. (JH) A normal bronchogram, filled to millimetre pattern, except in part of middle lobe and the posterior part of the upper lobe.

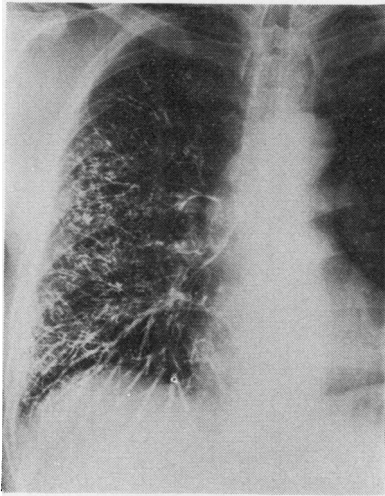


FIG. 3. (JF) No structural changes. Poor filling of basal bronchi perhaps due to excess of mucus. Also absence of side branches due either to mucus or to lack of contrast medium in these branches.

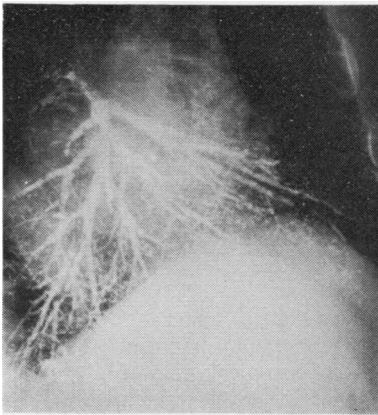


FIG. 4. (WS) The basal bronchi show absence of side branches, some dilatations, 'broken bough' endings, and at least one tapering ending.

basal bronchi in JF was probably due to a slight insufficiency of contrast medium or to mucous obstruction.

SLOWLY PROGRESSIVE GROUP (WS, RA, AT) These bronchograms showed areas of defective peripheral filling with some poor filling of side branches and 'broken bough' endings.

Occasional tapering termination in the middle and

basal bronchi and also some dilatation and deformed endings are noted.

The upper lobes showed normal filling in general.

There is thus evidence of a greater excess of mucus than in the stationary group A, and also evidence of structural change.

PROGRESSIVE GROUP (JGR, JL) In these bronchograms, regions in all lobes show poor peripheral filling, and bronchi with tapering ends, dilatations, and loss of side branches. 'Mimosa' patterns, indicating peripheral destruction, are also evident. There is also considerable excess of mucus.

LOCALIZATION OF THE BRONCHOGRAPHIC ABNORMALITIES A striking feature of all bronchograms

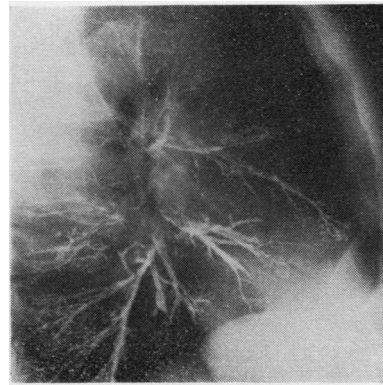


FIG. 5. (RA) Middle lobe: 'Broken bough' endings. Dilatation and deformed ending of one branch. Lower lobe: Dilatation and deformed occlusion in anterior basal segment. Poor filling on side branches in posterior basal segment. 'Broken boughs'.

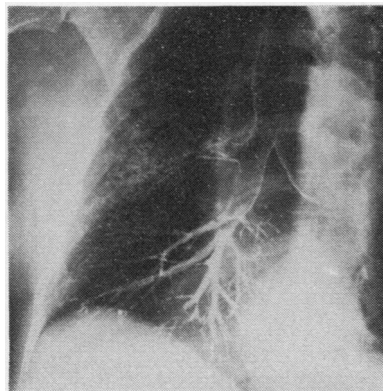


FIG. 6. (AT) Dilated mucous ducts. Upper lobe: Normal filling. Middle and lower lobes: Filling incomplete. Loss of side branches—'broken boughs'. Tapering endings.

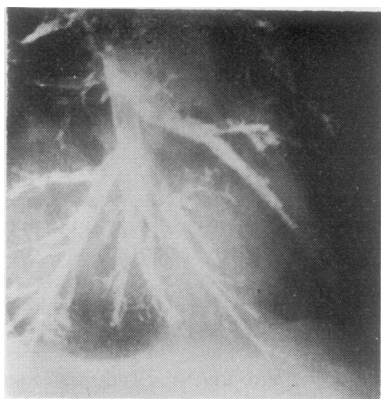


FIG. 7. (JL) Upper lobe: *Poor filling*. Middle lobe: *'Broken boughs'*. *Loss of side branches extensive*. *Dilatations*. Lower lobe: *Very few side branches*. *Pooling posteriorly*. *Tapering endings posteriorly*.

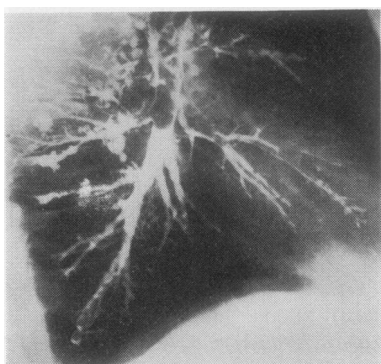


FIG. 8. (JGR) Upper lobe: *'Mimosa pattern' dilatations*. Middle lobe: *'Broken boughs'*. *Excess of mucus*. Lower lobe: *Excess of mucus*. *'Broken bough'*. *Loss of side branches*. *Tapering endings*. *Organic occlusions and dilatations*.

showing abnormalities was the relatively normal upper lobes.

In only two cases was the upper lobe seen to be damaged, and these men were the most severely affected in the series (JGR).

In the middle and lower lobes the abnormalities were scattered, varying in severity from lobe to lobe, from segment to segment, and from area to area within segments.

DISCUSSION

The purpose of this study was to ascertain the anatomical condition of the bronchial tree in a representative sample of a series of 67 male bronchitics studied prospectively over a period of 10 years.

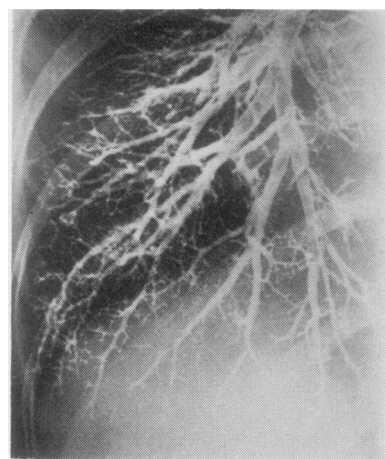


FIG. 9. *Normal bronchogram for comparison.*

Three men were chosen from each of three groups, graded according to their progress during this period, and bronchograms of the right lung were made in each case. It must be emphasized that the clinical grading was made before the bronchograms, which nevertheless showed a close correlation.

From the evidence presented it seems clear that mild mucous reaction is the initial phase of the disease, and that men may maintain this for a considerable time, and perhaps even permanently.

Only when this mucus reaction becomes greater is structural damage to be found. This, however, is local and scattered; certain segments or regions may be moderately or severely damaged, while other parts of the lung may be relatively normal or show mucous excess only.

It was noted that the upper lobes were usually free of any change except in the progressive cases. If this were a usual occurrence, one would expect a significant difference in ventilatory function in cases of chronic bronchitis between the upper and lower lobes. Few references to regional ventilation in chronic bronchitis are to be found, but Anthonisen *et al.* (1968) reported in a series of cases that the upper regions showed significantly better function than the lower.

It is of interest to compare the results in the present study with those obtained by Gregg and Trapnell (1969), who studied bronchitics at an even 'earlier' phase than those reported here. They included all men who had at any time noted breathlessness due to bronchitis, and on bronchography found only incomplete peripheral filling and occasional 'loss of parallelism', suggesting mucous reaction as the only abnormality. It is evident that in their cases the

mucous reaction was not severe enough to be associated with organic changes and it may be that in some of these cases such changes may never occur.

In conclusion, it is suggested that clinical assessment in chronic bronchitis may give some indication of the anatomical changes in the bronchial tree.

My grateful thanks are due to Dr. Charles Warrick, director of the Department of Radiology in the Royal Victoria Infirmary, Newcastle upon Tyne, and his staff for their help in carrying out bronchography in these cases.

It is a pleasure to thank Professor Lynne Reid for her advice, and Dr. George Simon both for advice and for the prints which comprise the illustrations. They are, of course, not responsible for the opinions expressed.

REFERENCES

- Anthonisen, N. R., Bass, H., Oriol, A., Place, R. E. G., and Bates, D. V. (1968). Regional lung function in patients with chronic bronchitis. *Clinical Science*, **35**, 495.
- Gregg, I. and Trapnell, D. H. (1969). The bronchographic appearances of early chronic bronchitis. *British Journal of Radiology*, **42**, 132.
- Ogilvie, A. G. and Newell, D. J. (1957). *Chronic Bronchitis in Newcastle upon Tyne*, p. 13. Livingstone, Edinburgh and London.
- Ogilvie, A. G., Strang, C., Leggat, P. O., and Newell, D. J. (1973). *A Ten-Year Prospective Study of Chronic Bronchitis in the North-East of England*. Churchill-Livingstone, Edinburgh and London.

Requests for reprints to: Dr. A. G. Ogilvie, Wood Cottage, Thropton, Morpeth, Northumberland.

APPENDIX

BRONCHOGRAPHIC TERMS MENTIONED IN TEXT

(after Reid (1955))

Broken bough: A 'snapped off' appearance at the 5th generation or more peripherally, with no filling beyond. The termination is flat or perhaps concave in the proximal direction. This is due to functional occlusion of the bronchus by mucus.

Tapering: Ending of a bronchus, and also a *bulbous termination*, indicating organic obstruction.

Pooling: A dilated bronchiole, with or without radiating 'spikes' due to branches beyond the pool—indicative of organic and structural changes.

Mimosa pattern: An appearance resembling a 'pool' but with a wavy outline and some mottling—indicative of dilatation proximal to a destroyed peripheral bronchiole.

REFERENCE

- Reid, L. M. (1955). Correlation of certain bronchographic abnormalities seen in chronic bronchitis with the pathological changes. *Thorax*, **10**, 199.