

Oesophageal motor dysfunction in patients with diverticula of the mid-thoracic oesophagus

MICHAEL D. KAYE

Departments of Medicine, University of Colorado Medical Center, and Veterans Administration Hospital, Denver, Colorado, USA

Kaye, M. D. (1974). *Thorax*, 29, 666–672. **Oesophageal motor dysfunction in patients with diverticula of the mid-thoracic oesophagus.** Oesophageal motor function was assessed by a perfused catheter manometric system in a consecutive series of 12 patients with diverticula located in the mid-thoracic oesophagus. In only one of the 12 patients was there radiographic evidence of prior tuberculous infection. Manometry revealed diffuse oesophageal spasm in five patients and vigorous achalasia in one. In the other six patients there was a definite but unclassifiable abnormality of motility, of moderate degree in four and mild in two. 'Traction' is of less importance in the pathogenesis of mid-oesophageal diverticula than is generally supposed. An underlying disorder of oesophageal motor function should be suspected in patients with this type of lesion.

Pharyngo-oesophageal (Zenker's) and epiphrenic diverticula are generally ascribed to 'pulsion'—that is to say, are considered to arise as a consequence of abnormal forces acting from within the lumen upon an area of relative weakness. The primary disorder in pharyngo-oesophageal diverticula has been variously described as a hypertensive upper oesophageal (cricopharyngeal) sphincter (Lahey, 1946), cricopharyngeal achalasia (Jackson and Shallow, 1926; Asherson, 1950; Sutherland, 1962), and an incoordination between the hypopharyngeal pressure wave and cricopharyngeal relaxation (Ardran and Kemp, 1961; Lund, 1965; Ellis, Schlegel, Lynch, and Payne, 1969). Although there are few reports of oesophageal manometric studies in epiphrenic diverticula, which, by the strictest definition, are adjacent to the diaphragm and arise from the terminal four centimetres of the thoracic oesophagus (Brombart, 1961), the association of this lesion with achalasia (Goodman and Parnes, 1952); Habein, Moersch, and Kirklin, 1956; Allen and Clagett, 1965; Garcia, Bengochen, and Wooler, 1972; Bruggeman and Seaman, 1973), oesophageal spasm (Harrington, 1949; Goodman and Parnes, 1952; Habein *et al.*, 1956; Allen and Clagett, 1965; Garcia *et al.*, 1972; Bruggeman and Seaman, 1973), and oesophageal muscular hypertrophy (Kay, 1953; Effler, Barr, and Groves, 1959) is well recognized. By contrast, outpouchings in the mid-portion of the oesophagus are generally

termed 'traction' diverticula. This designation stems from the early descriptions of Mondière (1833) and Rokitsky (1840) and from the studies of Kragh (1922), who was able to demonstrate, in a substantial proportion of necropsy specimens, attachment of a mid-oesophageal diverticulum to mediastinal lymph nodes which almost always showed evidence of active or prior tuberculous infection. Gradually, however, the concept of 'traction-pulsion' was applied to mid-oesophageal diverticula (Oekonomides, 1882; Barrett, 1933; Johnstone, 1949; Postlethwait and Sealy, 1961), and in relatively recent years sporadic reports of 'pulsion' diverticula of the mid-oesophagus have appeared (Harrington, 1949; Maier, 1953; Cross, Johnson, and Gerein, 1961; Gahagan, 1962; Belsey, 1963; Law and Overstreet, 1964). However, systematic studies of oesophageal motor function in a series of patients with diverticula in this location have not been described.

This report documents the findings in a consecutive series of 12 patients with diverticula of the mid-thoracic oesophagus. The emphasis is upon oesophageal manometry, since this provides the most detailed information about oesophageal motor function.

PATIENTS

There were six men and six women. Ages ranged from 38 to 76, with a mean of 61.3 years. Pertinent clinical data are shown in the Table. Of the 12 patients, only

T A B L E
PERTINENT CLINICAL DATA

	Age/Sex	Dysphagia	Substernal Pain	Heartburn and/or Sour Reflux	Associated Disease
HS	38 F	+	+	+	Cerebrovascular and coronary artery disease Alcoholism, osteoporosis
HBa	46 F	—	+	+	
JL	57 M	+	+	—	Rheumatoid arthritis Diabetes mellitus
VS	58 F	+	+	—	
JB	60 M	—	—	—	Diverticulosis coli, coronary artery disease Duodenal diverticulum
HH	61 F	+	—	+	
JK	62 F	+	+	—	Diverticulosis coli, coronary artery disease Coronary artery disease
RW	66 M	+	+	—	
HBr	66 M	+	+	+	Diverticulosis coli, duodenal diverticulum, coronary artery disease
CB	70 M	+	+	+	
AS	72 F	—	—	—	
JP	76 M	+	—	—	

one (JB) was free of oesophageal symptoms. However, in three others (VS, AS and JP) the presence of such symptoms became apparent only on close questioning after an oesophageal diverticulum had been demonstrated by radiography. Hence, the oesophageal diverticulum was an incidental radiological finding in four of the 12 patients. No other disease was seen with sufficient frequency to be clearly associated with oesophageal diverticulum, though coronary artery

disease, diverticulosis coli, and duodenal diverticulum were present in, respectively, four, two, and two patients.

Representative radiographic appearances of the oesophageal diverticula are shown in Fig. 1 for 11 of the 12 patients (poor quality prevented adequate reproduction of JL's radiographs). In eight patients, the diverticulum was located at, or close to, the interbronchial level. In two (VS and RW), it was at the junc-

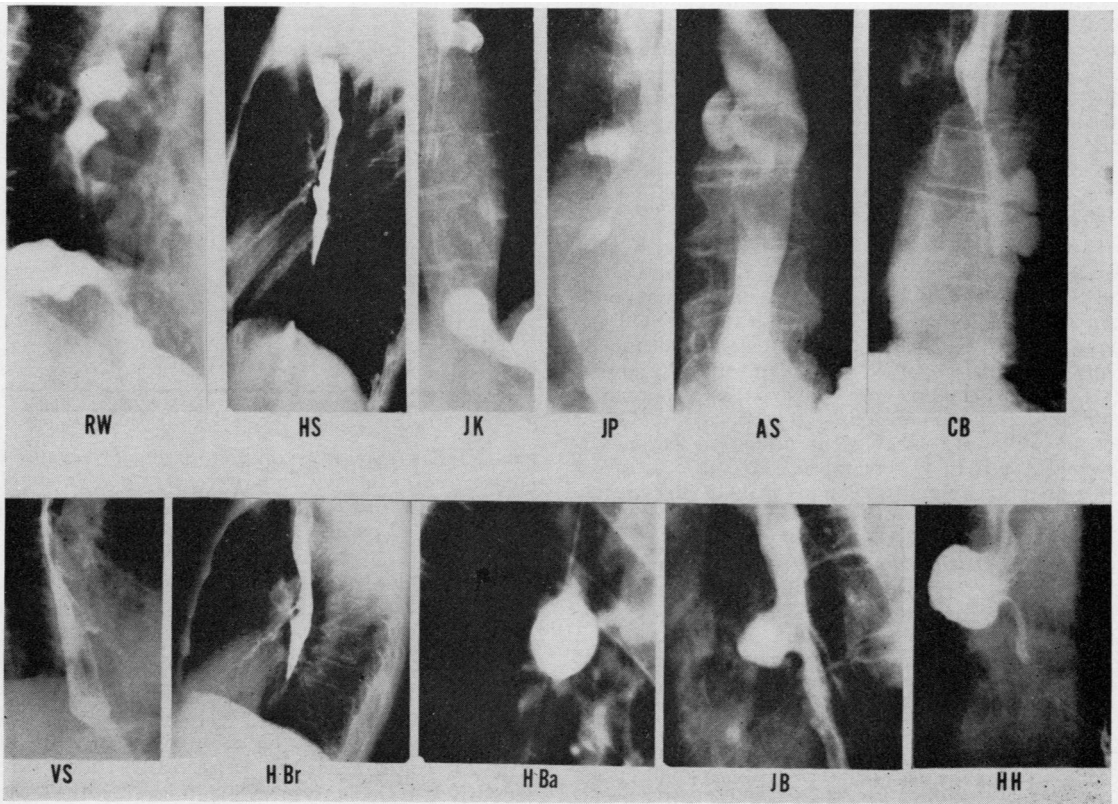


FIG. 1. Representative radiographs from 11 of the 12 patients (radiographs of JL inadequate for reproduction)

tion of middle and distal thirds of the oesophagus, while in two others (CB and HH) diverticula (multiple in CB) were within the distal third, though still not sufficiently close to the diaphragm to be strictly classified as epiphrenic. Disordered motility, manifest as impaired emptying in HBa and HS, and as curling (Schatzki, 1933) in RW and JK, was noted by the radiologist in only four of the 12 patients.

Manometric studies were performed in all patients.

MANOMETRIC METHODS

Patients were studied supine after an overnight fast, by means of three polyvinyl catheters (ID and OD, 0.044 and 0.065 inches respectively), cemented together with side openings spaced at 5 cm intervals. Each catheter was perfused with water at a rate of 1 ml/min by constant rate infusion pump (Harvard Apparatus Co. Inc.). Pressures were registered by means of Stratham P23 De transducers connected to a Gilson Macropolygraph recorder. Respiration was recorded by a bellows placed around the upper abdomen and connected to a fourth transducer, while swallowing was monitored either by electromyograph or by an additional bellows placed around the neck over the larynx.

For assessment of the lower oesophageal sphincter (LOS) each sensor was withdrawn from stomach to oesophagus 0.5 cm at a time, the assembly being maintained at each level until a stable baseline pressure had been recorded. Then, as the assembly was withdrawn towards the mouth in 1 cm steps, the response to at least one 'dry' swallow was observed at each level. Finally, one or more sensors were withdrawn, 0.5 cm at a time, through the upper oesophageal sphincter into the hypopharynx.

MANOMETRIC DEFINITIONS *Resting LOS pressure* was measured in end-expiration with gastric baseline pressures as zero reference. *Relaxation* of the LOS was considered to be abnormal if the lowest residual pressure following a swallow was greater than 10 mmHg.

LOS contractions were classified as abnormal if they occurred *spontaneously* (that is, in the absence of a swallow), if they were prolonged beyond 30 seconds, or if they were repetitive (that is to say, if two or more discrete elevations in LOS pressure occurred without relation to the respiratory cycle, in response to a single swallow).

The *oesophageal body* was considered to extend between the lower margin of the upper oesophageal sphincter and the upper margin of the lower oesophageal sphincter.

Spontaneous oesophageal motor activity was defined as (1) discrete contractions in the absence of a preceding swallow, and (2) sustained elevations in oesophageal baseline pressure.

Post-deglutitive oesophageal contractions were considered to be *prolonged* if they lasted for more than 10 seconds; *repetitive* if at least two easily discernible pressure elevations occurred in response to a single

swallow; *simultaneous* if the onset of contraction occurred within 0.4 seconds at two points 5 cm apart; and as *delayed* in propagation if the onset of contractions at points 5 cm apart was separated by 3 seconds or more.

Oesophageal contraction pressures are not included in these manometric assessments, since amplitude is measured accurately only if very rapid infusion rates are used (Pope, 1967; Hollis and Castell, 1972).

MANOMETRIC FINDINGS Maximum resting pressures ranged between 7 and 35 mmHg (mean 18.4). In the patients with symptoms of gastro-oesophageal reflux, pressures ranged between 11 and 23 mmHg and were not obviously different from those in patients without such symptoms (range 7–35 mmHg).

Abnormalities of sphincteric relaxation were observed in seven of the 12 patients (HS, VS, CB, HH, JB, JK, JL) and in five, sphincteric contraction was disturbed with spontaneous contractions in two (AS, JL) and repetitive and/or prolonged post-deglutitive contractions in three (HS, VS, HH).

OESOPHAGEAL BODY Prolonged and repetitive contractions were very common in this group of patients (Fig. 2). The frequency of prolonged

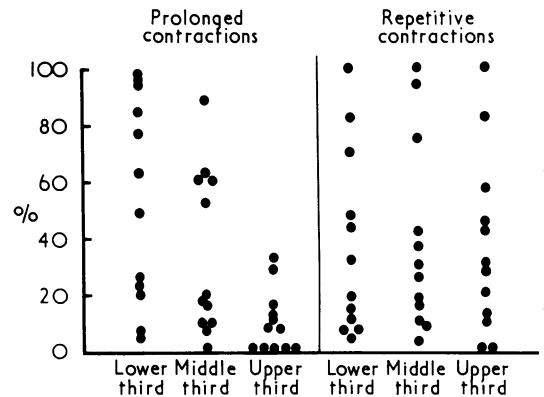


FIG. 2. The frequency of prolonged and repetitive contractions, expressed as a percentage, for proximal, middle, and distal thirds of the oesophageal body, in each of the 12 patients.

post-deglutitive contractions increased progressively from proximal to distal oesophagus, so that more than 20% of all contractions in upper, middle, and distal thirds were prolonged in, respectively, two, six, and 10 of the 12 patients. Repetitive contractions were frequent throughout the oesophageal body. Thus, in seven patients, at least 20% of all post-deglutitive contractions were repetitive, irrespective of axial level within the oesophagus.

Forty per cent or more of all post-deglutitive contractions recorded from the distal half of the oesophagus were simultaneous in 10 patients (Fig. 3). In contrast, the majority of contractions in the

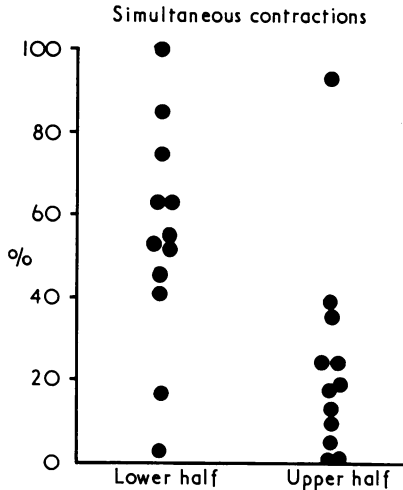


FIG. 3. The frequency of simultaneous contractions in upper and lower halves of the oesophageal body, for each of the 12 patients.

upper oesophagus were peristaltic, in all but one patient, who was judged to have 'vigorous' achalasia (Sanderson, Ellis, Schlegel, and Olsen, 1967).

Abnormal spontaneous (that is, unrelated to deglutition) motor activity in the oesophageal body was observed in nine patients. This was manifest as discrete segmental contractions in seven patients (HS, VS, RW, CB, HH, HBr, JK) and as spasmodic elevations in oesophageal baseline pressure in five (HS, VS, HH, JB, JL). The oesophageal response to mecholyl, studied in two patients, was positive in HS (marked elevation in oesophageal baseline pressure accompanied by substernal pain) and negative in RW.

The upper oesophageal sphincter was normal in all patients.

Disturbances in oesophageal motor function often defy precise classification. However, one patient (HS) had vigorous achalasia (Fig. 4), and five (HH, JK, JL, RW, VS) had the classical manometric features of diffuse oesophageal spasm (Creamer, Donoghue, and Code, 1958; Fig. 5). Motility was abnormal in the remaining six patients also, but the patterns seen did not conform to the strict, and perhaps undesirably rigid (Hogan, Caffisch, and Winship 1969; Kaye, 1973), classifications that are currently fashionable. In

these six patients, the degree of abnormality was moderate in four (HBa, HBr, AS, CB) and mild in two (JB, JP).

DISCUSSION

The widely accepted view that mid-oesophageal diverticula arise purely as a consequence of traction derives from the early observations of such authorities as Mondière (1833) and Rokitansky (1840), and from Kragh's detailed pathological studies, which were carried out at a time when tuberculous infection was far commoner than it is today (Kragh, 1922). Although the possibility that oesophageal motor dysfunction may be pathogenetically important is occasionally acknowledged (d'Abreu, 1949; Cornell, 1956), systematic manometric studies in patients with diverticula of the mid-thoracic oesophagus have not been reported previously.

In this series of 12 patients, a gross and classifiable disturbance of motor function was present in six (diffuse spasm in five, and vigorous achalasia in one) while in four others, there was a moderately severe abnormality which defied rigid classification. It would appear, therefore, that significant oesophageal motor dysfunction is associated frequently with this type of diverticulum. Although this group of patients was, inevitably, selected, it should be stressed that throughout the period of study a concerted effort was made to examine by manometry all patients found to have mid-oesophageal diverticula, whatever the nature of the patients' symptoms and modes of presentation. And indeed, the diverticulum was an incidental radiological finding in four patients, one of whom had no oesophageal symptoms, and three of whose oesophageal symptoms were so minor that they were discovered only after the diverticulum had been demonstrated radiologically.

Soergel, Zboralske, and Amberg (1964) reported disturbed oesophageal motor function—'presbyesophagus'—in a large proportion of non-agenarians, many of whom had overt abnormalities of the central and/or peripheral nervous systems. The rather high average age (61.3) in this group of patients with diverticula raises the possibility that the observed abnormalities might be related to age, at least in some.

Against this, however, the oldest patient was only 76, and more importantly, a recent study (Hollis and Castell, 1974) in truly healthy elderly men (aged 70–90) indicates that the only age-related change in oesophageal motor function is a diminution in the amplitude of post-deglutitive

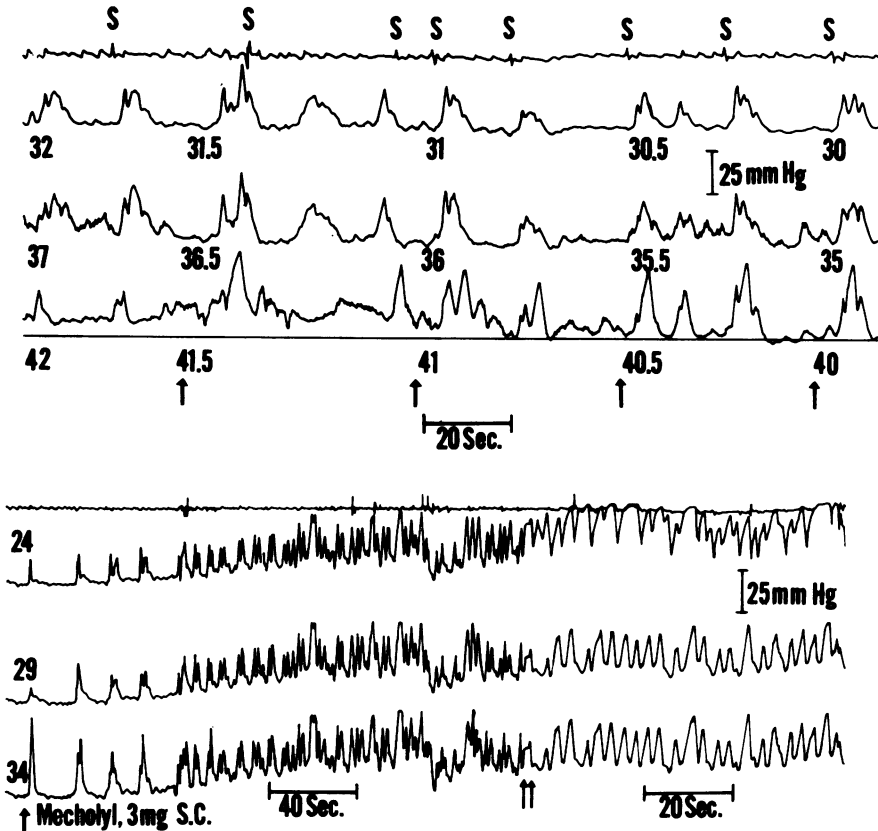


FIG. 4. Patient HS. Vigorous achalasia. For each panel, upper trace is a pneumograph (inspiration shown as downward deflection), while the other three traces are pressure recordings.

S represents dry and WS wet swallow; numbers indicate distances in centimetres from the incisors; and arrows indicate points at which the recording assembly was withdrawn 0.5 cm proximally.

The continuous horizontal line (lower tracing, upper panel, recording open in LOS) represents gastric end-expiratory baseline pressure. Contractions in response to swallowing are repetitive and invariably simultaneous. Relaxation of the LOS is absent or incomplete.

In the lower panel, the three pressure-transmitting openings are all located within the oesophageal body. Shortly after the subcutaneous injection of mecholyl (methacholine chloride) there is a striking elevation in pressure at all levels. This was accompanied by substernal pain.

The paper speed was altered at the point marked by two upward-pointing arrows.

oesophageal contractions, a feature that was conspicuously absent in the patients here reported.

Only one patient (JK) showed any radiographic evidence of tuberculosis, manifest as small scattered calcific densities in the left upper zone. One other (JB) gave a history of tuberculosis in childhood, but his chest radiograph was normal. However, in eight of these 12 patients the diverticulum

was located immediately distal to the tracheal bifurcation, and thus at the site classically associated with 'traction' between the oesophagus and healing mediastinal lymph nodes.

Since tuberculous adenitis cannot be implicated as a major factor in the causation of these lesions, the question arises as to what other factors may determine the site at which mid-oesophageal

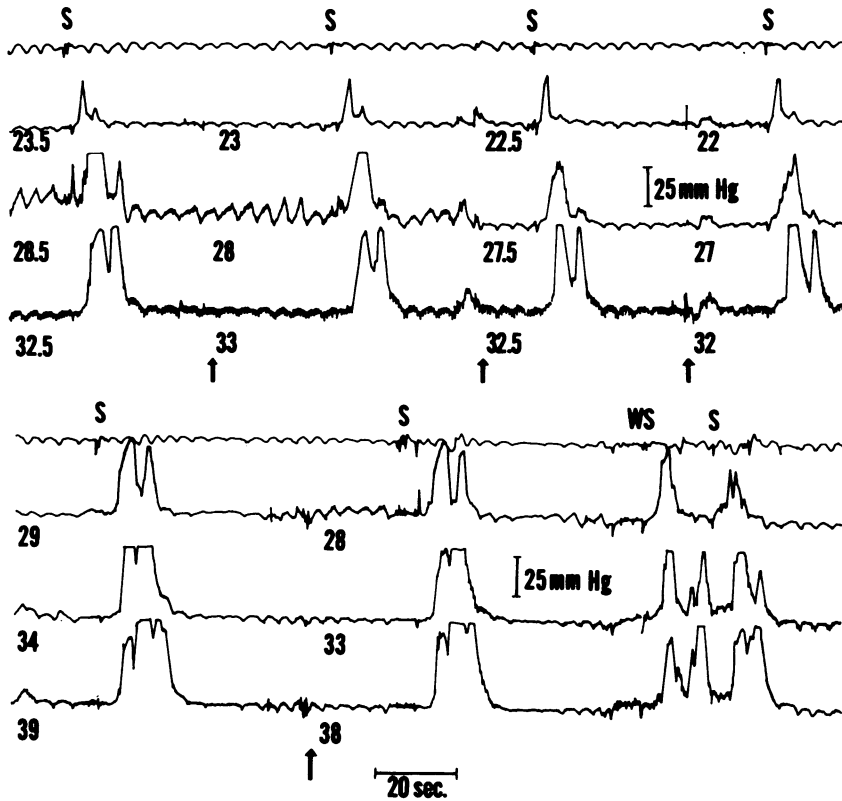


FIG. 5. Patient JL. Diffuse spasm. Notations are as in Figure 4. Figure shows two portions of motility tracing, one (upper panel) from proximal oesophagus and the other (lower panel) from distal oesophagus.

In the distal oesophagus contractions are nonpropulsive, prolonged, and repetitive. The abnormality is less striking proximally, contractions being normally propagated along the upper few centimetres of the oesophagus.

diverticula form. One attractive possibility (Cross *et al.*, 1961) implicates congenital attachment between oesophagus and trachea due to a failure of complete separation during embryological development. This hypothesis is unproven. Moreover, as Le Count (1915) pointed out, mid-oesophageal diverticula are not always attached to mediastinal structures. Whatever the factors responsible for their peculiar location, the chief purpose of this report is to emphasize the frequency with which these diverticula, like those situated more proximally and more distally, are associated with oesophageal motor dysfunction.

These studies were supported in part by grant No. AM 15952 from the National Institutes of Health, Bethesda, Maryland.

The expert help of J. Philip Showalter is gratefully acknowledged.

This work was presented in part at the V World Congress of Gastroenterology, Mexico City, October 1974.

REFERENCES

Allen, T. H. and Clagett, O. T. (1965). Changing concepts in the surgical treatment of pulsion diverticular of the lower esophagus. *Journal of Thoracic and Cardiovascular Surgery*, **50**, 455.
 Ardran, G. M. and Kemp, F. H. (1961). The radiography of the lower lateral food channels. *Journal of Laryngology and Otology*, **75**, 358.
 Asherson, N. (1950). Achalasia of the cricopharyngeal sphincter: record of cases, with profile pharyngograms. *Journal of Laryngology and Otology*, **64**, 747.
 Barrett, N. R. (1933). Diverticula of the thoracic oesophagus. *Lancet*, **1**, 1009.

- Belsey, R. (1963). Functional disease of the oesophagus. *Postgraduate Medical Journal*, **39**, 290.
- Brombart, M. (1961). *Clinical Radiology of the Oesophagus*, p. 35. Wright, Bristol.
- Bruggeman, L. L. and Seaman, W. B. (1973). Epiphrenic diverticula: an analysis of 80 cases. *American Journal of Roentgenology, Radium Therapy and Nuclear Medicine*, **119**, 266.
- Cornell, A. (1956). Diverticula of the esophagus. *Journal of the Mount Sinai Hospital*, **23**, 40.
- Creamer, B., Donoghue, F. E., and Code C. F. (1958). Pattern of esophageal motility in diffuse spasm. *Gastroenterology*, **34**, 782.
- Cross, F. S., Johnson, G. F., and Gerein, A. N. (1961). Esophageal diverticula. *Archives of Surgery*, **83**, 525.
- d'Abreu, A. L. (1949). Diverticula of the oesophagus. *British Journal of Radiology*, **22**, 423.
- Effler, D. B., Barr, D., and Groves, L. K. (1959). Epiphrenic diverticulum of the esophagus. *Archives of Surgery*, **79**, 459.
- Ellis, F. H. Jr., Schlegel, J. F., Lynch, V. P., and Payne, W. S. (1969). Cricopharyngeal myotomy for pharyngo-esophageal diverticulum. *Annals of Surgery*, **170**, 340.
- Gahagan, T. (1962). Diverticula of the thoracic esophagus. *Henry Ford Hospital Medical Bulletin*, **10**, 449.
- Garcia, J. B., Bengochea, J. B., and Wooler, G. H. (1972). Epiphrenic diverticula of the esophagus. *Journal of Thoracic and Cardiovascular Surgery*, **63**, 114.
- Goodman, H. I. and Parnes, I. H. (1952). Epiphrenic diverticula of the esophagus. *Journal of Thoracic Surgery*, **23**, 145.
- Habein, H. C., Moersch, H. J., and Kirklin, J. W. (1956). Diverticula of the lower part of the esophagus. *Archives of Internal Medicine*, **97**, 768.
- Harrington, S. W. (1949). The surgical treatment of pulsion diverticula of the thoracic esophagus. *Annals of Surgery*, **129**, 606.
- Hogan, W. J., Caffisch, C. R., and Winship, D. H. (1969). Unclassified oesophageal motor disorders simulating achalasia. *Gut*, **10**, 234.
- Hollis, J. B. and Castell, D. O. (1972). Amplitude of esophageal peristalsis as determined by rapid infusion. *Gastroenterology*, **63**, 417.
- , and —, (1974). Esophageal function in elderly men. A new look at presbyesophagus. *Annals of Internal Medicine*, **80**, 371.
- Jackson, C. and Shallow, T. A. (1926). Diverticula of the oesophagus, pulsion, traction, malignant and congenital. *Annals of Surgery*, **83**, 1.
- Johnstone, A. S. (1949). Diverticula of the oesophagus. *British Journal of Radiology*, **22**, 415.
- Kay, E. B. (1953). The inferior esophageal constrictor in relation to lower esophageal disease. *Journal of Thoracic Surgery*, **25**, 1.
- Kaye, M. D. (1973). Dysfunction of the lower esophageal sphincter in disorders other than achalasia. *American Journal of Digestive Diseases*, **18**, 734.
- Kragh, J. (1922). Tuberculous diverticula of the oesophagus (so-called traction diverticula). *Acta Otolaryngologica*, **4**, 49.
- Lahey, F. H. (1946). Pharyngo-esophageal diverticulum: its management and complications. *Annals of Surgery*, **124**, 617.
- Law, S. W. and Overstreet, J. W. (1964). Pulsion diverticula of the mid-thoracic esophagus. *Journal of Thoracic and Cardiovascular Surgery*, **48**, 855.
- Le Count, E. R. (1915). Epibronchial pulsion diverticula of the esophagus. *Transactions of the Chicago Pathological Society*, **10**, 35.
- Lund, W. S. (1965). A study of the cricopharyngeal sphincter in man and in the dog. *Annals of the Royal College of Surgeons of England*, **37**, 225.
- Maier, H. C. (1953). Dysphagia from diverticulum of the mid-thoracic esophagus. *Gastroenterology*, **23**, 318.
- Mondière, J. T. (1833). Notes sur quelques maladies de l'oesophage. *Archives Générales de Médecine*, 2nd series, **3**, 28.
- Oekonomides, G. (1882). Ueber chronische Bronchialdrusenaffektionen und ihre Folgen. Inaugural dissertation, Basel. Quoted by Harrington.
- Postlethwait, R. W. and Sealy, W. C. (1961). *Surgery of the Esophagus*, p. 104. Thomas, Springfield, Illinois.
- Pope, C. E. II (1967). A dynamic test of sphincter strength: its application to the lower esophageal sphincter. *Gastroenterology*, **52**, 779.
- Rokitansky, C. (1840). Spindelförmige Erweiterung der Speiseröhre. *Medizinische Jahrbücher des k.k. Österreichischen Staates*, **21**, 219.
- Sanderson, D. R., Ellis, F. H. Jr., Schlegel, J. F., and Olsen, A. M. (1967). Syndrome of vigorous achalasia: clinical and physiologic observations. *Diseases of the Chest*, **52**, 508.
- Schatzki, R. (1933). Reliefstudien an der normalen und krankhaft veränderten Speiseröhre. *Acta Radiologica*, Supplement, p. 18.
- Soergel, K. H., Zboralske, F. F., and Amberg, J. R. (1964). Presbyesophagus: esophageal motility in nonagenarians. *Journal of Clinical Investigation*, **43**, 1472.
- Sutherland, H. D. (1962). Cricopharyngeal achalasia. *Journal of Thoracic and Cardiovascular Surgery*, **43**, 114.

Requests for reprints to: Dr. M. D. Kaye, Associate Professor of Medicine, D302 Given Medical Building, University of Vermont College of Medicine, Burlington, Vermont 05401, USA.