

# Reconstruction of right ventricular outflow with a valved homograft conduit

D. J. WHEATLEY, S. PRUSTY, and D. N. ROSS

*Department of Surgery, National Heart Hospital, London W1*

**Wheatley, D. J., Prusty, S., and Ross, D. N. (1974). *Thorax*, 29, 617–623. Reconstruction of right ventricular outflow with a valved homograft conduit.** Since 1966 a conduit of homograft ascending aorta with its valve has been used for reconstruction of the right ventricular outflow. This technique has been applied to 123 operations for pulmonary autograft replacement of the aortic valve, 48 operations for correction of severe Fallot's tetralogy or pulmonary atresia, five operations for truncus arteriosus, two operations for transposition of the great arteries with ventricular septal defect, and six operations for tricuspid atresia or common ventricle. Ease of insertion and satisfactory function have encouraged us in the use of this form of conduit.

The problem of providing an adequate pathway for blood from the right ventricle to reach the pulmonary arteries arises in a number of cardiac surgical procedures. These include severe forms of Fallot's tetralogy, pulmonary atresia, truncus arteriosus, and transposition of the great arteries with ventricular septal defect.

In 1966 a conduit of homograft ascending aorta with its valve was first used to solve this problem in a patient with pulmonary atresia (Ross and Somerville, 1966). The patient remains alive and the technique is now well established. This paper reports experience with this technique since 1966 at the National Heart Hospital.

## SURGICAL TECHNIQUE

The homograft conduit consists of ascending aorta with its valve together with remnants of the anterior leaflet of the mitral valve. This tissue is obtained at routine necropsy within 48 hours of death and is currently sterilized and stored at 4°C in an antibiotic-nutrient medium (Lockey, Al-Janabi, Gonzales-Lavin, and Ross, 1972).

The insertion of the conduit presents few technical problems. The graft is trimmed to a suitable length and the coronary orifices of the graft are sutured. The graft is positioned to take advantage of its natural curvature, thus reducing distortion of the valve. The distal end of the graft is anastomosed with a continuous suture to the opened-out distal pulmonary artery or the region of the pulmonary artery bifurcation and may be exten-

ded into one or other pulmonary artery as required. Proximally the graft is 'countersunk' as far as possible into the right ventricle to give a satisfactory angle of origin; this requires trimming of the edges of the right ventriculotomy. There is usually a defect present anteriorly between the graft and the right ventricle and this is closed with a Dacron or pericardial gusset (Fig. 1).

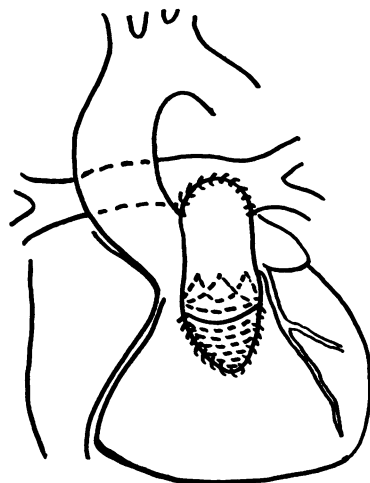


FIG. 1. Reconstruction of right ventricular outflow—homograft conduit in place.

The conduit functions well and provides a competent valve for the right ventricular outflow. Calcification commonly appears in the aortic wall of the graft and is visible radiologically after about six months. However, it does not appear to impair valve function nor involve the cusps (Somerville and Ross, 1972).

#### APPLICATIONS OF THE TECHNIQUE

**PULMONARY AUTOGRAFT REPLACEMENT OF THE AORTIC VALVE** Considerable experience has been gained in reconstructing the right ventricular outflow with a homograft conduit in the operation of aortic valve replacement with pulmonary autograft (Gonzales-Lavin, Geens, Somerville, and Ross, 1970). Since 1967, 123 operations for aortic valve replacement have been performed using the patient's autogenous pulmonary valve, which is excised early in the course of the operation once the need for replacement of the aortic valve has been confirmed (Fig. 2).

hospital deaths and three late deaths. Results in the survivors are gratifying (Ross, 1972). Thirty-five of these patients have had normally functioning homograft outflow conduits for five years or more. One of the late deaths occurred at five and a half years; no explanation was found and the homograft valve in the right ventricular outflow was remarkable for its normal appearance and integrity.

**CORRECTION OF SEVERE FALLOT'S TETRALOGY AND PULMONARY ATRESIA** Since 1966, 48 patients with severe Fallot's tetralogy or pulmonary atresia have had right ventricular outflow reconstruction using this technique. Although 24 were considered at operation to have pulmonary atresia of type I or type II (Somerville, 1970), and 24 to have severe Fallot's tetralogy with a hypoplastic infundibulum, pulmonary valve ring, or main pulmonary artery, the distinction may be difficult to make preoperatively, and from a surgical point of

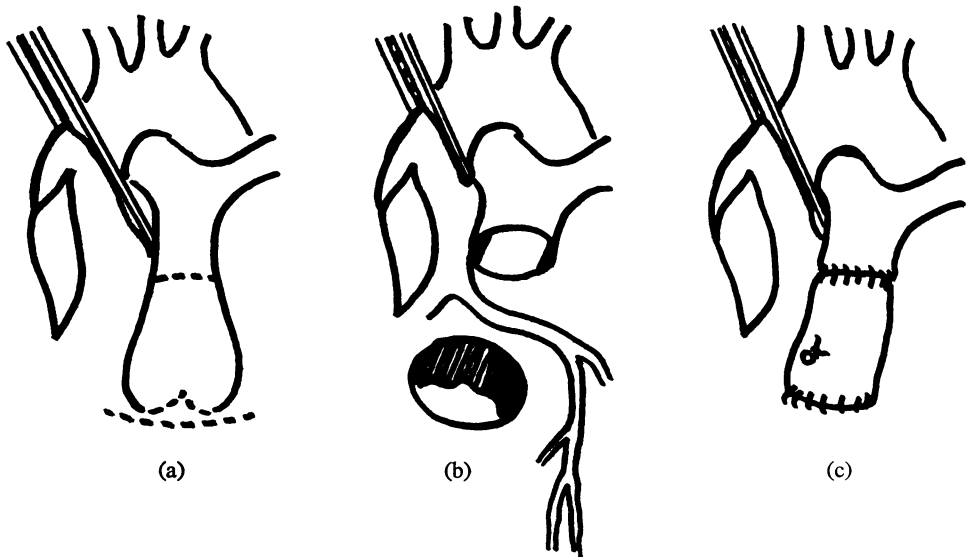


FIG. 2. (a, b) *Pulmonary valve excised for use in aortic position*; (c) *right ventricular outflow reconstituted with homograft*.

The pulmonary valve offers an ideal valve for replacement, not having been exposed to sterilization or storage techniques. The operation is technically demanding and it has been limited to younger patients. There have been no problems relating to the use of homografts in this application of right ventricular outflow reconstruction. In the group of 123 patients there have been 16

view they are varying degrees of the same basic problem. Indeed some patients who have been shown to have severe Fallot's tetralogy prior to systemic-pulmonary anastomosis have on re-investigation failed to opacify the right ventricular outflow, and the appearance at surgery has been of pulmonary atresia.

In this difficult group of 48 patients there have

been 21 hospital deaths. Reconstruction of the right ventricular outflow with a valved homograft conduit has not been technically difficult, although in one case a problem arose from compression of the graft by the sternum on closure of the chest. This was appreciated only after re-opening of the chest for low cardiac output state, and the patient subsequently died.

The age range of this group was 18 months to 34 years (Table I). The 18-month-old child was unsuccessfully operated on under emergency conditions following cardiac arrest during left thoracotomy for a Blalock anastomosis.

TABLE I

SEVERE FALLOT'S TETRALOGY/PULMONARY ATRESIA: AGE AT OPERATION AND RELATION TO HOSPITAL DEATH

Age (yr)	No. of Patients	Hospital Deaths
Under 2	1	1
2-4	3	2
5-12	24	9
Over 12	20	9

Previous palliative systemic-pulmonary anastomoses were present in 37 of the patients (Table II). These shunts were closed as a preliminary step to correction. In some patients a previous Waterston palliative anastomosis appeared to have kinked the right pulmonary artery and led to preferential filling of the right lung and lack of development of the segment of right pulmonary artery behind the aorta and of the left pulmonary artery. In seven patients it was necessary to dissect the right pulmonary artery off the aorta at the Waterston anastomosis and patch the right pulmonary artery to enlarge it at the shunt site.

TABLE II

SEVERE FALLOT'S TETRALOGY/PULMONARY ATRESIA: PREVIOUS SYSTEMIC-PULMONARY ANASTOMOSES

	No. of Patients	Hospital Deaths
Waterston	17	8
Blalock	12	4
Potts	3	0
Waterston + Blalock	4	2
Waterston + Blalock + Potts	1	1
No previous shunt	37	15
	11	6

A vertical incision has been preferred in the right ventricular outflow where the outflow is known to be atretic or narrowed as this incision can readily be extended up into the pulmonary artery if necessary (Fig. 3). The coronary arterial anatomy must be borne in mind in planning the

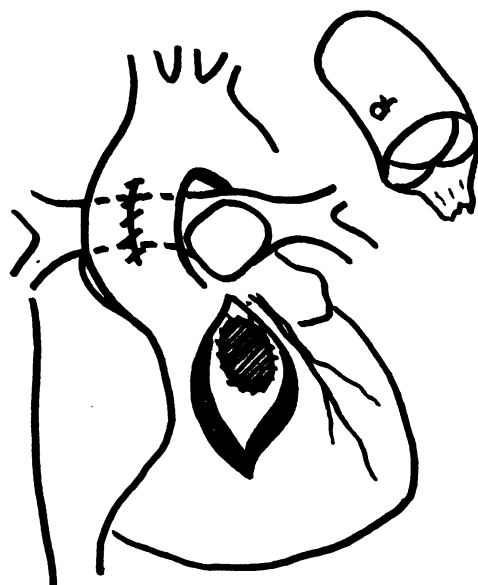

FIG. 3. Right ventricular outflow reconstruction in pulmonary atresia. Ventricular septal defect closed—homograft conduit ready for insertion.

incision. An anomalous left anterior descending artery is a particular hazard; division of such a vessel led to the death of one of our patients.

In all cases the ventricular septal defect was patched with Dacron cloth (one patient had three ventricular septal defects). In addition an atrial septal defect was closed in four patients. Other procedures required at the time of correction (in addition to closure of any systemic-pulmonary anastomosis) are shown in Table III.

TABLE III

SEVERE FALLOT'S TETRALOGY/PULMONARY ATRESIA: OTHER PROCEDURES REQUIRED AT TIME OF SURGERY

	No. of Patients	Deaths
Multiple ventricular septal defect closure	1	1
Closure of atrial septal defect	4	3
Closure of patent ductus arteriosus	5	3
Aortic valve replacement	1	1
Correction of hemi-truncus	1	0
Division of collaterals via thoracotomy	2	2

The major cause of death was failure to relieve right ventricular hypertension (Table IV), right ventricular pressure usually being equal to or in excess of left ventricular pressure immediately after correction. This was associated with a progressively falling arterial  $P_{O_2}$  and bleeding from the conduit anastomotic lines. In 10 patients who

TABLE IV

SEVERE FALLOT'S TETRALOGY/PULMONARY ATRESIA:  
MAJOR FACTORS IN DEATH

	No. of Patients
Unresolved right ventricular hypertension	10
Coronary arterial damage	2
Infection (endocarditis 1; septicaemia 2)	3
Obstruction of conduit by sternum	1
Bleeding	3
Emergency operation—critically ill patient	2

died, unresolved right ventricular hypertension was the major factor in the death. This was not due to obstruction in the homograft conduit, and pressures in the distal pulmonary arteries were similarly raised. The same problem has been encountered in severe Fallot's tetralogy treated by patch enlargement of the right ventricular outflow. Increased pulmonary vascular resistance due to high flow systemic connections, or hypoplastic pulmonary vessels well out into the lungs, have explained these deaths.

The ratio of right to left ventricular pressure after correction on the operating table has given a fairly good indication of the prognosis (Table V). In 19 of the 27 survivors the right ventricular pressure was half or less than half that of the left ventricle.

TABLE V

SEVERE FALLOT'S TETRALOGY/PULMONARY ATRESIA:  
RIGHT/LEFT VENTRICULAR PRESSURE AFTER  
CORRECTION

	No. of Patients	Deaths
Less than 70%	27	6
More than 70%	11	10

There was one totally unexplained death at two months, where the right ventricular outflow reconstruction looked entirely satisfactory at post-mortem examination. Results in the survivors have been good and there has been no evidence of dysfunction of the homograft conduit, with the exception of one patient whose central venous pressure remained elevated and was shown to have a gradient of 60 mmHg across the conduit 11 days after surgery. In seven patients the conduit has functioned well for over five years. Duration of homograft conduit function is shown in Table VI.

**CORRECTION OF TRUNCUS ARTERIOSUS** Correction of truncus arteriosus has been limited to five cases in our experience. There were two deaths. The pulmonary arteries were isolated from the truncus and the ventricular septal defect was closed, after

TABLE VI

SEVERE FALLOT'S TETRALOGY/PULMONARY ATRESIA:  
DURATION OF HOMOGRAFT CONDUIT FUNCTION

Duration (yr)	No. of Patients
8	2
7	1
6	3
5	1
4	3
3	5
2	8
1	3

which a valved aortic homograft conduit was used to reconstitute a right ventricular outflow in the usual manner described (McGoon, Rastelli, and Ongley, 1968; Weldon and Cameron, 1968) (Fig. 4).

**CORRECTION OF TRANSPOSITION OF THE GREAT ARTERIES WITH VENTRICULAR SEPTAL DEFECT** Experience with correction of transposition of the great arteries with ventricular septal defect and left ventricular outflow tract obstruction has been limited to two cases. After placing a patch to redirect left ventricular blood through the ventricular septal defect into the aorta a conduit of homograft aorta is used to reconstruct a right ventricular outflow—the proximal end of the divided pulmonary artery having first been oversewn (Rastelli, McGoon, and Wallace, 1969) (Fig. 5).

**CORRECTION OF TRICUSPID ATRESIA AND CORRECTION OF COMMON VENTRICLE** Recently this technique has been applied in a modified form to the problems of tricuspid atresia and to common ventricle. Here the right atrium is adapted to function as a 'right ventricle' and a conduit is used as a right ventricular outflow (Fontan and Baudet, 1971; Ross and Somerville, 1973) (Fig. 6).

Two of the four tricuspid atresia patients have survived, but the two common ventricle patients were near-terminal when operated on and did not survive long postoperatively. However, initial function was promising and it is possible that the technique may have application in this field.

## DISCUSSION

The need for construction of an outflow tract for the right ventricle is common to many conditions. The technique of using a valved conduit as outlined is one approach to the problem (McGoon, Wallace, and Danielson, 1973). This technique has given satisfactory results in our experience as well as in other centres (Brawley *et al.*, 1972).

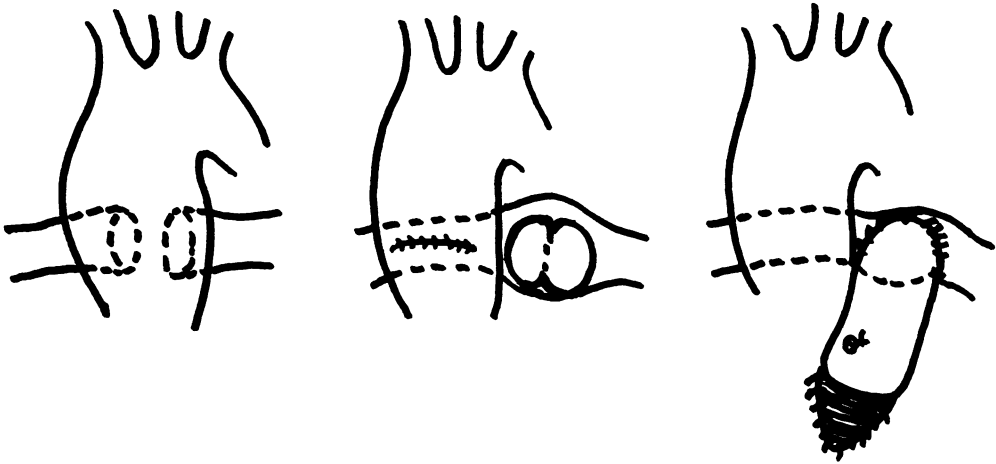


FIG. 4. Correction of truncus arteriosus. Pulmonary arteries isolated from truncus and joined to right ventricle by homograft.

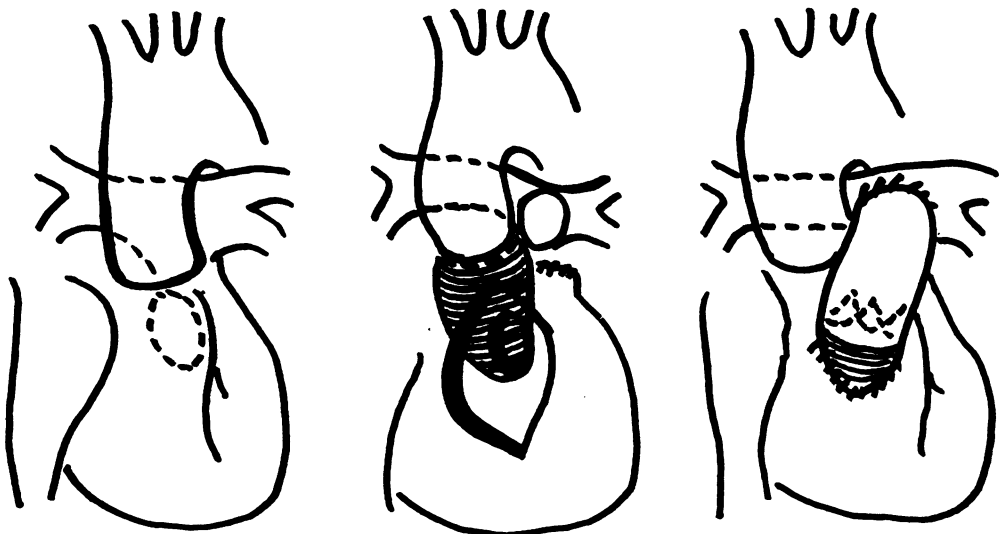

FIG. 5. Correction of transposition of great arteries. Patch directs blood via ventricular septal defect to aorta.

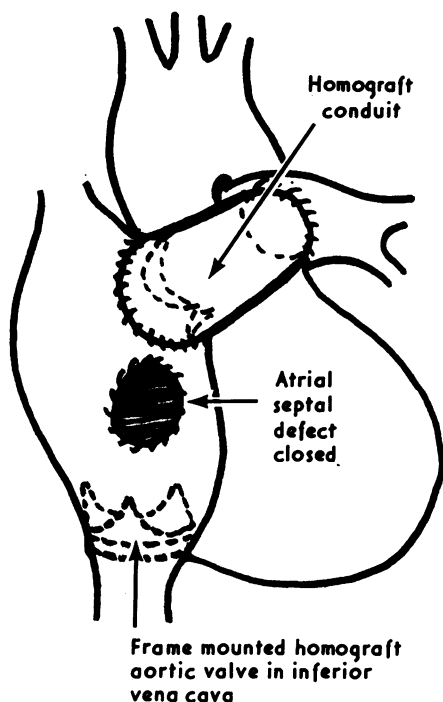


FIG. 6. Reconstruction for tricuspid atresia or common ventricle.

However, further observation is required before the long-term fate of such a conduit can be assessed.

Various other conduits are currently in use (Kouchoukos, Barcia, Barger, and Kirklin, 1971), tubes of Dacron with or without prosthetic, heterograft or homograft valves giving satisfactory results in other centres. Our early experience with tubes made of fascia lata containing a fascial valve was uniformly unsuccessful in 11 patients (Ross and Somerville, 1971). We have been concerned about the possible adverse effect of pulmonary regurgitation where a valve is not used, and prosthetic valves may be responsible for silent thromboembolism to the lungs.

Results of using homograft aortic segments to replace sections of the aorta resected for aneurysm or coarctation showed that although calcification is heavy in the non-viable grafts their function as conduits is retained for eight to 17 years after implantation (Brock, 1968). Long-term results following homograft aortic valve implantation suggest that reasonable long-term valve function can be expected, and the use of viable

homograft tissue may improve the outlook further (Barratt-Boyes, 1971; Angell, Shumway, and Kosek, 1972; Ross, 1972). Although it may appear that a homograft aorta with its valve used in the pulmonary position may last longer, as it is subjected to lower pressures, the observation of better survival of pulmonary grafts over aortic grafts has been reported in experimental conditions (Eguchi and Asano, 1968; Pierce, Thompson, Kazama, and Waldhausen, 1971).

The management of the outflow tract in severe Fallot's tetralogy is a subject for debate (Trusler, Iyengar, and Mustard, 1973). We feel that the emphasis in the past on relief of obstruction may be succeeded by a greater appreciation of the need for providing a reasonably competent pulmonary valve. Although isolated pulmonary regurgitation may be benign, it may not be well tolerated where there is an increase in pulmonary vascular resistance. Although we continue to manage the outflow tract of Fallot's tetralogy by patching where necessary, the severer forms of outflow tract hypoplasia appear to have been more satisfactorily dealt with by the use of a homograft aortic conduit with its valve. Good long-term function to date and ease of insertion of the conduits have encouraged us in their use in this situation.

#### REFERENCES

- Angell, W. W., Shumway, N. E., and Kosek, J. C. (1972). A five-year study of viable aortic valve homografts. *Journal of Thoracic and Cardiovascular Surgery*, **64**, 329.
- Barratt-Boyes, B. G. (1971). Long term follow-up of aortic valvar grafts. *British Heart Journal*, **33**, Supplement, p. 60.
- Brawley, R. K., Gardner, T. J., Donahoo, J. S., Neill, C. A. Rowe R. D., and Gott, V. L. (1972). Late results after right ventricular outflow tract reconstruction with aortic root homografts. *Journal of Thoracic and Cardiovascular Surgery*, **64**, 314.
- Brock, R. C. (1968). Long-term degenerative changes in aortic segment homografts, with particular reference to calcification. *Thorax*, **23**, 249.
- Eguchi, S. and Asano, K. (1968). Homograft of pulmonary artery and ascending aorta with valve as a right ventricular outflow. *Journal of Thoracic and Cardiovascular Surgery*, **56**, 413.
- Fontan, F. and Baudet, E. (1971). Surgical repair of tricuspid atresia. *Thorax*, **26**, 240.
- Gonzales-Lavin, L., Geens, M., Somerville, J., and Ross, D. N. (1970). Autologous pulmonary valve replacement of the diseased aortic valve. *Circulation*, **42**, 781.
- Kouchoukos, N. T., Barcia, A., Barger, L. M., and Kirklin, J. W. (1971). Surgical treatment of congenital pulmonary atresia with ventricular septal



- defect. *Journal of Thoracic and Cardiovascular Surgery*, **61**, 70.
- Lockey, E., Al-Janabi, N., Gonzales-Lavin, L., and Ross, D. N. (1972). A method of sterilizing and preserving fresh allograft heart valves. *Thorax*, **27**, 398.
- McGoon, D. C., Rastelli, G. C., and Ongley, P. A. (1968). An operation for the correction of truncus arteriosus. *Journal of the American Medical Association*, **205**, 69.
- , Wallace, R. B., and Danielson, G. K. (1973). The Rastelli operation. Its indications and results. *Journal of Thoracic and Cardiovascular Surgery*, **65**, 65.
- Pierce, W. S., Thompson, W. M., Kazama, S., and Waldhausen, J. A. (1971). Replacement of the pulmonary outflow tract and valve with a formalin-treated porcine heterograft. *Journal of Thoracic and Cardiovascular Surgery*, **61**, 924.
- Rastelli, G. C., McGoon, D. C., and Wallace, R. B. (1969). Anatomic correction of transposition of the great arteries with ventricular septal defect and subpulmonary stenosis. *Journal of Thoracic and Cardiovascular Surgery*, **58**, 545.
- Ross, D. N. (1972). Biologic valves; their performance and prospects. *Circulation*, **45**, 1259.
- and Somerville, J. (1966). Correction of pulmonary atresia with a homograft aortic valve. *Lancet*, **2**, 1446.
- and — (1971). Fascia-lata reconstruction of the right ventricular outflow tract. *Lancet*, **1**, 941.
- and — (1973). Surgical correction of tricuspid atresia. *Lancet*, **1**, 845.
- Somerville, J. (1970). Management of pulmonary atresia. *British Heart Journal*, **32**, 641.
- and Ross, D. N. (1972). Long-term results of complete correction with homograft reconstruction in pulmonary outflow tract atresia. *British Heart Journal*, **34**, 29.
- Trusler, G. A., Iyengar, S. R., and Mustard, W. T. (1973). Reconstruction of the pulmonary valve and outflow tract. A report of 25 cases. *Journal of Thoracic and Cardiovascular Surgery*, **65**, 245.
- Weldon, C. S. and Cameron, J. L. (1968). Correction of persistent truncus arteriosus. *Journal of Cardiovascular Surgery*, **9**, 463.

Requests for reprints to: D. N. Ross, F.R.C.S., Department of Surgery, The National Heart Hospital, Westmorland Street, London W1.