Thorax (1974), **29**, 382.

Primary pulmonary nocardiosis: case report

P. B. HAMAL

Department of Pathology, Dudley Road Hospital, Birmingham B18 7QH

Hamal, P. B. (1974). *Thorax*, **29**, 382–386. **Primary pulmonary nocardiosis: a case report.** A case of fulminating pulmonary nocardiosis is reported. Diagnosis was made before death but too late for treatment to be effective. At necropsy extensive multiple pulmonary abscesses with involvement of the pleura, resulting in an empyema, were discovered. One cervical node showed a similar abscess. No brain lesions nor involvement of other organs was seen. Gram-positive organisms were seen in the lesions but acid-fastness could not be demonstrated.

Nocardiosis is a rare fungal disease affecting the lungs. Thirteen species of Nocardia have been described, *Nocardia asteroides* being the most usual one found as a pathogen in man. The organism may also infect subcutaneous tissue and brain. Infection, which occurs most commonly in patients with malignant disease or immunological depression, occurs by inhalation or sometimes at the site of skin trauma. In the lungs it may produce a disease ranging from chronic to fulminating, while in skin and other viscera it produces chronic suppuration, sinuses, and abscess formation (Riddell and Stewart, 1958; Ciba Foundation, 1968). The present report is of a case of acute fulminating pulmonary nocardiosis.

CASE REPORT

A 32-year-old male decorator was admitted to hospital on 8 August 1970 with a short history of retrosternal pain radiating to both sides and the back, cough with yellow-white sputum, breathlessness, and fever. He was anxious and dyspnoeic with a temperature of 40°C, pulse 120/minute, and blood pressure 110/80 mmHg. Bronchial breath sounds were heard over the left lower lobe and crackles over both lungs. A chest radiograph (Fig. 1) showed bilateral patchy opacities. Haemoglobin was 11·9 g/100 ml, white count 22,000/mm^3 with a polymorphonuclear leucocytosis, ESR 73 mm per hour. A light growth of Candida was the only organism isolated from the sputum.

Pneumonia, presumably viral, was diagnosed and treatment with co-trimoxazole, ampicillin, and then gentamicin was tried. The patient appeared to improve and his temperature fell. He was discharged on 22 August 1970 but readmitted 10 days later. He was then severely dyspnoeic with a sore chest, night sweats, and purulent sputum with some haemoptysis. He was cyanosed with a pulse of 130/minute and a fever of 39°C. His liver was enlarged and he had signs of bilateral bronchopneumonia.

INVESTIGATIONS On this admission the results were as follows:

Haemoglobin Between 10 and 12 g/100 ml.

White cell count Between 16,000 and 29,000/mm^3 with polymorphonuclear leucocytosis.

ESR (Westergren) Between 85 and 120 mm per hour.

Urea and electrolytes Predominantly low urea, sodium, and chloride.

Liver function Alkaline phosphatase 33·4 units, serum aspartate aminotransferase 16 IU/l, serum alanine aminotransferase 23 IU/l.

Proteins 6·6 g with low albumin and raised α 1 and 2 and β globulins.

Sputum Gram films and culture were negative until three days before death when possible diphtheroids were noted. The day before death a heavy growth of Nocardia was obtained. No acid-fast organisms were seen.

Urine Culture grew *Entamoeba coli* and Candida on two occasions.

Serological tests for psittacosis, Aspergillus, Histoplasma, Nocardia, and Candida were negative.

Viral complement fixation tests Negative.

Cold agglutinins Negative.

Cytology Sputum and pleural aspirate—negative.

Mantoux Negative to 10 TU.

Electrocardiogram Sinus tachycardia.

Chest radiograph (Fig. 2) Further confluence of the bilateral opacities, abscess formation, and eventually bilateral hydropneumothoraces.

Liver biopsy Non-specific portal tract infiltration by inflammatory cells.

Bronchial aspirate One week and one day before death: both showed a heavy growth of *Nocardia asteroides.*

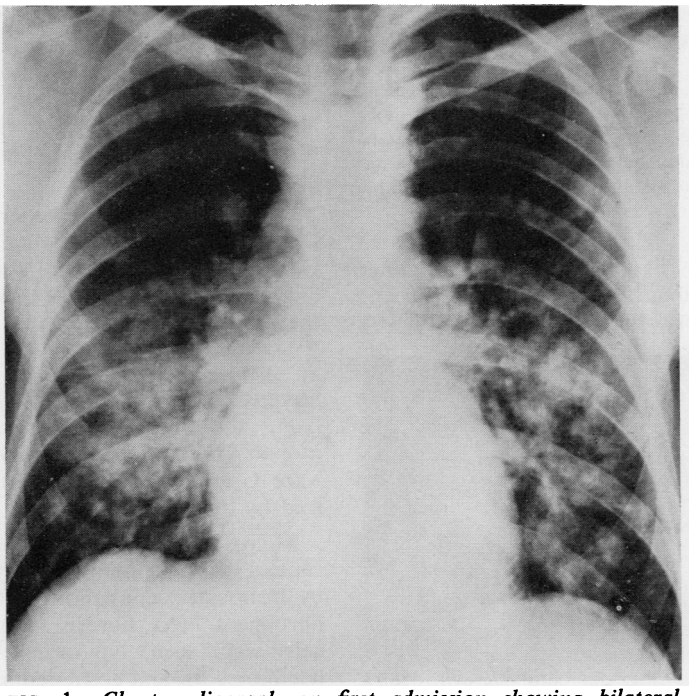

FIG. 1. *Chest radiograph on first admission showing bilateral patchy bronchopneumonia.*

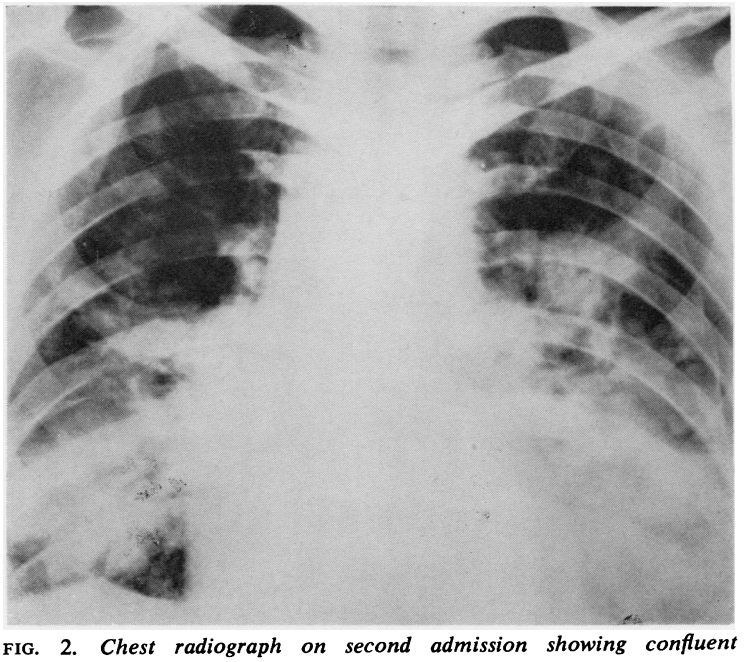

FIG. 2. *Chest radiograph on second admission showing confluent consolidation and left hydropneumothorax.*

TREATMENT AND PROGRESS The patient had deteriorated in spite of ampicillin given since his first admission. He was given instead chloramphenicol, 250 mg six-hourly, and cephaloridine, 1 g intramuscularly twice daily with prednisone, 15 mg daily. For the last week he was given ampicillin, 0·5 g six-hourly, and on the day before death sulphadimidine. He deteriorated steadily and died on 29 September 1970.

NECROPSY FINDINGS The pleural cavity contained pus, and the pleural surfaces were thickened and covered with necrotic fibrinous exudate (Fig. 3).

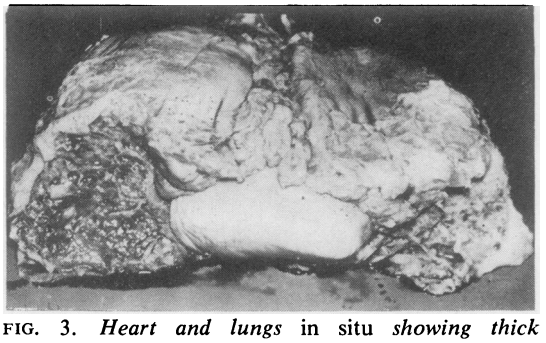

FIG. 3. *Heart and lungs* in situ *showing thick fibrinopurulent exudate in the pleura.*

The lungs showed multiple abscesses with areas of whitish consolidation between, in places breaking down into small abscesses (Fig. 4). There was some lower lobe collapse. Some of the lung abscesses had ruptured into the pleural cavity and others into the bronchial tree, which contained purulent exudate.

The hilar nodes were oedematous and enlarged. One cervical node showed minute abscesses. There were a few enlarged para-aortic nodes, but these did not contain abscesses. No lesion was found in the brain or other organs.

POSTMORTEM BACTERIOLOGY AND HISTOLOGY Swabs from abscesses and bronchi showed a heavy growth of *Nocardia asteroides*. The organisms were Gram-positive, acid-fast, and not decolourized by dilute sulphuric acid.

Microscopy showed the abscesses to consist of central polymorphonuclear leucocytes surrounded by histiocytes, epithelioid cells, lymphocytes, and fibroblasts. No fibrosis, granulomata or giant cells were seen. No organisms were seen with haematoxylin and eosin staining, but Gram stains showed abundant coccobacillary forms and my-

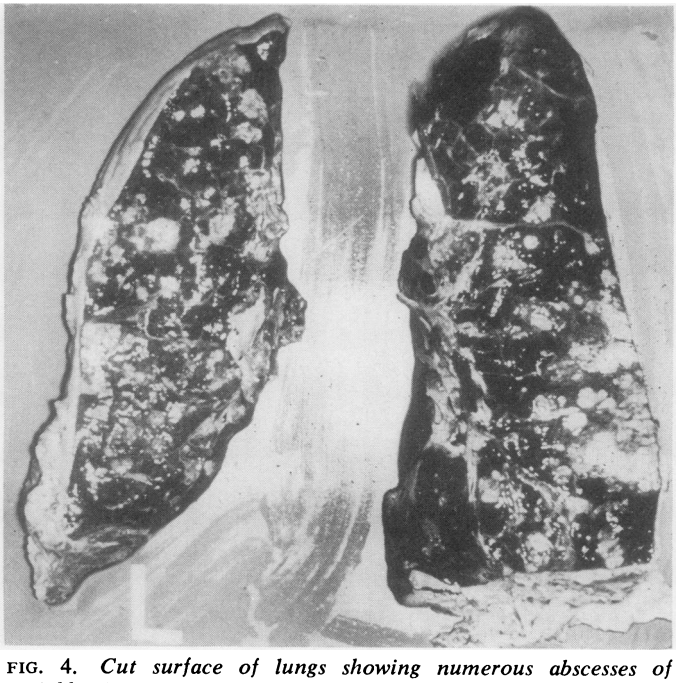

FIG. 4. *Cut surface of lungs showing numerous abscesses of variable sizes.*

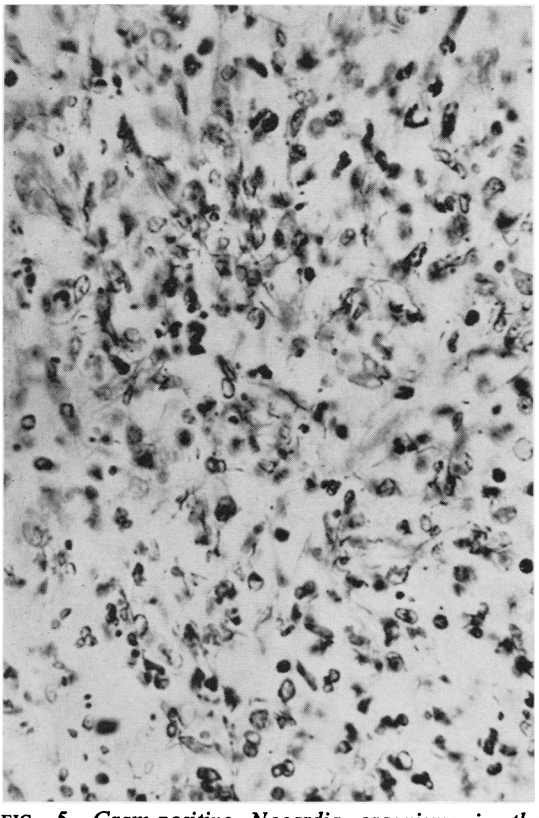

FIG. 5. *Gram-positive Nocardia organisms in the abscesses of the lymph node.*

celial filaments around the abscesses (Fig. 5). Acid-fast stains with dilute acid did not produce consistent results.

No histological lesion was found in any other organ.

DISCUSSION

Nocardia asteroides is a saprophyte in nature, present in soil and decaying organic matter. It is an Actinomycete, classified between fungi and bacteria. It occurs in bacillary and coccobacillary forms which produce mycelia and branching, are Gram-positive and variably acid-fast. Nocardia is not seen on haematoxylin and eosin staining and so special stains are necessary for histological diagnosis. The organism is aerobic, in contrast to the anaerobic Actinomyces, and grows in ordinary nutrient agar at 37°C and room temperature in three to six days. It is variably pathogenic to rabbits and guinea-pigs. It may produce red, orange or yellow granules.

Nocardia was first isolated from cattle by Nocard in 1888 and a case of human infection with cerebral abscesses was reported by Eppinger in 1890. Sporadic case reports appeared until about a decade ago, but more recently an increased number of cases have been reported, especially from North America. There appears to be an increase in the incidence of the disease, though there are geographical variations in its distribution (Murray, Finegold, Froman, and Will, 1961; Brine, 1965). Murray *et al.* (1961) reviewed 179 cases reported in the literature up till 1961. McQuown (1955) suggested that 5% of all sanatorium patients had Nocardia, though it was not determined whether the organism was pathogenic or simply a commensal. Freese, Young, Sealy, and Conant (1963) found one case per annum in a 500-bed general hospital in the United States. Larsen, Diamond, and Collins (1959) described seven cases over five years, five of their patients suffering from malignant disease in addition.

It is now recognized that milder forms of the disease occur, and early diagnosis and treatment are clearly vital. Diagnosis is easy if suspected. Treatment with sulphonamides is often effective, Hathaway and Mason (1962) having reported cure in 11 of 14 cases, and Freese *et al.* (1963) 7 out of 11 cases. Baikie, MacDonald, and Mundy (1970) reported cure in an apparently hopeless case of disseminated nocardiosis with knee joint abscesses effected by co-trimoxazole after amputation, drainage, and other sulphonamides had failed.

The present case is an example of the fulminant type of infection with extensive tissue invasion and a purely suppurative reaction. It illustrates the fact that early diagnosis is important, because had the diagnosis been made on the initial admission the patient's life might have been saved. If the disease is suspected bacteriological diagnosis is fairly easy. Plates must be incubated rather longer than usual as Nocardia takes at least three days to grow. The radiographic findings are not helpful (McQuown, 1955; Hathaway and Mason, 1962) as they may vary from a coin lesion to diffuse bronchopneumonia. Tuberculosis is often considered in the radiological differential diagnosis. In this case the pleural involvement was somewhat atypical, although it has been described before (Larsen *et al.*, 1959). The hepatic enlargement and raised alkaline phosphatase were probably non-specific findings related to the patient's toxaemia. The negative precipitin tests for Nocardia suggest that this test is not reliable in a seriously ill patient.

Our patient appears to have had primary infection, since there was no evidence of any underlying disease process. Spread was local and by lymphatics and not by blood-borne dissemination. The treatment with steroids may well have aggravated the disease. Failure to isolate the organism necessitated blind chemotherapy and was the important cause of the missed diagnosis. It is necessary to suspect Nocardia as the pathogen in obscure bronchopneumonic illnesses with apparently sterile sputum and to request the appropriate bacteriological investigations.

I am indebted to Drs. F. E. D. Griffiths and J. D. Williams, Miss Jean McCulloch, and Miss Vivian Barlow for help in the preparation of this paper.

REFERENCES

Baikie, A. G., MacDonald, C. B., and Mundy, G. R. (1970). Systemic nocardiosis treated with trimethoprim and sulphamethoxazole. *Lancet*, **2**, 261.

Brine, J. A. S. (1965). Human nocardiosis: A developing clinical picture. *The Medical Journal of Australia*, **1**, 399.

Ciba Foundation (1968). *Systemic Mycoses*. Edited by G. E. W. Wolstenholme and R. Porter, Churchill, London.

Freese, J. W., Young, W. G., Sealy, W. C., and Conant, N. F. (1963). Pulmonary infection by *Nocardia asteroides*. *Journal of Thoracic and Cardiovascular Surgery*, **46**, 537.

Hathaway, B. M. and Mason, K. N. (1962). Nocardiosis. *American Journal of Medicine*, **32**, 903.

Larsen, M. C., Diamond, H. D., and Collins, H. S. (1959). *Nocardia asteroides* infection. *Archives of Internal Medicine*, **103**, 712.

McQuown, A. L. (1955). Actinomycosis and nocardiosis. *American Journal of Clinical Pathology*, **25**, 2.

Murray, J. F., Finegold, S. M., Froman, S., and Will, D. W. (1961). The changing spectrum of nocardiosis. *American Review of Respiratory Diseases*, **83**, 315.

Riddell, R. W. and Stewart, G. T. (1958). *Fungous Diseases and Their Treatment*. Butterworth, London.

Requests for reprints to: Dr. P. B. Hamal, Department of Pathology, Dudley Road Hospital, Birmingham, B18 7QH.