

# Stented pulmonary valve allografts as tricuspid valve substitutes in sheep

## Their macroscopic and microscopic decline

J. BORRIE and N. R. REDSHAW

*University of Otago, Dunedin, New Zealand*

In sheep, stented pulmonary semilunar valves have been allografted as tricuspid valve substitutes and their biological behaviour has been followed postoperatively. Whereas there was initial pleasing function with normal cusp competence, by day 102 the cusps had retracted to partial incompetence. This process of valve decline was accentuated by day 150, and by day 241 was complete. Histological studies at day 150 showed cusp foreshortening, with scant nuclei and collagen looser than normal. These findings suggested that the mechanism causing the valve decline was a host to foreign body reaction rather than the usual histological pattern of graft rejection.

Human aortic valve allografts are frequently used in clinical cardiac surgery as aortic valve substitutes and have given excellent long-term palliation at this site (Brandt, Roche, Barratt-Boyes, and Lowe, 1969; Ross and Yacoub, 1969). Nevertheless there is evidence that, over a period of time, degenerative changes can occur, with risk to the recipient (Smith, 1967) and the need for further replacement. Such changes, predicted as possible by Brock (1968), occur in sheep within five to seven months of implantation (Borrie and Hill, 1968). The changes include calcification in the muscle at the base of the valve cusp, a lessening of valve cellularity, and host-tissue extension on to the base of the grafted cusps.

Again, in clinical practice, mitral and tricuspid valves cannot be successfully allografted to produce long-term satisfactory results at these sites; but inverted aortic or pulmonary valve allografts, supported on Dacron-covered Teflon stents, have been used (Sugie *et al.*, 1969).

There are few long-term animal survival studies to compare with the experience that is being gained in humans, and there is a need to establish experimentally the month-by-month biological behaviour pattern of each type of graft used at each valve site. This paper amplifies our preliminary report (Borrie and Redshaw, 1971) and illustrates macroscopically and microscopically the long-term functional decline of fresh stented pulmonary semilunar valves when allografted as tricuspid valve substitutes in sheep.

### METHOD

Forty-eight hours before operation day donor hearts were taken from freshly killed sheep and their pulmonary valves were aseptically dissected. After redundant myocardium and pulmonary arterial wall had been trimmed off, the fresh valves were sutured with continuous Mersilene in two layers—one above and one below—to the knitted Dacron covering of the Teflon stent, scalloped to match the size and shape of sheep pulmonary valves (Fig. 1).

The stent had been sterilized with ethylene oxide before the graft was sutured to it. When prepared, the test valve was checked for valve competence and was stored in nutrient medium (T.C. 199) (Morgan, Morton, and Parker, 1950), at 4° C (Fig. 2). The

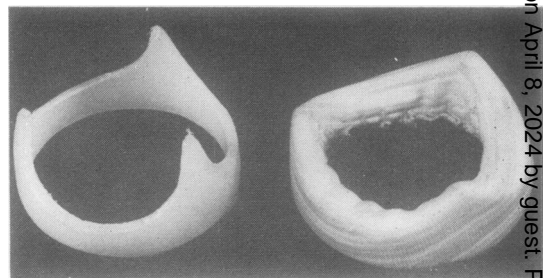


FIG. 1. View of the Teflon stent before and after being covered with Dacron fabric.

outside diameter of the stent, uncovered, was 3 cm and its inside diameter 2.75 cm. When covered with Dacron, the outside diameter was 3.2 cm and the inside diameter 2.5 cm.

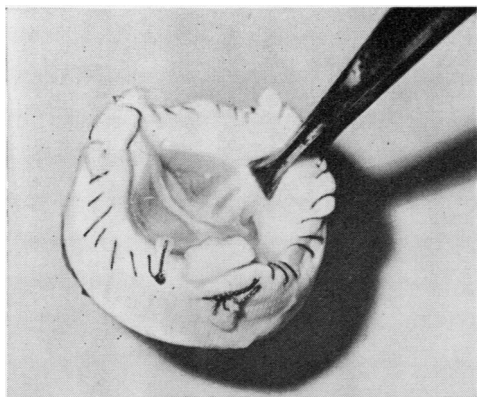


FIG. 2. The test valve ready for insertion.

**OPERATION** Romney/Southdown wethers weighing 60 kg were used. The recipient heart was exposed via a right thoracotomy and lifted, and the left azygos vein, normally present in sheep, was suture ligated where it entered the coronary sinus. The sheep was then given heparin, the venae cavae and right femoral artery were cannulated, and cardiopulmonary bypass was instituted, as previously described (Borrie and Hill, 1968). The right atrium was opened, the tricuspid valve cusps were excised, and the stented valve was inverted and inserted with interrupted Mersilene mattress sutures. Thereafter the right atrial incision was closed with continuous Mersilene sutures and—if fibrillation was present—the heart was defibrillated, as previously described (Borrie, Lichter, and Miller, 1967). Blood pH,  $\text{Na}^+$ , and  $\text{K}^+$  and an electrocardiogram and arterial blood pressure were monitored during operation; blood pH, electrolytes, and blood gases were checked for two days after operation.

**POSTOPERATIVE CARE** The animal was kept ventilated for two hours after operation. In addition to standard right pleural tube thoracostomy drainage, a Readivac suction catheter was placed dorsally in the pleural cavity. This was intermittently aspirated for 48 hours after operation. An intravenous drip was kept running via the right jugular vein, using Hartmann's solution at rates equal to those for humans of the same weight. Crystamycin, 1 megaunit, was given for five days postoperatively. No anticoagulants were given postoperatively.

(Postoperative care has recently been greatly improved by placing the animal in a mobile galvanized iron pen, 100 cm long by 45 cm wide by 80 cm high. The animal can thus be observed and medicated without entangling itself in its intravenous and chest drainage tubes.)

If the animal was slow to feed, as sometimes happened during the first 48 hours after operation, it was given a tube feed of milk, sugar, and Complan.

## RESULTS AND DISCUSSION

Eleven experiments were completed. Causes of death within 24 hours of operation were: low output failure (3), haemothorax (1), inhalation of

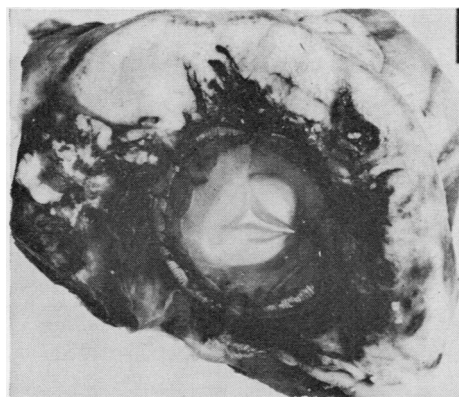


FIG. 3. Day 1. The test valve with competent cusps.

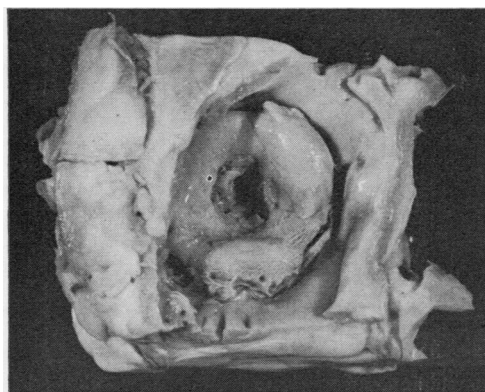


FIG. 4. Day 23. Valve narrowing from granulation tissue.

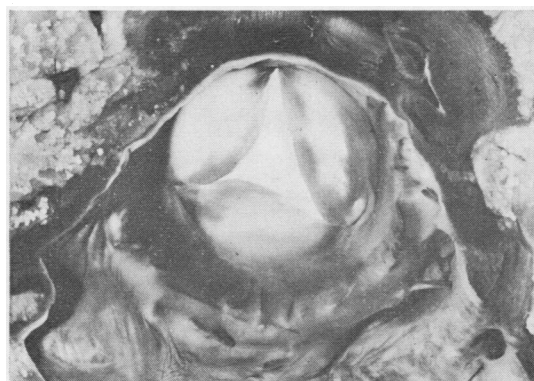


FIG. 5. Day 102. The cusps have progressively retracted and tricuspid valve incompetence is now present.



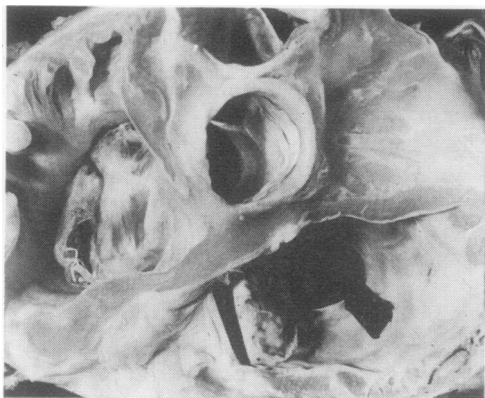


FIG. 6. Day 150. There is further cusp retraction and tricuspid valve incompetence.

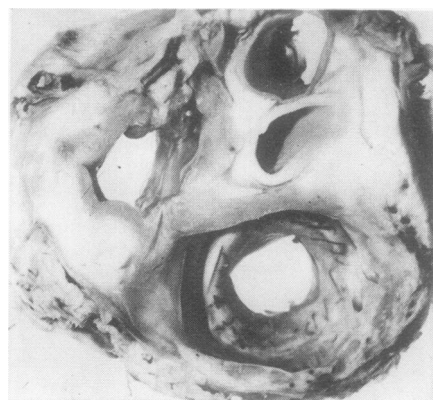


FIG. 7. Day 241. Total disappearance of the allograft valve cusp, leaving only the endothelial covered stent.

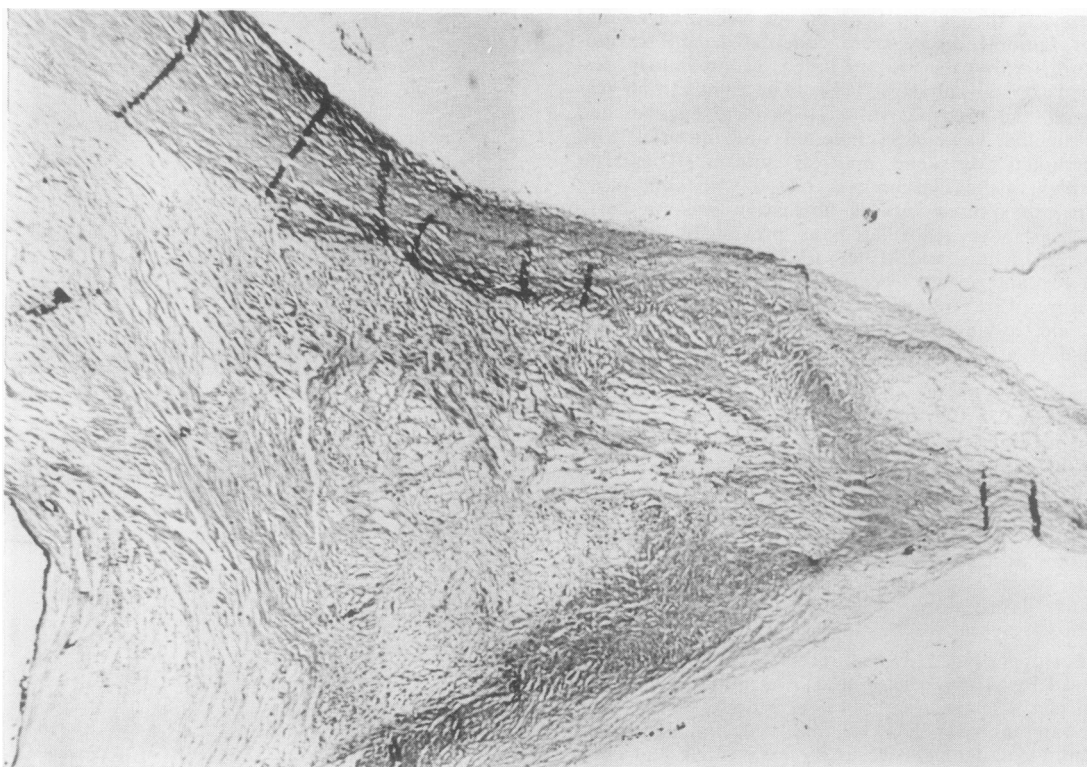


FIG. 8. There is foreshortening of the cusp, few nuclei, and an occasional fibroblast nucleus. The collagen is loose than normal. (H. and E.  $\times 28$ .)

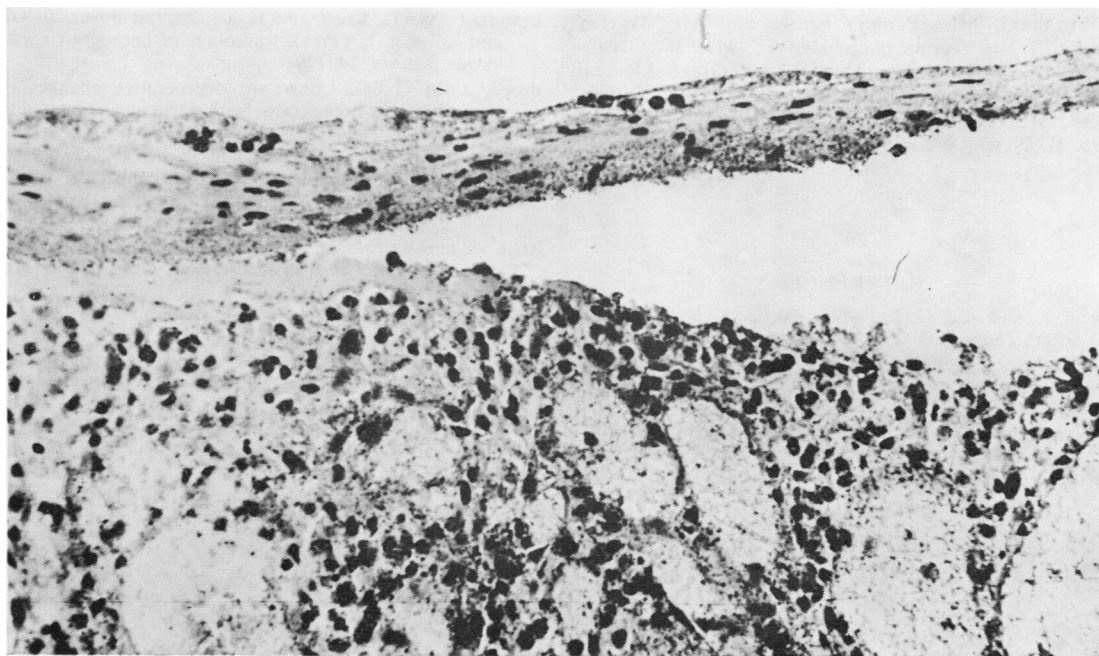


FIG. 9. At the cusp base, and on its pulmonary artery side, there is infiltration with polymorphs and macrophages. (Van Gieson  $\times 160$ .)

vomit (1), pneumothorax (1), and electrolyte imbalance (1). Necropsy showed that in these animals the valve cusps were competent (Fig. 3).

Four sheep lived respectively 23, 102, 150 and 241 days. The sheep that lived 23 days developed granulations of endocarditis on the cusps of the implanted valve and died from cusp obstruction (Fig. 4).

The remaining three sheep returned to pasture on the Otago University farm. There they slowly developed congestive heart failure. In each, necropsy confirmed that the allograft cusps had progressively shortened until, with no functioning cusp tissue remaining, severe tricuspid incompetence occurred. This progressive process had begun by day 102, as seen in Fig. 5, where the valve cusps, by shortening, had become incompetent.

By day 150 there had been further valve decline (Fig. 6) and the cusps were greatly foreshortened. By day 241 this process was complete, with total disappearance of cusp tissue, leaving just the endothelial-covered Dacron fabric over the Teflon stent and tricuspid incompetence (Fig. 7).

**HISTOLOGY** Sections were studied at day 150 by

standard light microscopy. These showed the cusp itself to be foreshortened and to be virtually acellular with an occasional fibroblast nucleus. The collagen structure was looser than normal. There was hyalinization of the cusp tip (Fig. 8). At the base of the cusp on the arterial side of the valve, in one very localized area, was an acute inflammatory reaction infiltrated with polymorphs. This lay over a mass of vascular granulation tissue with minimal collagen formation (Fig. 9). The appearances did not suggest the usual histological pattern of graft rejection but rather the standard reaction of a host to a foreign body.

#### CONCLUSION

It was concluded that, while stented fresh pulmonary allografts in sheep can function well immediately after insertion as tricuspid valve substitutes, by 100 days the cusps can become progressively shortened and incompetent, so that by day 240 no cusp tissue need remain.

We are grateful to Assoc. Professor Barbara Heslop, M.D., Department of Surgery, Otago Medical School, for her assessment of the macroscopical and microscopical examination of the specimens.

We thank Miss Pamela Fraser and Mr. Murray Cockerill for technical assistance; Mr. B. Glynn-Jones, of the Pathology Department, Otago Medical School for the preparation of the microscopic sections; Mr. Donald Weston for the photography; and Mrs. R. Newlove for secretarial services.

## REFERENCES

- Borrie, J., and Hill, G. L. (1968). Aortic valve allografts in sheep. *Thorax*, **23**, 230.
- , Lichter, I., and Miller, W. N. (1967). Experimental heart surgery in sheep. Alternating- and direct-current defibrillation. *J. surg. Res.*, **7**, 560.
- , and Redshaw, N. R. (1971). Pulmonary valve allografts used as tricuspid valve substitutes in sheep. *Proc. Univ. Otago med. Sch.*, **49**, 5.
- Brandt, P. W. T., Roche, A. H. G., Barratt-Boyes, B. G., and Lowe, J. B. (1969). Radiology of homograft aortic valves. *Thorax*, **24**, 129.
- Brock, Lord (1968). Long-term degenerative changes in aortic segment homografts, with particular reference to calcification. *Thorax*, **23**, 249.
- Morgan, J. F., Morton, H. J., and Parker, R. C. (1950). Nutrition of animal cells in tissue culture, I. Initial studies on a synthetic medium. *Proc. Soc. exp. Biol. (N.Y.)*, **73**, 1.
- Ross, D., and Yacoub, M. H. (1969). Homograft replacement of the aortic valve. A critical review. *Progr. cardiovascular Dis.*, **11**, 275.
- Smith, J. C. (1967). The pathology of human aortic valve homografts. *Thorax*, **22**, 114.
- Sugie, S., Watanabe, M., Aoki, T., Murakami, T., Tanabe, T., Takagi, M., Kubo, Y., Ohta, S., Misaka, K., Tomiyama, M., and Sugiyama, M. (1969). Clinical experience with supported homograft heart valve for mitral and aortic valve replacement. *J. thorac. cardiovascular Surg.*, **57**, 455.