

Methotrexate pneumonitis: case report and review of the literature

MICHAEL E. WHITCOMB, MARVIN I. SCHWARZ,
and DOUGLASS C. TORMEY

*Department of Medicine, Walter Reed General Hospital and Division of Medicine,
Walter Reed Institute of Research*

Methotrexate has been recommended for long-term therapy of an increasing number of diseases including acute lymphoblastic leukaemia, psoriasis and other chronic dermatoses, Wegener's granulomatosis, and multiple solid tumours. Acute pneumonitis is a known complication of methotrexate therapy. An additional case is reported and the clinical features of the 13 previous cases are summarized. Clinical and radiographic evidence of acute pneumonitis associated with eosinophilia and a rapid clearing with steroid treatment is the characteristic syndrome.

In 1968, Clarysse reported seven cases of acute pulmonary disease in patients receiving a maintenance dose of methotrexate for acute lymphoblastic leukaemia (Clarysse, Cathey, Cartwright, and Wintrobe, 1969). More recently, the development of acute pulmonary disease has been reported in patients receiving long-term methotrexate therapy for chronic skin diseases (Goldman and Moschella, 1971). This paper reports an additional example of methotrexate induced lung disease and summarizes the previously reported cases of this syndrome.

CASE REPORT

A 50-year-old man was admitted to Walter Reed General Hospital on 21 January 1971 with a mass in the left hilum which subsequently proved to be an oat-cell carcinoma at mediastinoscopy. The patient was treated with cobalt radiation therapy to the mediastinum and left hilum, and a course of cyclophosphamide and methotrexate, 40 mg twice a week. The mass regressed and the patient became free of symptoms. On 15 July 1971, the patient developed a non-productive cough, malaise, and a temperature rising to 101° F. Chest radiographs at this time revealed no acute changes. He was seen as an out-patient and was started on tetracycline, 250 mg every six hours. Despite this treatment, the fever and cough persisted, he noted progressive shortness of breath and marked fatigue, and was admitted to hospital on 31 July 1971. Physical examination at that time revealed a patient in acute respiratory distress with a temperature of 102° F and a pulse rate of 110/minute. There was no obvious cyanosis, clubbing or jugular

venous distention. Coarse crepitations were heard over the lower lung fields. The remainder of the physical examination was negative. A chest radiograph revealed diffuse mottling which was most prominent at the bases (Fig. 1). A Gram stain and acid-fast stain of the sputum showed no pathogenic organisms and blood cultures were sterile. The white blood cell count was 7800/mm³ with 22% eosinophils. The haemoglobin, haematocrit, platelet count, blood urea, electrolytes and liver function tests were within normal limits. It was felt that the patient's illness was consistent with methotrexate induced pneumonitis, methotrexate was therefore withdrawn and prednisone, 60 mg per day, was given. Within 48 hours, the patient's symptoms had improved and the fever had settled. Six days after admission, the chest radiograph was clear (Fig. 2) and the eosinophil count had returned to normal. Steroids were then withdrawn and methotrexate therapy was resumed without recurrence of symptoms or radiographic changes.

DISCUSSION

The course of this patient's illness was consistent with that seen in the majority of cases of methotrexate pneumonitis previously reported. The onset of cough, fever, dyspnoea, progressive bilateral pulmonary mottling, and eosinophilia, five and one-half months after the institution of methotrexate therapy, is characteristic. The response to steroids but not to antibiotics is also in keeping with this diagnosis.

A total of 13 cases of methotrexate pneumonitis have been reported previously and the relevant clinical features are summarized in the Table. Ten

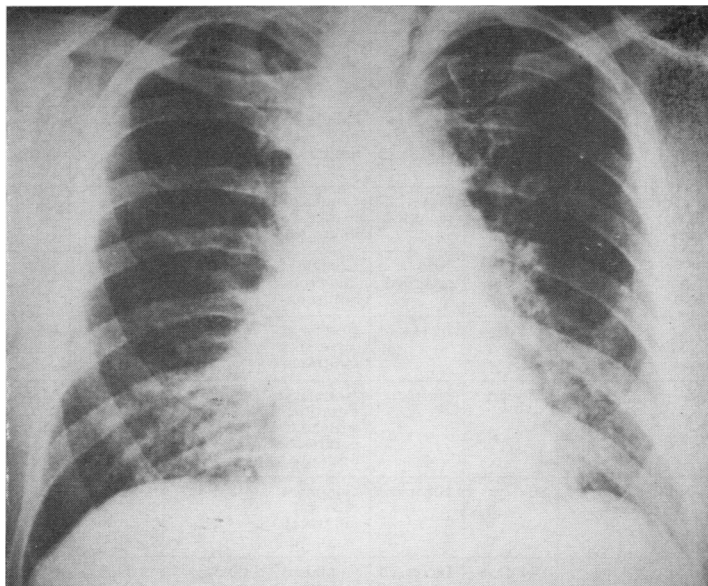


FIG. 1. *Chest radiograph demonstrating diffuse pulmonary mottling, most prominent in the lower and middle lobes.*

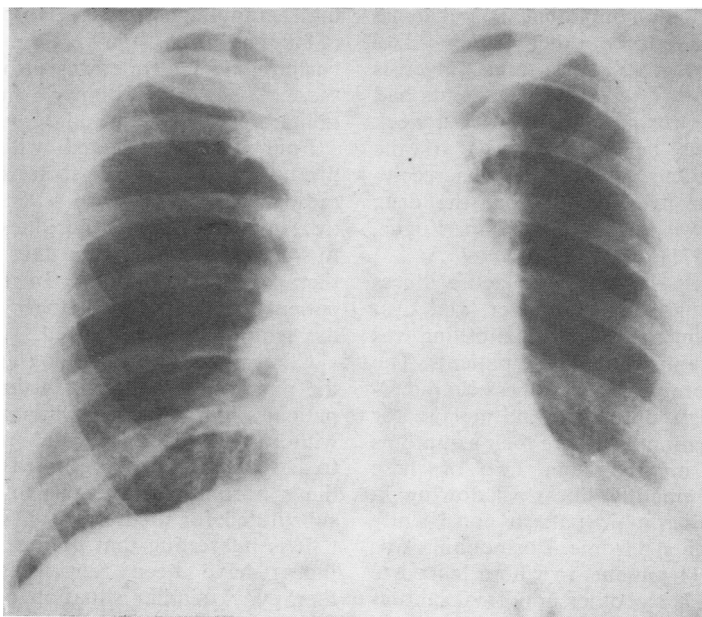


FIG. 2. *Chest radiograph taken one week later demonstrating clearing of the mottling.*

TABLE
CLINICAL SUMMARY OF REPORTED CASES OF METHOTREXATE PNEUMONITIS

Case	Disease	Methotrexate Dose	Onset of Symptoms	Eosinophil Count	Chest Radiograph	Duration of Symptoms	Steroid Therapy	Comment
1-7 Clarysse <i>et al.</i> (1969)	Acute lymphocytic leukaemia	13-20 mg/m ² twice weekly	12-100 days	Increased in five cases	Confluent bilateral infiltrates	10-40 days in 6 cases	No	One patient had persistent infiltrates and recurrent symptoms for one year
8: Schwartz and Kajani (1969)	Acute lymphocytic leukaemia	25 mg twice weekly	150 days	Not recorded	Confluent bilateral infiltrates	6 days	Yes	
9: Schwartz and Kajani (1969)	Acute lymphocytic leukaemia	25 mg twice weekly	80 days	Not recorded	Confluent bilateral infiltrates	4 days	Yes	
10: Robertson (1970)	Acute lymphocytic leukaemia	21 mg/m ² twice weekly	196 days	Increased	Confluent bilateral infiltrates	6 days	Yes	Clinical relapse when prednisone was decreased to 10 mg
11: Filip <i>et al.</i> (1971)	Psoriasis	25 mg weekly	5 years	Normal	Nodular infiltration with hilar & paratracheal adenopathy	21 days	No	Methotrexate was discontinued but syndrome recurred on thioguanosine
12: Goldman and Moschella (1971)	Pemphigus vulgaris	50 mg weekly	90 days	Normal	Confluent bilateral infiltrates	8 days	Yes	Patient was on prednisone when syndrome occurred. Syndrome responded to supplemental doses of hydrocortisone
13: Goldman and Moschella (1971)	Mycosis fungoides	50 mg weekly	42 days	Increased	Confluent bilateral infiltrates	40 days	No	Methotrexate was discontinued during acute syndrome and relapse occurred when it was restarted
14	Oat-cell carcinoma of lung	40 mg twice weekly	165 days	Increased	Confluent bilateral infiltrates	6 days	Yes	

of the patients had acute lymphoblastic leukaemia in remission and the three other patients had psoriasis, pemphigus vulgaris, and mycosis fungoides respectively. Twelve of the patients had been receiving methotrexate once or twice a week for 12 to 196 days before the onset of the pulmonary disease. One patient had been receiving this therapy for five years before the drug induced syndrome was recognized (Filip, Logue, Harle and Farrar, 1971).

Ten of the patients developed an acute illness characterized by cough, malaise, fever, and dyspnoea. Bilateral confluent pulmonary mottling was noted in the radiographs of all these patients. The other three had a more prolonged illness characterized by chronic cough, dyspnoea, and malaise for several weeks to five months before their symptoms were attributed to methotrexate. Two of these patients had predominantly linear shadowing in contrast to the radiographic pattern consistently observed in the acute syndrome. Eosinophilia was present in 7 of the 11 patients in whom leucocyte counts were recorded. No other abnormal laboratory findings were consistently noted.

Lung biopsies were performed in 3 of the 13 patients. Two of the biopsies revealed non-caseat-

ing granulomas and lymphocytic infiltrates (Clarysse *et al.*, 1969; Filip *et al.*, 1971); an eosinophilic infiltrate was also present in one of these. The third biopsy showed bronchiolitis obliterans (Goldman and Moschella, 1971).

Four patients treated with steroids showed prompt resolution of their symptoms and the radiographic changes. In seven of the patients not treated with steroids, the illness abated within 10 to 40 days despite the fact that methotrexate therapy was continued. In the remaining two patients, radiographic changes persisted long after the symptoms had resolved.

Clinical relapse following initial resolution of the pneumonia occurred in three patients. In one patient, this happened while steroids were being withdrawn and in a second patient when methotrexate treatment was resumed. In the third patient the syndrome recurred when thioguanosine was substituted for methotrexate (Filip *et al.*, 1971).

It is interesting that both an acute and chronic illness have been reported with methotrexate therapy. A similar situation occurs with the pulmonary disease associated with nitrofurantoin therapy. The patient with the most prolonged reaction to methotrexate had been receiving a lower

weekly dose than any of those with the acute syndrome. It is conceivable that the cumulative concentration of the drug is an important factor in determining the character of the pulmonary disease that develops.

The subject of this report is the fourteenth case of methotrexate induced pulmonary disease reported in the literature to date and the fifth such patient treated with steroids. In each instance when steroids have been used, prompt resolution has occurred. Many of the patients who develop this syndrome will have serious underlying diseases and, in this setting, the drug-induced illness may easily be overlooked or attributed to pneumonia. Prompt recognition of methotrexate pneumonitis and treatment with steroids will result in dramatic resolution of the illness within several days.

REFERENCES

- Clarysse, A. M., Cathey, W. J., Cartwright, G. E., and Wintrobe, M. M. (1969). Pulmonary disease complicating intermittent therapy with methotrexate. *J. Amer. med. Ass.*, **209**, 1861.
- Filip, D. J., Logue, G. L., Harle, T. S., and Farrar, W. H. (1971). Pulmonary and hepatic complications of methotrexate therapy of psoriasis. *J. Amer. med. Ass.*, **216**, 881.
- Goldman, G. C., and Moschella, S. L. (1971). Severe pneumonitis occurring during methotrexate therapy. *Arch. Derm.*, **103**, 194.
- Robertson, J. H. (1970). Pneumonia and methotrexate. *Brit. med. J.*, **2**, 156.
- Rosenow, E. C., DeRemee, R. A., and Dines, D. E. (1968). Chronic nitrofurantoin pulmonary reaction. *New Engl. J. Med.*, **279**, 1258.
- Schwartz, I. R., and Kajani, M. K. (1969). Methotrexate therapy and pulmonary disease. *J. Amer. med. Ass.*, **210**, 1924.