

'Vineyard sprayer's lung': a new occupational disease

J. CORTEZ PIMENTEL AND FERNANDO MARQUES

From I.A.N.T. (Department of Pathology and Thoracic Surgery of Sanatorio D. Carlos I) and Institute of Pathology, Faculty of Medicine, University of Lisbon, Portugal

The mildew of the vineyards is prevented by the use of sprays with a solution of copper sulphate neutralized with hydrated lime. The inhalation of this solution while spraying may give rise to predominantly interstitial pulmonary lesions which may lead to respiratory insufficiency. These lesions, which were experimentally reproduced in guinea-pigs, have a well-defined histological picture characterized by three stages—intra-alveolar desquamation of macrophages, formation of predominantly histiocytic granulomas in the septa, and the healing of these lesions generally under the form of fibro-hyaline nodules very similar to those found in silicosis. These lesions contain variable amounts of copper. The pathogenesis of these lesions and the possibility of their regression when the offending agent is removed are discussed; and the value of lung biopsy and the necessity of protecting these workers are stressed.

Mildew is one of the vineyard's most serious diseases. There are, as yet, no ways of treating it, but it can be avoided. Perrey (1884) noted the preventive action of copper salts and Millardet and Gayon (1885) developed the mixture known as Bordeaux Mixture, still widely used in France, Portugal, and southern Italy, although highly efficient organic and organo-cupric compounds are now available.

Bordeaux Mixture is a 1%, 1.5%, or, rarely, 2% solution of copper sulphate neutralized with hydrated lime. The time of year at which the treatment of the vineyards is undertaken and the number of 'treatments' given depend on various factors, particularly those related to weather conditions. In Portugal, as a rule, six to eight 'treatments' are given, but in some parts of the country there may be as many as 12 to 14 each season.

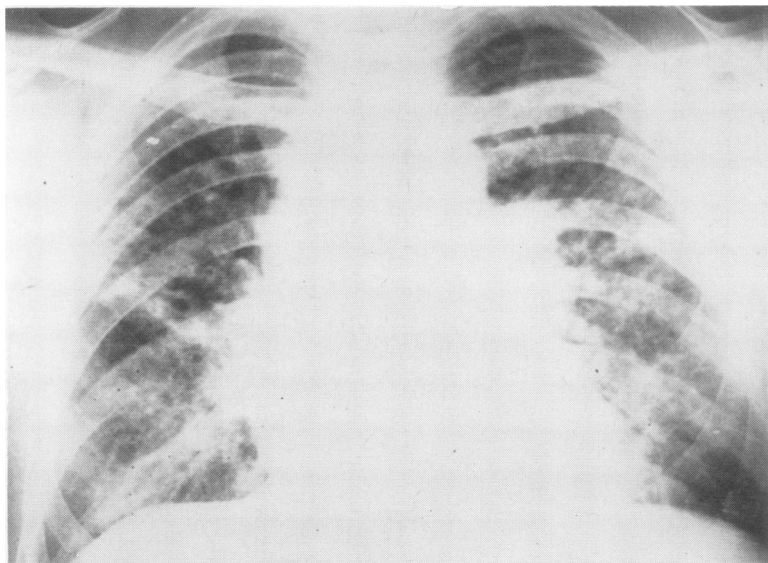


FIG. 1. Case 1. Chest film showing diffuse, bilateral, reticulo-nodular pulmonary lesions.

The Bordeaux Mixture is sprayed on the vines using either manual sprayers or, in mechanized vineyards, atomizers or other low-flow apparatus.

The purpose of this paper is to show that the inhalation of Bordeaux Mixture while spraying the vineyards can cause changes in the pulmonary interstitial tissues which may lead to respiratory insufficiency. These lesions have a clearly defined and characteristic histological picture which can easily be identified by lung biopsy: we have reproduced these changes experimentally in the guinea-pig.

CASE REPORTS

CASE 1 A 35-year-old male rural worker, who for many years had sprayed vineyards and cleaned the tartar from wine presses, was admitted to the Thoracic Surgery Centre of the Sanatorio D. Carlos I (IANT) in October 1965 for investigation of diffuse lung lesions (Fig. 1). A year previously, tuberculosis had been diagnosed at mass radiography and the patient had been treated for nine months with streptomycin, isoniazid, and PAS. There was considerable improvement but not complete clearing on the radiograph, and, as his sputum had always been persistently negative for tubercle bacilli, surgical lung biopsy was proposed.

The patient's general condition was good, but he developed dyspnoea on moderate exertion. Bronchoscopy was non-contributory. His blood count and sedimentation rate were within normal limits. Lung function tests showed some restriction and moderately decreased ventilatory parameters. At thoracotomy, the right lung showed extensive blue patches in which nodules and bands could be palpated due to their greater consistency in relation to the surrounding lung. The biopsy specimen showed that these corresponded to blue nodules and bands or to greyish-white fibrous-appearing areas. Microscopically the lesions had a focal distribution and corresponded to three different patterns, with all transitions between them—a varying number of alveoli filled with desquamated macrophages (Figs 2 and 3), granulomas in the alveolar septa (Fig. 2), and fibro-hyaline nodules which seem to be the scars of the granulomas (Figs 4 and 5). The intra-alveolar macrophages frequently form large sheets, and a yellowish-brown granular material is found in their cytoplasm. This does not give the haemosiderin reactions—Perls' technique—but is positive for copper techniques—rubeanic acid (Fig. 6) and benzidine.¹ The alveolar septa in these areas are either infiltrated by lymphocytes, plasma cells, or histiocytes, and a number of fibroblasts, or are more or less fibrotic and, in some areas, hyalinized.

The granulomas develop in the septa and form

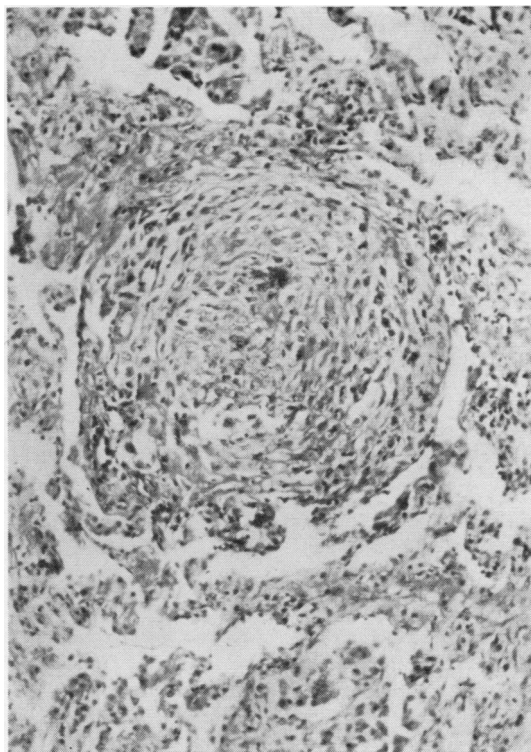


FIG. 2. Case 1. Septal granuloma around which some alveoli are filled with desquamated macrophages and with a slight inflammatory infiltration of the septa. H. and E. $\times 72$.

rounded, well-limited nodules made up of histiocytes frequently containing the material already mentioned, and a few lymphocytes and plasma cells. Sometimes a few foreign body giant-cells containing copper or cholesterol inclusions can be seen in the granulomas. Finally, all transitions between these granulomas and their fibro-hyaline scars made up of whorls of collagen fibres concentrically placed and very similar to 'silicotic nodules' can be found (Fig. 5). Polarized light shows no silica in these nodules and chemical studies show no increase of this substance in the lung. Some of the cicatricial nodules contain appreciable quantities of the copper-containing material mentioned. Some of the sections show large fibro-hyaline plaques due to the conglomeration of the cicatricial nodules with notable collagen formation (van Gieson's technique).

Microscopic study of the less involved areas of the lung shows small dispersed foci, similar to those described, around the bronchioli and vessels and sometimes in the interlobular septa.

During the four months the patient was in hospital and under observation, dyspnoea disappeared and

¹Copper salts combine with rubeanic acid (dithio-oxamide) to give a deep greenish-black inner complex salt (chelate) of the di-imido form of rubeanic acid, and also react with benzidine in the presence of alkali cyanides to give benzidine blue (Pearse, 1960).

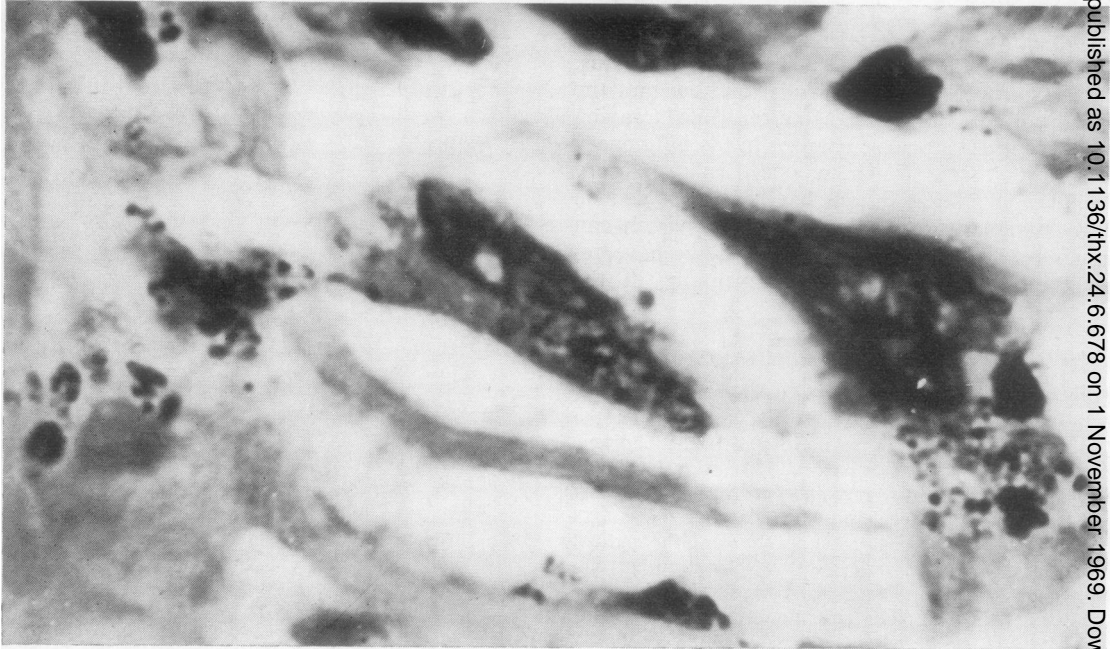


FIG. 3. A detail of the alveolar macrophages shown in Fig. 2, stained by rubanic acid and contrasted with carmine.

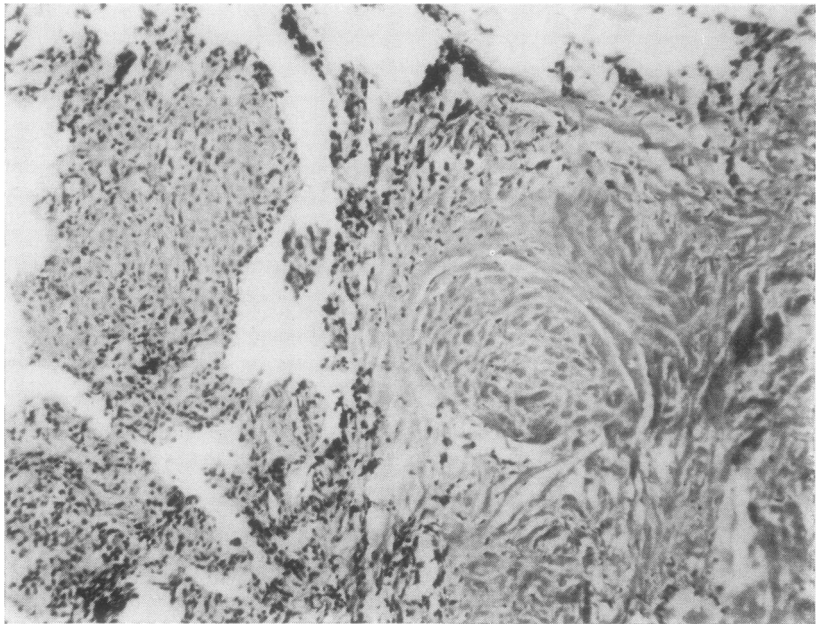


FIG. 4. Case 1. Extensive healing of the lesions, partially in the form of a fibrohyaline nodule. In the left half a septal granuloma is still visible. H. and E. $\times 75$.

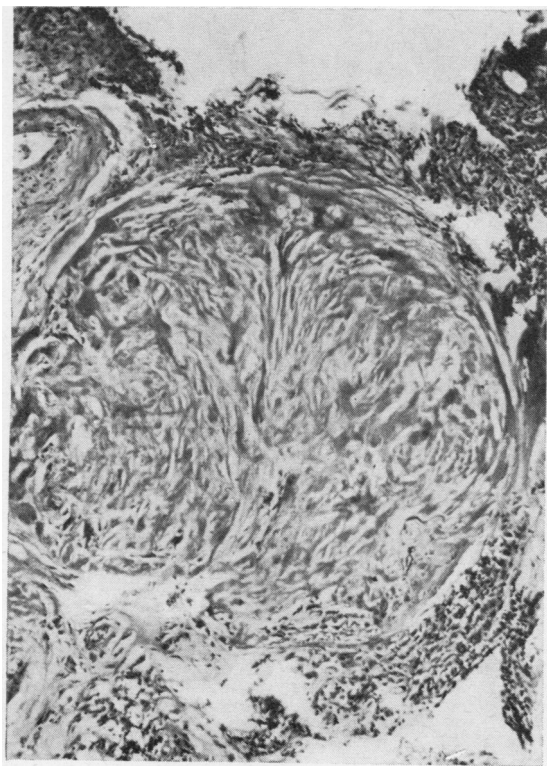


FIG. 5. Case 1. Various fibro-hyaline nodular scars very similar to 'silicotic nodules'. H. and E. $\times 69$.

there was considerable radiological improvement. Lung function tests showed a slight improvement of ventilation.

CASE 2 A 36-year-old rural worker, whose main occupation was vine spraying, was admitted to the Thoracic Surgery Centre of the Sanatorio D. Carlos I (IANT) for weakness, loss of weight, and cough productive of a thick, yellowish sputum. About 14 months before admission he had complained of the same symptoms and a chest radiograph led to the diagnosis of tuberculosis, for which he was treated in a sanatorium for 10 months with streptomycin, isoniazid, and PAS, and slowly improved. On returning to his working conditions the symptoms soon reappeared.

The patient was a thin man with a completely negative physical examination. His sputum was negative for tubercle bacilli, as it always had been. The chest film showed increased pulmonary markings and an area of consolidation in the right upper lobe, considered to be a tuberculoma (Fig. 7). Bronchoscopy was negative, as were the bronchial secretion for both tubercle bacilli and tumour cells. The blood count was within normal limits and the sedimentation rate

was never above 35 mm./hour. Right upper lobectomy was done and blue areas were seen on the pleural surface of the lung, especially of the upper lobe.

Pathological examination of the lobe showed numerous blue foci, in plaques, one of which was 2.5 cm. in its largest diameter and corresponded to the consolidation seen on the radiograph. There was also a fine, well-defined nodulation, standing out on the cut surface of the lung (Fig. 8). Large sheets of fibrosis and marked thickening of the reticulum were seen in some areas. Microscopy showed, alongside the more diffuse lesions made up of large cicatricial foci preserving or destroying alveolar structure, various sized foci presenting three main patterns—areas of desquamative pneumonia, granulomas (Fig. 9), and fibro-hyaline scars. The desquamated cells form sheets and contain a granulomatous, yellowish-brown material, Perls' negative, but giving the histochemical reactions for copper—rubeanic acid and benzidine. The septa that limit these sheets are partly infiltrated with lymphocytes, plasma cells, and fibroblasts and are partially transformed into fibrous bands, sometimes partially or totally hyalinized. The granulomas are rounded and made up of histiocytes, fibroblasts, and some lymphocytes and plasma cells. The majority of the histiocytes have within their cytoplasm the same material seen in the macrophages. All transitions were seen between these granulomatous foci and the nodular, well-defined scars made up of concentrically disposed bands of hyalinized fibrous tissue. These nodules do not contain silica and have plentiful copper-containing material. Some of them are partially broken down or contain small calcium deposits.

EXPERIMENTAL OBSERVATIONS

MATERIAL AND METHODS Although there seemed to be no doubt as to the close relationship between this pulmonary condition and the inhalation of the product with which the patients worked, we tried to confirm this experimentally using Bordeaux Mixture, wine tartar, and sulphur, the latter to study the possibility of a common pathogenic mechanism.

Four lots of six guinea-pigs each were placed in poorly ventilated glass cages. One was used as control and two were made to inhale finely pulverized Bordeaux Mixture and a solution of wine tartar using a Flit spray-gun. This was done three times a day, so that the atmosphere of the cage was completely saturated with the spray. The Bordeaux Mixture was prepared in the proportion of 1.5 kg. of hydrated lime for 100 litres of water and the tartar solution in the concentration of 150 g. for one litre of water. The animals in the fourth lot were submitted three times a day to sulphur dioxide fumes produced by burning 'sulphur wicks', such as are used for the disinfection of the wine vats, of which 5 cm. long pieces were used.

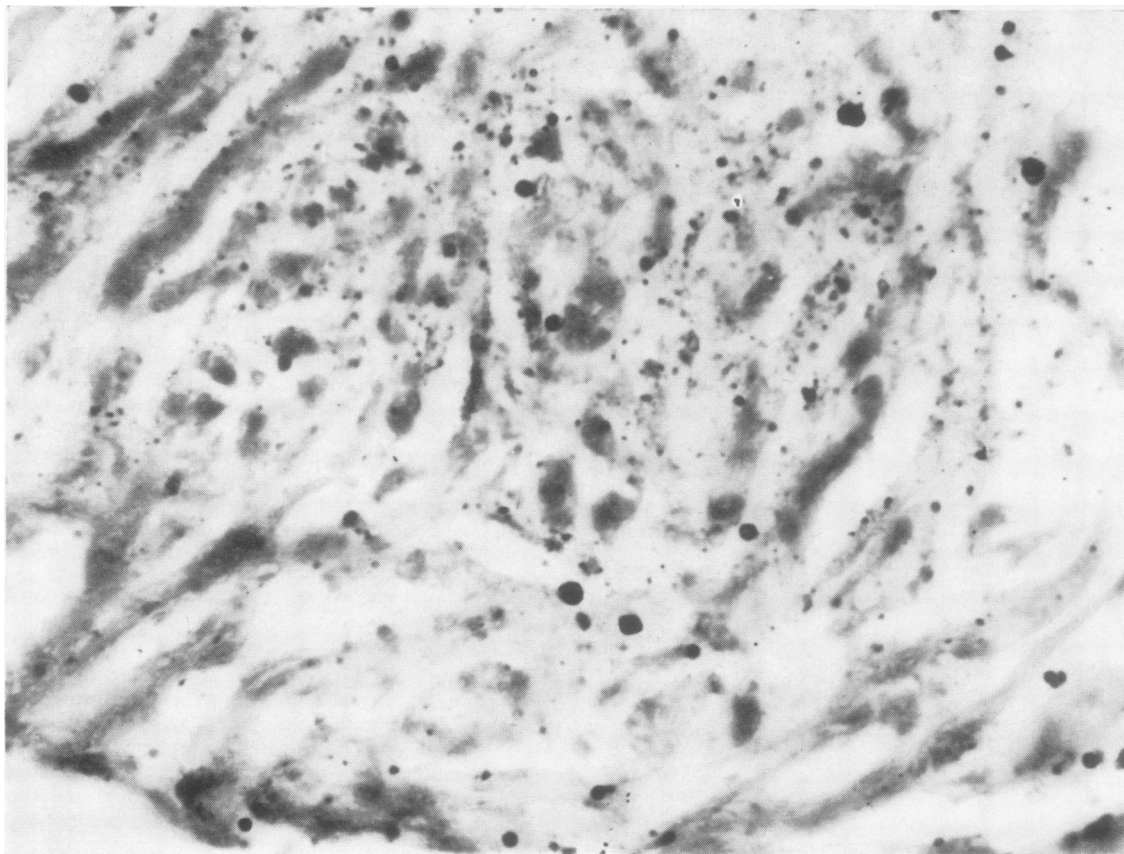


FIG. 6

FIG. 6. *Case 1. Plentiful deposition of copper in a fibro-hyaline nodular scar. (Rubeanic acid technique using carmine as a contrast.)* $\times 320$.

FIG. 7. *Case 2. Chest radiograph showing a definite increase in the pulmonary markings in both lungs and a segmental condensation in the right upper lobe.*

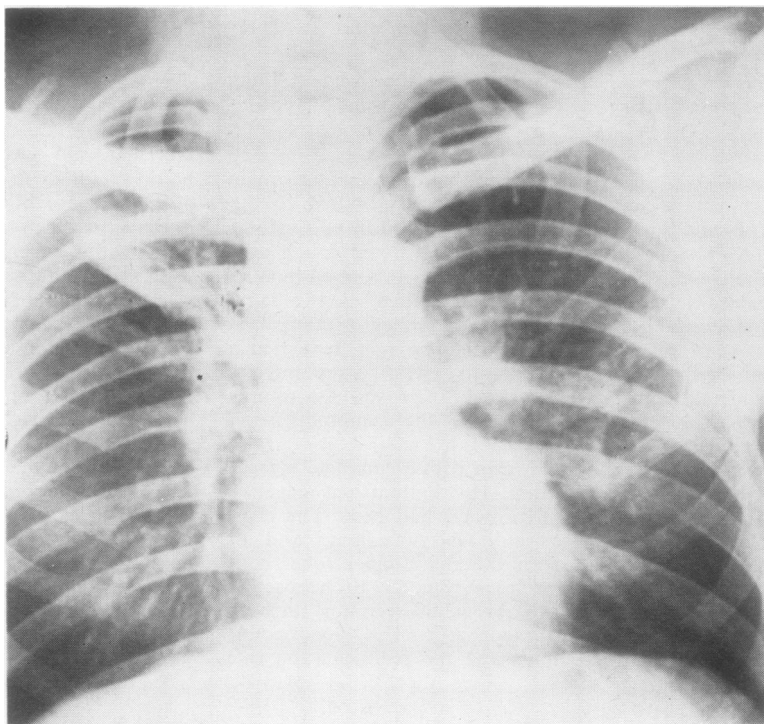


FIG. 7

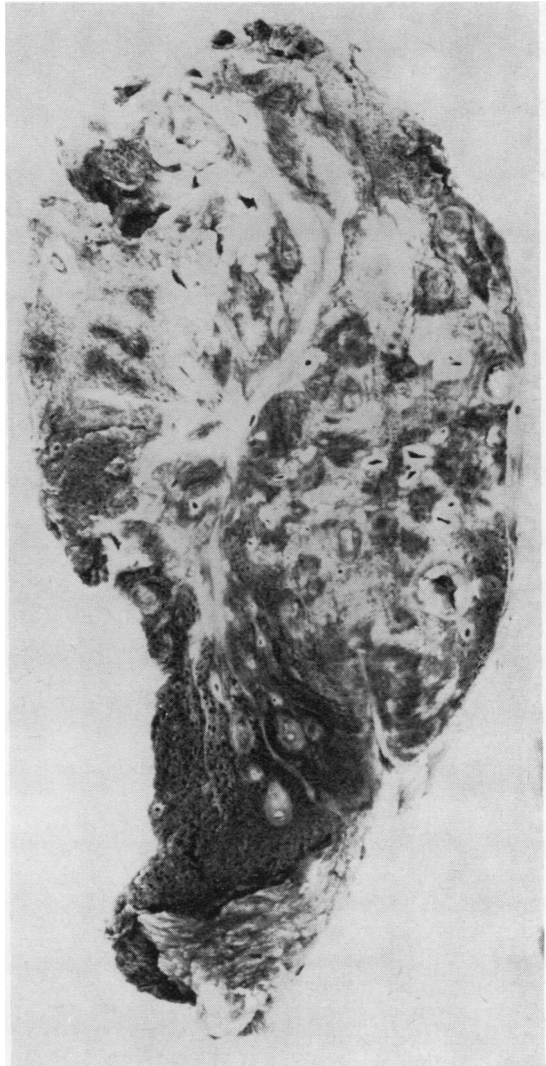


FIG. 8. Case 2. Section of part of the resected lobe shows micronodular lesions and extensive scars.

The experiment was started on 16 April 1968 and ended on 30 October of the same year. The guinea-pigs were radiographed at the beginning of the experiment, at the second month, at the end of the experiment, and two of them three months later. Only the animals that inhaled the Bordeaux Mixture showed any radiographic changes, and four animals of this lot were sacrificed at the end of the experiment and the other two three months after suspension of the inhalations.

The pulmonary lesions were studied by the methods of fixation and staining currently employed in human

cases—fixation in 10% neutral formalin and staining with haematoxylin and eosin, van Gieson, reticulin, periodic acid-Schiff, von Kossa, Gram, and Perls' stains, and rubeanic acid and benzidine for copper. To study the lungs in which the lesions had regressed in greater detail, fine sections no thicker than 1.5μ were used.

RESULTS The lungs of the animals exposed to sulphur dioxide fumes showed scanty intra-alveolar cells containing brownish-yellow or dark

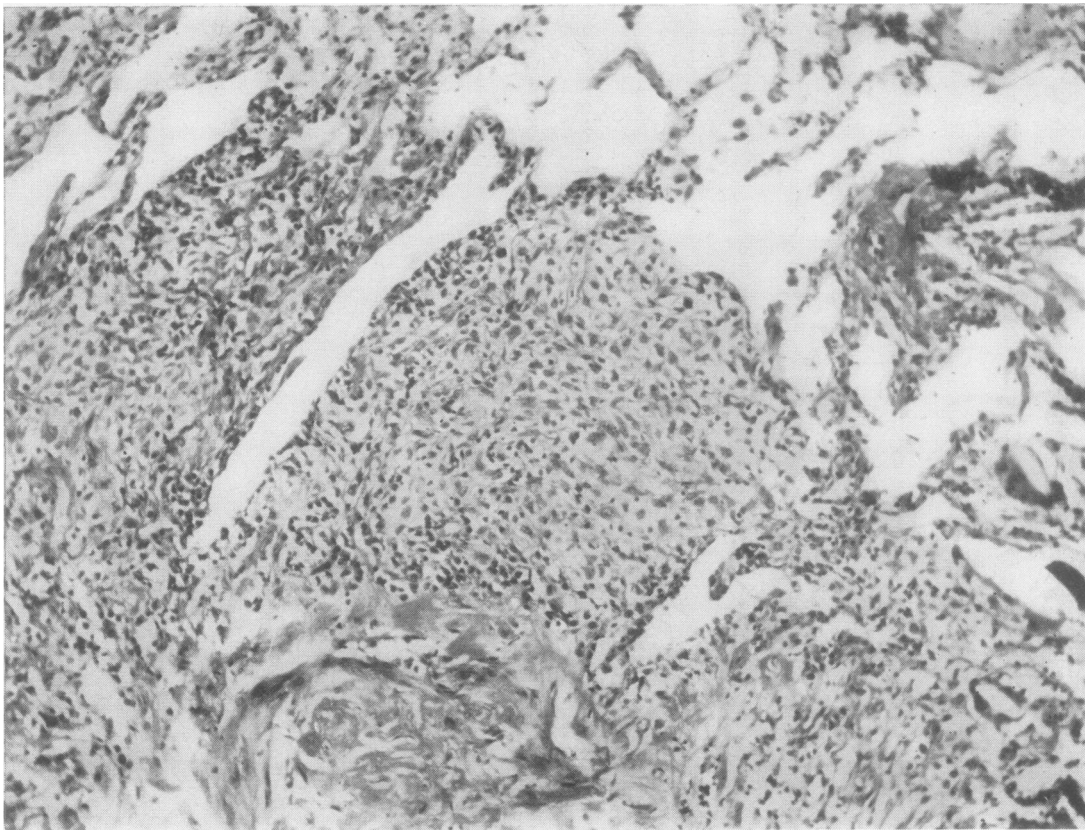


FIG. 9. Case 2. Septal granulomas. In the lower half one of these lesions is already in an advanced stage of healing and hyalinization. H. and E. $\times 67$.

brown granules which stained by the performic acid-alcian blue method, indicating the presence of sulphur-containing amino-acids. The lungs of the animals treated with the wine tartar spray showed occasional inter-alveolar cells bearing a brownish-yellow or dark brown granular pigment which gave the histochemical reactions of copper. Four of the six animals treated with the Bordeaux Mixture showed micronodular lesions both on chest radiography and on macroscopic examination of the lungs. In three of these, the nodules corresponded to foci involving a variable number of alveoli filled with plugs of desquamated macrophages with inclusions of a substance rich in copper (Figs 11 and 13). Histiocytes, lymphocytes, plasma cells, and a variable number of fibroblasts infiltrated the septa (Fig. 10). In some of the foci small hyaline deposits were seen. In the fourth guinea-pig of this lot, besides the lesions described, small histiocytic granulomas (Fig. 10) were seen in the septa with the appearance of fibro-hyaline scars similar to those found in human cases (Fig. 12).

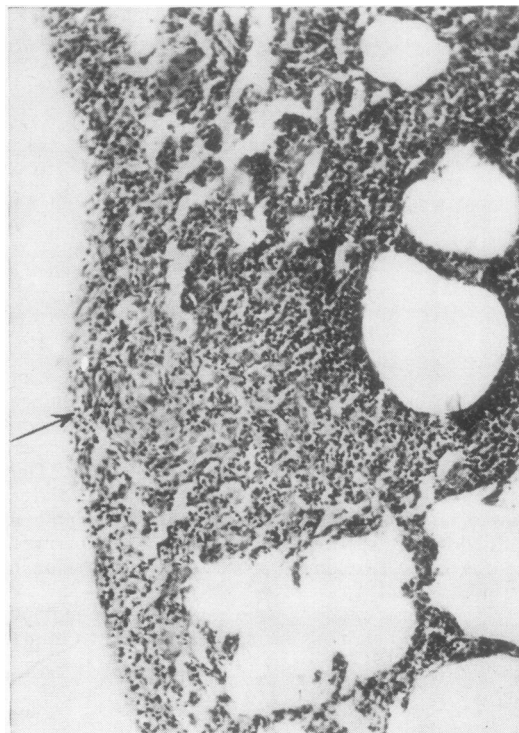

FIG. 10. Lesions produced experimentally in the guinea-pig by inhalation of sprayed Bordeaux Mixture. Intra-alveolar desquamation of macrophages and septal granulomas (arrow). H. and E. $\times 76$.

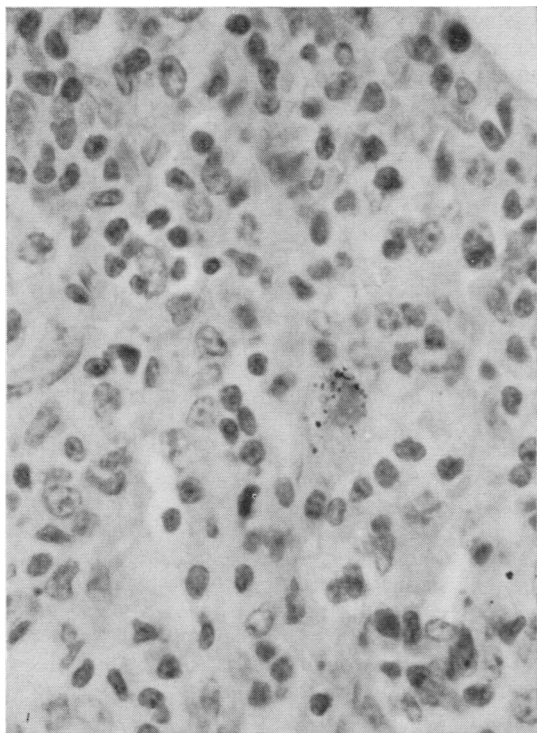


FIG. 11. Detail of Fig. 10 (macrophages with inclusions of a substance rich in copper). *H. and E.* $\times 333$.

In the animals sacrificed three months after cessation of the exposure, an apparently total regression of the lesions was noted on the radiograph. Microscopy of the lungs showed fewer changes than in those sacrificed three months earlier, but it revealed fibrous bands, small groups of alveoli filled with macrophages, hyaline deposits often vaguely nodular, and, especially, small areas of condensation of the reticulin fibres of the septa in regions apparently not involved when using the routine stains.

DISCUSSION

The two patients reported had spent most of their working time spraying the vineyards. One was apparently asymptomatic and diagnosed on mass miniature radiography survey and the other had evident respiratory symptoms. Both were initially considered tuberculous and thoracotomy was done because of antituberculous therapy clearing was not complete and because of persistently negative sputum for tubercle bacilli.

Thoracotomy showed the intensely blue aspect of the visceral pleura which could not be explained by known pathological conditions. The lesions had a focal distribution and their density varied in different areas. The histological picture was well defined and seemed to progress through three principal stages—desquamation, intra-alveolar macrophages (Fig 2), histiocytic granulomas in the inter-alveolar septa, and the scars of these lesions, the greater part of which showed as fibro-hyaline nodules somewhat similar to those found in silicosis (Figs 4 and 5). The granulomas sometimes contain foreign body giant-cells and rarely are of sarcoid type'. The nodular scars may show areas of softening and calcification. The presence of the yellowish-brown or yellowish-green material giving copper histochemical reactions is notable.

The results of the pulmonary function tests in both cases agree with the predominantly interstitial localization of the pulmonary damage.

Experimental reproduction in the guinea-pig of lesions similar to those found in man confirmed

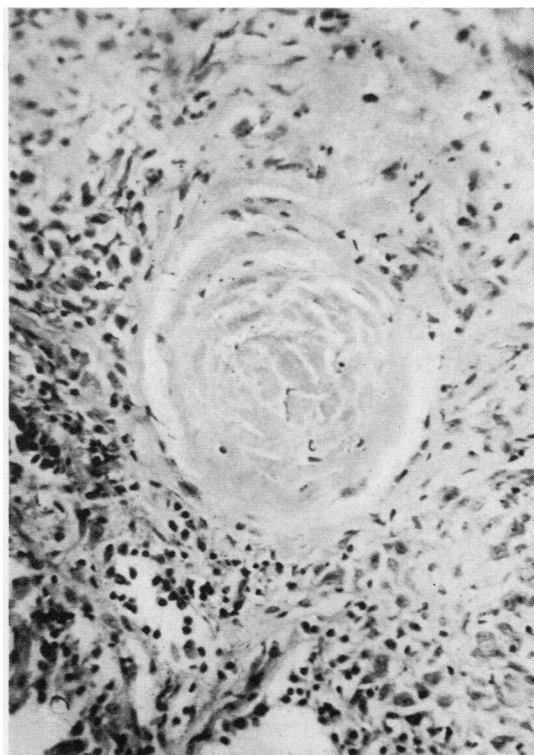

FIG. 12. Fibro-hyaline nodular scar seen in one of the guinea-pigs. *H. and E.* $\times 88$.

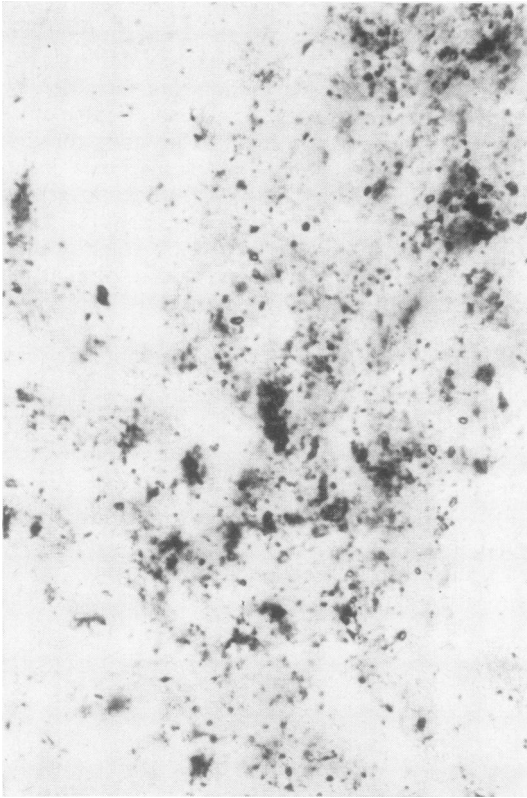


FIG. 13. Experimentally produced lesions. Large deposits of copper, largely inside the macrophages that fill the alveolar lumina. Rubenic acid. $\times 110$.

the relationship between the inhalation of Bordeaux Mixture and the disease (Figs 10, 11, and 12).

However, no human or experimental data permitted us to conclude that the copper contained in the inhaled mixture was responsible for the lesions or that these were due to the sulphur dioxide or to the sulphurous or sulphuric acids formed at tissue level by reduction of copper sulphate.

We recently examined a lung biopsy of a patient with miliary type lesions on the chest radiograph, who worked in the disinfection of wine casks using burning 'sulphur wicks' and thus inhaling sulphur dioxide. We noted that, although the lesions were macroscopically blue, microscopically they were quite different. In this case there was a sarcoid-type granuloma with extensive healing, hyalinization, and calcification but with no tendency to form fibro-hyaline scars characteristic of the two cases reported.

Among the morphological aspects of 'vineyard sprayer's lung' we wish to emphasize the great similarity between the scars and 'silicotic nodules' because of the possible confusion between the two conditions in biopsy specimens if polarized light is not systematically used in these cases.

Another important aspect of 'vineyard sprayer's lung' is the possibility of the clearing of part of the lesions if the patient is removed from contact with the offending agent. This fact was very evident in the experimental disease and was also noted in the human cases, although less markedly. We believe this to be definitely related to the extension and degree of collagenization, as has been noted in other conditions of this type. Figures 14 and 15, made from a tridimensional reconstruction in acrylic material of serial sections of small areas of the lungs of the two reported cases, gave us, within certain limits, the idea of the focal character of the lesions and their density, as well as an opportunity to evaluate their regressive possibilities by contrasting the lesions with and without collagenization. It should also be noted that the regression of the lesions is less marked than radiology would lead us to suppose. This is particularly true of the animal which seemed to show complete clearing yet had localized widening of the alveolar septa.

Another fact that should be stressed is that the inhaled substance seems to keep on acting long after the patient has been removed from contact with it. Thus, in the first case, the patient had not done any spraying for over a year, yet microscopy showed many clusters of intra-alveolar macrophages and septal granulomas with little scarring and abundant deposits of copper.

We have not had the opportunity of examining large numbers of vineyard sprayers to try to determine the incidence of the disease, but we believe that only a limited number of workers develop lung changes. This fact, together with the experimental data, lead us to suggest that for the disease to appear, there must exist a 'patient factor', which may be of an immunological nature, besides the 'chemical factor'. At present we believe that only the existence of a possible hypersensitivity mechanism can connect the lesions we describe in this study with other granulomatous occupational diseases of the lung, such as farmer's lung (Emanuel, Wenzel, Bowerman, and Lawton, 1964; Pepys, Longbottom, and Jenkins, 1964; Seal, Hapke, and Thomas, 1968), maple bark disease (Emanuel, Lawton, and Wenzel, 1962), and bagassosis (Jamison and Hopkins, 1941). We have no personal experience

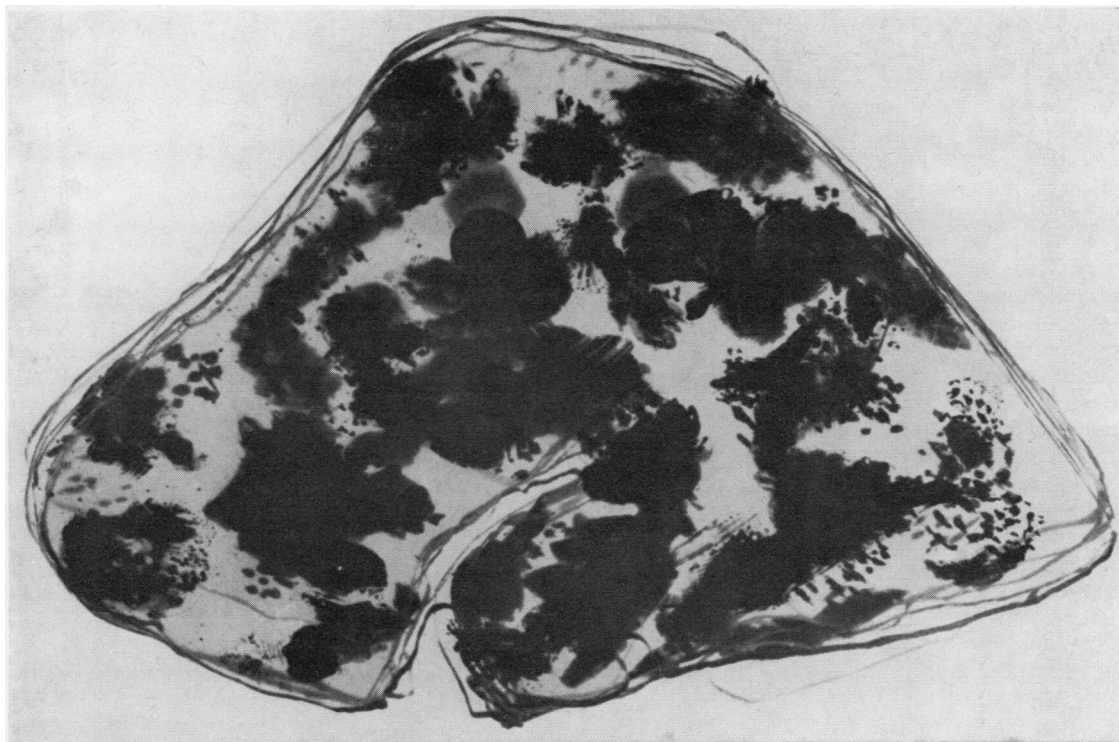


FIG. 14. *Case 1. Tridimensional reconstruction in acrylic material of serial histological sections. The black areas correspond to collagenized lesions and the dotted ones to changes capable of regression.*

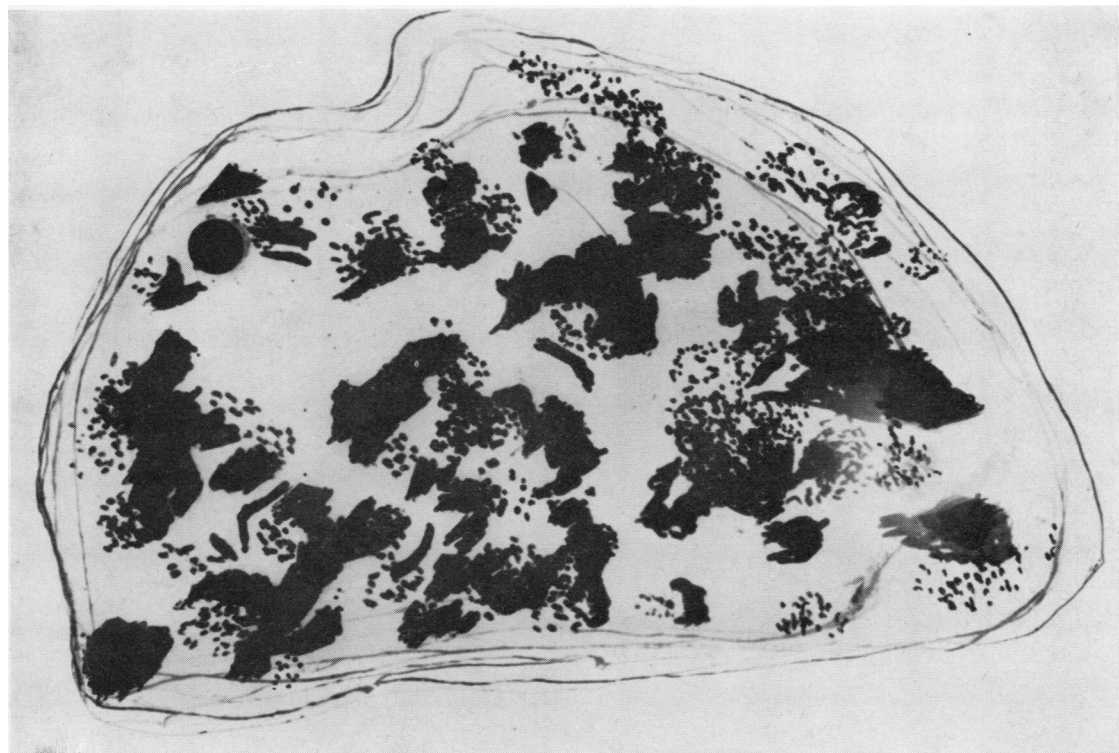


FIG. 15. *Case 2. Tridimensional reconstruction similar to that shown in Fig. 14.*

these diseases. However, we are interested at the moment in the pathology of suberosis, a disease that seems to be similar to those mentioned and which is quite common in Portugal (Cancellata, 1955; Horta and Cancellata, 1957; Cancellata, 1959; Avila, Teles de Araújo, and Villar, 1968; Avila and Villar, 1968). The granulomas of vineyard sprayer's lung are quite different from the granulomatous diseases caused by vegetable dusts, and only in a few areas in case 2 were 'sarcoid' features found which are common in the other diseases. On the other hand, in the cases presented in this study the offending agent is a well-defined chemical substance, while in the vegetable dusts the main antigen seems to be a fungus.

The present investigation shows the need for protective measures for these workers while they do their spraying, and also the great value of lung biopsy for the correct identification of this type of condition.

REFERENCES

- Avila, R., Teles de Araújo, A., and Villar, T. G. (1968). Doença pulmonar nos corticeiros. *J. M^d. (Pôrto)*, **66**, 8.
- Avila, R., and Villar, T. G. (1968). Suberosis. Respiratory disease in cork workers. *Lancet*, **1**, 620.
- Cancellata, L. de Carvalho (1955). On a special kind of pneumoconiosis the suberosis. *Med. contemp.*, **73**, 235.
- (1959). Suberose. Ph.D. thesis, Lisbon University.
- Emanuel, D. A., Lawton, B. R., and Wenzel, F. J. (1962). Maple-bark disease. Pneumonitis due to *Coniosporium corticale*. *New Engl. J. Med.*, **266**, 333.
- Wenzel, F. J., Bowerman, C. I., and Lawton, B. R. (1964). Farmer's lung. Chemical, pathologic and immunologic study of twenty-four patients. *Amer. J. Med.*, **37**, 392.
- Horta, J. da S., and Cancellata, L. de C. (1957). Experimentelle Korkstaubkoniose. Experimentelle Suberose. *Arch. Gewerbepath. Gewerbehyg.*, **15**, 319.
- Jamison, S. C., and Hopkins, J. (1941). Bagassosis: a fungus disease of the lung. A case report. *New Orleans med. surg. J.*, **93**, 580.
- Millardet and Gayon (1885). Cit. J. Lafon and P. Covilland. *Maladies et Parasites de la Vigne*, p. 31. Baillièrre, Paris, 1955.
- Perrey (1884). Cit. J. Lafon and P. Covilland. *Maladies et Parasites de la Vigne*, p. 31. Baillièrre, Paris, 1955.
- Pearse, A. G. E. (1960). *Histochemistry*. 2nd ed., pp. 697, 698. Churchill, London.
- Pepys, J., Longbottom, J. L., and Jenkins, P. A. (1964). Vegetable dust pneumoconioses. Immunologic responses to vegetable dusts and their flora. *Amer. Rev. resp. Dis.*, **89**, 842.
- Seal, R. M. E., Hapke, E. J., and Thomas, G. O. (1968). The pathology of the acute and chronic stages of farmer's lung. *Thorax*, **23**, 469.