

Traumatic rupture of the diaphragm

J. Y. NEVEUX, E. HAZAN, J. C. LEVASSEUR,
J. J. GALEY, AND J. MATHEY

From the Clinique de Chirurgie Thoracique, Hôpital Laennec, 42 rue de Sèvres, Paris 7e

Twelve cases of traumatic tear of the diaphragm have been operated upon. In nine operation was done less than a week after the accident, with eight excellent results and one death. Three cases were recognized late in patients who had sustained chest injuries months or years earlier. Repair was accomplished in all patients through a thoracic approach.

Ruptures of the diaphragm have been encountered with increasing frequency in recent years, probably because of the increased frequency of accidents on the roads.

These lesions usually occur in patients with multiple trauma and, on account of this, offer special diagnostic and therapeutic problems.

The purpose of this article is to report 12 cases of traumatic tears of the diaphragm that we have seen and treated.

CLINICAL MATERIAL

These 12 observations will be divided into two groups, the first dealing with those cases diagnosed and operated on less than a week after their occurrence, and the second including those in which the diagnosis was made months or years after the accident had been sustained.

GROUP I Nine such cases were seen; the youngest patient was 11½ and the oldest 63 years. There was a definite sex incidence; seven of these patients were men.

In four the diagnosis was made shortly after the patient had been seen, either from a routine chest film done systematically in patients with multiple trauma, or because our attention had been focused on the thorax because of trauma to the chest wall.

In the remaining five patients the lesion was discovered one to five days after the accident had occurred; each of these patients had been seen in the emergency room of another institution and was referred to our clinic later for treatment of the thoracic lesions.

Pathology and anatomy The right hemidiaphragm was involved in only one case. The lesion

consisted of a peripheral tear, 3 cm. long, in the vicinity of a fractured rib (Figs 1 and 2). The left hemidiaphragm was involved in the remaining eight patients. In every one of these the lesion consisted of a radial tear starting from near the oesophageal hiatus and extending forward and to the left toward the centre of the hemidiaphragm for a distance varying between 4 and 10 cm.

In three cases there was an associated rupture of the left crux. The pericardium was never involved in our patients.

All nine patients in group I had associated bone injuries. The types of associated fracture are listed in Table I. If it is banal to observe chest (cage)

TABLE I
ASSOCIATED FRACTURES

Fracture Site	No. of Cases
Rib	4
Pelvis	4
Long bones	6

injuries in this type of patient who has usually suffered thoraco-abdominal injuries, the frequent association of fractures of the long bones and pelvis underlines the usual violence of these injuries.

In five patients there were associated visceral injuries (Table II) and in our series these visceral lesions were always multiple.

In three patients kidney injury revealed itself by haematuria, which could not be accounted for by any other lesion. These symptoms were never dramatic and the haematuria subsided spontaneously in all patients.

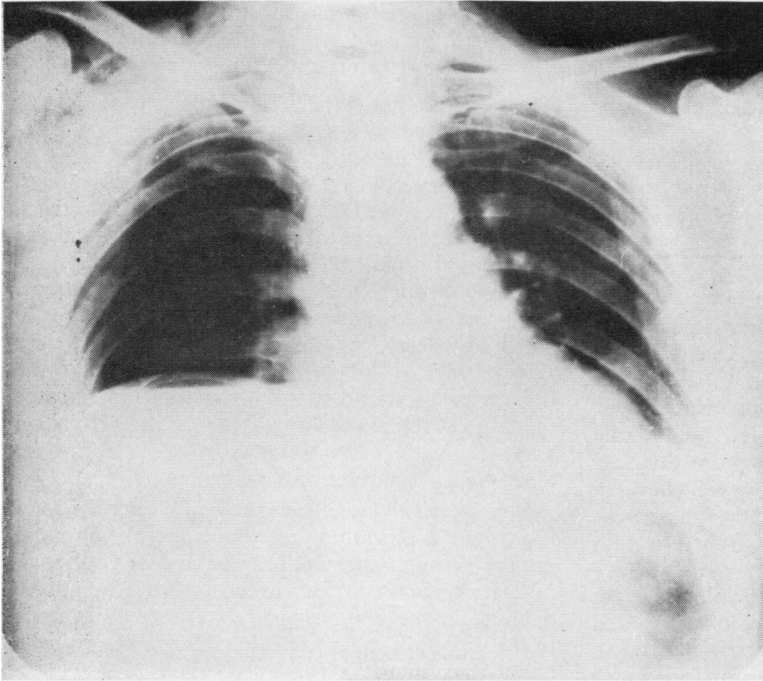


FIG. 1

FIGS 1 and 2. *Tear of the right hemidiaphragm, front and right lateral views.*

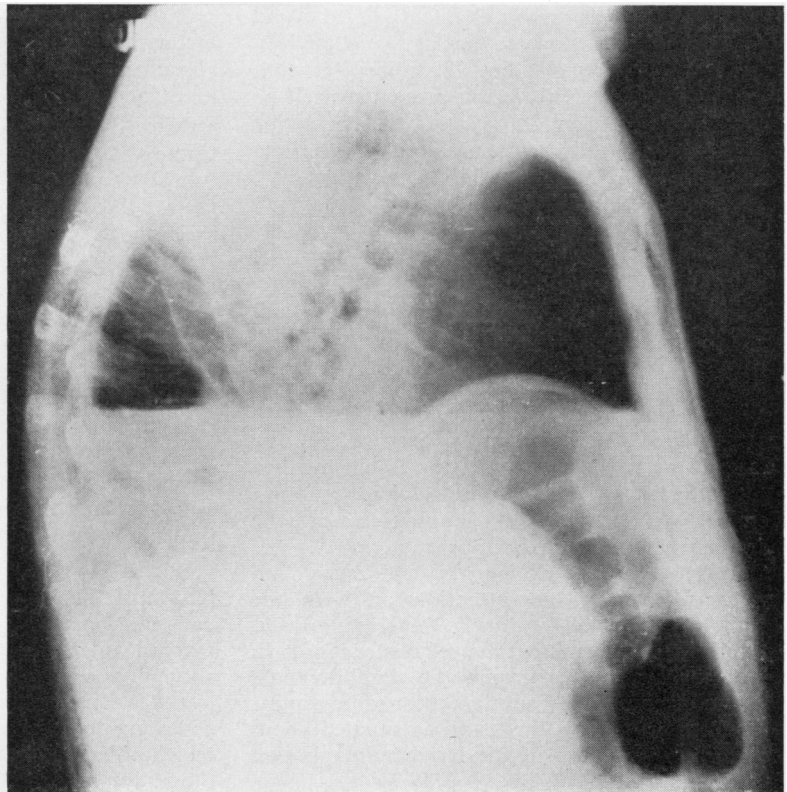


FIG. 2

TABLE II
ASSOCIATED VISCERAL INJURIES

Site of Injury	No. of Cases
Tear of the liver	1
Kidney contusion	3
Rupture of the spleen	2
Contusion of the pancreas	1
Localized necrosis of the gastric wall	1
Tear through the mesentery of the small bowel	1
Partial rupture of the aortic isthmus	1

Two patients had associated rupture of the spleen. In both, the spleen had herniated, along with the stomach and left colon, into the left pleural cavity.

In one patient there was an associated tear along the posterior surface of the left lobe of the liver. There was no active bleeding from this tear when the lesion was discovered at exploration.

In one patient there was a tear in the mesentery of the small bowel which did not interfere with the blood supply to the intestine.

Whereas the abdominal visceral injuries were frequent, we observed only one case of associated intrathoracic injury. The lesion consisted of a partial rupture of the wall of the aortic isthmus (only the adventitia was still intact) just beyond the subclavian artery on the medial side (Langlois, Galey, Binet, Zuber, Cadot, Thomine, Neveux, and Mathey, 1964). This lesion presented itself as a medium-sized haematoma of the posterior mediastinum. The tear was repaired by arteriorrhaphy about eight hours after the accident.

GROUP II In three patients the tear in the diaphragm was recognized a long time after the original accident (7 months, 14 and 21 years).

The initial trauma had been severe enough in every case to require hospital treatment for several days after the accident. Unfortunately, we did not know if radiography had been carried out in every case. It would have helped us in retrospect to know if the tear had simply been missed by ignorance or negligence, or if the lesion evolved in two stages with asymptomatic rupture 'd'emblée' and secondary herniation of the abdominal viscera into the thorax.

Only one of these patients had signs and symptoms focusing our attention on both the thorax (shortness of breath and chest pain) and the abdomen (intermittent bowel obstruction). In the other two in this group, the diaphragmatic tear was discovered by routine chest radiography.

In all three patients the tear was situated about the tendinous portion of the left hemidiaphragm (Figs 3 and 4).

Once suspected, the nature of the lesion was confirmed by barium enema and radiography of the upper gastro-intestinal tract.

OPERATIONS PERFORMED

GROUP I Except for the first case in this series, in which the approach was through a left thoracophreno-laparotomy, the tear in the diaphragm was repaired through a left postero-lateral thoracotomy through the seventh intercostal space. Such an approach involves an incision 15 to 20 cm. long, which ends 4 or 5 cm. proximal to the sternal end of the rib, cutting only partly the latissimus dorsi and usually respecting the serratus magnus. We have always obtained in this way a good exposure of the leaflet of the diaphragm, allowing an accurate and easy repair.

We have always been able to carry out a thorough exploration of the upper abdominal organs through the diaphragmatic tear, although in certain cases it was necessary to extend the opening in the diaphragm by splitting the muscle in the direction of its fibres in order to introduce a hand or retractors.

We then proceeded to a systematic exploration of the pleural cavity, making sure in every case to visualize the posterior mediastinum by lifting the lung forward.

After the abdominal organs had been returned to the abdominal cavity, the diaphragm was closed using interrupted o-silk sutures, making sure that the rough edges were displaced toward the abdominal cavity. In all of these cases an adequate repair was carried out without tension on the suture line and without the use of prosthetic material.

It was necessary in three patients who had extensive intra-abdominal injuries to explore the abdomen separately through a short midline incision extending above or below the umbilicus according to the site of the injury.

For the last seven patients, routine systematic anticoagulant therapy was instituted, starting on the fourth post-operative day.

GROUP II The approach was the same in all three patients—postero-lateral thoracotomy through the seventh interspace. The adhesions between the abdominal viscera and the lung or the chest wall were easily freed and we had no difficulty in returning the stomach, colon, and spleen (which had herniated into the chest in all three cases) to the abdominal cavity.

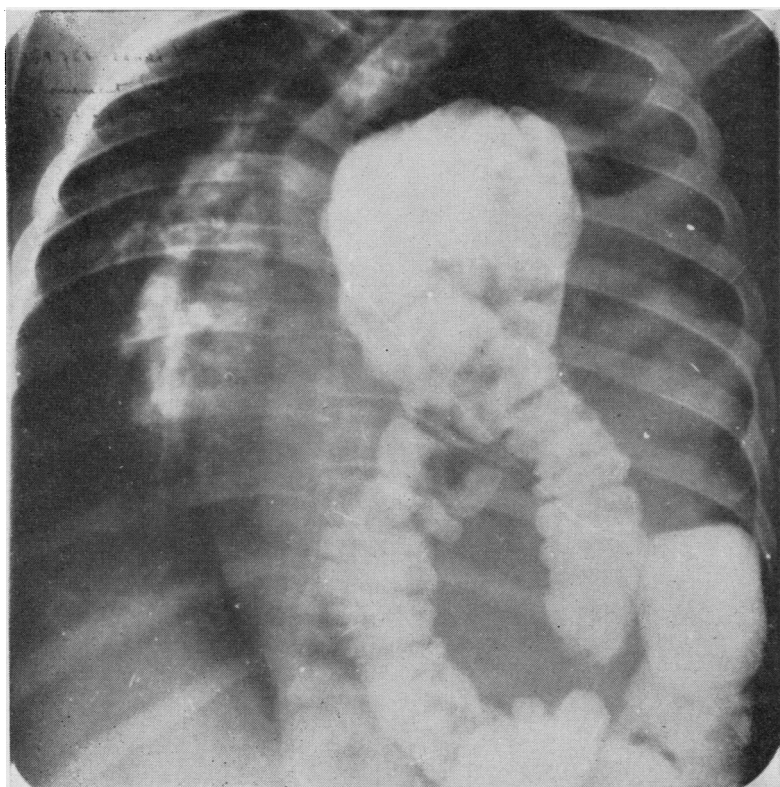


FIG. 3

FIGS 3 and 4. *Pre- and post-operative views of a rupture of the left hemidiaphragm. Late diagnosis. Herniation of the left hemicolon.*

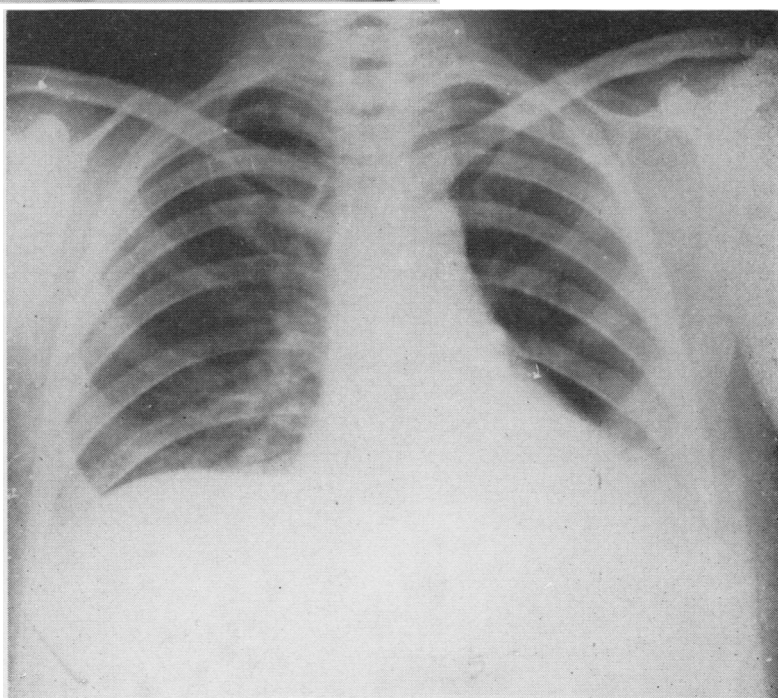


FIG. 4

It was easy to approximate the edges of the diaphragm without tension and without need for prosthetic material.

RESULTS

GROUP I We had excellent results in six out of the nine patients without any complications, abdominal or thoracic.

One patient died 48 hours post-operatively. This 63-year-old man, who had ruptured his right hemidiaphragm, developed shortly after the operation an acute respiratory failure without relation to his primary injury. Tracheotomy and endotracheal breathing were of no avail. At necropsy the right lung was emphysematous and

showed oedema and haemorrhagic effusions which were not explained by any vascular cause which could have been the end result of the original trauma.

Other complications occurred in two patients. One developed intestinal obstruction, apparently as a result of a wound abscess (about the site of laparotomy). This patient was re-explored on the seventh post-operative day, and after division of adhesions he did well. The second patient developed during his convalescence a haemothorax which required decortication. He did well thereafter.

GROUP II All three patients had an uneventful post-operative course without any complication.

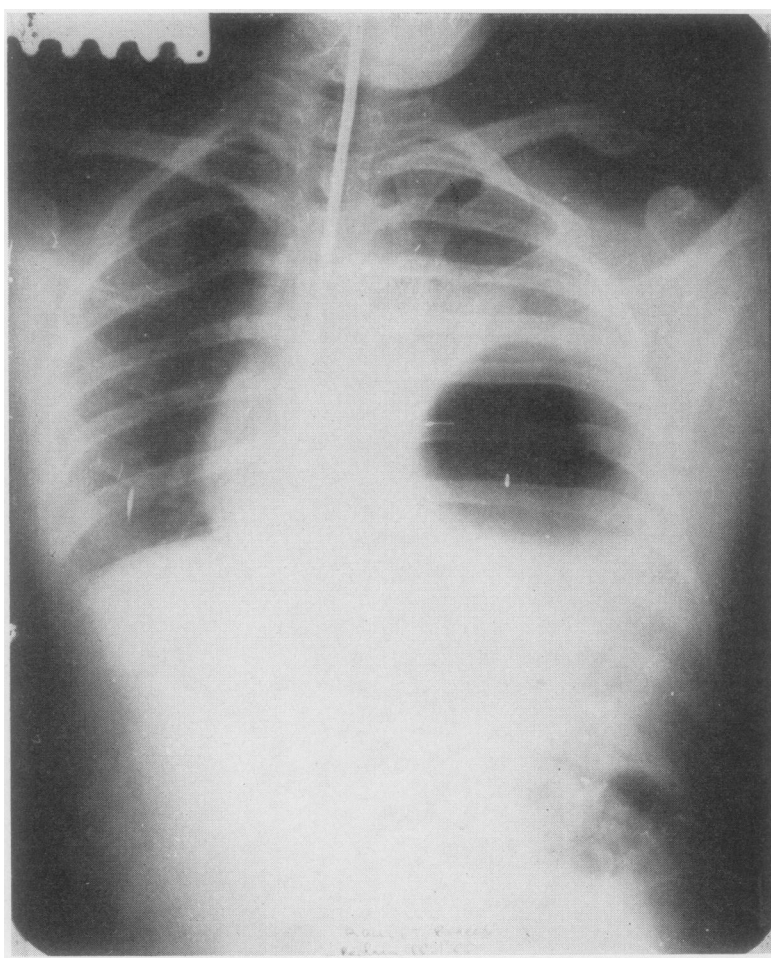


FIG. 5. Tear of the left hemidiaphragm with partial necrosis of the gastric wall.

DISCUSSION

Traumatic rupture of the diaphragm is now encountered with increasing frequency. Of our 12 patients 10 were seen within the last two years.

The greater incidence of abdominal visceral injuries as compared with intrathoracic complications seems to support the view that these lesions usually occur as a result of increased intraperitoneal pressure due to pressure on the abdominal wall. Early diagnosis is usually made only by radiographic examination of the thorax. We therefore favour the opinion that chest radiographs should be taken routinely after chest injury as well as after abdominal injury, particularly in the multi-trauma patient and especially if the trauma has been severe enough to produce a fracture of the pelvis.

The mere fact that a few days may elapse before the abdominal viscera herniate through the diaphragm is reason enough to justify repeat chest radiographs during the first few days after the accident.

Wherever or whenever the situation is diagnosed early, we believe that the patient should be explored as soon as possible. The only reason why we have explored some patients so late is because they were referred late from other institutions, but we did explore them as soon as the diagnosis was made. Nobody is likely to argue against the necessity to explore these patients early; the risk of strangulation of the herniated viscera is reason enough.

Strangulation of the herniated viscera may occur early. We believe that in one of our cases this was the cause of the partial necrosis of the gastric wall (Fig. 5). On account of this we had to perform a partial gastric resection near the fundus.

Some surgeons advocate exploration through the abdomen only. We have favoured and continue to favour the thoracic route for several reasons: the good exposure obtained of the diaphragm; the possibility of ruling out pulmon-

ary injuries and of verifying complete expansion of the lungs; and also the possibility of instituting drainage of the chest cavity. This is also the only way of exploring the posterior mediastinum. Through an abdominal approach we would certainly have missed the tear in the wall of the thoracic aorta. Razemon and co-workers have mentioned the possible association of ruptures of the oesophagus and tears of the diaphragm, and this is another reason for favouring the trans-thoracic approach (Razemon, Ribet, Gautier-Benoit, and Decoulx, 1965).

If exploration of the abdomen is not deemed sufficient or thorough enough through the opening in the diaphragm, even after it has been enlarged, we think it wise, after the chest wall has been closed, to approach the peritoneal cavity through a separate abdominal incision. This is certainly better than extending the thoracic incision across the costal margin. Such incisions always create the risk of inadequate lung ventilation post-operatively. Furthermore, since one has to extend the opening in the diaphragm through its anterior segment, there is the risk that the outer portion of the diaphragm will be deprived of its nerve supply. We start these patients on anticoagulant therapy, usually with dicoumarol or coumadin, routinely from the third post-operative day, because of the high incidence of phlebitis in such cases (Moreau, 1960; Validire and Reynier, 1959). We had no such complication in our series.

REFERENCES

- Langlois, J., Galey, J. J., Binet, J. P., Zuber, Ch., Cadiot, B., Thomine, J. M., Neveux, J. Y., and Mathey, J. (1964). Un cas de rupture traumatique de l'isthme de l'aorte thoracique, opéré avec succès huit heures après l'accident. *Ann. Chir. thorac. cardiovasc.*, **3**, 4, C 1120-1131, Ct 412-423.
- Moreau, Cl. (1960). Un cas de rupture traumatique du diaphragme droit avec hernie hépatique intrathoracique. Opération retardée. Embolie pulmonaire. Guérison. *Mém. Acad. Chir.*, **86**, 403.
- Razemon, P., Ribet, M., Gautier-Benoit, C., and Decoulx, J. (1965). Ruptures traumatiques récentes du diaphragme. *Lille Chir.*, **20**, 14.
- Validire, and Reynier (1959). Un cas de rupture du diaphragme associée à une désinsertion phrèno-costale. Opération immédiate. Mort par embolie au dixième jour. *Mém. Acad. Chir.*, **85**, 223.