

Transient pulmonary densities around retained lipiodol

A. P. ROODVOETS¹, J. SWIERENGA, AND A. P. OEFNER

From St. Antonius Ziekenhuis, Utrecht, The Netherlands

During the last five years we have seen the temporary appearance of massive pulmonary densities around retained lipiodol in 10 patients. In four of these, dense shadows were observed five to 14 days after bronchography; in the other six, four to 35 months after the last intratracheal instillation of lipiodol.

The incidence of this complication can be estimated from the fact that 8,650 bronchographies were performed in this hospital between 1959 and 1964 (1,300 to 1,600 yearly). In over 90% of these we used lipiodol, in adults 9 to 15 ml. at each investigation. It is likely that a number of these lesions have escaped notice because of the lack of clinical symptoms and the limited period of time that they have been observed after investigation.

Densities conforming to the distribution of residual lipiodol occurring one to two weeks after bronchography have been reported previously (Amberson and Riggins, 1933; Kooperstein and Bass, 1946; Bass, 1949). These were sometimes accompanied by fever and allergic phenomena, but otherwise the patients did not appear to be ill, considering the impressively extensive lesions. These subsided after a few days, leaving the residual lipiodol still visible. Kooperstein and Bass (1946) drew attention to the resemblance of the allergic phenomena to the 'delayed reaction' of serum sickness and reported that their three patients were all asthmatics and had positive scratch tests to iodopyracet (Diodrast), and two of them to lipiodol. Sputum cultures were negative.

Reports of similar densities occurring several months after bronchography are rare. We have been able to find only two other cases. Dijkstra (1958) reported an infiltrative lesion six months after bronchography, which had vanished three weeks later. Figures 1 and 3 in his article show that the shadow was localized around retained lipiodol. The patient, an asthmatic, did not feel ill, although she had a slight fever (38.5° C.—101.3° F.) for two days.

Berg (1962) mentions one patient who was found to have 'cloudy' shadows, four weeks after bronchography, localized around retained lipiodol. She stated that after a time both these shadows and the lipiodol disappeared.

Öfner (1962) has previously described our first cases.

CASE REPORTS

CASE 1 A 52-year-old woman suffering from chronic bronchitis underwent bronchography with lipiodol of the right lung on 27 November and of the left lung on 30 November 1959. In May 1960 a considerable amount of residual lipiodol was still present. On 24 August 1960 a fairly massive density in the lingula was seen (Fig. 1). The patient had no other complaints than her usual cough with expectoration of a small quantity of whitish sputum and no fever. Laboratory results: haemoglobin 12.0 g./100 ml., 3,900 leucocytes/c.mm., 400 eosinophils/c.mm., erythrocyte sedimentation rate (Westergren) 35 mm. in one hour. In May 1960 these values had been: 14.2 g. haemoglobin/100 ml., 5,400 leucocytes/c.mm., 377 eosinophils/c.mm., erythrocyte sedimentation rate 13 mm. in one hour.

In order to investigate the cause of the opacity, bronchography with lipiodol was performed on the left side on 30 August 1960. No obstruction was shown. On 1 September the bronchi on the right side were filled.

In the afternoon of that day the patient's temperature went up to 39.3° C. (103° F.). She did not feel very ill. The next day there were leucocytes 7,500/c.mm., 5% eosinophils, total eosinophil count 89/c.mm. Sputum culture yielded no pathogens. The patient was treated with penicillin, chloramphenicol, thiazinamon, and promethazine in order to combat possible infection or allergic reaction. The temperature remained raised to 39° C. (102.2° F.).

On 6 September a radiograph of the chest showed a large opacity in the right lung. The shadow in the left lung had diminished slightly. On 14 September marked eosinophilia (22% of 9,200 leucocytes/c.mm.) and anaemia (9.8 g. haemoglobin/100 ml., 2,840,000 erythrocytes/c.mm.) had developed. The patient received a transfusion of 500 ml. whole blood. A chest radiograph on 22 September (Fig. 2) showed that the

¹Present address: University Hospital, Leiden

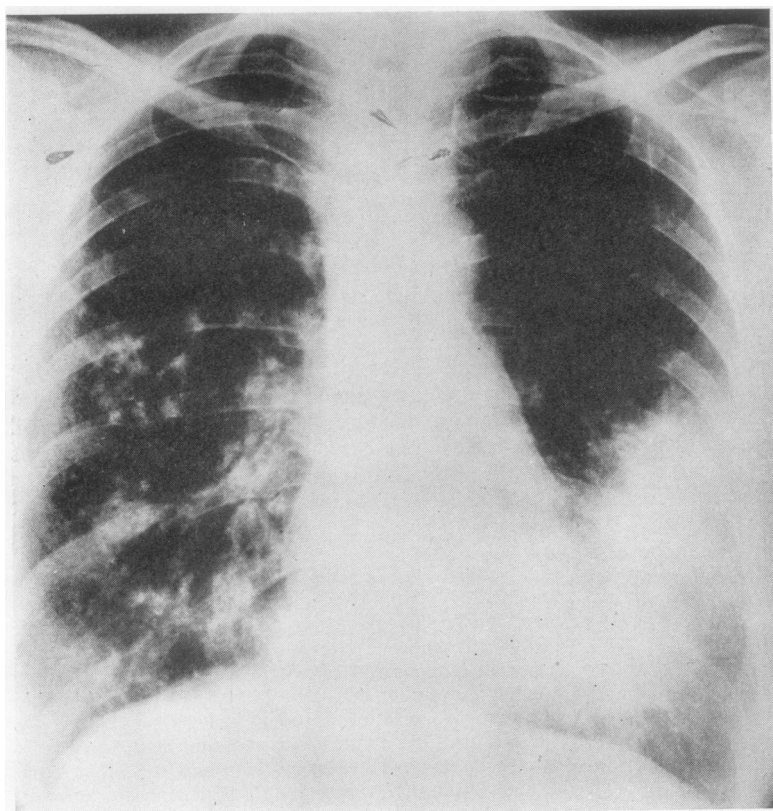


FIG. 1. *Case 1. Massive density in lingula nine months after bronchography.*

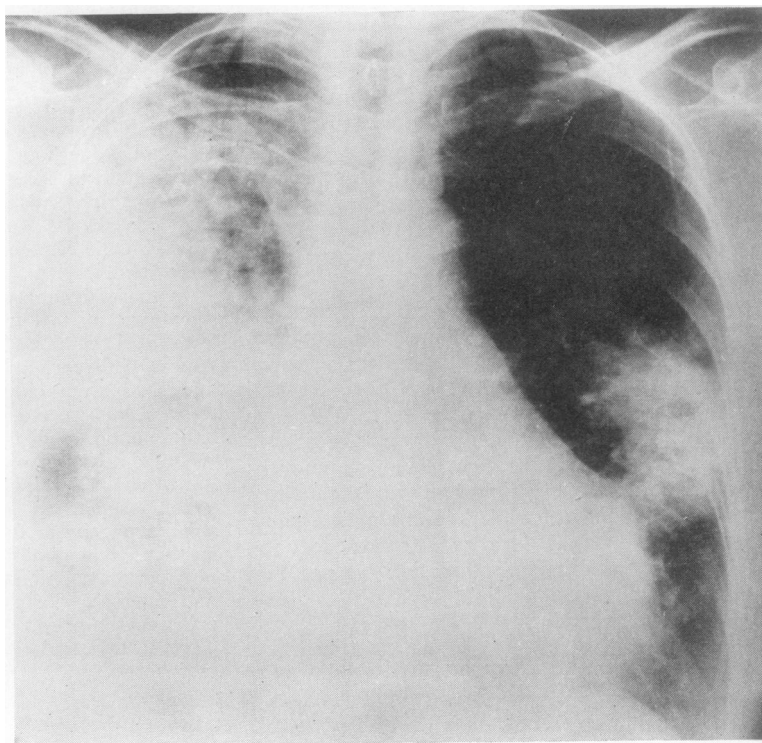


FIG. 2. *Case 1. Three weeks after second bronchography. Extension of lesion in right lung. Decrease of density in lingula.*

density occupied a large part of the right lung. On 27 September 30% of 8,900 leucocytes/c.mm. were eosinophils. The sedimentation rate had risen to 80 mm. in one hour. The temperature had gradually become subfebrile.

On 29 September therapy with prednisone, 20 mg. daily, and long-acting corticotrophin, 10 units three times a week, was begun. The next day the eosinophil count had come down to 2%. The temperature also became normal. A chest radiograph taken on 3 October showed that the consolidation in the right lung had decreased; that in the left lung only slightly. The sedimentation rate had fallen to 12 mm. in one hour. From 10 October (Fig. 3) onwards, radiographs showed only residual lipiodol on the right side; on the left a shadow suggestive of fibrosis remained.

CASE 2 A 69-year-old man, who subsequently proved to have a squamous-cell carcinoma and chronic bronchitis, underwent bronchography with lipiodol on the right side on 20 March 1964. Five days later he became feverish (38° C.—100·4° F.). A radiograph showed patchy shadows around retained lipiodol. Eosinophilia of the blood was not marked.

Prednisolone sodium succinate was given intravenously, 25 mg. on 25 March and 12·5 mg. the next

day. The patient also received penicillin and thiazinamon. The temperature was normal from 27 March. Chest radiographs showed that the consolidations had decreased by 2 April and had disappeared by 9 April. Residual lipiodol remained visible in the lung.

On 17 April the right upper lobe was resected. The surgeon was able to feel the tumour but did not notice any other abnormality in the lung. Microscopical examination showed squamous-cell carcinoma. There was no other evidence of infiltration or granuloma. A biopsy of the apex of the lower lobe showed evidence of previous inflammation.

CASE 3 In a 71-year-old man, who later proved to have a squamous-cell carcinoma of the left lower lobe, bronchography with lipiodol on the left side was performed on 6 July 1961. On 17 July the patient developed fever (39·4° C.—103° F.). The white cell count was 15,000/c.mm.; the differential white count showed an eosinophil level of 10% (before bronchography 6,000/c.mm. and 0%). The chest radiograph showed densities around retained lipiodol, which increased up to 21 July but had disappeared by 26 July. The temperature returned to normal on 20 July. On 21 July there were 7,100 leucocytes/c.mm. and 1% eosinophils. Therapy consisted of penicillin and

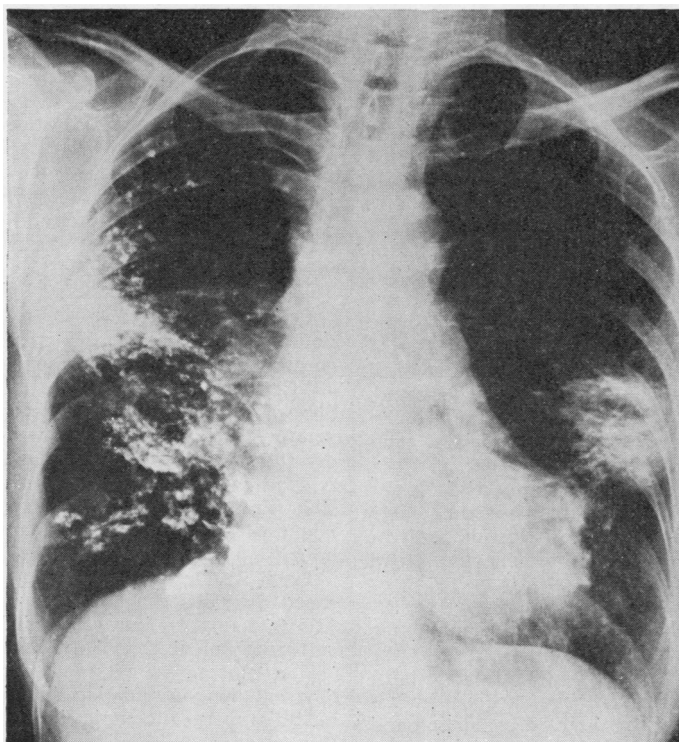


FIG. 3. Case 1. Six weeks after second bronchography. Opacities in right lung have disappeared, leaving residual lipiodol visible. Shadow in left lung remains but has diminished.

streptomycin from 18 to 27 July, prednisone, 15 mg. daily from 20 July, 5 mg. daily from 25 to 28 July. On 3 August lobectomy of the left lower lobe was performed. The surgeon could palpate the tumour but did not notice infiltration elsewhere. On microscopical examination inflammation behind the tumour was noted, but there was no other infiltration or granuloma.

CASE 4 A 55-year-old woman had had periods of fever with a non-productive cough since June 1964. In November an opacity was seen dorsally in the right lung. Bronchography with lipiodol was performed in another hospital.

On 1 February 1965 the patient was admitted to our hospital. No lipiodol was visible at that time. Bronchography with lipiodol was performed on 3 February on the right side, and on 5 February on the left, revealing bronchiectases.

On 13 February fever developed during therapy with penicillin and streptomycin. This treatment was discontinued and chloramphenicol was given instead. A sputum culture grew only *Streptococcus viridans*. The white cell count was 8,400/c.mm., 4% eosinophils. A chest radiograph on 14 February showed a vague shadow in the left lower zone and on 17 February massive densities around retained lipiodol. The temperature was 38.2° C. (100.7° F.), white cell count 6,300/c.mm., 9% eosinophils. The sedimentation rate had risen from 2 to 31 mm. in one hour. Chloramphenicol treatment was stopped. The patient was given antihistamine drugs—Calcistin,¹ six tablets daily, and thiazinamon, 1 ml. intramuscularly twice daily.

From 20 February onwards the temperature was normal. Eosinophils went up to 26% of 8,300 leucocytes/c.mm. The sedimentation rate fell to 5 mm. in one hour. The massive opacities had disappeared but the lipiodol had not.

On 26 February the basal segments of the left lower lobe were resected. The surgeon noted that no lesions were palpable in any part of the lung. In the removed lobe, besides enlarged bronchi with inflamed walls, patches of material, which stained red with Sudan and in which iodine could be demonstrated, were found in the alveolar walls surrounded by granulomatous changes with macrophages and fibrosis; in fact, typical lipiodol granulomata.

On 12 April the basal segments of the right lower lobe were removed. Again the surgeon was not able to find any pathological process on palpation. Microscopical examination revealed bronchiectases and large lipiodol granulomata.

CASE 5 In a 56-year-old man who had emphysema, bronchography with lipiodol was performed, of the right lung on 11 July, of the left on 15 July 1963. In 1960 he had suffered from a spontaneous hydropneumothorax which had been treated by suction and drainage. On 25 November 1963 the patient was

admitted because of fever and expectoration of green sputum of three weeks' duration, which had not responded to chloramphenicol. A chest radiograph (Fig. 4) revealed massive consolidations in both lungs around retained lipiodol. On admission the patient had no fever. The white cell count was 8,900/c.mm., differential eosinophil count 2%, total eosinophils 200/c.mm., sedimentation rate 16 mm. in one hour.

Treatment consisted of prednisone, 20 mg., and chloramphenicol, 2 g. daily, until 12 December. Prednisone was then continued in a dosage of 15 mg. daily; from 18 December, 10 mg. daily. The shadows gradually diminished but only as late as 23 January 1964 (Fig. 5) had they nearly disappeared. Retained lipiodol remained visible.

On 24 April 1964 the patient was again admitted because of consolidation around residual lipiodol. In the axillary area of the left lung a fluid level was seen at the site of a previous pneumothorax. The sedimentation rate had risen to 86 mm. in one hour, the leucocyte count was 7,300/c.mm., eosinophils 167/c.mm. On 29 April the consolidation had diminished slightly but the fluid had increased. From 10 May the patient was treated with 20 mg. prednisone daily as well as para-aminosalicylic acid and isoniazid. The sedimentation rate soon decreased to 14 mm. in one hour. The differential eosinophil count did not change. The fluid had disappeared by 19 May but the consolidation took longer to go. On 15 January 1965 only minor amounts of retained lipiodol were visible with no infiltration.

CASE 6 In a 49-year-old woman who had suffered from asthma for many years, bronchography with lipiodol was performed, on the right lung on 25 June and on the left on 29 June 1964. From November 1961 the patient had been on betamethasone, 1 or 0.5 mg. daily. Treatment was changed to prednisone, 10 mg. daily, in June 1964. A chest radiograph on 20 July 1964 showed residual lipiodol (Fig. 6).

On 19 December 1964 the patient complained of a non-productive cough and pain in the left shoulder; she was not troubled by dyspnoea but had a fever of 40° C. (104° F.). On 29 December she was admitted. She was still taking 7.5 mg. prednisone daily. A temperature of 40° C. (104° F.) was recorded. Scattered dry rhonchi were heard, as was usual for this patient. A chest radiograph showed massive densities (Fig. 7). The white cell count was 11,600/c.mm., eosinophil count 44/c.mm., sedimentation rate 25 mm. in one hour.

From 29 December treatment consisted of prednisone, 15 mg. daily, and prednisolone sodium succinate, 12.5 to 50 mg. by intravenous infusion for three days, chloramphenicol, 2 g. daily, and antihistamine drugs.

The temperature returned to normal the following day, but the consolidation diminished slowly and had not disappeared completely on 22 February 1965 (Fig. 8).

CASE 7 A 66-year-old man with post-pneumonic empyema underwent bronchography with lipiodol of

¹Boehringer, Mannheim: tablets consisting of 200 mg. calcium lactate and 20 mg. histapyrrolidinum

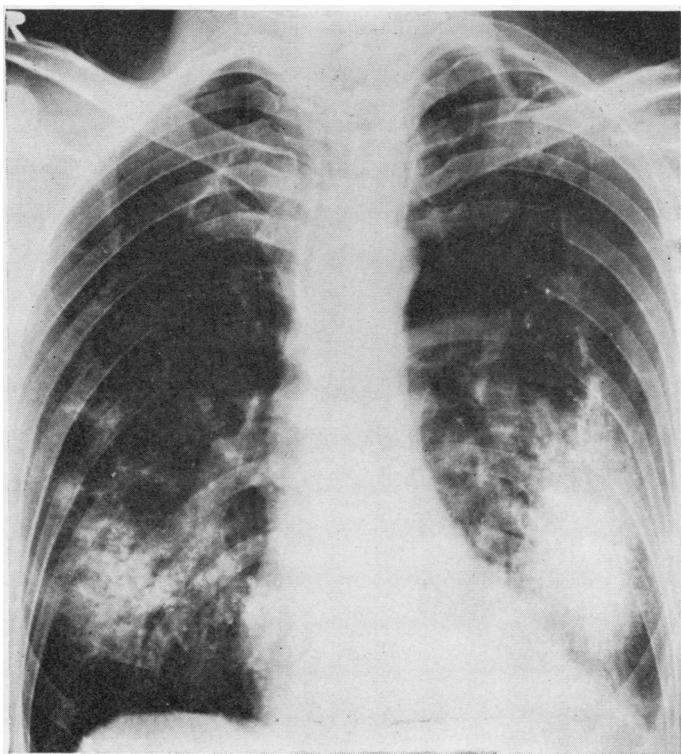


FIG. 4. *Case 5. Massive densities around retained lipiodol four months after bronchography.*

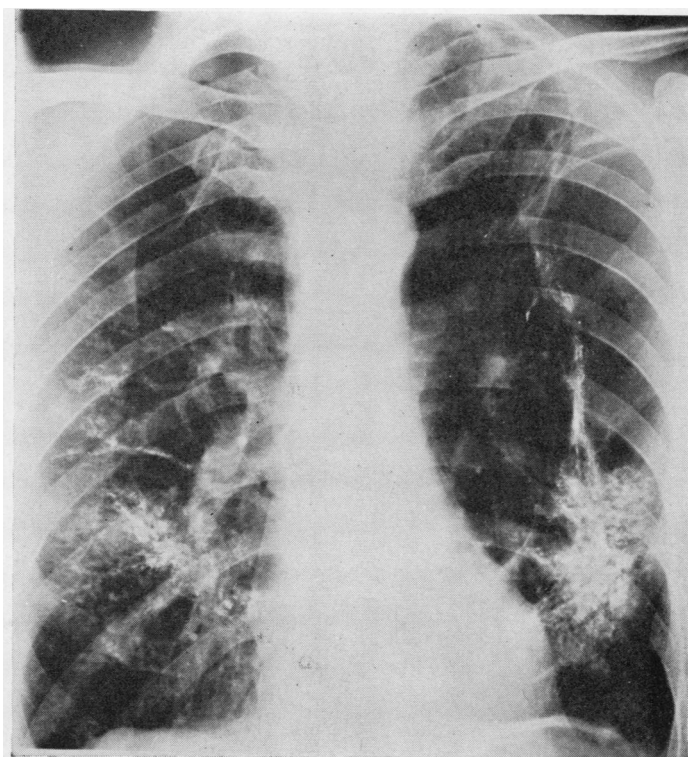


FIG. 5. *Case 5. Opacities have practically disappeared six months after bronchography. Residual lipiodol. Pneumothorax in left axillary region.*

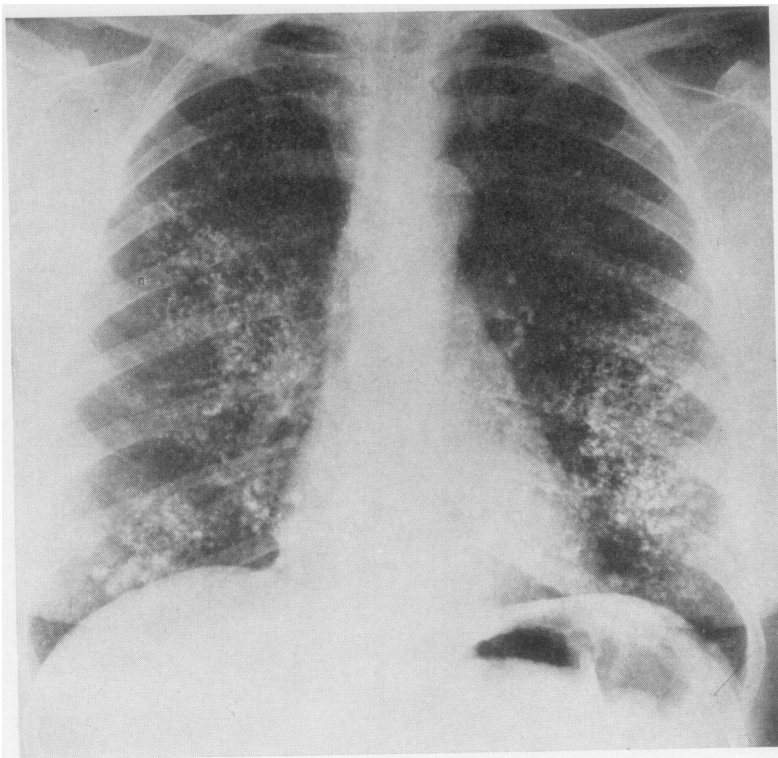


FIG. 6. *Case 6. Residual lipiodol four weeks after bronchography.*

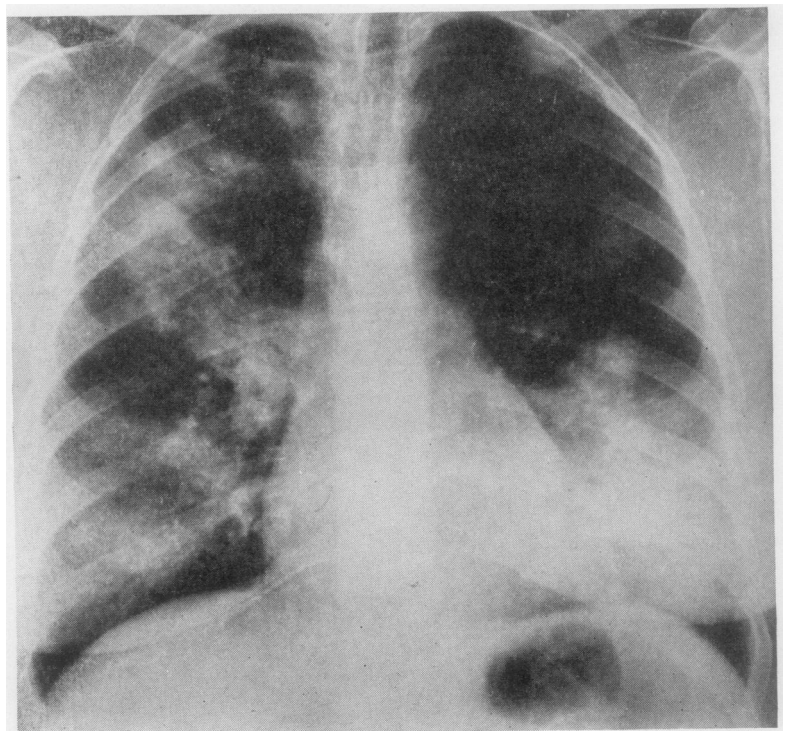


FIG. 7. *Case 6. Massive densities in both lungs six months after bronchography.*

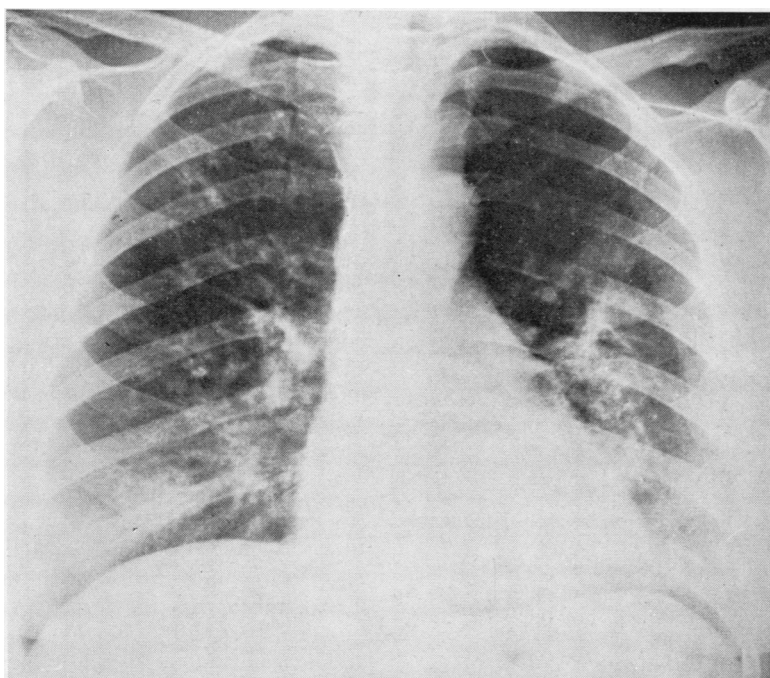


FIG. 8. Case 6. Eight months after bronchography. Densities have nearly disappeared. Some lipiodol still visible.

the left lung on 9 December 1960. In July 1961 he was advised to consult us because mass radiography had revealed a shadow around retained lipiodol in the upper area of the left lung. He had no complaints, in fact it was difficult to persuade him to come to the hospital for investigation because he felt perfectly well. He had no fever and did not appear ill. There was no leucocytosis nor eosinophilia. Only the sedimentation rate, which had been 14 mm. in one hour, was somewhat higher (24 mm.).

He was treated with prednisone, 20 mg. daily, from 22 July in lower dosage, 10 mg., until 18 August. He also received penicillin and streptomycin. The opacity gradually decreased until a chest radiograph on 17 August showed only retained lipiodol.

CASE 8 A woman aged 35 years suffering from asthma underwent bronchography with lipiodol of the right lung on 11 March and of the left lung on 13 March 1964. In October 1964 she complained of tiredness and a sore throat. She recorded a temperature of 38° C. (100·4° F.). On 3 November, when she came for her three-monthly check-up, opacities were seen around retained lipiodol. The patient did not appear ill and her temperature was normal. Physical examination revealed nothing abnormal. There were 7,500 leucocytes/c.mm., 22% eosinophils, 778/c.mm., sedimentation rate 80 mm./hour. Previously 4% of 6,500/c.mm. leucocytes had been eosinophils.

This had occurred while the patient was taking 2·5 mg. prednisone three times a week. From 11 November the dose was increased to 15 mg. daily. On 23 November the opacities had vanished, leaving residual lipiodol visible as before.

CASE 9 A woman aged 44 years, who had suffered from asthma since the age of 5, as well as chronic bronchitis, underwent bronchography with lipiodol of both lungs on 15 June 1962. When she came to the out-patient department for her routine visit on 25 March 1963 the chest radiograph showed a dense opacity around retained lipiodol in the right upper area. She did not feel ill. She was still on 0·75 mg. betamethasone daily for her asthma. The white cell count was 6,300/c.mm., eosinophils 6%, sedimentation rate 8 mm. in one hour.

The patient was admitted to hospital and treated with 25 mg. prednisone daily for 15 days from 17 April. On 24 April the density had decreased and by 1 May it had practically disappeared. On 27 August 1963 some lipiodol could still be seen in the right upper area, but with no sign of consolidation.

CASE 10 Bronchography with lipiodol was performed in a woman aged 46 years, who had cystic disease of the lung, on 25 July 1958 on the left, and on 28 July on the right side. By March 1960 a small amount of residual lipiodol was still visible. In order to ascer-

tain the possibility of operation, bronchography with lipiodol was again performed on 14 March 1960 in the left lung, and on 16 March in the right. On 6 April 1960 left pneumonectomy was done. On microscopical examination it was reported that many bronchi were dilated into cystic malformations with slight chronic inflammatory changes in the bronchial walls. The lung tissue contained fibrotic and emphysematous patches. No tubercles or granulomata were seen.

In the remaining right lung, scattered residual lipiodol was visible on radiographs. On 2 February 1963 pathological irregular patchy shadows were seen in the right lung. The patient complained of cough and copious yellow-brownish expectoration since November 1962. She had no fever. The white cell count was 7,700/c.mm., eosinophils 99/c.mm., sedimentation rate 17 mm. in one hour. Sputum cultures yielded *Strep. viridans* and sporadic colonies of pneumococci. There was no improvement during treatment with chloramphenicol or penicillin. On 27 March the differential eosinophil count was 17% of 5,300 white blood cells/c.mm., 1,300 eosinophils/c.mm., sedimentation rate 20 mm. in one hour.

From 30 March the patient was treated with 25 mg. prednisone daily. Five days later a radiograph showed that the shadows had diminished, but thereafter they remained stationary.

DISCUSSION

Cases 1 to 4 occurred five to 14 days after bronchography. Two of these, 1 and 4, had also had a bronchogram nine and three months earlier. In the other six (5 to 10), the interval between intratracheal instillation of lipiodol and densities conforming to the localization of residual iodized oil was four months (case 5), six to nine months (cases 6 to 9), and nearly three years (case 10). Case 1 probably had a late reaction nine months after her first bronchography, followed by an early reaction five days after the second. Case 5 was affected by this condition twice, four and nine months after bronchography.

All patients had remarkably little illness or dyspnoea, considering the impressively dense and extensive lesions shown on radiographs. We were unable to detect signs of consolidation on physical examination.

The four 'early' cases all had fever. Of the 'late reactors', cases 5, 6, and 8 reported that they had been feverish at home. In patient 6 a raised temperature was recorded on admission.

Sputum cultures in the majority did not yield pathogens. From the sputa of cases 2, 8, and 10 small numbers of pneumococci were cultured and from cases 2, 5, and 6 *Haemophilus influenzae*. The infiltrative lesions did not appear to be caused by infection and did not respond to antibiotic therapy.

All patients had a raised sedimentation rate except cases 3 and 9, while in case 2 the sedimentation rate was not taken at the time of the lesion.

A leucocytosis between 9,000 and 15,000/c.mm. was noted in cases 1, 2, 3, and 6.

In cases 1, 4, 8, and 10, marked eosinophilia was found. None of our patients demonstrated urticaria during the episode, as Kooperstein and Bass (1946) described in their cases.

It is not obvious from our material that this reaction to lipiodol occurs only in persons prone to allergic manifestations, although a proportion did suffer from allergic conditions. Cases 6, 8, and 9 had had asthma for a number of years. Case 4 suffered from allergic rhinitis and had an asthmatic sister. Intradermal tests with the usual allergens were negative, or only slightly positive, in most patients. Only case 9 exhibited positive reactions to dust and certain vegetables (peas and beans). No scratch tests with lipiodol were done.

In cases 1, 2, 5, and 10, evidence of bronchospasm was found during lung function tests. By this we mean that the forced expiratory volume was less than 70% of the vital capacity and improved more than 10% after the administration of a bronchodilator drug (thiazinamon).

In those cases in which lung function was tested while the consolidations were present (5, 7, 8, and 9), the vital capacity was 300 to 900 ml. less than previously and improved after treatment with prednisone. It is not unusual to find improvement in lung function during a stay in hospital, particularly in asthmatics and patients under the influence of corticosteroid therapy. In none of the patients was the lesion accompanied by an attack of asthma. The asthmatic patients did not exhibit an exacerbation of their asthma.

We do not have sufficient evidence that the anaemia, which in case 1 coincided with the lung lesions, was causally related to lipiodol reaction. The haemoglobin fell from 12.0 to 9.8 g./100 ml. in nine days without any evidence of blood loss. No further investigations were done at the time. In case 6, when the densities occurred the haemoglobin was also lower than previously. Evidence of iron deficiency was found: the serum iron was 15 µg./100 ml., total iron-binding capacity 340 µg. This patient complained of frequent menstrual periods. The haemoglobin started to rise rapidly during corticosteroid treatment before the iron therapy, which was instituted later, could have taken effect.

The massive lesions usually cleared rapidly and the fever subsided one or two days after the institution of corticosteroid therapy. In some

patients a low maintenance dose of corticosteroids did not prevent the lesions occurring. Case 4 recovered rapidly without steroid therapy.

Improvement was especially striking in the cases that occurred soon after bronchography. In these, the massive densities disappeared completely within a fortnight. The cases in which the consolidations represented a late complication of bronchography showed fair improvement in the first week, but the densities frequently took several months to disappear, sometimes leaving residual shadows which we consider to be due to fibrosis. In case 4, the shadows had decreased in five days, although this patient did not receive corticosteroid therapy.

The localization of these lesions and the fact that they vanish without a trace in a short time may suggest that this is an exudative reaction to lipiodol. In cases of long standing, the consolidations may lead to residual fibrosis. In our cases 2, 3, and 4, which were operated on nine days to three weeks after the densities had been visible on radiographs, no signs of massive infiltration were noticed by either the surgeon or the pathologist.

It does not seem that these densities are related to the lipiodol granulomata, which were found in case 4, and are a less rare reaction to residual lipiodol.

We have investigated the possibility that the lipiodol used had deteriorated, due to having been stocked too long, but we were not able to confirm this. Fresh stock is used which does not show any discolouration.

How frequently these densities occur in persons who have failed to eliminate instilled lipiodol within a short time we cannot accurately estimate. It is by no means rare that retained lipiodol is still visible months after bronchography. The number of patients in whom we have seen this reaction is certainly smaller.

SUMMARY

Ten cases of transient densities around retained lipiodol are reported. In four, these occurred five to 14 days, in the other six, four to 35 months, after bronchography.

The incidence was approximately one in 400 patients who underwent intratracheal instillation of lipiodol; but it may in fact be higher.

A fever of short duration accompanied the condition in seven patients. None of the patients appeared to be very ill.

Some of the patients had previously suffered from an allergic condition.

Corticosteroid therapy appeared to have a beneficial effect, but antibiotics and antihistamine drugs did not affect the process.

In lung tissue removed at operation nine days to three weeks after the lesions had been visible on radiographs, in three cases no signs of massive infiltration were found. In one of these, lipiodol granulomata were present, but this is probably a different type of reaction to residual lipiodol.

We wish to thank Prof. Dr. J. Vossenaar, Chief, Department of Pathology, St. Antonius Ziekenhuis, Utrecht, who performed the pathological examinations. The operations were performed by A. L. E. M. S. Schaepkens van Riepst and H. J. Gelissen, of St. Antonius Ziekenhuis, Utrecht.

REFERENCES

- Amberson, J. B., Jr., and Riggins, H. M. (1933). Lipiodol in bronchography: its disadvantages, dangers and uses. *Amer. J. Roentgenol.*, **30**, 727.
- Bass, H. E. (1949). Delayed pneumonia and urticaria following bronchography. *New Engl. J. Med.*, **240**, 505.
- Berg, W. C. (1962). Bronchografie bij tuberculose (Bronchography in tuberculosis). Thesis, University of Groningen.
- Dijkstra, C. (1958). Symptoomarme longinfiltraten (Lung infiltrations with few symptoms). *Ned. T. Geneesk.*, **102**, 2361.
- Kooperstein, S. I., and Bass, H. E. (1946). A pulmonary reaction following intrabronchial instillation of lipiodol in bronchial asthma. *Amer. J. Roentgenol.*, **58**, 569.
- Öfner, A. P. (1962). Problemen rondom de bronchografie. (Problems concerning bronchography). *Ned. T. Geneesk.*, **106**, 1160.