

# Primary chondrosarcomatous mesenchymoma of the mitral valve

C. S. MUIR AND C. S. SEAH

*From the Department of Pathology, University of Singapore, General Hospital, Singapore, and Thomson Road Hospital, Singapore*

Despite the oft-quoted assertion that the heart is an organ too noble to be attacked by a primary tumour (de Sénac, 1783), such neoplasms are being reported with increasing frequency. While these primary tumours may occur in any part of the heart they are least frequent on the valves and most common in the atria (Rucks, Russell, and Motley, 1963).

We report a very unusual primary malignant heart tumour, a mixed mesenchymal sarcoma, largely chondrosarcomatous in structure, arising in the region of the mitral valve, probably from papillary muscle.

## CASE REPORT

A 50-year-old Chinese housewife was admitted to Thomson Road Hospital, Singapore on 19 January 1963. She claimed to have been in good health until three months before admission. At this time she had become aware of a cough associated with scanty white sputum, but there was no haemoptysis or fever. She experienced exertional dyspnoea such that when she sought admission to hospital she could barely walk.

Her appetite had become very poor since the onset of her illness. She was nauseated most of the time, vomiting gastric content intermittently. Nine days before admission she had developed swelling of the legs and face, and her urinary output fell. Stools were scanty and infrequent. Menstruation was normal.

Her past and family history did not appear to be related to her present illness. She had no history of rheumatic fever or of a similar illness in the past.

**CLINICAL EXAMINATION** She was a pale, thin, ill Chinese woman. The extremities were cold but pink. There was a slight icteric tint to the sclerae. There was no cyanosis or clubbing of the digits, and she did not have fever. The blood pressure was 120/90 mm. Hg; the pulse, 120 beats a minute, was regular in rate and rhythm and was of small volume. The peripheral pulses were intact and equal. The jugular veins were engorged with prominent 'a' waves. The apex beat was in the fifth left interspace  $4\frac{1}{2}$  in. (108 mm.) from the mid-sternal line. A left parasternal heave was

noted. Auscultation revealed the presence of a regular presystolic gallop, a loud split second sound in the pulmonary area, and a soft systolic murmur over the precordium. There was no diastolic murmur.

Persistent inspiratory crepitations were heard over the left base of the lung. The liver was enlarged and firm, extending one inch below the costal margin. The spleen and kidneys were not felt. Examination of the nervous system showed absent knee- and ankle-jerks even on reinforcement. The plantar responses were flexor. The ocular fundi were normal.

**INVESTIGATION** The haemoglobin was 9.8 g./100 ml. The total white cell count was 4,500/c.mm., the differential count being within normal limits. The erythrocyte sedimentation rate (E.S.R.) was 7 mm. in the first hour. A trace of albumin was found in the urine. The blood urea was 27 mg./100 ml. The blood serum cholesterol was 244 mg./100 ml. A blood Kahn test was negative. Three blood cultures were sterile.

A chest radiograph showed the heart to be enlarged with increased prominence of both borders. A barium swallow showed some backward displacement of the oesophagus with appearances consistent with a mitral lesion (Fig. 1). The electrocardiograph showed bifid P waves in leads 1 and 2. There was inversion of the T in 3 and AVF with slight depression of the ST segment in 2. The other leads seemed normal, the rhythm was sinus, and there was no clear evidence of right ventricular preponderance.

**PROGRESS** Despite treatment—diuretics, salt restriction, and bed rest—heart failure persisted. She complained of vague retrosternal pains, made worse by movement, and of a sensation of tightness in the chest. The irritating cough persisted. She had very little appetite. Occasional extrasystoles were noted. On 24 February 1963, *i.e.*, five weeks after admission, a diastolic murmur was heard in the left axilla (Fig. 2) radiating over a wide area extending from the pulmonary area to the left lung base, being maximal in the left axilla. This murmur was low pitched, occupied the whole of the diastole, and was not altered by respiration. The first heart sound was not accentuated. There was no opening snap.

She was discharged on 21 April 1963. A fortnight later she was seen as an out-patient. Her sputum was

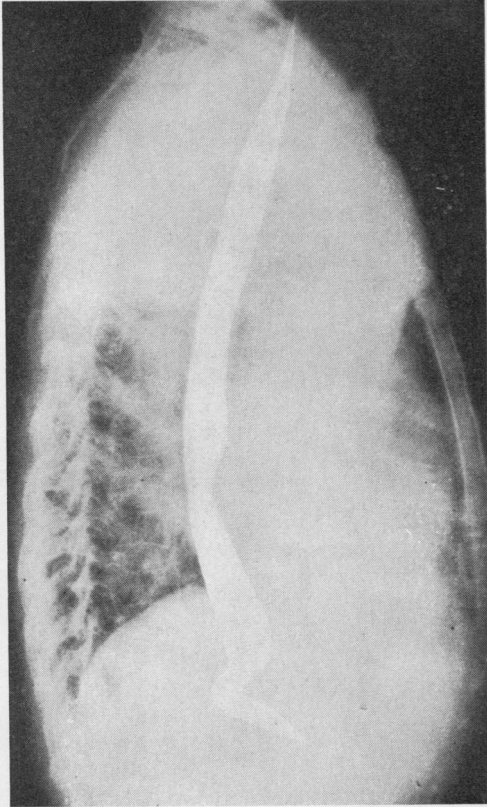


FIG. 1. Barium swallow showing oesophageal displacement consistent with a mitral lesion.

blood-streaked. Oedema of the legs had increased and she had orthopnoea.

READMISSION She was readmitted on 17 May 1963. Her condition was worse, with pitting oedema of the

legs, sacrum, and dorsum of the hands. Her temperature was raised to 99.5° F. The blood pressure was 100/50 mm. Hg. The Hb was now 9.0 g./100 ml., and the E.S.R. was 5 mm. in the first hour. The chest radiograph was as on the first admission.

On 30 May 1963 she developed rapid atrial fibrillation, about 140 to 150 beats per minute. Digitalis was given, with moderate improvement in her condition. Although small doses were used she became even more nauseated and developed bradycardia and paroxysmal pulsus bigeminus. When digitalis was withdrawn she felt much better. At this stage in her illness it had become apparent that the atrial fibrillation was probably not the result of rheumatic heart disease, and an appointment was made for angiocardiology. She was not well enough for this investigation, and two subsequent appointments were cancelled for the same reason.

Her condition became progressively worse; jaundice, oedema, and abdominal discomfort increased. She finally lapsed into a shock-like state with cold purplish extremities, absent peripheral pulses, unrecordable blood pressure, and stupor. She lay in this state for 24 hours before her death on 12 July 1963.

**NECROPSY** The heart was enlarged. The right atrium and right ventricle were considerably dilated. There were patches of white endocardial thickening posteriorly 2 cm. below the pulmonary valve. The apical endocardium of the right ventricle was slightly thickened. The pulmonary arteries showed a considerable degree of atheroma both within and without the lung. The left atrium was distended by antemortem thrombus and post-mortem clot (Fig. 3). This filled the auricular appendage and, adhering to the superior surface, extended into both superior pulmonary veins. The inferior pulmonary veins were not involved.

The opening of the mitral valve was not visible, being filled by a smooth whitish mass, 2.5 × 3.5 cm., with a shallow central dimple. This mass, firmly attached to most of the lateral wall of the left

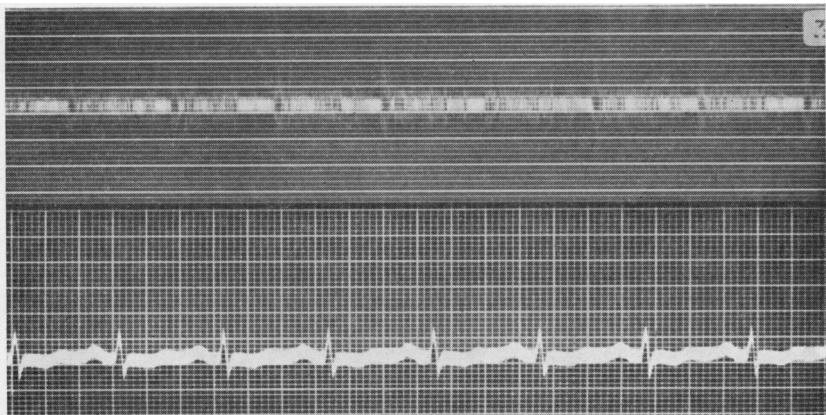


FIG. 2. Phonogram (mid-axillary line, eighth left intercostal space) showing long low diastolic murmur.

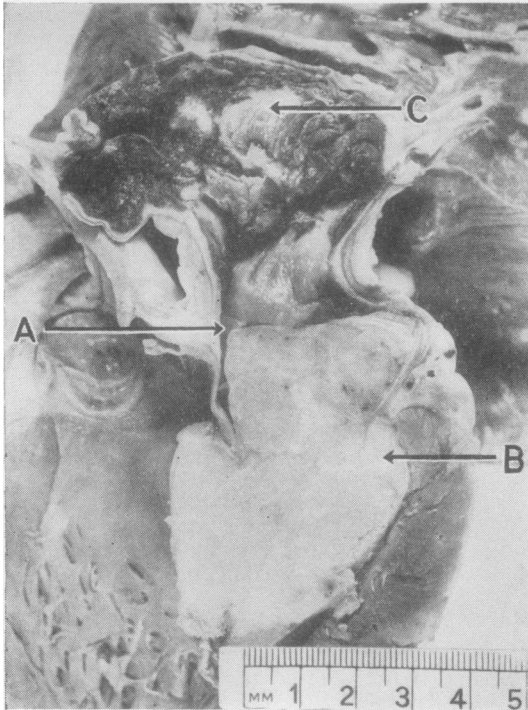


FIG. 3. A firm cartilaginous tumour obstructing the mitral opening and enveloping the mitral valve leaflets. (A) Orifice of channel permitting blood to enter the left ventricle. The histology of the somewhat whiter area (B) is shown in Fig. 6. The left atrium, above, is distended by ante-mortem thrombus (C).

ventricle, reached almost to the apex, enveloping the mitral leaflets and the papillary muscles. One area, about 1 cm. long, just beneath the atrioventricular ring, was of a whiter, more homogeneous appearance (Fig. 3). Posterior to the mass, which was some 5 cm. long, a small channel led to the region of the apex, permitting a small flow of blood into the left ventricle. The mass was homogeneous, of cartilaginous consistency, very firmly attached to, but not seeming to infiltrate, the cardiac muscle. The cut surface was composed of pale yellow islets, 1 to 2 mm. across, surrounded by fine whitish septa. A few coarser septa were also present. That portion of endocardium of the left ventricle which was free of tumour seemed normal.

Five hundred millilitres of blood-tinged fluid was found in the right pleural cavity, 250 ml. in the left pleural cavity and 200 ml. in the peritoneal cavity.

Both lungs were oedematous and very firm to the touch, so much so that they seemed consolidated. Both apices showed healed pulmonary tuberculosis. The liver was tense, mottled, and congested. Most of the parenchyma was yellow. There was no evidence of reverse lobulation. No other tumour was found. The remainder of the organs appeared normal.

The anatomical findings were (1) heart failure due to blockage of the mitral opening by ? tumour, ? thrombus; (2) pulmonary hypertension, oedema, and induration.

**HISTOLOGY** Sections were cut from numerous paraffin-embedded blocks at 6  $\mu$ . These were stained by haematoxylin and eosin, Gordon and Sweet's method for reticulin, Masson's trichrome, Verhoeff-Van Gieson, phosphotungstic acid haematoxylin, and by Perls' method for iron.

The tumour showed several distinct lines of differentiation. The bulk of the neoplasm was composed of islets of malignant cartilage which varied considerably in the degree of dedifferentiation. A few foci of almost normal cartilage were seen, but the vast majority of the chondroid tissue islets showed cells with irregular polyhedral hyperchromatic nuclei of unequal size. Many binucleate and some trinucleate cells were seen. In several areas the nuclei were very large: some were hyperchromatic, others vesicular with prominent nucleoli; in other areas the nuclei formed tight clusters which were separated by relatively wide strands of homogeneous, faintly basophilic ground substance; in yet others the nuclei were spread diffusely throughout the matrix (Figs 4, 5, and 6).

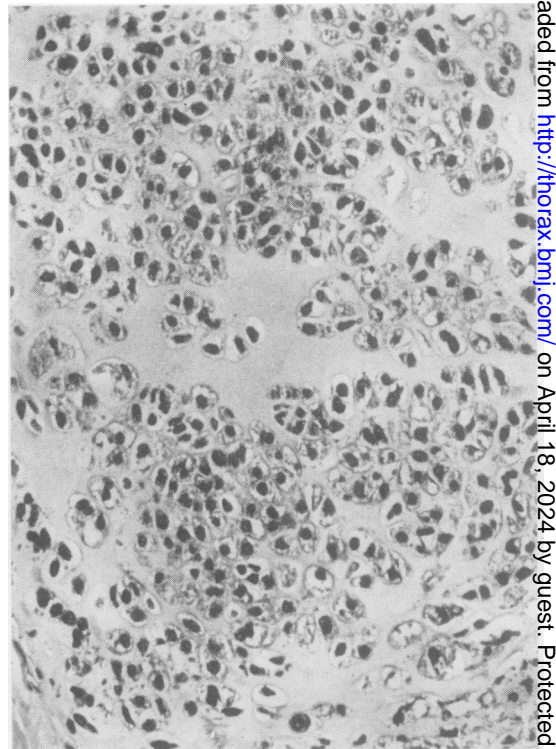


FIG. 4. Chondrosarcomatous area of neoplasm with large numbers of irregular polyhedral nuclei. H. and E.,  $\times 150$ .

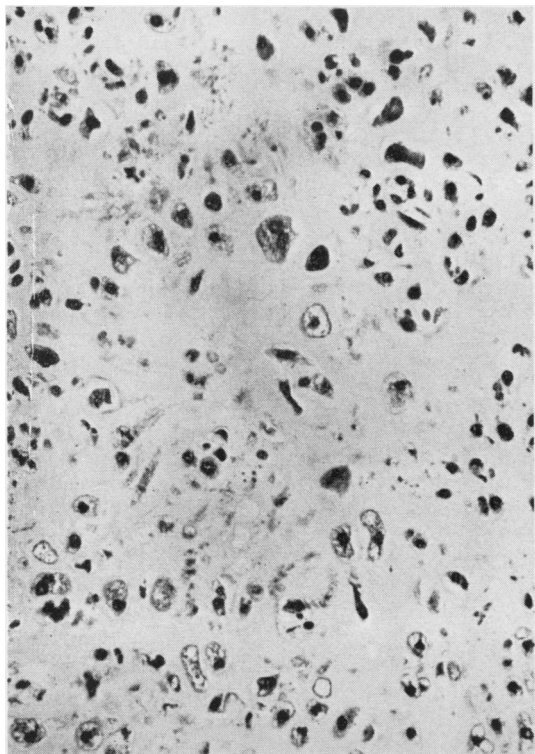


FIG. 5. Chondrosarcomatous area with striking nuclear pleomorphism. A binucleate cell is seen top centre. *H. and E.*,  $\times 150$ .

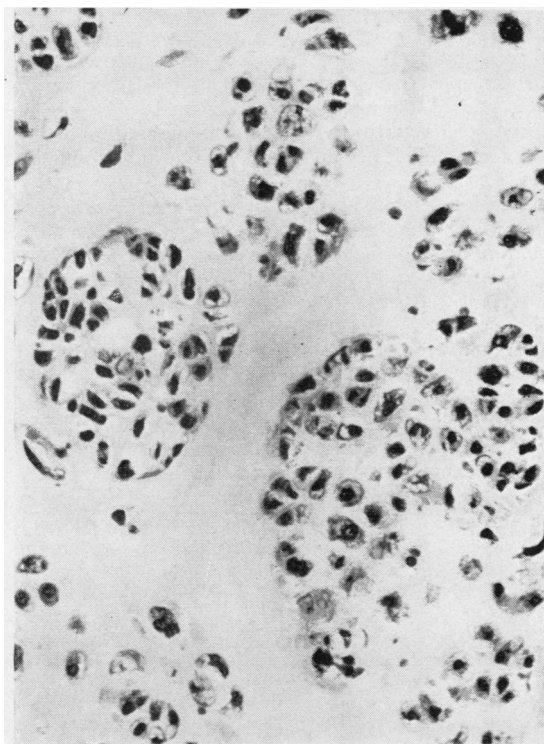


FIG. 6. Tight clusters of malignant nuclei separated by relatively broad bands of ground substance ('B' in Fig. 3). *H. and E.*,  $\times 150$ .

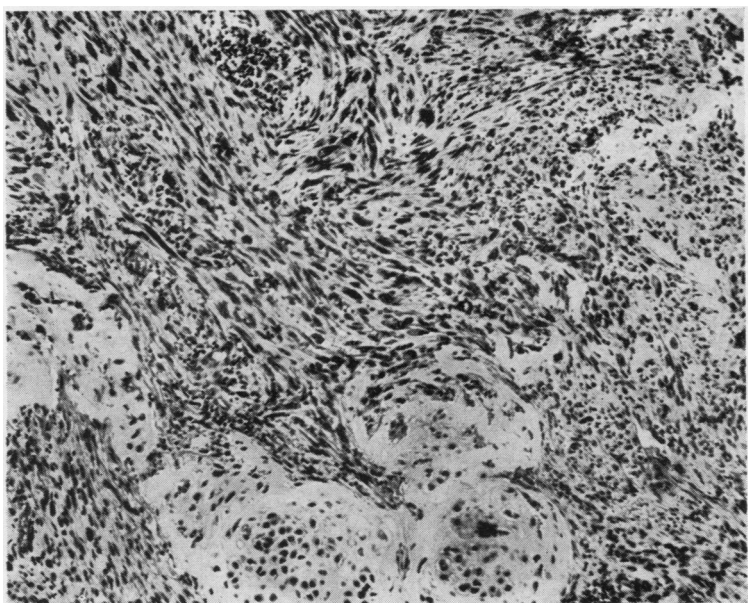


FIG. 7. Chondrosarcomatous area (bottom centre) surrounded by interweaving strands of spindle cells. There is a suggestion of nuclear regimentation (top centre). *H. and E.*,  $\times 75$ .

The tissue between the islets of cartilage was highly cellular, being composed of interweaving strands of cells exhibiting the characteristics of a fibrosarcoma. For the most part these cells were moderately well differentiated, the nuclei being of even size, shape, and staining characteristics. Rarely, some palisading of the nuclei was noted, but this was by no means prominent (Fig. 7).

Occasional foci of nuclear pleomorphism were seen. Such nuclei were either several times larger than the usual, or several nuclei were present in one cell. Many of these cells could fairly be described as being strap or tadpole cells, but no cross-striations could be seen (Fig. 8).

Parts of the neoplasm showed poorly canalized cords of small cells with a scanty cytoplasm and round hyperchromatic nucleus (Fig. 9). Although no red cells were seen in the poorly defined lumina, these areas were interpreted as being haemangiosarcomatous. These malignant blood vessels could be readily differentiated from the few normal blood vessels in the tumour. The normal vessels were situated near the valves and were often infiltrated by malignant cells (Fig. 10).

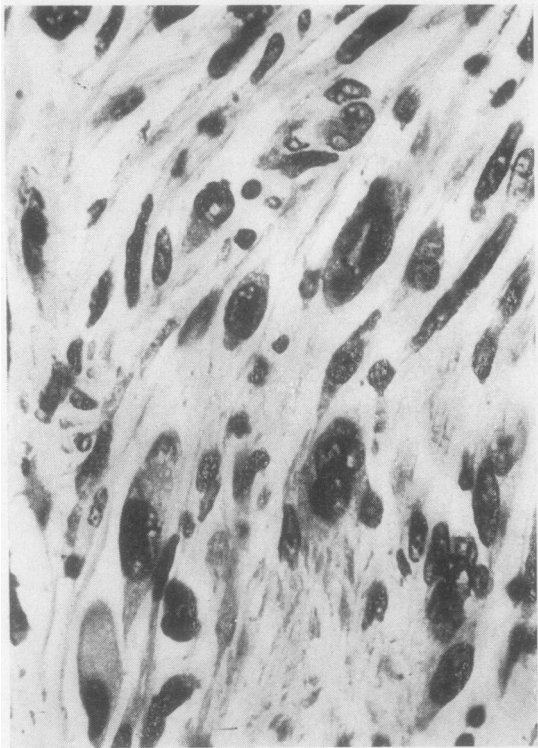


FIG. 8. Area of nuclear pleomorphism with 'strap' and 'tadpole'-like cells; no cross-striation could be demonstrated. H. and E.,  $\times 500$ .

The tumour was seen to invade at one point only. This was over an area  $1.0 \times 0.5$  cm. at the mid-point of the papillary muscle (Fig. 11). In the sections stained by Verhoeff-Van Gieson the tumour could clearly be seen to break the subendocardial elastic tissue and infiltrate between the papillary muscle fibres. Invasion of the myocardial wall, or of the valve leaflets, was not observed. Both the cartilaginous islets and the fibrosarcomatous matrix were in close contact with the subendocardial elastic tissue of the ventricular wall, but they did not penetrate this barrier (Fig. 12).

Several small lacunae, some containing a few red cells, were seen between the ventricular wall and the tumour. Similar small gaps existed between the chordae tendineae and valve leaflets and the tumour.

The free surface of the tumour mass was usually clothed in a layer of fibrous or fibrosarcomatous tissue, so that the chondroid component was not exposed to the blood stream. In a few areas this was merely a thin endothelial lining, but in others, particularly close to the aortic valve, large numbers of loose, bizarre, pleomorphic cells with hyperchromatic contorted nuclei and varying amounts of cytoplasm were conspicuous (Fig. 13). Around these cells there

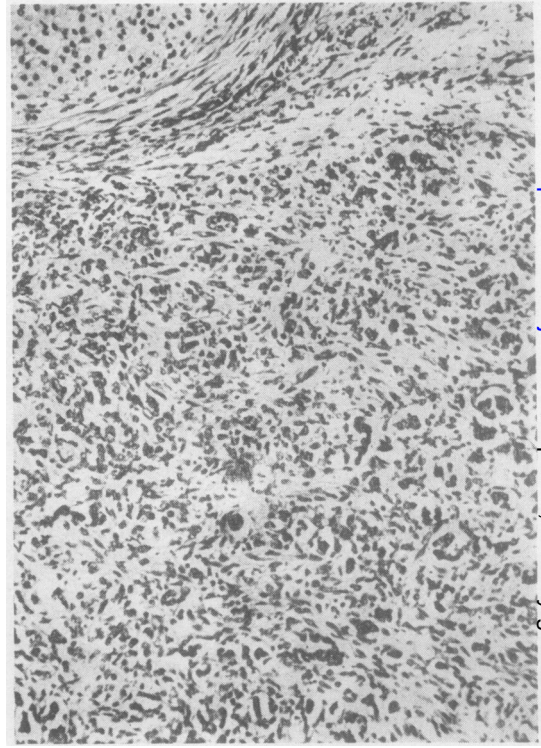


FIG. 9. Area of tumour, interpreted as angiosarcoma showing poorly canalized cords. A chondroid area is seen (top left). H. and E.,  $\times 75$ .

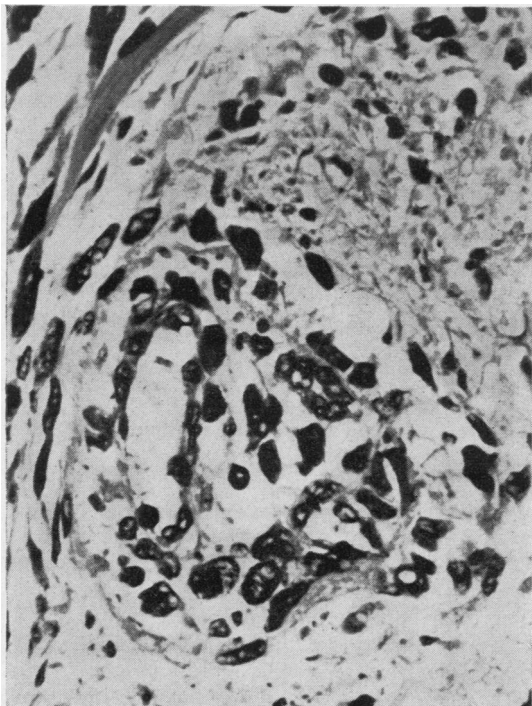


FIG. 10. Normal blood vessel in tumour, infiltrated by cuff of malignant cells. *H. and E.*,  $\times 500$ .

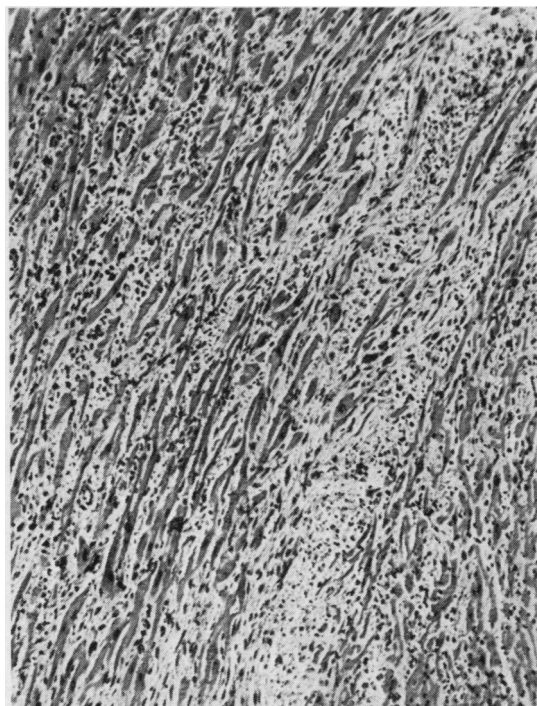


FIG. 11. Infiltration of papillary muscle by tumour. *H. and E.*,  $\times 75$ .

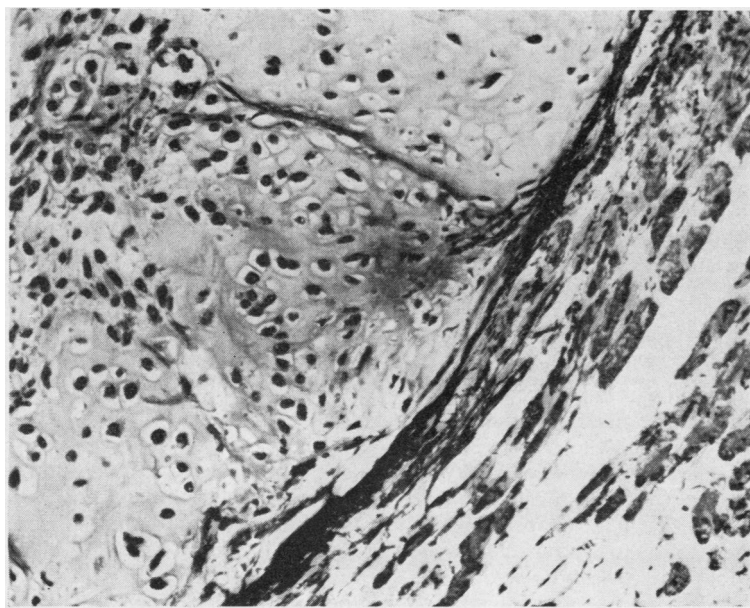


FIG. 12. The tumour on the left is separated from the cardiac muscle by a band of subendocardial elastic tissue. *Verhoeff-Van Gieson*,  $\times 150$ .

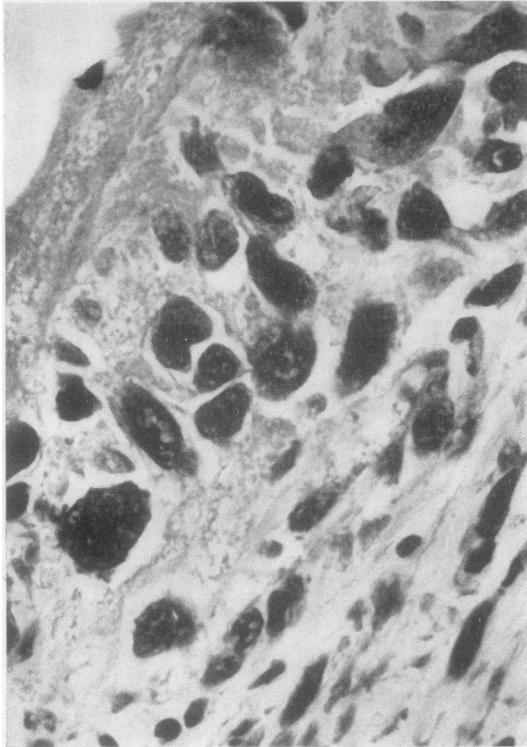


FIG. 13. Bizarre pleomorphic cells close to lumen of ventricle (top left). *H. and E.*,  $\times 150$ .

was abundant reticulin. A little fibrin was present on the surface of some parts of the tumour. Part of the blood clot in the left atrium showed early organization.

In the many blocks of tumour examined there was virtually no haemosiderin.

The alveolar walls were thick, tortuous, and congested. Moderate numbers of haemosiderin-laden macrophages lay in the alveolar spaces. Fibrosis was minimal. The liver showed acute centrilobular congestion. No significant abnormalities were detected in other organs.

#### DISCUSSION

Saphir (1960) tabulated the relative frequency of primary cardiac neoplasm at necropsy, the figures given ranging from 1 in 2,000 to nil in 36,000. The present case was the first in a series of 36,471 consecutive necropsies performed in Singapore in the 17-year period 1947–63. Such comparisons are of little value other than to show that these tumours are rare, since the age and sex distribution of the necropsy population, and its relation to the population of all deaths, are rarely given (Muir, 1964).

Primary malignant tumours of the heart have been recorded in Indians (Nath, 1931) and in Japanese (Tatsumi, Nagatomo, and Kashiwai, 1949) as well as in the White races and American and African negroes. To date no Chinese case seems to have been reported. Recent reviews include those by Whorton (1949), Brucker and Glassy (1955), and Somers and Lothe (1960).

**MORBID ANATOMY** Most tumours taking origin in the mitral valve are myxomata: primary sarcomata are rare. Forker, January, and Lawrence (1963) collected six cases, adding one of their own. Their tumour clearly arose from the posterior commissure and the mural leaflet of the valve, extending into the left inferior pulmonary vein. This neoplasm, which was surgically removed, appeared to have arisen in a pre-existent hamartoma, since part was composed of hyaline material, normal fibrocytes, and vascular spaces, only a portion showing malignant transformation.

There remains some doubt as to the exact point of origin of the tumour described. Although it has been assumed that the site of invasion of the papillary muscle (Fig. 11) represents the origin of the neoplasm, it is quite possible that the tumour sprang from the mitral valve leaflets or from the wall of the left ventricle, since the many sections examined represent but a small fraction of the tumour/heart interface.

A striking feature of primary heart tumours, those of lymphomatous origin excepted, is the lack of local invasion. Woll and Vickery (1947) described the invasion of the subendocardium in their case as local and appreciable only microscopically, noting that most tumours seem to grow over a thick but undisturbed endocardium. Cumming and Shillitoe (1957) observed that 'at no point had the tumour penetrated the walls of the pulmonary veins or atrium'. Vacek (1963) described diffuse infiltration of the myocardium but did not indicate the depth or extent of spread. Despite this lack of local invasion about half the primary sarcomata of the heart give rise to metastases (Yater, 1931).

**HISTOLOGICAL APPEARANCES** About 40% of the malignant primary cardiac tumours reported have been of the 'spindle cell' variety, *i.e.*, fibrosarcoma, myxosarcoma, leiomyosarcoma, or tumours incorporating several of these elements. Approximately 25% have been of the 'round cell' type, principally malignant lymphoma.

Among the less common histological variants reported have been neurogenic sarcoma (Dam-

mert, Elfving, and Halonen, 1955), malignant haemangioendothelioma (Brandenburg and Edwards, 1954), myosarcoma (Leach, 1947), metastasizing malignant teratoma (Solomon, 1951), Anitschkow myocyte tumour (Mainwaring and Ayres, 1952), undifferentiated pericardial mesenchymoma (Bickford, Egan, and Bryce, 1956), and mixed mesenchymoma (Hagström, 1961).

Bone- and cartilage-forming neoplasms of the heart are very rare. Cumming and Shillitoe (1957) described a bone-forming tumour which arose in the left pulmonary vein, extending into the left atrium and obstructing the mitral orifice. Part of this consisted of well-formed non-malignant osseous tissue which rapidly gave way to an osteogenic sarcoma. Hagström (1961) described a tumour which arose in the infundibulum of the right ventricle extending along the pulmonary artery; it was of mixed histological appearance, part fibrosarcoma, part osteochondrosarcoma, part rhabdomyosarcoma. The portion with the cartilaginous component arose from the pulmonary valve cusp and was rather unlike the present case in that the nodules were predominantly spindle-cell sarcoma 'in which there had developed small nodules of very primitive cartilage and also small foci with slender spicules of bone'.

Vacek (1963) reported an intracardiac hamartoblastoma arising from the region of the fossa ovalis, which filled most of the right atrium and ventricle and part of the left atrium. Microscopy revealed a variety of histological appearances. The outer layers were myxomatous. Elsewhere cords of mucin-containing epithelial cells and aggregations of cartilage-like material presented an appearance reminiscent of salivary gland pleomorphic adenoma. Deeper lay solid onion-like cords of epithelial cells, some showing a cribriform appearance, interpreted as indicating mesothelial origin. Glands, lined by cuboidal or cylindrical epithelium, were present in pulmonary artery metastases as well as in the primary tumour.

Bone (Goldberg and Steinberg, 1955) and cartilage (Lekisch, 1957) are also rare in myxoma. Cartilage has been found in intracardiac cysts, associated with ciliated epithelium (Brandt, 1951).

It is interesting to note that hamsters inoculated with polyoma virus develop primary heart neoplasms. A few of these may show areas of cartilage, atypical osteoid, and bone (Stanton and Otsuka, 1963). While some of these cancers could be explained on the grounds of neoplastic conversion of the normal cartilaginous aortic ring,

several were far removed from the site of the normal cartilage. Farris, Yeakel, and Seitner (1946) found normal-appearing ossifying cartilage attached to the left ventricular endocardium of rats.

The present tumour, with cartilaginous, fibrous, and angiomatous components, is patently a malignant neoplasm of mesenchymal tissues. The large bizarre cells seen in the superficial layers (Fig. 13), being surrounded by reticulin, seem to represent an area of polymorphous cell sarcoma. There was no evidence of a pre-existing hamartoma (Raeburn, 1953), such as was found by Forker *et al.* (1963), but such a malformation could well have been destroyed by the proliferating tumour. There was no suggestion of the epithelial or cystic structures described by Vacek (1963). The histologically benign tumours of pericardial origin (Perry and Rogers, 1934; Anderson and Dmytryk, 1946), which usually arise in the region of Tawara's node, are cystic. The neoplasm shows a certain similarity to the rare mesenchymal chondrosarcoma reported by Lichtenstein and Bernstein (1959) and by Dahlin and Henderson (1962). These tumours exhibited relatively benign round or oval chondroid islets set in a highly anaplastic intervening stroma, the contrast in differentiation being characteristic. Such tumours were locally destructive and tended to produce metastases in unusual locations, sometimes after a remarkable delay.

The question arises whether the tumour described in this report was secondary to such a primary malignancy. This is held to be unlikely, as, although observed over a period of six months, at no time did the patient complain of swelling or pains in or around bones or joints (or elsewhere). Eight of the 10 patients reported by Dahlin and Henderson (1962) had palpable skeletal tumours, and nearly all showed calcification. Further, the chondroid moiety of our tumour was highly pleomorphic, no bizarre ovarian or other mid-line tumours were present, and there was an almost complete absence of invasion.

The atheroma of the pulmonary artery and the changes in the alveolar walls suggest a pulmonary hypertension of some duration. The alveolar wall lesions described by Kidd, Carson, and Lamont (1961) and Andrews (1957) were much more extensive, with fibroblastic proliferation and alveolar cuboidal metaplasia.

**CLINICAL FEATURES** The clinical diagnosis will not be discussed, as several excellent reviews of left atrial myxoma and other rare causes of mitral



valve obstruction are available (Goodwin, Stanfield, Steiner, Bentall, Sayed, Bloom, and Bishop, 1962; Beard, McNamara, Cooley, Rosenberg, and Jordan, 1964).

The mode of presentation of our patient was typical and caused us to suspect that something other than rheumatic mitral stenosis was the cause of the rapid heart failure. Had angiography been feasible, the low E.S.R. would have suggested (MacGregor and Cullen, 1959) that the space-occupying lesion was probably not a myxoma.

#### SUMMARY

A mixed mesenchymal sarcoma, largely chondrosarcomatous in structure, arising in the region of the mitral valve, probably from papillary muscle, is described. This tumour was found in a 50-year-old Chinese Singapore housewife who presented with signs of mitral stenosis and with heart failure of rapid onset which failed to respond to therapy.

We wish to thank the Director of Medical Services, Singapore, for permission to publish, and Professor K. Shanmugaratnam and Dr. B. Gellei for histological opinion. Mrs. M. Low cut the sections, Mr. T. C. Tan took the photographs, and Mr. P. A. Samuel typed the script.

#### REFERENCES

- Anderson, W. A. D., and Dmytryk, E. T. (1946). Primary tumor of the heart containing epithelium-like elements. *Amer. J. Path.*, **22**, 337.
- Andrews, E. C. (1957). Five cases of an undescribed form of pulmonary interstitial fibrosis caused by obstruction of the pulmonary veins. *Bull. Johns Hopk. Hosp.*, **100**, 28.
- Beard, E. F., McNamara, D. G., Cooley, D. A., Rosenberg, H. S., and Jordan, J. D. (1964). Unusual causes of obstruction at the mitral valve. *Amer. J. Cardiol.*, **14**, 169.
- Bickford, B. J., Egan, M., and Bryce, A. G. (1956). Surgical treatment of tumours of the heart. A report of two cases. *Brit. J. Surg.*, **43**, 514.
- Brandenburg, R. O., and Edwards, J. E. (1954). Cardiac clinics: Cardiac sarcoma; report of case and comparison with a case of metastatic carcinoma of the pericardium. *Proc. Mayo Clin.*, **29**, 437.
- Brandt, M. (1951). Über Herzcyستن. *Frankfurt Z. Path.*, **62**, 149.
- Brucker, E. A., and Glassy, F. J. (1955). Primary reticulum-cell sarcoma of the heart with review of the literature. *Cancer (Philad.)*, **8**, 921.
- Cumming A. R. R., and Shillitoe A. J. (1957). Ball-valve mitral obstruction by a sarcoma of a pulmonary vein. *Brit. Heart J.*, **19**, 287.
- Dahlin, D. C., and Henderson, E. D. (1962). Mesenchymal chondrosarcoma. Further observations on a new entity. *Cancer (Philad.)*, **15**, 410.
- Dammert, K., Elfving, K., and Halonen, P. L. (1955). Neurogenic sarcoma in the heart. *Amer. Heart J.*, **49**, 794.
- Farris, E. J., Yeakel, E. H., and Seitner, M. M. (1946). Ossifying cartilage and thrombi in the hearts of rats. *Amer. J. Path.*, **22**, 613.
- Forker, E. L., January, L. E., and Lawrence, M. S. (1963). Primary sarcoma of the mitral valve. *Amer. Heart J.*, **66**, 243.
- Goldberg, H. P., and Steinberg, I. (1955). Primary tumors of the heart. *Circulation*, **11**, 963.
- Goodwin, J. F., Stanfield, C. A., Steiner, R. E., Bentall, H. H., Sayed, H. M., Bloom, V. R., and Bishop, M. B. (1962). Clinical features of left atrial myxoma. *Thorax*, **17**, 91.
- Hagström, L. (1961). Malignant mesenchymoma in pulmonary artery and right ventricle. Report of a case with unusual location and histological picture. *Acta path. microbiol. scand.*, **51**, 87.
- Kidd, B. S., Carson, D. J., and Lamont, E. S. (1961). Intra-atrial sarcoma. *Brit. med. J.*, **2**, 1476.
- Leach, W. B. (1947). Primary neoplasms of the heart. *Arch. Path.*, **44**, 198.
- Lekisch, K. (1957). Myxoma of the left atrium: report of a case. *Ann. intern. Med.*, **46**, 982.
- Lichtenstein, L., and Bernstein, D. (1959). Unusual benign and malignant chondroid tumors of bone: A survey of some mesenchymal cartilage tumors and malignant chondroblastic tumors, including a few multicentric ones, as well as many atypical chondroblastomas and chondromyxoid fibromas. *Cancer (Philad.)*, **12**, 1142.
- Mainwaring, R. L., and Ayres, W. W. (1952). Anitschkow cell sarcoma of the heart. *Amer. J. Path.*, **28**, 823.
- MacGregor, G. A., and Cullen, R. A. (1959). The syndrome of fever, anaemia, and high sedimentation rate with an atrial myxoma. *Brit. med. J.*, **2**, 991.
- Muir, C. S. (1964). Demography and age-sex distribution of the autopsy populations of multiracial Singapore. *Singapore med. J.*, **5**, 96.
- Nath, V. (1931). A case of primary sarcoma of the heart. *Indian med. Gaz.*, **66**, 673.
- Perry, C. B., and Rogers, H. (1934). Lymphangio-endothelioma of the heart causing complete heart block. *J. Path. Bact.*, **39**, 281.
- Raeburn, C. (1953). Papillary fibro-elastic hamartomas of the heart valves. *Ibid.*, **65**, 371.
- Rucks, W. W., Russell, H. T., and Motley, R. F. (1963). Primary reticulum cell sarcoma of the heart. Report of a case. *Amer. Heart J.*, **66**, 97.
- Saphir, O. (1960). Neoplasms of the pericardium and heart. In Gould, S. E. (Ed.), *Pathology of the Heart*, 2nd ed. Thomas, Springfield, Illinois.
- de Sénac, J. [B.] (1783). *Traité de la Structure du Cœur, de son Action, et de ses Maladies*, 2nd ed. Méquignon l'aîné, Paris. Cited by Whorton (1949) *loc. cit.*
- Solomon, R. D. (1951). Malignant teratoma of the heart: report of a case with necropsy. *Arch. Path.*, **52**, 561.
- Somers, K., and Lothe, F. (1960). Primary lymphosarcoma of the heart. Review of the literature and report of 3 cases. *Cancer (Philad.)*, **13**, 449.
- Stanton, M. F., and Otsuka, H. (1963). Morphology of the oncogenic response of hamsters to polyoma virus infection. *J. nat. Cancer Inst.*, **31**, 365.
- Tatsumi, T., Nagatomo, T., and Kashiwai, K. (1949). An autopsy case of primary heart tumor. *Gann*, **40**, 174.
- Vacek, R. (1963). Das intrakardiale Hamartoblastom. *Zbl. allg. Path. path. Anat.*, **104**, 383.
- Whorton, C. M. (1949). Primary malignant tumors of the heart. *Cancer (Philad.)*, **2**, 245.
- Woll, E., and Vickery, A. L. (1947). Primary fibrosarcoma of heart with vertebral metastasis. *Arch. Path.*, **43**, 244.
- Yater, W. M. (1931). Tumors of the heart and pericardium; pathology, symptomatology and report of nine cases. *Arch. intern. Med.*, **48**, 627.