

Pulmonary atresia with left ventricular-right atrial communication: basis for 'circular shunt'¹

KENNETH L. JUE, GEORGE NOREN, AND JESSE E. EDWARDS

From the Departments of Paediatrics and Pathology, University of Minnesota, the Department of Paediatrics, Hennepin County General Hospital, Minneapolis, and the Department of Pathology, The Charles T. Miller Hospital, St. Paul, Minnesota

In the usual instance of an intracardiac right-to-left shunt the blood participating in the shunt traverses a capillary bed before it returns to the chamber from which it originated. In an uncommon instance some of the shunted blood returns to the chamber of origin through intracardiac channels, yielding a phenomenon which may be termed a 'circular' shunt. This term was first used with reference to a case reported from our group by Shone, Anderson, Elliott, Amplatz, Lillehei, and Edwards (1962). In that case it was assumed that some of the right atrial blood had been shunted in a right-to-left direction into the left atrium. Some of this blood then escaped from the left ventricle through a small ventricular septal defect into the right ventricle. Then, in the presence of pulmonary stenosis and of tricuspid insufficiency, some of the blood which had originated in the right atrium returned to that chamber to complete a 'circular' shunt in which each of the four cardiac chambers had participated.

We have studied two additional cases which fulfil the foregoing definition of a 'circular' shunt. In each there was pulmonary valvular atresia in association with a left ventricular-right atrial communication. In the first, the left ventricular-right atrial communication was of the classical variety. In the second, this communication resulted from a combination of Ebstein's malformation of the tricuspid valve and a ventricular septal defect in which the defect opened into that part of the right ventricle which lay proximal to the attachments of the malformed tricuspid valve.

CASE REPORTS

CASE 1 Shortly after birth a 36-hour-old, full-term infant girl showed cyanosis and dyspnoea. Physical examination revealed a cyanotic and tachypnoeic infant with respiratory retraction of the subcostal areas and of the suprasternal notches. No cardiac murmurs were heard, and the cardiac sounds were thought to be normal. The lower edge of the liver lay 4 cm. below the right costal margin and that of the spleen at the left costal margin. Chest radiographs showed mild cardiomegaly and diminished pulmonary vascular markings (Fig. 1). The electrocardiogram was interpreted as showing a normal axis for age, right atrial enlargement, and left ventricular preponderance (Fig. 2).

A forward angiocardiogram, taken at the University of Minnesota Hospitals when the infant was 23 hours old, was interpreted as representing pulmonary atresia with an intact ventricular septum (Fig. 3). A deteriorating condition, despite intensive medical management, led to the transfer of the patient to the Hennepin County General Hospital for surgical treatment under hyperbaric conditions. Under these conditions, with halothane anaesthesia and with the aid of inflow occlusion, valvulotomy of the atretic pulmonary valve was performed. The child failed to improve and died on the operating table.

Pathologically, the findings were related to the heart. The main ventricular mass was formed by the left ventricle. The pulmonary trunk was narrow and normally related to the aorta, which was wider than normal. The ductus arteriosus was patent. The pulmonary valve, which had been atretic, was found, for the most part, to have been removed during the surgical procedure. The right ventricle showed the features commonly seen in pulmonary valvular atresia, since its chamber was hypoplastic and its wall was relatively thick. No septal defect led into this chamber. In concert with the hypoplastic nature of the right ventricle, the tricuspid valve was hypoplastic although the individual leaflets could be identified.

¹This study was supported by Research Grant HE-5694 and Training Grant 5 T1 HE 5570 of the National Institutes of Health, United States Public Health Service.

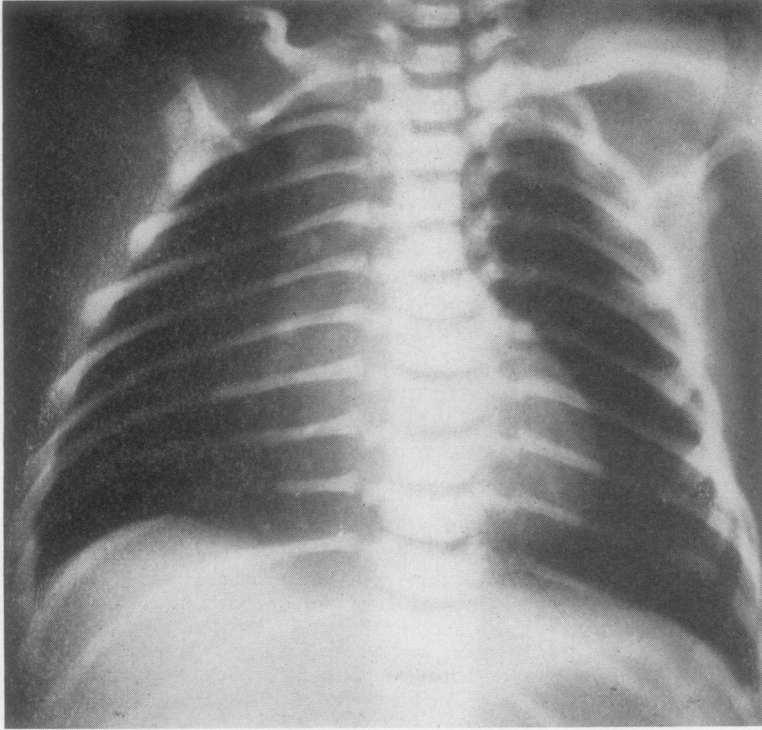
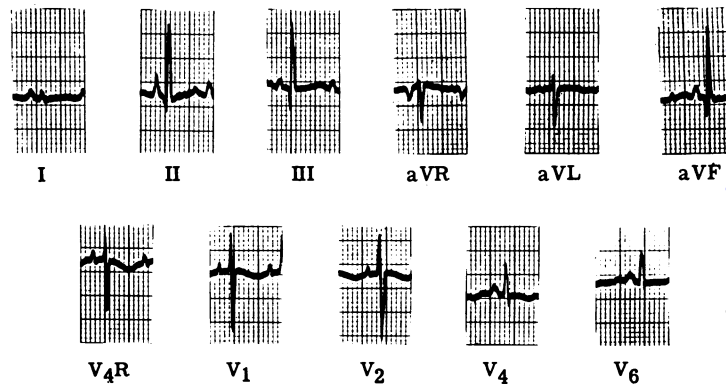


FIG. 1. Case 1. Frontal radiograph of thorax. Marked decrease of pulmonary vascular markings. The pulmonary arterial segment is concave.

FIG. 2. Case 1. Electrocardiogram. Peaked P waves in lead II, indicating right atrial enlargement. Normal electrical axis in the frontal plane. Left ventricular preponderance.



A communication, 2 mm. in diameter (Fig. 4), was found between the left ventricle and the right atrium. The left ventricular opening of this communication lay in the ventricular septum below the junction of the right and posterior aortic cusps. The right atrial opening lay in the septal wall immediately superior to the septal leaflet of the tricuspid valve. The right atrial cavity was enlarged and the foramen ovale was patent. In the left side of the heart the aortic and mitral valves were normal and the left ventricular chamber was somewhat enlarged.

CASE 2 A 7-day-old, cyanotic infant girl was referred to the University of Minnesota Hospitals for evaluation. Physical examination revealed a cyanotic infant in no distress. No thrill was palpable. A grade II (on basis of I to IV) pansystolic murmur was best heard in the second and third intercostal spaces along the left sternal border. The second cardiac sound was single (with marked diminution of the pulmonic component). No diastolic murmurs or ejection clicks were heard.

An electrocardiogram was interpreted as showing a normal axis for age, right atrial hypertrophy, and

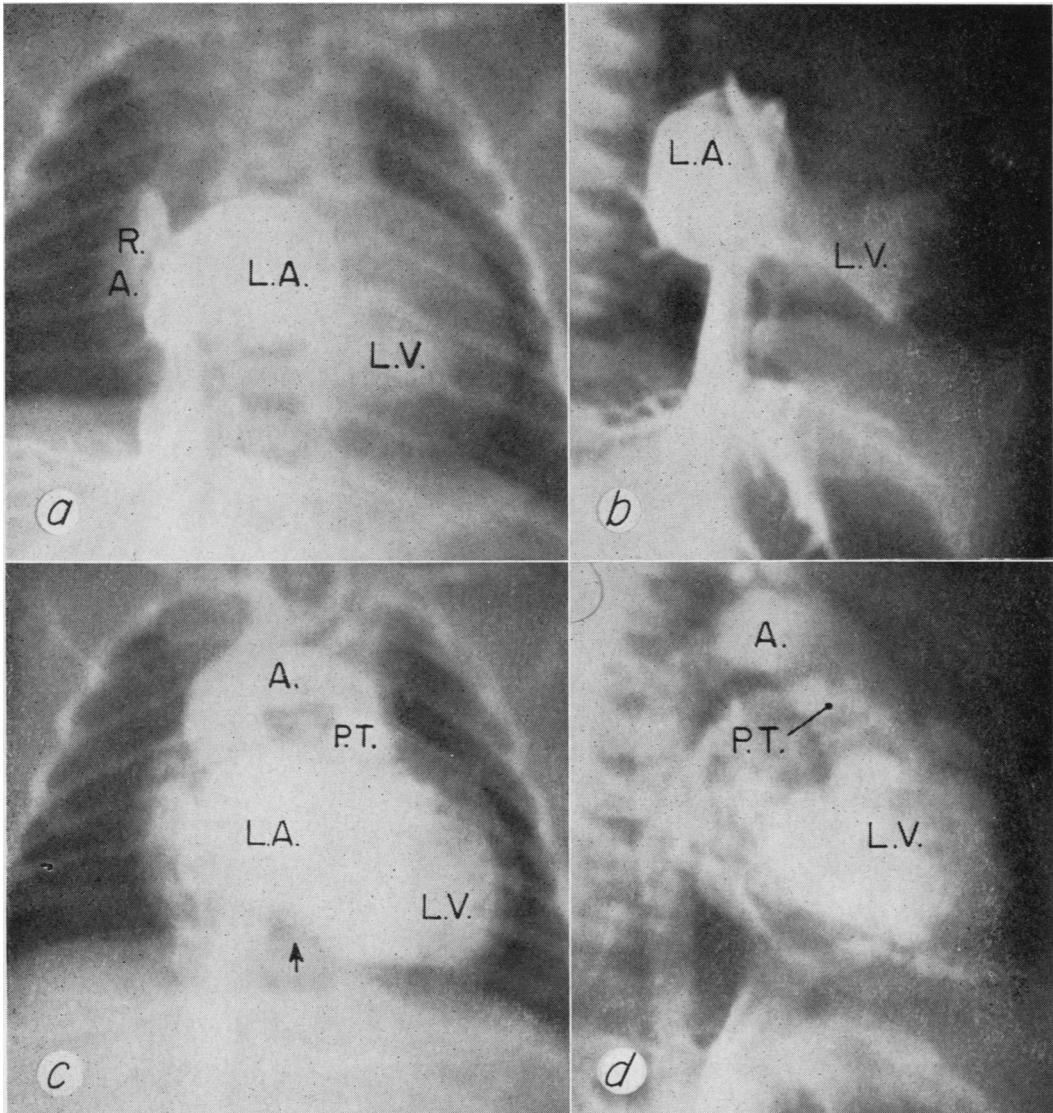


FIG. 3. Case 1. Venous angiogram: (a) and (b) early phases of frontal and lateral views, respectively. Contrast material extends from the opacified right atrium (R.A.) (in frontal view) into the left atrium (L.A.), and from the latter chamber into the left ventricle (L.V.); (c) and (d) late phases of study in frontal and lateral views, respectively. Opacification of the left atrium (L.A.), left ventricle (L.V.), and aorta (A.). The aorta is markedly dilated. The pulmonary trunk (P.T.), which is hypoplastic, has been opacified through a patent ductus arteriosus. In the frontal view (c) the arrow indicates the position of an opacified right ventricle.

left ventricular hypertrophy (Fig. 5). Chest radiographs showed a concentrically enlarged and globular heart (Fig. 6). The pulmonary arterial segment was flat but not distinctly concave. The peripheral pulmonary vascular markings were markedly diminished.

A venous angiogram from a saphenous vein (Fig. 7) was interpreted as being compatible with

pulmonary atresia, an intact ventricular septum, and a hypoplastic right ventricle. When 4 weeks of age the patient developed congestive cardiac failure, but responded well to medical management. With the infant in an apparently optimal physical condition, an end-to-end anastomosis between the pulmonary trunk and the innominate artery was performed. Marked re-

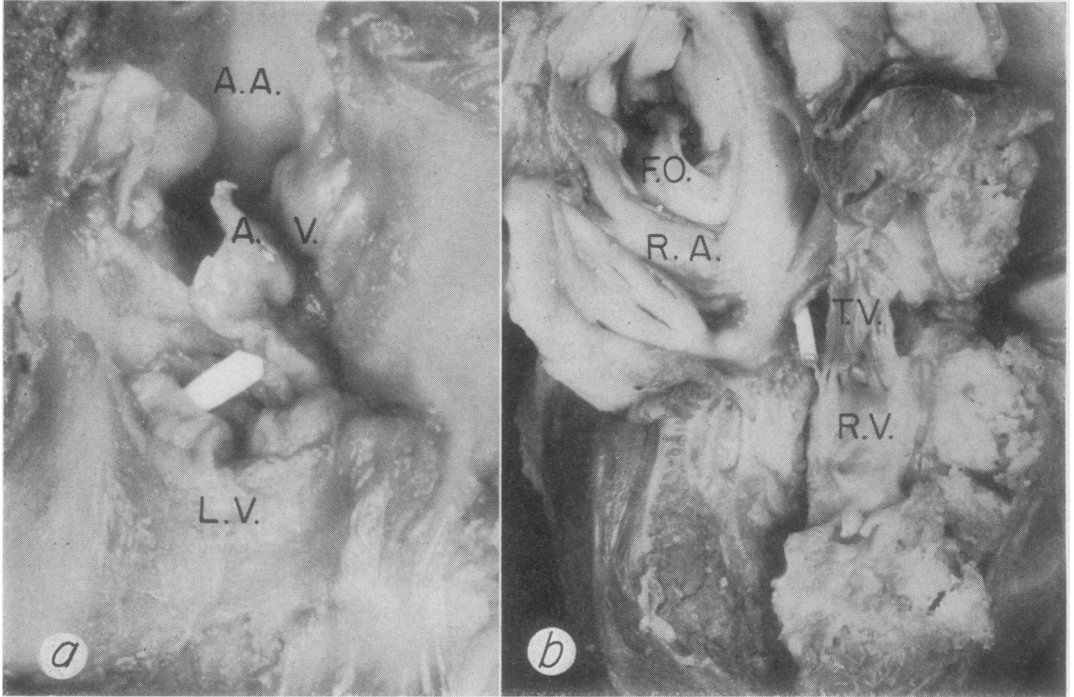


FIG. 4. Case 1. Gross specimen of heart. (a) Interior of left ventricle (L.V.) and the ascending aorta (A.A.). Immediately inferior to the level of the aortic valve (A.V.) is a defect (containing probe). This leads from the left ventricle into the right atrium, beyond. (b) Right atrium (R.A.) and right ventricle (R.V.). The right ventricular chamber is hypoplastic. The pulmonary valve is atretic. Above the tricuspid valve (T.V.) is a defect (containing probe) representing a communication between the left ventricle (beyond) and the right atrium. The foramen ovale (F.O.) is patent.

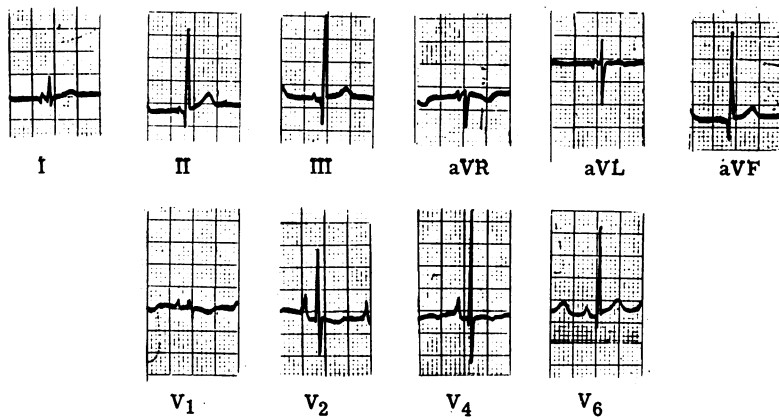


FIG. 5. Case 2. Electrocardiogram. In frontal plane normal electrical axis for age. Right atrial enlargement (peaked P waves in leads V_2 and V_3) and left ventricular hypertrophy.

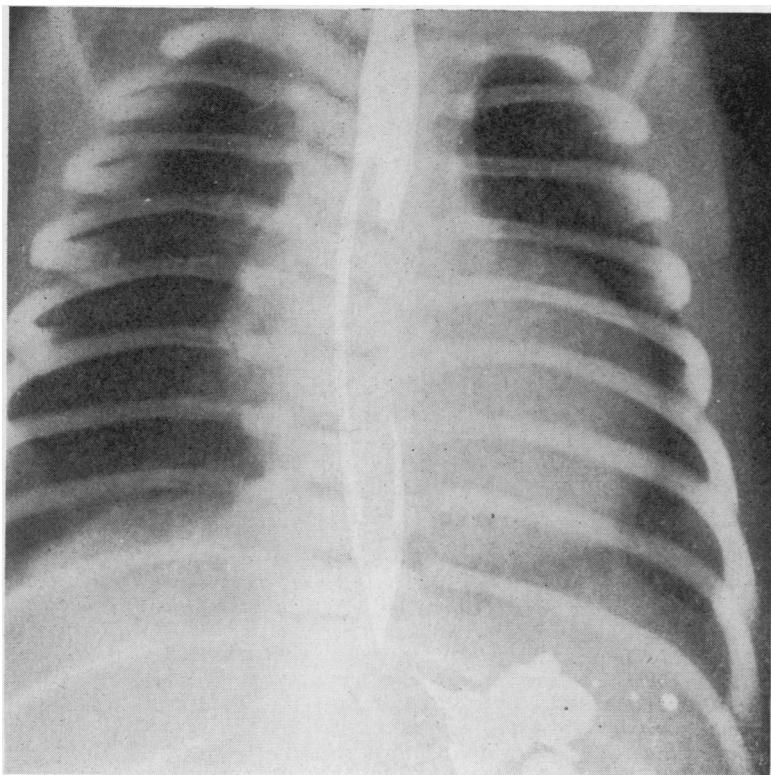


FIG. 6. Case 2. Frontal chest radiograph. Decreased pulmonary vascular markings, left ventricular enlargement, and lack of prominence of pulmonary arterial segment.

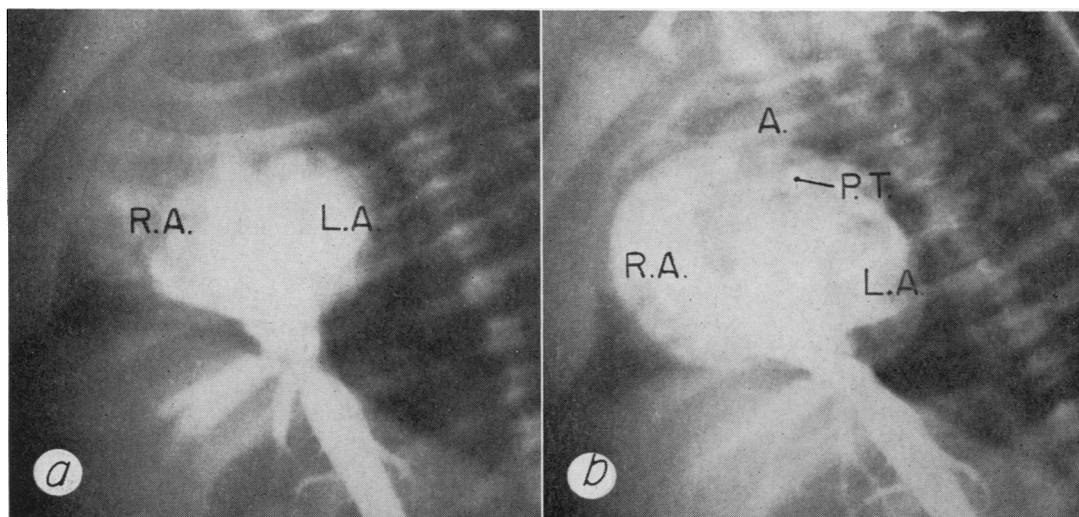


FIG. 7. Case 2. Venous angiogram. (a) Early phase in left anterior oblique view. Right-to-left shunt at the atrial level. R.A.=right atrium; L.A.=left atrium. (b) Late phase in left anterior oblique view. Opacification of right atrium (R.A.), left atrium (L.A.), and left ventricle. The aorta (A.) is markedly dilated and the pulmonary trunk (P.T.), which has been opacified through a patent ductus arteriosus, is correspondingly hypoplastic.

H

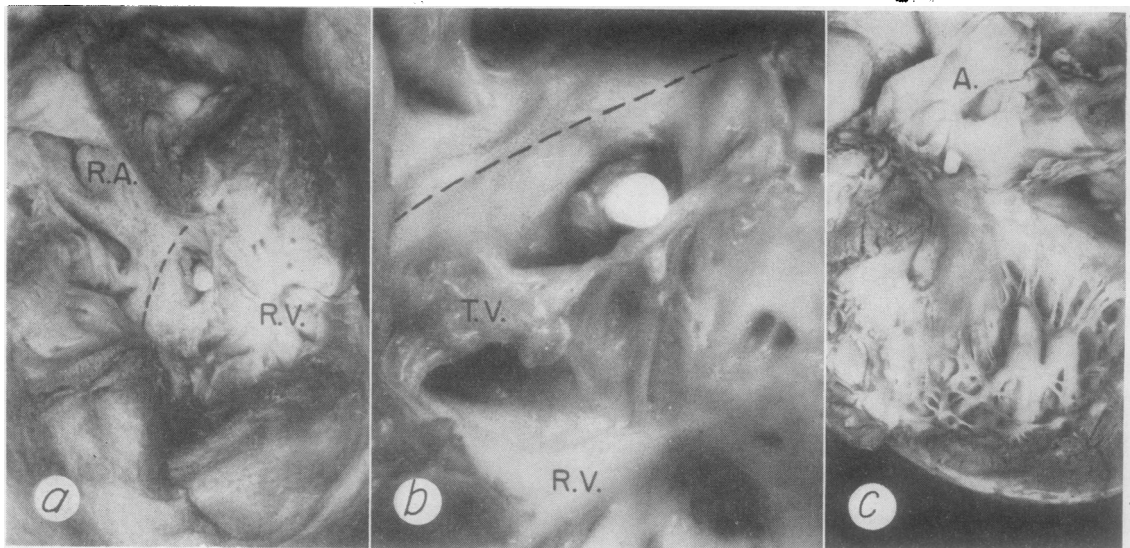


FIG. 8. Case 2. Pulmonary atresia associated with an Ebstein-like malformation of the tricuspid valve and a small defect of the ventricular septum yielding a communication between the left ventricle and the right atrium. (Illustrations from Elliott et al. (1963). Reproduced with permission.) (a) Interior of right atrium (R.A.) and right ventricle (R.V.). The tricuspid valve is displaced downward from the annulus fibrosus (dotted line) as part of an Ebstein's malformation. The probe lies in the communication between the left ventricle and the 'atrialized' portion of the right ventricle which lies above the tricuspid valve. (b) View of tricuspid valve (T.V.) and adjacent structures. Tricuspid valve is inserted below the annulus fibrosus (dotted line). Probe in defect. (c) Left ventricle and aorta (A.). Probe lies in the defect which leads to the 'atrialized' portion of the right ventricle beyond.

spiratory distress developed 24 hours after the operation and the infant died soon afterwards.

At necropsy the heart was found to be slightly enlarged and the great vessels normally related. The ductus arteriosus was patent and the pulmonary trunk hypoplastic. The main ventricular mass was formed by the left ventricle. The right atrium was dilated and hypertrophied.

The pulmonary valve was atretic and the right ventricle hypoplastic. The tricuspid valve showed an Ebstein's malformation in which its septal and posterior leaflets were attached to the right ventricular wall below the annulus of the valve.

A narrow ventricular septal defect (Fig. 8), measuring about 1 mm. in diameter, was present. From the left ventricular side the defect lay immediately inferior to the right aortic cusp. From the right ventricular side the defect was found to open into that part of the right ventricle which lay proximal to the malformed tricuspid valve; that is, the defect communicated with the 'atrialized' portion of the right ventricle.

This case was included in the report of Elliott, Adams, and Edwards (1963) on pulmonary atresia with intact ventricular septum. In that report emphasis was placed on polypoid, loose, fibrous tissue attached to the rim of the defect. It is suggested that this tissue, in company with nearby tricuspid valvular

tissue, might have closed the defect during systole. The right atrium was grossly enlarged and the foramen ovale was patent.

COMMENT

In each of the cases presented there was a communication, though narrow, between the left ventricle and the right atrium in the presence of pulmonary atresia. Although venous angiocardiology had been performed in each patient, the left ventricular-right atrial communication was not identified. This may have resulted from a rapid circulation time, so that during the levo-phase of the study opaque material was still present in the right atrium. A left ventriculogram might have demonstrated the left ventricular-right atrial communication. In spite of this, one may assume that some blood passed from the left ventricle to the right atrium. If one refers to the diagrams of the basic abnormalities in each of the two cases reported (Fig. 9), several features are apparent. The first is that in the presence of pulmonary atresia and without a communication between the two propelling ventricles, blood in the right atrium is shunted into the left atrium

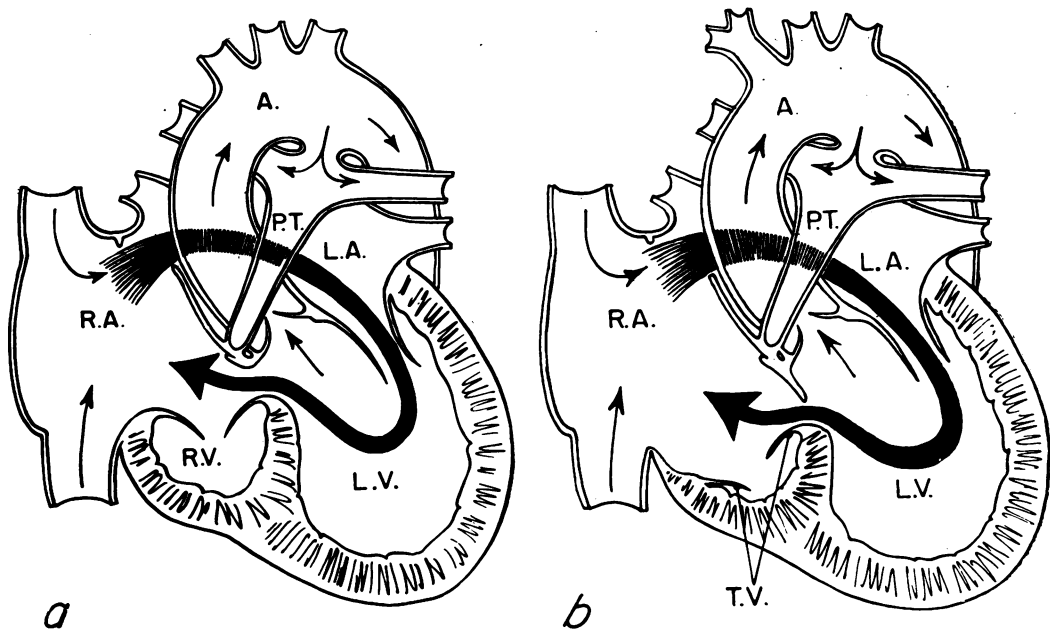


FIG. 9. Diagram of the central circulation in the two cases reported. (a) Case 1. Pulmonary valvular atresia associated with left ventricular-right atrial communication. A circular shunt is engendered by the presence of pulmonary atresia, the left ventricular-right atrial communication, and the patent foramen ovale. Of the blood in the right atrium which shunts into the left atrium and then flows into the left ventricle, some is recirculated into the right atrium through the left ventricular-right atrial communication. (b) Case 2. Pulmonary valvular atresia associated with Ebstein's malformation of the tricuspid valve and a communication between the left ventricle and the 'atrialized' portion of the right ventricle. As in case 1, of the blood originating in the right atrium and then shunting into the left atrium and the left ventricle, some, in turn, is delivered through the abnormal communication into the right atrium to complete the 'circular' shunt.

through the foramen ovale. This blood then reaches the left ventricle, from which chamber some of the blood which had originated in the right atrium returns directly to this chamber. In this way the definition of a 'circular' shunt is fulfilled. It is recognized that, in the situation peculiar to each of the two cases presented, the propelling right ventricle does not participate as a conduit in carrying right atrial blood back to the right atrium. This is in contrast with the 'circular' shunt in the case of Shone *et al.* (1962).

In each of our cases the small size of the left ventricular-right atrial communication probably precluded the 'circular' shunt from being of large volume. As indicated, Elliott *et al.* (1963) suggested that the defect in case 2 might have been closed during systole by the accessory tissue in relation to the defect. The two cases are instructive because the same findings may be present in other cases in which, under basically similar conditions, the left ventricular-right atrial

communication is wider than in the two cases here presented.

The co-existence of a left ventricular-right atrial communication with pulmonary atresia has previously been noted (Lauer, Fink, Petry, Dunn, and Diehl, 1964).

SUMMARY

A 'circular' shunt is defined as a condition in which blood originating in one cardiac chamber is shunted through the heart to return to the original chamber without having passed through a capillary bed.

In each of two cases of pulmonary atresia a left ventricular-right atrial communication was associated. In one the later communication was of the classical variety. In the other, an Ebstein's malformation of the tricuspid valve was present. In this instance a ventricular septal defect entered

the right ventricle proximal to the valve and in this way accounted for the left ventricular-right atrial communication.

In each case, on the basis of the pulmonary atresia, a right-to-left transatrial shunt occurred. It is assumed that some of the blood which had originated in the right atrium was returned to the right atrium after passing through the left atrium and the left ventricle. This peculiar course of the

blood would fulfil the definition of a 'circular' shunt.

REFERENCES

- Elliott, L. P., Adams, P., Jr., and Edwards, J. E. (1963). Pulmonary atresia with intact ventricular septum. *Brit. Heart J.*, **25**, 489.
- Lauer, R. M., Fink, H. P., Petry, E. L., Dunn, M. I., and Diehl, A. M. (1964). Angiographic demonstration of intramyocardial sinusoids in pulmonary-valve atresia with intact ventricular septum and hypoplastic right ventricle. *New Engl. J. Med.*, **271**, 68.
- Shone, J. D., Anderson, R. C., Elliott, L. P., Amplatz, K., Lillehei, C. W., and Edwards, J. E. (1962). Clinical pathologic conference. *Amer. Heart J.*, **64**, 547.