

## PULMONARY EMBOLISM

BY

P. R. ALLISON, M. S. DUNNILL, AND R. MARSHALL

*From the Nuffield Department of Surgery, Oxford*

The sudden reduction of the pulmonary vascular bed to one half its natural volume by the ligation of the left or right pulmonary artery under anaesthesia, as is frequently performed for excision of a lung, is not associated with any serious cardiovascular disturbance. That this is independent of anaesthesia has been proved by the blocking of one main branch of the pulmonary artery by a balloon on a cardiac catheter passed through an arm vein under local anaesthesia (Carlens, Hanson, and Nordenström, 1951; Brofman, Charms, Kohn, Elder, Newman, and Rizika, 1957). This phenomenon is not surprising if it is realized that the lungs take the total cardiac output, and that this may be increased three or four times with moderate exercise. The doubling of the flow through one lung by the obstruction of the opposite pulmonary artery therefore throws a strain on the circulation that is only slight compared with its everyday experience.

The pathologist and the clinician alike frequently express surprise that a patient may collapse and die between the first and second weeks after operation from an embolus which at necropsy hardly seems big enough to obstruct the pulmonary circulation as much as a ligature round one main branch.

These observations have given rise to much discussion, many possible interpretations, and a considerable amount of experiment. Some investigators using glass beads, starch, or lycopodium powder, lead shot, or turnip seeds, have made useful contributions to the knowledge of the anatomy of the pulmonary circulation, but the reports on intrapulmonary vascular reflexes as possible causes of acute vascular insufficiency have not been consistent or convincing.

The surgeons, on their side, have been more or less satisfied that the trouble begins on the operation table when the muscles are relaxed and when pressure on the calf muscles may occur. They have taken steps towards avoiding venous thrombosis by placing air cushions under the tendo Achillis to keep the calf muscles off the table, by nerve stimulation to keep the muscles contracting

at intervals during operation, and by early post-operative ankle movements.

It has been shown recently (McLachlin, McLachlin, Jory, and Rawling, 1960) that radio-opaque dye can remain for up to an hour in the valve sinuses of the deep veins of the leg when it is horizontal, and that the radio-opacities thus demonstrated correspond to the position, shape, and size of the clots found in the veins at necropsy. It has also been shown by the same investigators that elevation of the leg to 15° is a more effective way of emptying the veins than are active movements.

Prophylactic measures are carried out with varying degrees of vigour in different clinics, but the sad fact remains that many surgical patients, and still more medical patients, with or without heart failure, die from pulmonary embolus. In the Radcliffe Infirmary at Oxford during the year 1957 there were 838 necropsies, and in 70 (8%) of these the cause of death was pulmonary embolism. This figure corresponds with statistics from many other centres. Some patients die suddenly, some may take a few hours, occasionally they may die after a few days or even weeks, and some unaccountably recover. It has been said, but with no more precise backing than clinical observation, that those who recover do so completely without any residual physical handicap.

Precise answers are needed to the following questions:

(1) What is the day-to-day history of a thrombus that forms in peripheral veins, becomes detached in the circulation and lodges in the lung?

(2) Why does a patient die from a clot which often seems too small to affect a large enough area of the pulmonary vascular bed?

(3) If a clot lodges in a pulmonary artery without causing death, is it completely absorbed, leaving a full-lumen vessel with smooth intima and normal circulation, or does the vessel recanalize inefficiently and incompletely, with diminished flow and diminished lung function?

An interest in these problems has been stimulated by the following histories of two patients.

## CASE REPORTS

CASE 1.—H. W., a man aged 59, had had good health and his weight had increased by 21 lb. in 16 months after giving up smoking. In February, 1957, he developed pleuritic pain in the right axilla. He was treated at home for a week, when a radiograph showed an opacity thought to be caused by pneumonia and pleurisy (Fig. 1). A month later he complained of pain in the right calf which was relieved by rest, and in April, 1957, he was admitted to the Southampton Chest Hospital for investigation. His pulse was 92, and his blood pressure 175/110 mm. Hg. The left ventricle was enlarged, and a radiograph showed an opacity in the apex of the right lower lobe (Fig. 2). An electrocardiogram showed a partial right bundle branch block and ventricular ectopic beats. He was thought to have an inflammatory lesion in the right lung for which he was given penicillin and streptomycin. In June, 1957, because some opacity remained in the lung field the right side of the chest was explored. At operation the lung was found to be totally adherent by adhesions which were dense over the apical and posterior basal segments of the lower lobe but flimsy over other parts. There was a nodule, 3 cm. by 2 cm., in the apex of the lower lobe. The rest of the lung appeared normal. Right lower lobectomy was carried out, and a note was made that the dissection of the artery was difficult because of a dense inflammatory reaction around it. When the artery was cut it was seen to be filled with thrombus, and the seat of intimal thickening which suggested endarteritis. The report on the specimen by Dr. R. Goodbody, the pathologist, stated that the lobar branch of the pulmonary artery was thrombosed, and

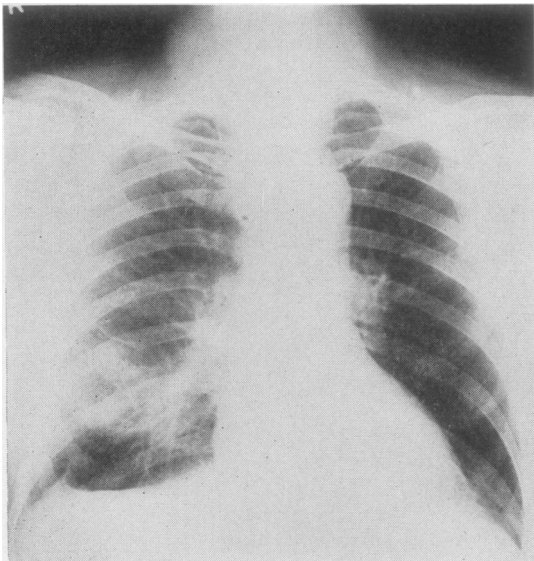


FIG. 1.—H.W.: Radiograph taken on February 8, 1957, at the time of right-sided pleurisy.

microscopic examination showed it to be organizing (Fig. 3). The nodule in the apex of the lobe was a quiescent tuberculous focus of many years' standing.

In August, 1957, he returned to work feeling well, but 10 days later, while walking, he became very breathless and felt "as though he had influenza." After four days his dyspnoea became worse, and was accompanied by a persistent, left-sided pleural pain. In September, 1957, he was readmitted to hospital under the care of Dr. MacLeod. The important findings were: Dyspnoea at rest, cyanosis, pulse 120, auricular fibrillation, impaired percussion note, friction rub, and crepitations at the left base. A radiograph on September 5, 1957, showed an enlarged heart, distended superior vena cava, a hazy opacity in the lower half of the right chest, and a circumscribed opacity above the diaphragm on the left side (Fig. 4). The right calf was unduly firm and 1.5 cm. larger than the left. The patient was given 10,000 units of heparin intravenously and an initial dose of 250 mg. of "phenindione." Thereafter phenindione was given according to the prothrombin index. He was also treated with penicillin, digitalis, mersalyl, oxygen, and a low-salt diet.

So far he had had no haemoptysis, but shortly before death he coughed blood on a few occasions and he went into coma. A radiograph taken on September 15, 1957, the day before death, is shown in Fig. 5.

At necropsy on September 16, 1957, there was some 600 ml. of blood-stained fluid in the left pleura and the whole left lung appeared to be infarcted. An enormous embolus blocked the left main pulmonary artery. A smaller embolus was adherent to the wall

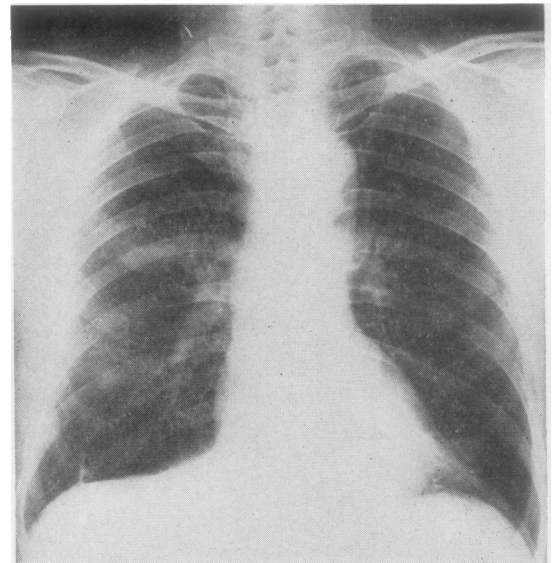


FIG. 2.—H.W.: Radiograph taken on April 3, 1957, showing an opacity in the apex of the right lower lobe.



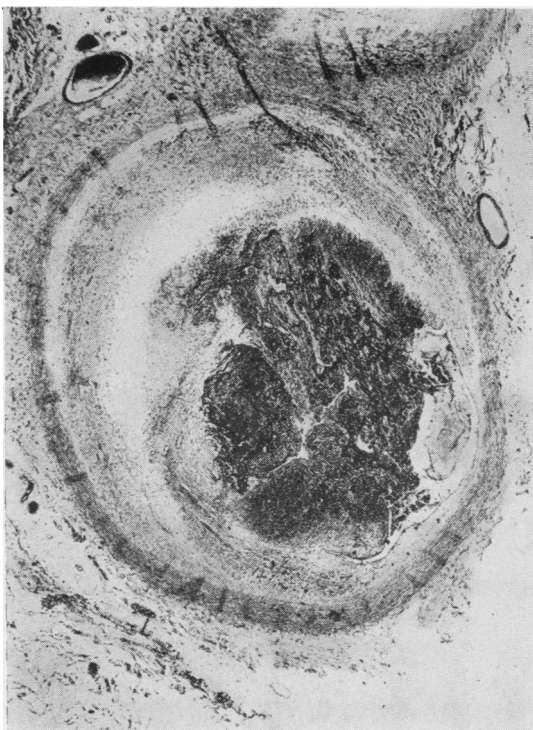


FIG. 3

FIG. 3.—H.W.: Photomicrograph of organizing thrombus in the right lower lobe artery.  $\times 16$ . (Masson's trichrome.)

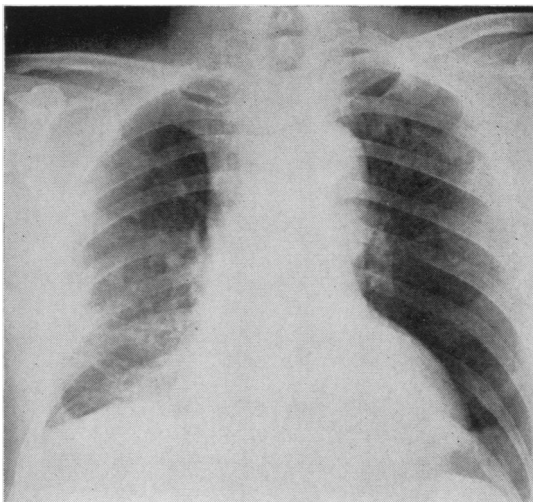


FIG. 4

FIG. 4.—H.W.: Radiograph on September 5, 1957, taken when the patient was gravely ill. Hazy opacity on the right and circumscribed opacity above the left diaphragm. At this time patient was in cardiac failure with dilatation of the heart and great veins.

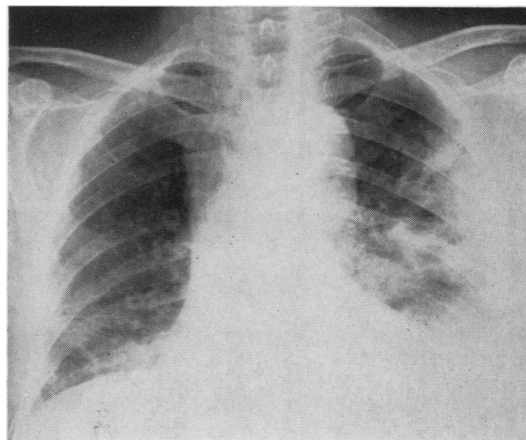


FIG. 5

FIG. 5.—H.W.: Radiograph taken the day before death, showing dilatation of the heart and great veins and infarcts of left lung with some pleural fluid.

of the right pulmonary artery. The right ventricle was much dilated, and the left femoral vein was completely occluded by clot.

This man, therefore, took seven months to die of repeated pulmonary emboli which arose from thrombosed veins of the right leg. The first clinically obvious embolus was to the right lower lobe. This embolus was not absorbed but became organized and completely obliterated the right lower lobe artery. The early radiographic appearances were complicated by an old tuberculous focus which at operation was the only abnormality in an otherwise healthy-looking lung. The later radiographs which showed opacities were influenced by left ventricular failure, for by this time the patient had enlargement of the heart, bundle branch block, and an electrocardiographic pattern of increasing strain. Only in the last stage of heart failure did haemoptysis occur.

CASE 2.—C. W., a man aged 29 years, had been healthy and vigorous without any significant previous illness. On February 22, 1958, he received a severe kick on the right thigh while playing football. The thigh became very swollen with an estimated blood loss into the tissues of 2 to 3 pints. After a period of immobilization in hospital he was fitted with an elastic bandage and sent home.

On March 8, 1958, he bumped his right thigh and fainted, and after this he became short of breath. On March 17, 1958, he suddenly had a pain in the epigastrium and felt "queer." While trying to go upstairs to bed he became very dyspnoeic and dizzy and fainted again.

He was admitted to hospital complaining of pleuritic pain in the right lower chest and epigastrium. A radiograph showed the lung fields to be clear (Fig. 6). It was noted that the right thigh was still swollen and

that the blood pressure was very variable, falling to 65/60 mm. Hg if he tried to sit up or to turn on to his left side. He was given a blood transfusion.

On March 20, 1958, he was gravely ill. Examination was difficult because if he was turned on to his left side or propped up he fainted. The right thigh was still swollen and cyanosed, but the pulses at the ankles were palpable. A radiograph showed some right-sided pleural effusion (Fig. 7), and the electrocardiogram indicated increasing right heart strain. The next day there was further deterioration. A diagnosis of packing pulmonary emboli was made. The striking effect of posture on the circulation raised the possibility of thrombus in the auricle blocking the tricuspid orifice in the left lateral position, but exploration seemed indicated in either case.

Operation was performed on March 21, 1958. The patient was cooled in a water-bath to 29° C. and the chest opened by a trans-sternal approach passing into the third interspace on each side. The left lung and pleura appeared normal; 600 ml. of slightly blood-stained fluid was aspirated from the right pleural cavity. The right upper and middle lobes looked normal, but the lower margin of the lower lobe was firm and felt like liver. No clot was found in the right auricle. The venae cavae were occluded and the main pulmonary artery opened. Dark blood welled up from the distal vessels but no clot was seen. Powerful suction applied down the right pulmonary artery produced nothing but blood. Embolectomy forceps were then passed and a mass of tough thrombus removed from the right pulmonary artery. After this suction was effective in drawing out many lengths of softer "tailed" thrombus, the tails representing branches of the artery. Although there had never been any signs in the left lung and in spite of this looking normal when exposed, similar firm thrombus with soft tails was removed by forceps from the left pulmonary artery (Fig. 8). The vessel was then closed by continuous suture, the circulation restored, and the chest closed.

The right external iliac vein was ligatured and no thrombus was present at this level. Apart from the development of gangrene of the toes of the right foot he recovered completely. Fig. 9 shows the radiographic appearance of the chest four months after embolectomy.

This patient, therefore, after an injury to the thigh with much vascular damage, threw off emboli into his lungs over a period of one month before he approached the point of death. Some of the emboli were presumably big ones and associated with major circulatory changes, but it seems likely, from the insidious onset of dyspnoea and "queer feelings," that smaller emboli were occurring more often without causing dramatic disturbance. After the major attacks the radiograph of the chest was clear, and the left lung remained so even though firm clot was found in the left pulmonary artery at operation.

On the technical side the point most worthy of note is that powerful suction is inadequate for removal of

anything but very loose soft clot from blood vessels. For adherent clot, forceps are necessary.

#### EXPERIMENTAL INVESTIGATIONS

The original object of the experiments was to find out if a non-fatal pulmonary embolus was absorbed completely, leaving a normal pulmonary artery and normal lung function, or if permanent changes like those found in the lower lobe artery of Case 1 were to be expected. There might, of course, be some circumstances in which the one process occurred and in some the other. If arteries were to be examined histologically after given intervals from the lodging of the embolus it was important to know exactly which artery had been affected. The best way of knowing this seemed to be to make the embolus radio-opaque and localize it under radiographic control.

#### METHODS

Most radio-opaque substances added to blood stopped it from clotting, but finally the following procedure was found to be effective: 5 ml. of blood was withdrawn from the fore-leg vein of the dog into a siliconized syringe and transferred in an ice-box; 0.5 g. "dionosil" powder was placed on a sterilized watch glass and made into a paste with a few drops of the dog's blood. Glass cannulae with smooth bevelled ends were made of varying diameter each with a glass plunger on which a rubber bung was fixed. The rubber bung fitted the inside of the tube exactly. A tube of appropriate size for the experiment was chosen and autoclaved. With the plunger withdrawn 10-15 cm., according to the size of embolus required, 0.5 ml. of brain thromboplastin was instilled and the tube rotated in order to spread this round the inner wall. The radio-opaque paste was mixed with the blood evenly and the mixture poured into the cannula. The cannula was held horizontally and rotated around its long axis to produce even contact with the thromboplastin and avoid air bubbles. In a few minutes a good radio-opaque clot was formed and it was ready for injection by pressure on the plunger.

The dogs were premedicated by subcutaneous injection according to the following formula:

Morphia	..	1.27 mg.
Atropine	..	0.059 mg.
Largactyl	..	1.06 mg. for each kilogram of body weight

Half an hour later the 5 ml. blood was aspirated for making the clot, and nembutal was given intravenously until the animal relaxed.

The clots were injected into either the left jugular vein or the inferior vena cava. In the former event a small incision over the vein was all that was necessary. In the latter a right abdominal incision parallel with the outer border of the rectus abdominis was made, the intestine drawn over to the left and the posterior peritoneum incised over the inferior vena cava below the renal veins. About 5 cm. of the cava



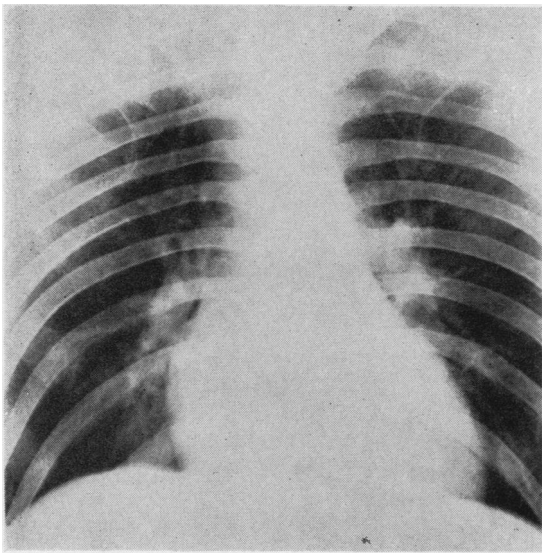


FIG. 6

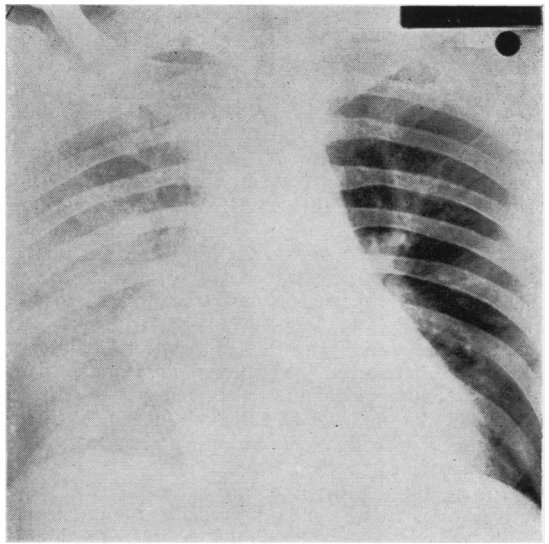


FIG. 7

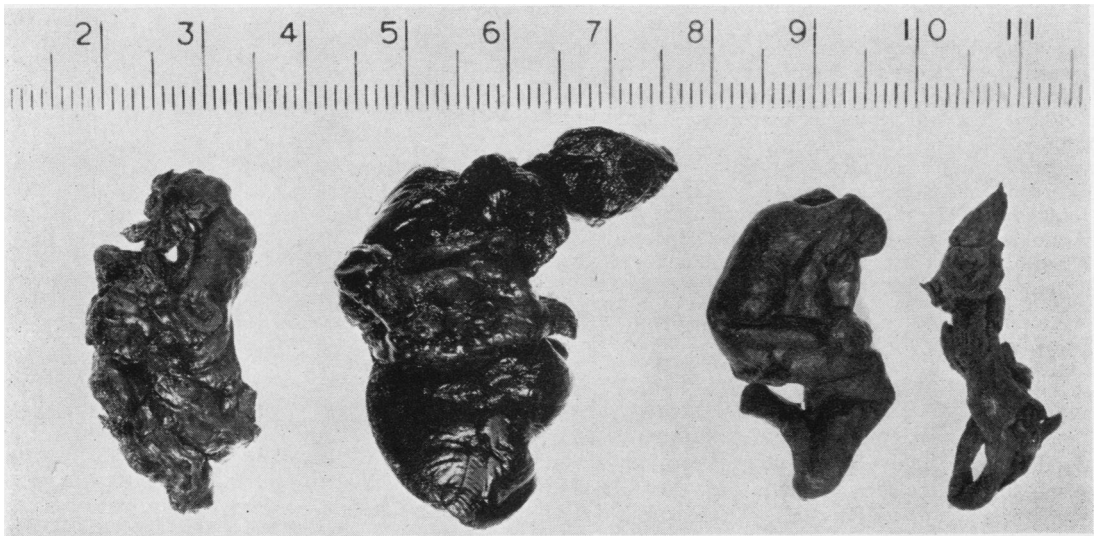


FIG. 8

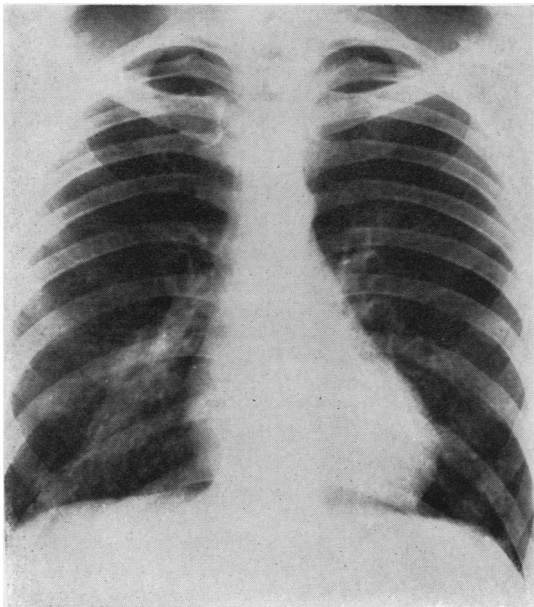


FIG. 9

FIG. 6.—C.W.: Radiograph taken on March 18, 1958, 24 days after injury, showing clear lung fields.

FIG. 7.—C.W.: Radiograph (supine) taken on March 20, 1958, 26 days after injury, showing pleural effusion on right side. Left side clear.

FIG. 8.—C.W.: Firm and soft clots, the latter with "tails," removed at operation from the right and left pulmonary arteries.

FIG. 9.—C.W.: Radiograph taken on July 28, 1958, approximately four months after bilateral pulmonary embolectomy.

was isolated and controlled by sling ligatures. Whichever vein was used the animal was maintained on its back without rotation to one or other side. The cannula was inserted into the vein and the injection made on a given signal.

In the first experiments only the time of insertion of the clot was noted and antero-posterior and lateral radiographs were taken immediately and at intervals. In later experiments, injections were made during ciné-radiography so that the passage of the clot through the heart could be visualized. In some experiments the electrocardiogram and systemic artery pressure were recorded throughout.

In one dog the injection was made while pulmonary artery pressure was being recorded through a cardiac catheter, but the clot partially occluded the holes in the catheter, and, as it was not certain if the catheter would influence the passage of the clot, the recording of pulmonary artery pressure during the injection was discontinued. The dog was allowed to recover from the anaesthetic and radiographs were repeated over the following days or weeks.

When the radiographic appearances had been followed for the requisite time, the dog was anaesthetized again, the pulmonary artery pressure was recorded, and exsanguination by arterial section carried out. The carcass was then perfused with 10% formal saline through a catheter tied in a vein. When fixed the lungs were removed and examined histologically.

### RESULTS

The experiments were carried out on eight mongrel dogs. The clots used in the first experiments were small ones in the neighbourhood of  $2 \times 0.2$  cm. Later bigger clots were used, and when these were freshly made they were  $15 \times 0.7$  cm. The initial volume of the clot was 5.5 ml., but owing to retraction the actual size of the clot introduced into the vein was somewhat smaller. The passage of the clot through the heart was studied by ciné-radiography, and this showed that, although the clots did not pass through the heart without impediment, they were injected into the pulmonary vessels within six seconds of their release in the systemic vein. They usually passed through as a single clot, but occasionally a small piece might become detached from the main mass during the churning process inside the heart, and sometimes the clot would fragment. It was found that the large clots as described above containing 0.5 g. of "dionosil," although able to withstand gentle agitation in a saline-filled tube for two or more days, were more fragile than normal blood clot, and this may have played some part in the fragmentation of some of them. The passage of the large clots through the heart caused no disturbance on the electrocardiogram or alteration

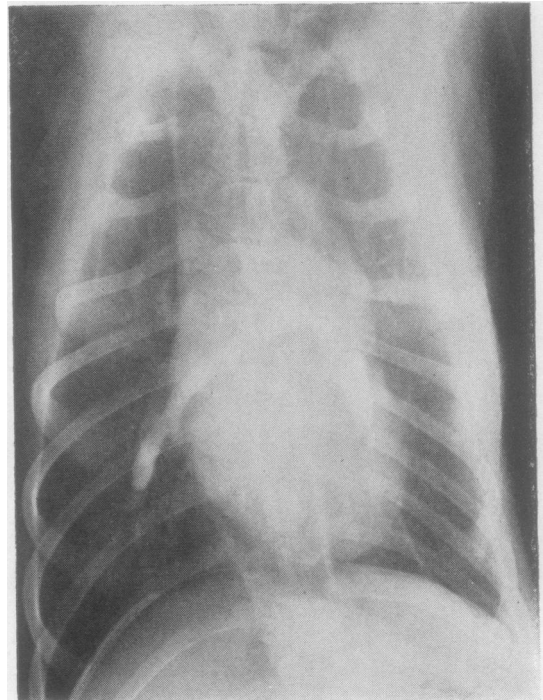


FIG. 10a

FIG. 10 (a and b).—Antero-posterior and lateral radiographs taken at 4 p.m. on September 14, 1959, immediately after introduction of radio-opaque blood clot into the inferior vena cava. The clot lies astride the bifurcation of the main pulmonary artery.

of the arterial blood pressure, and even when they became impacted at the bifurcation of the main pulmonary artery or in the branches of the right or left pulmonary artery, no circulatory disturbances were noted. When the animals recovered from the anaesthetic they showed no evidence of respiratory or circulatory difficulty, and there were no abnormal physical signs to be found in the chest.

In the days following injection no opacity ever appeared in the lung fields apart from that of the clot itself. There was no shadowing to suggest infarction and no accumulation of fluid in the pleura. The size of the heart remained unchanged. The opacity of the clot rapidly diminished in size. That this indicated absorption of the clot and not a washing out of the "dionosil" was probable because clots similar to those used in the dogs were rotated in tubes of saline for days without any sign of the dye being washed out. The rate of disappearance of the clot, as judged by the radiographs, is shown by the illustrations (Fig. 10 a to e) from which it is apparent that, if a patient does not die immediately from an embolus, the



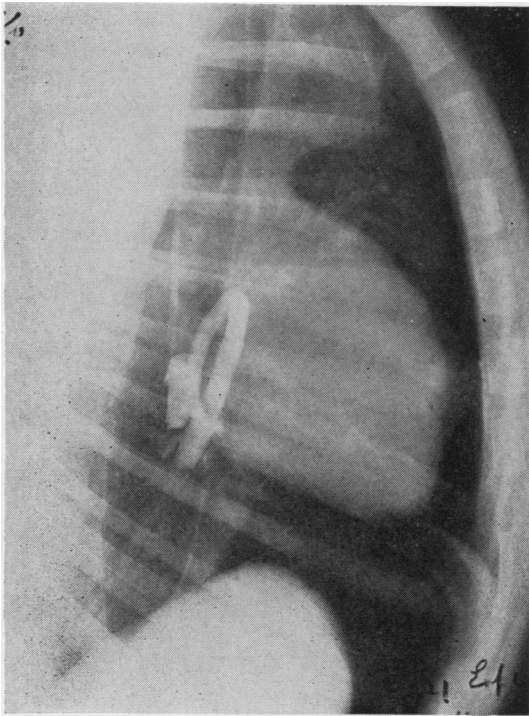


FIG. 10b

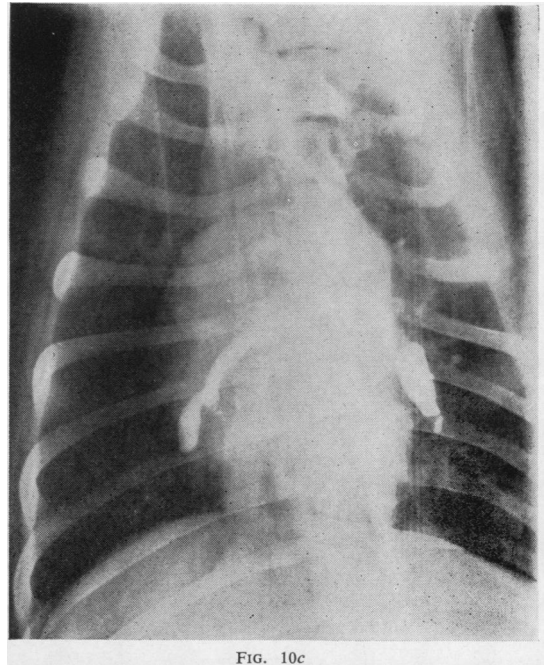


FIG. 10c

FIG. 10 (c).—Antero-posterior radiograph of the same dog as in *a* and *b* taken at 6.30 p.m. on September 14, 1959. There appears to be some diminution of the size of the clot in the short interval of two and a half hours.

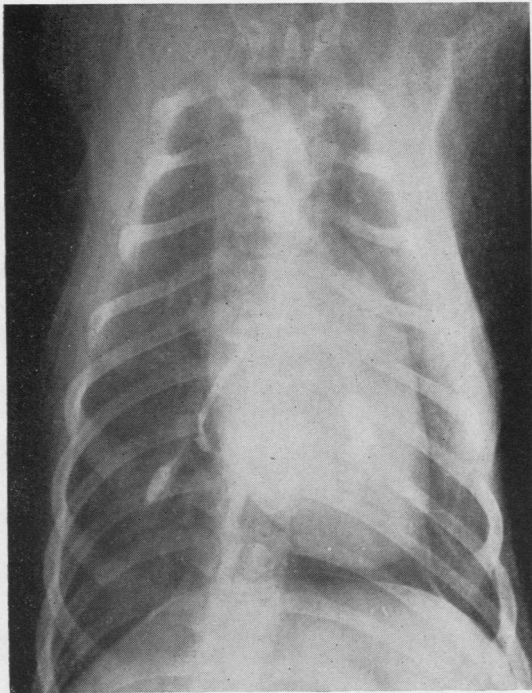


FIG. 10d

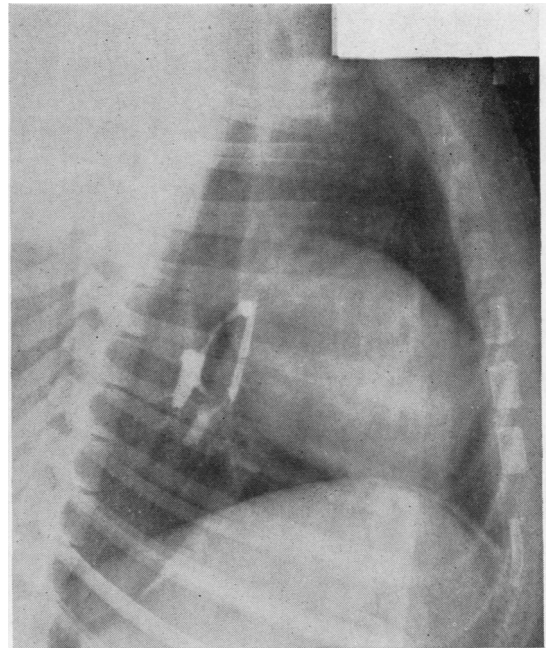


FIG. 10e

FIG. 10 (*d* and *e*).—Antero-posterior and lateral radiographs of the same dog as in *a* and *b* taken at 11 a.m. on September 15, 1959. Notable diminution of the size of the clot. No lung opacity noted at any time.



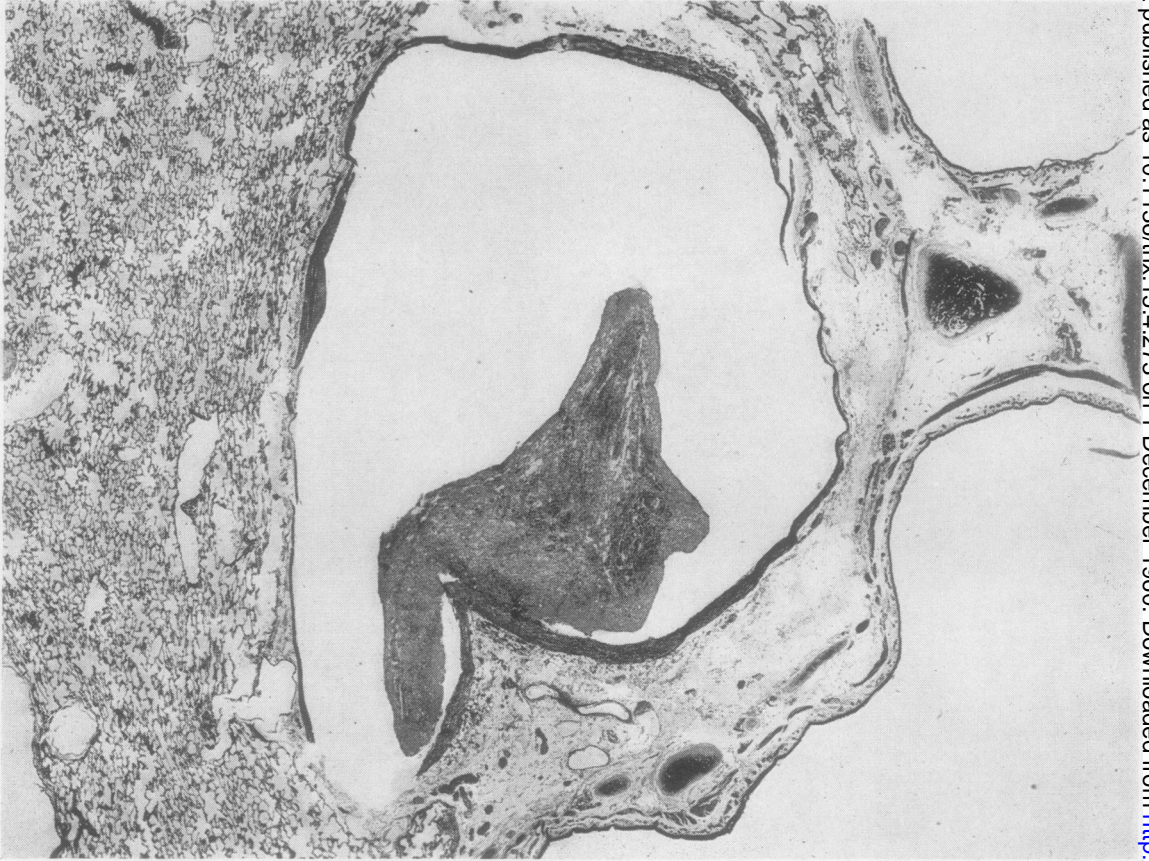


FIG. 11.—Photomicrograph of clot adherent at bifurcation of pulmonary artery and forming a polypoid projection into the lumen of both branches four days after introduction. Haematoxylin and eosin,  $\times 13$ .

size of clot found at necropsy may be a poor indication of the size of the clot originally reaching the lungs.

Following the introduction of the clot, defaecation sometimes occurred, whether the site of entry was the jugular vein or the inferior vena cava, and in spite of pre-operative starvation for 24 hours.

At varying intervals after the introduction of the embolus the pulmonary artery pressure was measured and the dogs then sacrificed.

In the dogs sacrificed at four days it was apparent that the clot had been greatly reduced in size as compared with that at the time of its introduction into the pulmonary circulation. The clot had become attached to the walls of the conducting or elastic pulmonary arteries at several focal points, often resulting in a rather polypoid mass waving about in the lumen of the vessel. Usually the clot was adherent to the bifurcation of the artery or at a point where a small branch was given off (Fig. 11). "Endothelium" had

grown over it in all areas. At its base the most interesting feature was the striking dilatation of the vessels in the adventitia adjacent to the point of attachment. The media at this point showed some oedema and contained a few polymorphonuclear leucocytes. The smaller arteries and arterioles appeared relatively free from the presence of clot, but a few hyaline masses of platelets and fibrin were present in one or two small arteries. The lung parenchyma at this stage showed a few areas of focal intra-alveolar haemorrhage in the regions supplied by the arteries containing clot. These areas were not extensive and seemed to be confined to the peribronchial and peribronchiolar regions.

At seven days the clots appeared further reduced in size and, instead of having a rather polypoid structure, they appeared flattened against the vessel wall. "Endothelium" was prominent over the clot, and immediately beneath this endothelium, and separating it from the disintegrating red cells



FIG. 12.—Photomicrograph of base of adherent clot showing vasa vasorum growing through the media of the artery at the point at which the clot is adherent seven days after introduction of clot. Masson's trichrome,  $\times 40$ .

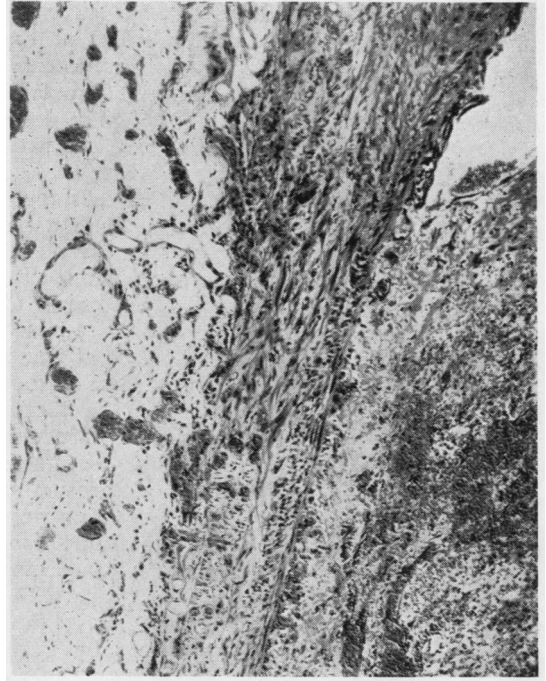


FIG. 12

FIG. 13.—Relics of adherent clot 21 days after introduction. A fibrous nodule (above) in the intima of a pulmonary artery (below) containing many vascular channels, probably in communication with the dilated vasa vasorum. Haematoxylin and eosin,  $\times 50$ .

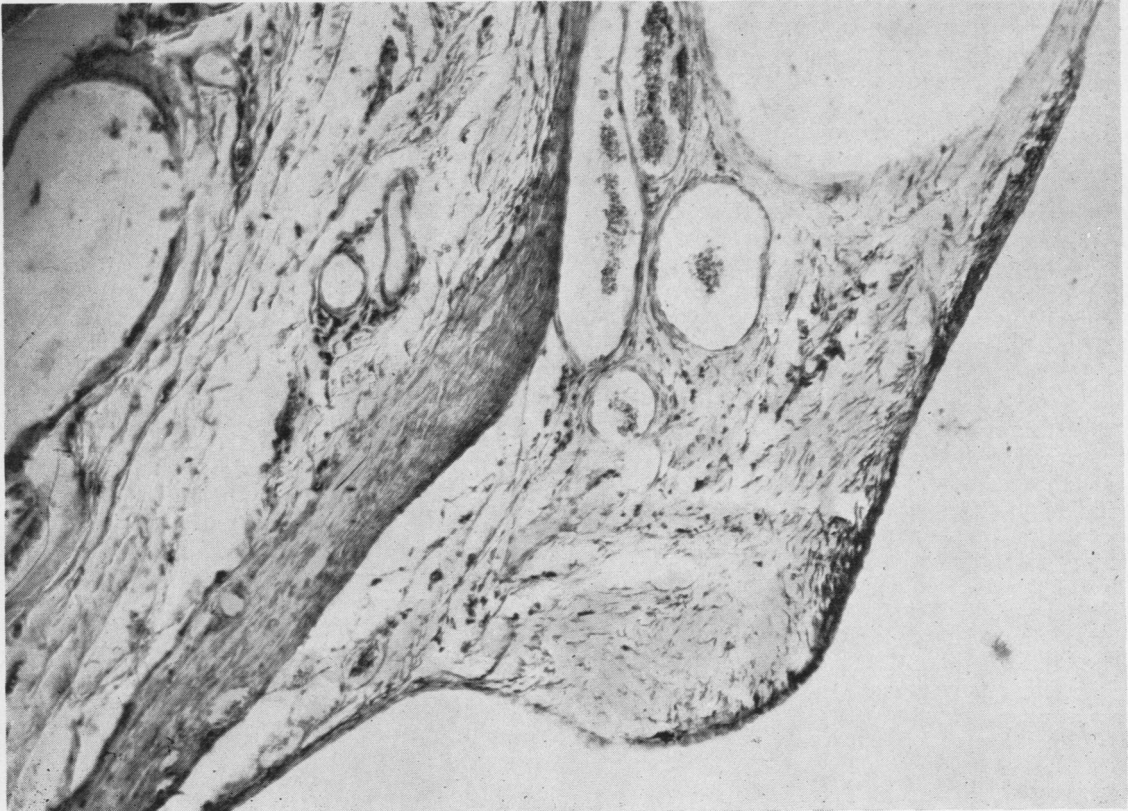


FIG. 13

of the clot, there was a thin layer of newly formed collagen. Vascularization of the vessel at the point of attachment of the clot was more intense, and small capillaries together with some fibroblasts had penetrated its base (Fig. 12). The lung parenchyma showed early peribronchial and peribronchiolar fibrosis and organization of the haemorrhages seen at four days. Red cells could still be made out in these areas. At 21 days the appearances were very interesting. In the elastic pulmonary arteries there was no recognizable clot. There were, however, several focal areas of subintimal fibrosis and these were often at points where small branches were given off, or at points of bifurcation. In some instances these fibrous plaques had a rather polypoid form. The fibrous tissue was loose and contained dilated vascular channels (Fig. 13). It would appear that these channels communicated with the vasa vasorum of the parent artery. The dilated vasa vasorum were still present in the adventitia of the artery adjacent to the fibrous intima and could be seen penetrating through the entire thickness of the media. The whole process was one of organization rather than canalization, a distinction emphasized by Dible (1958). There did not appear to be any fat in the plaques of intimal fibrous tissue. The parenchyma of the lung showed a sheath of fresh fibrous tissue with plump fibroblasts in the peribronchial and peribronchiolar regions at one or two focal points. The greater part of the lung parenchyma was normal.

At 28 days the fibrous nodules had disappeared, leaving an apparently normal pulmonary vascular tree.

It seems that clots introduced in this way do not obstruct a pulmonary vessel completely for any length of time. In none of the dogs was propagation of the clot observed and this supports the impression that some flow was rapidly established past the obstruction.

#### DISCUSSION

The experiments described above have been concerned with the injection of blood clots into anaesthetized dogs. It may be that this bears little relation to the release of true thrombi into the circulation of unanaesthetized human beings. They show that a clot embolus, which in relation to the size of the dog could be considered massive, can pass through the heart into the pulmonary circulation without causing death, and without causing detectable alteration in the electrocardiogram, the pulse, or the systemic arterial pressure. It produces no symptoms or physical signs in the post-operative period, and no radiological changes

in the lung fields. It is absorbed quite rapidly, leaving an apparently normal pulmonary vascular tree. While the clinical, cardiovascular, and radiological effects of large blood clots in the pulmonary circulation in the conditions of these experiments are so small as to be negligible or at least undetectable, respiratory changes have been noted, and these are being investigated further.

If it turned out that the results recorded here were applicable to the clinical problems of pulmonary embolus in man, a number of observations, which at present are difficult to explain, would fall into a comprehensible pattern. The most important deduction would be that there is, as yet, no clinical way of diagnosing pulmonary embolus unless it occurs either in the presence of previous severe pulmonary artery obstruction, or in the presence of pre-existing pulmonary venous congestion, as from left ventricular failure, hypostatic pneumonia, or mitral stenosis. In the latter event a true infarct will occur with pleurisy, haemoptysis, and a radiographic opacity. If indeed it is true that pulmonary embolus can occur without cardiovascular disturbance or physical signs, then it seems possible that, in the post-operative period, repeated small emboli could be a normal and undetectable occurrence. It would be natural for these to be absorbed quickly and without trouble (unless it be a slight febrile reaction), as the foregoing experiments suggest. Only when repeated small emboli occurred faster than they could be absorbed would the pulmonary circulation reach a critical point at which a further single embolus of moderate size might cause the sudden cardiac failure observed clinically. Such a train of events would fit in well with the pathologists' observations, for, in patients dying of pulmonary embolus, smaller organizing thrombi of varying ages are almost invariably found in the medium-sized branches of the pulmonary artery. It might well be, therefore, that the problem of pulmonary embolus is not the prevention or treatment of the single massive thrombus, but the counteracting of a process that is going on all day and every day as a natural result of operation. Whilst attention to the problems of stagnation and thrombosis in the deep veins of the legs would not be reduced, a further effort to promote lysis of clots reaching the lungs would be an important ancillary approach.

The speed and completeness with which clots were absorbed from the pulmonary circulation were surprising. This was presumably dependent in the first place on the continued flow of blood past them in the pulmonary artery. The combination of natural shrinkage of the clot and the fibrino-



lysins in the blood passing over it would tend to promote gradual absorption. The way in which this occurs in the systemic circulation has been observed by the use of a transparent ear chamber on the ear of a rabbit by Rabin, Thomas, Lee, Konikov, and Scott (1957). In a diseased lung or in an infarct the flow of blood in the pulmonary artery is either absent or very greatly diminished. The presence of an old tuberculous lesion in Case 1 might be associated with impaired pulmonary artery flow and might therefore be used to explain the persistence and organization of a thrombosed pulmonary artery in the right lower lobe. This argument can hardly be maintained, however, for the close microscopic examination of the experimental specimens shows that the clots become covered with "endothelium" and invaded by vessels from the wall of the artery within four days. Further absorption of the clot from this time onwards would seem to depend on the vasa vasorum. These are branches of the bronchial arteries which are known to be greatly hypertrophied in those diseases of the lung associated with diminished pulmonary blood flow.

It is therefore still obscure why thrombi can in some circumstances be completely absorbed, and in others remain as permanent plugs in the pulmonary blood vessels. Perhaps the same obscurity surrounds similar happenings in the systemic vessels.

#### SUMMARY

Two patients with recurrent subacute pulmonary emboli are described. One of these recovered

after pulmonary embolectomy under hypothermia.

Large single radio-opaque blood clots have been made from a dog's own blood and introduced into the inferior vena cava or jugular vein under anaesthesia. Ciné-radiographs showed that they passed rapidly through the heart into the pulmonary artery.

The passage of such clots caused no change in the pulse, systemic blood pressure, or electrocardiogram.

Repeated radiographic study showed the clots to be absorbed from the pulmonary circulation very rapidly. There was never any opacity in the lungs such as might be produced by an infarct or pleural fluid.

Histological examinations at intervals of four, seven, 14, 21, and 28 days were performed. In four days there was a smooth layer of cells covering the clot, and vasa vasorum were growing in from the adventitia of the artery. In 21 days the clot had become a subintimal fibrous plaque and at 28 days the artery had returned to normal.

We wish to thank Dr. MacLeod, of Southampton, for permission to quote Case 1, and Dr. R. Goodbody for his report on the pathology of the resected lobe.

#### REFERENCES

- Brofman, B. L., Charms, B. L., Kohn, P. M., Elder, J., Newman, R. and Rizika, M. (1957). *J. thorac. Surg.*, **34**, 206.  
 Carlens, E., Hanson, H. E., and Nordenström, B. (1951). *Ibid.*, **22**, 527.  
 Dible, J. H. (1958). *J. Path. Bact.*, **75**, 1.  
 McLachlin, A. D., McLachlin, A. J., Jory, T. A., and Rawling, E. G. (1960). Presented at American Surgical Association.  
 Rabin, E. R., Thomas, W. A., Lee, K. T., Konikov, N., and Scott, R. F. (1957). *A.M.A. Arch. Path.*, **64**, 75.