

# INCARCERATED AND OBSTRUCTED DIAPHRAGMATIC HERNIA

BY

J. HORTON AND J. D. S. HAMMOND

*From the University Department of Medicine, Royal Hospital, Sheffield*

(RECEIVED FOR PUBLICATION OCTOBER 12, 1959)

Diaphragmatic hernia is now recognized as a common abnormality of the upper gastro-intestinal tract, especially in elderly people (Harrington, 1948; Allison, 1951; Belsey, 1952). However, whereas strangulation is a common occurrence in most forms of hernia, it is rare in herniation through the diaphragm (Sellors and Papp, 1955). Carter and Giuseffi in 1948 were able to find only 39 cases of strangulated diaphragmatic hernia reported since 1798, to which they added four more of their own. Five years later, Pearson (1953) had been able to find another 33 cases, making 76 in all. Belsey (1952) stated that volvulus of the herniated stomach and strangulation were uncommon, and Aird (1957) considered that complete obstruction was exceptional.

The treatment of completely obstructed or strangulated diaphragmatic hernias is usually surgical and most of the case reports have appeared in surgical journals. During the past 12 months, two patients with incarcerated, obstructed, diaphragmatic hernias have been admitted as emergencies to the wards of the Professorial Medical Unit at the Royal Hospital, Sheffield. One was admitted with a diagnosis of haematemesis, the other was in overt tetany. Because of the infrequency of complete obstruction of a diaphragmatic hernia and the difficulties in diagnosis, we thought it would be of interest to report these two cases.

## CASE REPORTS

CASE 1.—A 48-year-old housewife was admitted on September 23, 1958, as a case of haematemesis.

She had been well until two years before admission, when she first noticed that meals were followed almost immediately by a burning sensation localized to the lower end of the sternum. She began to eructate freely and frequently, and bending forward sometimes caused her to vomit. A barium meal showed a hiatus hernia, and, six months before the present admission, this was treated surgically by an Allison-type repair at another hospital in the same city. After the operation, she remained perfectly well until three days

before admission, when she started to vomit clear fluid which contained partly digested food. After vomiting repeatedly for two hours, she developed a severe, constricting pain to the left of the xiphisternum, which did not radiate. At the same time she ceased to vomit, but noticed that she regurgitated all fluids shortly after swallowing. The pain and regurgitation persisted until a few hours before admission to hospital, when the regurgitated fluid became blood-stained and later contained actual clots of blood. During the two days before admission the patient passed neither faeces nor flatus.

On admission she was found to be an obese, extremely ill, cyanosed woman, with rapid, shallow respiration at a rate of 40 per minute. The pulse rate was 140 per minute, the rhythm regular; the blood pressure 120/85 mm. of mercury, and the temperature 100° F. Examination of the chest showed the signs of a left-sided tension pneumothorax, with diminished movements, hyperresonant percussion note, almost absent breath sounds, and a positive coin sign over the left hemithorax, and the mediastinum displaced to the right. Abdominal examination revealed only slight epigastric tenderness.

A tentative diagnosis of a perforated oesophagus was made. The results of laboratory investigations carried out immediately after admission were as follows: Haemoglobin 17.0 g. per 100 ml.; serum sodium 133 mEq./litre, serum chloride 94.5 mEq./litre, serum potassium 4.5 mEq./litre, plasma carbon dioxide 30.4 mEq./litre.

An antero-posterior radiograph of the chest taken in the ward (Fig. 1) showed a wide, dome-shaped shadow half-way up the left side of the chest with a large gas bubble and fluid level below. The heart and trachea were deviated to the right. The patient was then given a small amount of thin barium paste to swallow and the chest was screened (Fig. 2). This showed that the left leaf of the diaphragm was immobile and that there was obstruction at the lower end of the oesophagus, which was, however, in its normal position. A little barium entered the stomach, but it was not possible to outline the upper border of the stomach satisfactorily. The appearances were thought to be due to a volvulus of the stomach, but it was uncertain whether this had taken place below the diaphragm or through a recurrent hiatal opening. The patient was seen by Mr. D. J. Robertson, who

considered that there had been a recurrence of the hiatus hernia and that the major part of the stomach was above the diaphragm.

The patient was given 2 litres of 5% glucose in normal saline and started on 2 mega-units of penicillin

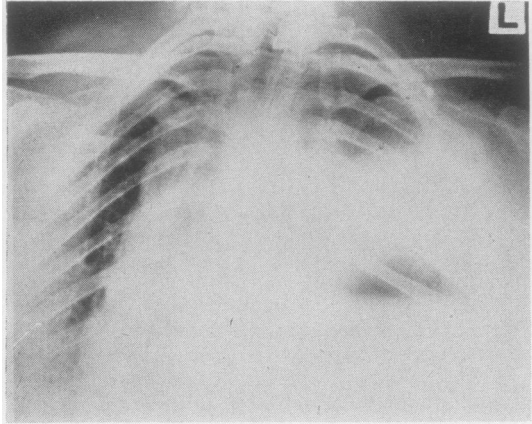


FIG. 1.—Case 1: Antero-posterior chest film taken in the ward. This shows a wide, dome-shaped shadow half-way up the left side of the chest below which is a gas bubble and fluid level. The mediastinum is markedly deviated to the right.

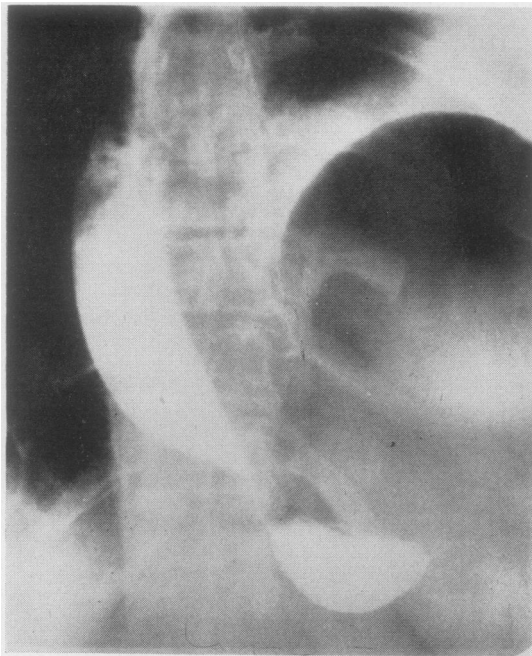


FIG. 2.—Case 1: Barium swallow. The gastro-oesophageal junction is in the normal position. Only a little barium has entered the stomach. The gas shadow with a crescentic upper margin is clearly shown to the left of the vertebral column.

and 1 g. of streptomycin daily, in divided intramuscular injections. Twelve hours later a blood transfusion was begun and a thoracotomy performed by Mr. Robertson. Four hundred ml. of blood-stained fluid was found in the left pleural cavity, together with a large, strangulated diaphragmatic hernia which contained only the stomach. The major part of this viscus was gangrenous, but it did not appear to have perforated. The gangrenous portion was excised and continuity restored between the viable tissue round the gastro-oesophageal junction and in the pre-pyloric region. The spleen was removed and the reconstructed stomach replaced in the abdominal cavity. The hernial ring was about 3 in. in diameter and was close to the oesophageal hiatus, but not continuous with it. The defect in the diaphragm was then securely closed in two layers. During the operation and in the 12 hours afterwards the patient received a total of 6 pints of whole blood.

Post-operatively the patient made an uneventful recovery, and a barium meal 16 days later showed that the remnant of the stomach was in a normal position (Fig. 3). Nine months later she was well, having lost 20 kg. in weight as the result of adhering carefully to a low-calorie diet. Her only complaint was of inability to eat a large meal because of a post-prandial sensation of epigastric distension.

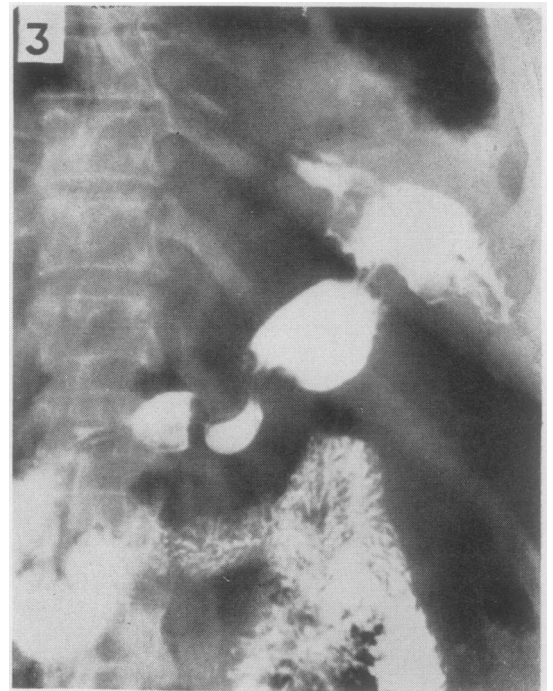


FIG. 3.—Case 1: Post-operative barium meal. The gastro-oesophageal junction, stomach remnant, and duodenal cap are shown in the normal position below the diaphragm.

CASE 2.—A 62-year-old man, a credit collector, was admitted on June 20, 1959. The patient was unable to give a history, which was obtained from his wife.

Two weeks before admission to hospital he began to vomit. The vomiting usually took place in the evenings and consisted of several pints of colourless fluid mixed with partially digested food. Four days before admission he developed constant, severe pain in the epigastrium. At the same time the vomiting increased in frequency and occurred almost immediately after any food or fluid. Shortly before admission his hands began to tingle and became stiff. During the previous three days the patient had had absolute constipation and had passed no urine for 24 hours before admission.

Examination revealed a semiconscious, cyanosed, dehydrated man with carpo-pedal spasm. Respiration was shallow, the rate 16 per minute; the pulse was regular, the rate 80 per minute, the blood pressure 95/60 mm. of mercury, and the temperature normal. On examination of the abdomen there was slight epigastric distension, but no visible peristalsis was seen and no succussion splash was elicited. The cardiovascular system and lungs were normal, but bowel sounds were heard posteriorly over the left hemithorax.

A provisional diagnosis of pyloric stenosis with alkalotic tetany was made.

The results of investigations carried out shortly after admission were as follows: Haemoglobin 15.2 g. per 100 ml.; haematocrit 49%, serum sodium 132 mEq./litre, serum chloride 52 mEq./litre, serum potassium 3.2 mEq./litre, alkali reserve 58 mEq./litre, calcium 8.5 mg./100 ml., blood urea 160 mg./100 ml. An electrocardiogram showed changes compatible with an old posterior myocardial infarction and potassium depletion.

Treatment was begun with gastric suction, intravenous fluids, and intramuscular penicillin. In the first 24 hours after admission, a total of 5 litres of 5% glucose in normal saline was given. Within 10 hours, the carpo-pedal spasm had disappeared and the patient started to pass urine after a further eight hours. During the next 24 hours he received 4 litres more of glucose-saline together with 6 g. of potassium chloride, after which he began to take fluids by mouth. The serum chloride concentration was now 85 mEq./litre and the alkali reserve 39.8 mEq./litre. Despite improvement in the patient's physical condition, he remained confused and disorientated until the fourth day after admission, when he suddenly became alert and rational. Laboratory investigations at this time were reported as follows: Serum sodium 149 mEq./litre, serum chloride 109 mEq./litre, serum potassium 4.1 mEq./litre, alkali reserve 32 mEq./litre; blood urea 100 mg./100 ml.

Gastric suction was discontinued and the patient was subsequently able to take a normal diet. At this time, the records of a previous admission to hospital, on another unit, six years before, were obtained. A chest radiograph had shown a gas-filled shadow

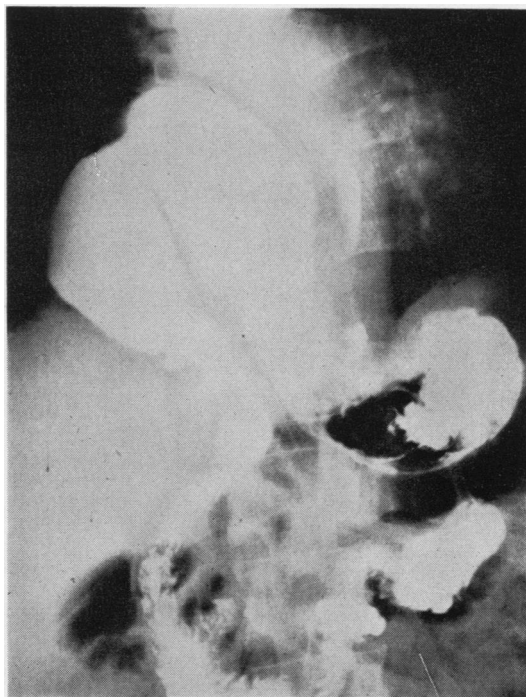


FIG. 4.—Case 2: Barium meal, postero-anterior film. The barium-filled oesophagus is displaced to the left by a large hiatus hernia. The fundus and gastro-oesophageal junction are normally situated below the diaphragm. Most of the stomach has undergone a partial volvulus and lies in the right hemithorax.

behind and to the right of the heart. A barium meal had confirmed that this was a large para-oesophageal diaphragmatic hernia. Before the present admission the patient had had no symptoms referable to this lesion.

On the ninth day after admission, a barium meal showed that the hiatus hernia was still present and that most of the stomach was above the diaphragm (Fig. 4). The radiographs appeared identical with those taken six years before. There was no evidence of pyloric stenosis and no delay in gastric emptying. At this time the blood urea had fallen to 34 mg./100 ml.

A diagnosis of volvulus of the stomach in a hiatus hernia was now made.

During the next few days, the patient had two further attacks of substernal pain, during each of which he vomited 3 to 4 pints of clear fluid containing partially digested food. In view of these recurrent episodes of pain and vomiting, he was seen by Mr. J. T. Chesterman, who carried out an Allison-type repair of the hernia on the sixteenth day after the patient's admission to hospital. The patient made an uneventful post-operative recovery and a subsequent barium meal showed that the stomach and oesophagus were entirely normal. He had no further attacks of pain or vomiting.

## DISCUSSION

Although both patients had incarcerated, obstructed diaphragmatic hernias which contained only stomach, their symptoms and signs were different. This could be attributed to two factors, namely, the site at which the stomach became obstructed and the fact that, in the first patient, the hernia occurred acutely and the obstruction was associated with irreversible interference with the blood supply of this viscus. Previous workers have often stressed the difficulties in the diagnosis of strangulated, diaphragmatic hernias (Mackey and Bingham, 1945; Smith and Sarkissian, 1953; Branson, 1955; Sellors and Papp, 1955; Sheridan, 1955); our first case was no exception and before operation the exact pathology was uncertain. The patient's history pointed to an abdominal condition, whereas the physical signs were found in the chest and simulated those of a left-sided tension pneumothorax. This feature has been noted by several previous writers (Gibson, 1929; Carter and Giuseffi, 1948; Smith and Sarkissian, 1953). Sellors and Papp (1955) and Boyd (1956) have also drawn attention to the similarity between the symptoms and signs of a strangulated diaphragmatic hernia and those of a perforated oesophagus, which was the tentative diagnosis made when our patient was first seen. The radiographs ruled out a pneumothorax, but it was uncertain whether the stomach was above or below the diaphragm. Even after the patient had swallowed a little barium sulphate paste, the position of the diaphragm remained obscure, although it was evident that a volvulus of the stomach had occurred. When the correct diagnosis was made at operation, it became obvious that the upper margin of the stomach had been thought to be the left leaf of the diaphragm. This difficulty in interpretation of the chest radiographs in cases of acute herniation of the stomach through the diaphragm has been emphasized by Loitman, Hoover, Miscall, and Evans (1957) and by Keshishian and Magovern (1958). Gangrene of the contents of a strangulated diaphragmatic hernia is very rare (Boyd, 1956; Joynst, 1956), and the mortality rate is high. Hughes, O'Brien, and Morris (1955) described one case of their own and found nine previously reported cases, and, of these 10 patients, only two survived gastric resection. Our patient was extremely ill, and her condition on the operating table was such that a formal reconstruction of the stomach was not attempted. Despite this she made an uneventful post-operative recovery, and, like the patient described by Sheridan (1955), her only remaining symptom is the inability to eat large meals.

In retrospect, it seems probable that the initial recurrent vomiting was responsible for the rupture of the counter-incision in the diaphragm, which had been made when the patient's hiatus hernia had been repaired six months previously. Dehiscence of the stomach through such a counter incision is uncommon (Sweet, 1952; Boyd, 1956; Loitman and others, 1957). However, recurrent severe vomiting was the initial symptom in one of the cases reported by Loitman and others (1957), and Carter and Giuseffi (1948) and Sheridan (1955) stressed the importance of the increase in intra-abdominal pressure, which accompanies coughing, sneezing, and vomiting, as a cause of strangulation of a diaphragmatic hernia. In view of the increasingly frequent recognition and surgical treatment of diaphragmatic hernias, it seems likely that this post-operative complication of the method of repair described by Allison (1951) will be seen more often than in the past. We are in complete agreement with Loitman and others (1957), who concluded that it was a serious complication endangering life, with a high mortality rate.

The second patient's symptoms were similar to those of pyloric stenosis, which was thought to be the most likely diagnosis when the patient was admitted to hospital. The absence of abdominal distension and of visible peristalsis was considered unusual. The correct diagnosis should perhaps have been suggested by the bowel sounds which were heard over the left hemithorax, as these have been noted in previous reports of cases of obstructed diaphragmatic hernia (Gardiner, 1944; Pearson, 1953). There was, however, no concavity of the upper abdomen, which Sheridan (1955) described as a feature of incarcerated diaphragmatic hernia. We have not been able to discover any previously recorded case of incarcerated diaphragmatic hernia in which vomiting has been severe or persistent enough to result in alkalotic tetany. This must thus be an extremely rare complication of such a hernia. The barium meal performed six years before the patient's present admission to hospital was almost identical with the pre-operative one, and both showed the major part of the stomach to lie in the thoracic cavity, behind and slightly to the right of the heart. The radiographs were very similar to those described by Hillemand, Bernard, Haas, and Roux (1955) in patients who had a volvulus of the stomach in a diaphragmatic hernia. These authors stressed that when the stomach had undergone volvulus, it always projected to the right of the gastro-oesophageal junction. It thus seems likely that a partial volvulus of the stomach had been present

for the six years between the two barium meals and that complete obstruction had only taken place a few days before the patient's admission to hospital. The severe alkalosis which was present on admission and the large volumes of fluid vomited by the patient on two occasions after he had started to take a normal diet suggest that the site of obstruction was close to the pylorus.

In this patient the initial biochemical disturbances were so profound that three days of intensive therapy was required before the serum electrolyte concentrations reached normal levels and before he became alert and rational. Because of the absence of strangulation, the repair of the diaphragmatic hernia was not as urgent as it had been in the first patient. Hence we were able to defer surgical treatment until the patient's condition was as satisfactory as possible. This must have appreciably reduced the risk of the operation, which was followed by an uneventful recovery.

SUMMARY

Two cases of incarcerated, obstructed diaphragmatic hernia are described. One patient was admitted as a case of haematemesis, the other in overt tetany. The first had suffered an acute herniation of the stomach through the counter incision of an Allison-type repair of a hiatus hernia, carried out six months previously. The stomach was gangrenous, but the patient survived resection and made a good recovery. The second patient had a large para-oesophageal hiatus hernia

which contained only stomach and which had been present for at least six years without causing any symptoms. Volvulus and complete obstruction had resulted in a profound degree of alkalosis and extrarenal uraemia. After medical treatment, the hernia was repaired surgically and the patient recovered uneventfully.

The difficulties in diagnosis in both patients have been discussed.

We would like to thank Professor C. H. Stuart-Harris for permission to publish reports of the patients who were admitted under his care, and Mr. D. J. Robertson for advice.

REFERENCES

Aird, I. (1957). *A Companion in Surgical Studies*, 2nd ed. Livingstone, Edinburgh and London.  
 Allison, P. R. (1951). *Surg. Gynec. Obstet.*, **92**, 419.  
 Belsey, R. (1952). In *Modern Trends in Gastro-enterology*, ed. F. Avery Jones, p. 128. Butterworth, London.  
 Boyd, D. P. (1956). *Surg. Clin. N. Amer.*, **36**, 631.  
 Branson, K. (1955). *Ann. Surg.*, **141**, 273.  
 Carter, B. N., and Giuseffi, J. (1948). *Ibid.*, **128**, 210.  
 Gardiner, H. (1944). *Brit. med. J.*, **2**, 114.  
 Gibson, F. S. (1929). *J. Amer. med. Ass.*, **93**, 1719.  
 Harrington, S. W. (1948). *Surg. Gynec. Obstet.*, **86**, 735.  
 Hillemand, P., Bernard, H.-J., Haas, R., and Roux, P. (1955). *Arch. mal. Appar. dig.*, **44**, 417.  
 Hughes, J. F., O'Brien, F. T., and Morris, A. J. (1955). *Delaware St. med. J.*, **27**, 6.  
 Joynt, G. H. C. (1956). *Surgery*, **40**, 696.  
 Keshishian, J. M., and Magovern, G. J. (1958). *Ann. Surg.*, **148**, 276.  
 Loitman, B. S., Hoover, W. B., Miscall, L., and Evans, J. A. (1957). *Amer. J. Roentgenol.*, **78**, 633.  
 Mackey, W. A., and Bingham, D. L. C. (1945). *Brit. J. Surg.*, **33**, 135.  
 Pearson, S. (1953). *A.M.A. Arch. Surg.*, **66**, 155.  
 Sellors, T. H., and Papp, C. (1955). *Brit. J. Surg.*, **43**, 289.  
 Sheridan, J. T. (1955). *Surgery*, **38**, 741.  
 Smith, R. A., and Sarkissian, S. (1953). *Brit. J. Surg.*, **41**, 73.  
 Sweet, R. H. (1952). *Ann. Surg.*, **135**, 1.

Dr. J. G. Scadding

Dr. J. G. Scadding is no longer a co-editor of *Thorax*: his place has been taken by Dr. John Robertson of Liverpool. The change has come about for two reasons. Dr. Scadding himself expressed the wish to devote more time to other projects, and the Council of the Thoracic Society agreed that in the future it would be unwise to rely upon two editors of equal seniority.

This note is to explain the reasons for the change, and to thank Dr. Scadding for his untiring efforts to improve the literary and the scientific standard of the journal. He has been an editor since the journal was founded, and has championed the idea that it is preferable not to publish anything rather than to accept poor material. The

first number of *Thorax* appeared in March, 1946, and, at that time, it was not easy to attract a steady flow of original papers. In March, 1947, for instance, three papers were accepted, and in the following number all but two were rejected: since then the reputation of the journal has been built up, and the Editors can now select papers from an ample supply of good manuscripts. The Editors and the Editorial Committee appreciate, and are grateful for, the part that Dr. Scadding has played. They wish him well in his new endeavours, and thank him for the work he has done during the last 14 years.

N. R. BARRETT.

A. JOHN ROBERTSON.