

ADENOCARCINOMA OF THE OESOPHAGUS

BY

D. W. SMITHERS

From the Radiotherapy Department, Royal Marsden Hospital, and Institute of Cancer Research, Royal Cancer Hospital, London

(RECEIVED FOR PUBLICATION APRIL 5, 1956)

ORIGINS

During the past few years an increasing number of patients with adenocarcinoma of the oesophagus have been reported. The chief reasons for this are probably the fresh interest which has been taken in oesophageal hiatus hernia, with which these tumours are quite commonly associated, and the changing views about the frequency of congenital shortening of the oesophagus.

There are a number of ways in which adenocarcinomas have been said to arise, or may appear to arise, in the oesophagus, namely, (1) developing from ectopic islets of gastric mucosa or in oesophageal glands; (2) arising in an oesophageal mucous membrane, a section of which has failed to undergo squamous transformation before birth; (3) developing in a mucosa which has undergone some glandular metaplasia following attrition or long-standing infection; (4) appearing in minor extensions or folds of gastric mucosa lining the hiatal canal; (5) occurring in the thorax distal to the cardia in a tube-like extension of the stomach in a patient with a congenitally short oesophagus; (6) spreading from primary tumours of the stomach, preferentially in the oesophageal submucous lymphatics. Those in groups 1, 2, and 3 would be true adenocarcinomas of the oesophagus; those in group 5, like those in group 6, would be primarily tumours of the stomach, even though they may perhaps occur in the thorax at least as high as the level of the tracheal bifurcation. Those in group 4 would either be minor variations of group 2 and so oesophageal, or inconstant indrawings towards the oesophagus of a small portion of stomach which flattens out again when this organ is distended, and so gastric.

There has been some confusion about the anatomical limits of the oesophagus caused by introducing into the definition questions of the type of mucosal lining. The mouth of the oesophagus lies behind the cricoid cartilage where

there is nothing to distinguish its mucosa from that of the pharynx. The upper limit is quite an arbitrary one so far as the microscopical appearance of the mucous membrane is concerned, but is a functional one due to the slight constriction, chiefly resulting from the pull of the cricopharyngeus. The mouth of the oesophagus is often apparent as a functioning site to someone passing a tube, because it may offer a momentary difficulty. It can, at times, be distinguished by virtue of the relative pallor of the mucous membrane at the level where the cricopharyngeus exerts its pressure (Lederman, 1955). The lower limit of the oesophagus has usually been accepted as that line where it ceases to be a tube and enters the sac of the stomach. Since, in the past, this was generally assumed to be the level at which the mucous membrane changed from squamous to glandular, no great difficulty in nomenclature arose. In 1950 Barrett distinguished between two types of lower oesophageal ulceration, that associated with the reflux oesophagitis occurring with a hiatus hernia, and those less common peptic ulcers found in gastric mucosa lining what appeared to be the lower part of the oesophagus. These latter, or Barrett's ulcers, were in his opinion properly described as gastric in origin, since he considered that such patients had a congenitally short oesophagus and that the ulcers occurred in a part of the stomach which extended upwards into the mediastinum. In 1951 Bosher and Taylor published an account of a patient in whom the whole lower half of the oesophagus was found to be lined by columnar epithelium, and Raeburn another in which the lower half was studded with irregular areas of columnar ciliated epithelium. In the same year Johnstone pointed out that the lower limit of the oesophagus was frequently lined by glandular epithelium. Allison and Johnstone in 1953 reported seven patients with the lower oesophagus lined by gastric mucosa, in all of whom an oesophageal hiatus hernia of an undoubted portion of stomach was

also present. Morris (1955) reported further cases of gastric mucosa within the oesophagus, accepting the theory that the lower oesophagus was at times lined by gastric epithelium but saying that the origin of this gastric mucosa was a matter of conjecture. Further evidence from a study of oesophageal tumours (Thomas and Hay, 1954; Smithers, 1955) suggested that an oesophagus lined for much of its length proximal to the cardia by gastric mucous membrane was no great rarity. Wyndham (1956) reported the case of a boy aged 9 with an oesophageal stricture at the level of the aortic arch; the stricture and the lower part of the oesophagus was excised, and the part above the stricture was found to be lined by squamous epithelium, that below being mostly gastric in pattern but in places of intestinal type; there was no hiatus hernia. Another patient with gastric mucosa in the lower oesophagus is reported here.

CASE 1 (027300, K.C.).—A housewife of 61, a patient of Mr. R. C. B. Ledlie, had a three to four years' history of solid food sticking behind the sternum, relieved by vomiting. Barium swallow (Fig. 1) showed a stricture with its upper limit at the level of the tracheal bifurcation and a hiatus hernia. Oesophagoscopy by Mr. W. A. Mill showed the stricture 25 cm. from the gum margin. Pieces removed from the stricture site showed epithelial hyperplasia but no tumour, and one piece taken from beyond the stricture showed gastric glandular tissue.

At neither end is any change in the character of the mucosa a reliable guide to the anatomical limits of the oesophagus, since there is no distinction at the proximal end and the change at the distal end is inconstantly placed in relation to the gastro-oesophageal junction. Not only may the change be located at a line high up in the thorax, but the mucosa at the lower end may be loosely attached and so vary in position in relation to the cardia. The lower limit of the oesophagus, like the upper, is best defined in terms of function and may be said to be that place at which it ceases to be a tube and enters the stomach sac: in other words, the termination of the gastro-oesophageal vestibule, which is sometimes demonstrable radiologically as a ring when using the oil-contrast radiographic technique (Poppel, Zaino, and Lentino, 1955). This region is fairly mobile, particularly in children and in old people, and though usually situated in the abdomen may be in the thorax, either as the result of herniation or of congenital shortening of the oesophagus.

It may be difficult at times to apply this simple functional definition of the anatomical limits of

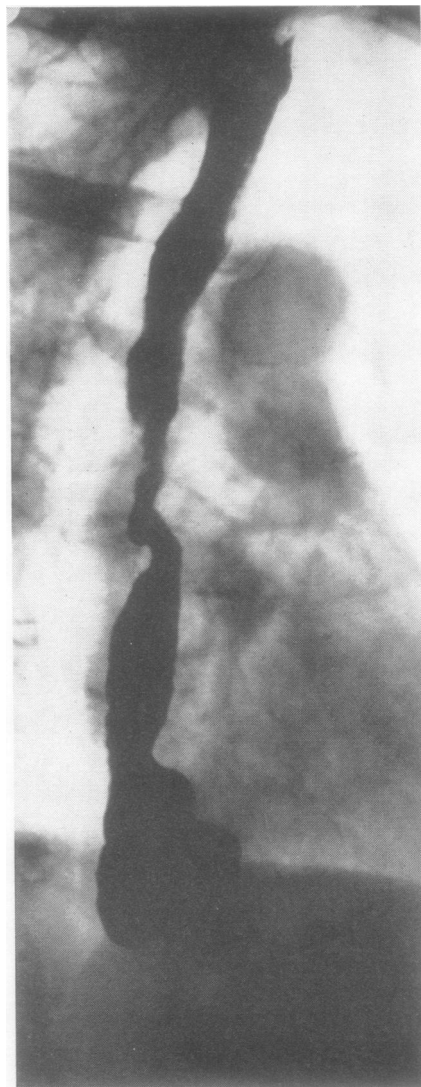


FIG. 1.—Woman, aged 61, patient of Mr. R. C. B. Ledlie, with a mid-oesophageal stricture, gastric glandular tissue distal to it, and a hiatus hernia.

the oesophagus, especially in attempting to distinguish radiologically between one lined by gastric mucosa and a true case of congenital shortening of the oesophagus where the intrathoracic portion of the stomach tends to be rather tubular in form. In most cases of congenital shortening there is, however, a clear picture of an oesophageal tube entering like a stalk into the top of an imperfectly descended pear-shaped stomach sac (Smithers, 1945, Fig. 5). There is the further difficulty that a small portion of stomach mucosa immediately

distal to the normally placed cardia may be drawn up into a narrowed segment which continues the course of the oesophagus sometimes for as much as 3 cm. (Palmer, 1953). This portion may be stretched out to become part of the stomach sac again when the gastric fundus is distended.

Despite some slight difficulties in anatomical classification, the demonstration that quite large sections of the columnar epithelial lining of the oesophagus may sometimes fail to undergo squamous transformation before birth has removed the chief objection to accepting adenocarcinomas involving the oesophagus, and apparently confined to it, as being primary tumours of that organ and so has opened the whole question once more to discussion. Barrett (1950) showed that peptic ulceration in glandular epithelium occurred in this situation; it is the purpose of this paper to show that adenocarcinomas also occur under similar circumstances and to suggest that it is a failure of lower oesophageal mucosa to undergo squamous transformation which is the basic defect in both cases rather than any congenital shortening of the oesophagus.

CARCINOMAS ARISING IN OESOPHAGI LINED BY GASTRIC MUCOSA

Morson and Belcher (1952) published an account of a case in which the junction between squamous and glandular epithelium in the oesophagus was situated at the level of the tracheal bifurcation with an adenocarcinoma at this site. The whole oesophagus distal to the tumour was lined by glandular epithelium except for a few islands which were squamous-celled. There was no hiatal hernia and the stomach appeared normal. Allison and Johnstone (1953) reported an adenocarcinoma arising 1 cm. above the line of the cardiac orifice and extending up for 4.5 to 6 cm., the epithelium above being squamous and below the tumour gastric; a sliding hiatal hernia was present in this case. Thomas and Hay (1954) recorded another case of adenocarcinoma in the lower third of the oesophagus, extending over 2 cm., where the whole resected portion of the oesophagus for 8 cm. proximal to the tumour and distally for 5 cm. as far as the cardia was lined by glandular epithelium; no hiatal hernia was present. Pattinson, Osborne, and Morson (1955) recorded nine cases of adenocarcinoma associated with hiatus hernia, three of which were primary stomach tumours. One of the other six was merely reported as an oesophageal tumour, one as being present at the level of the tracheal bifurcation (but was said to be at the cardia), and the

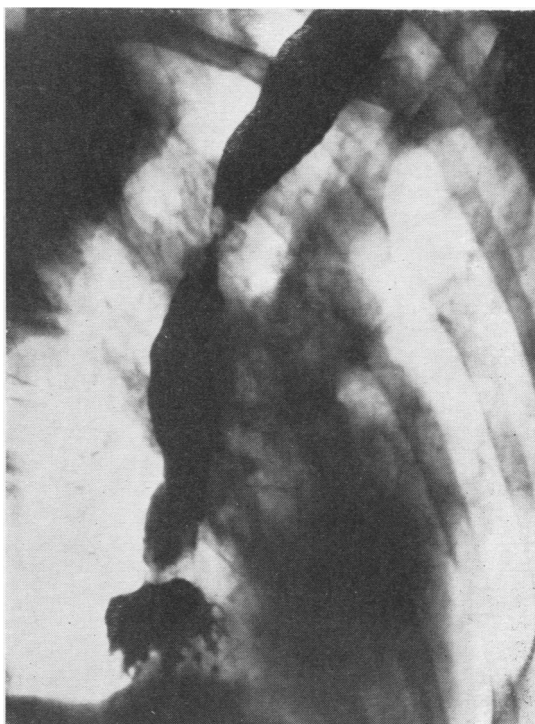

FIG. 2.—Man, aged 40, patient of Mr. N. R. Barrett, with adenocarcinoma of the oesophagus and hiatus hernia of the stomach.

other four as occurring in oesophagi of which the terminal $1\frac{1}{2}$ –2 in. were lined by gastric mucosa. Puestow, Gillesby, and Guynn (1955) have recently reported 603 patients with oesophageal carcinomas admitted to hospital in a period of 23 years; five of these carcinomas they regarded as adenocarcinomas arising proximal to the cardia, with one adenocarcinoma at the level of the aortic arch.

In previous papers (Smithers, 1945, 1950, 1955) I have recorded seven patients with adenocarcinomas of the oesophagus associated with hiatus hernia (Case 3, 1945; Case 4, 1950; Cases 2, 3, 4, 9, and 10, 1955). Of the five cases reported in 1955, three were found to be extensive tumours: in Case 3 the tumour reached all the way from the level of the aortic arch to the cardia; in Case 4, from the level of the tracheal bifurcation to the cardia; in Case 9, 10.5 cm. of the lower oesophagus was involved; Case 10 showed a tumour 5 cm. long in the middle third of the oesophagus with apparently normal mucous membrane distal to it on radiological examination. Since then one further patient with a middle third oesophageal adenocarcinoma and a sliding hiatal hernia has been seen, and is here described.

CASE 2 (026335, W.D.).—A ticket collector, aged 40, a patient of Mr. N. R. Barrett from the Brompton Hospital, had a history of increasing dysphagia for three years. A biopsy showed a well-differentiated adenocarcinoma. Radiological examination revealed a tumour of the middle third of the oesophagus and a hiatal hernia (Fig. 2). The patient was treated by 2 MeV. x rays in September, 1955, and was clear of tumour on oesophagoscopy and biopsy in January, 1956.

From 1936 to 1951, 343 patients were first seen at the Royal Marsden Hospital in whom a diagnosis of carcinoma of the oesophagus was made. When these were reviewed the diagnosis was rejected in 29, made up of 19 with tumours at the upper end reclassified as tumours of the laryngopharynx, and 10 with tumours at the lower end reclassified as tumours of the stomach. The total number now accepted as having primary carcinoma of the oesophagus in this period is therefore 314. In this group there were 26 patients (8%) with adenocarcinomas, 23 not associated with hiatus hernia and three previously reported with such an association. Since 1951 there have been five more cases of adenocarcinoma of the oesophagus with hiatus hernia, four previously reported and one (Case 2) now reported for the first time. Since those associated

with hiatus hernia have already been recorded, only the 23 new cases without hernia, first seen from 1936 to 1951, will be reviewed here. These are divided into upper third (one), middle third (three), extensive involvement of lower half (eight), and lower third (11).

The patient with an adenocarcinoma situated at the upper oesophageal limit is described below.

CASE 3 (011267, E.L.).—An accountant aged 68, a patient of Dr. M. Lederman, had complained of pain, dysphagia, and loss of weight for seven months. A tumour was seen on oesophagoscopy 18 cm. from the gum margin; a piece removed for biopsy showed a mucus-secreting adenocarcinoma. Radiological examination demonstrated a growth extending from the upper limit of the oesophagus down to a point 3 in. below the level of the sterno-clavicular joint (Fig. 3). He was treated with x rays in January, 1950, but died the following April. There is no record of the nature of the mucous membrane lining the whole length of the oesophagus.

Three patients had adenocarcinomas located in the middle third of the oesophagus, with what appeared radiologically to be a normal mucosa distal to them: two men (1940, W.B.; 004440, J.W.) with tumours in the oesophagus at the level of the tracheal bifurcation, and one woman (G.H.

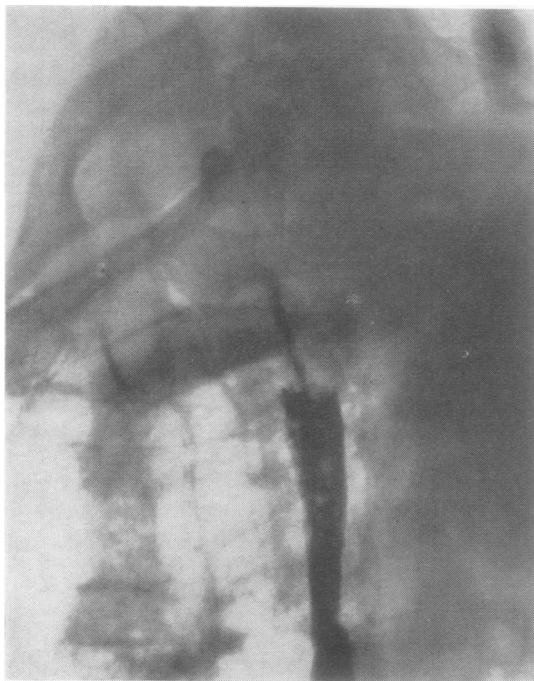


FIG. 3.—Man, aged 68, patient of Dr. M. Lederman, with adenocarcinoma of the upper limit of the oesophagus.

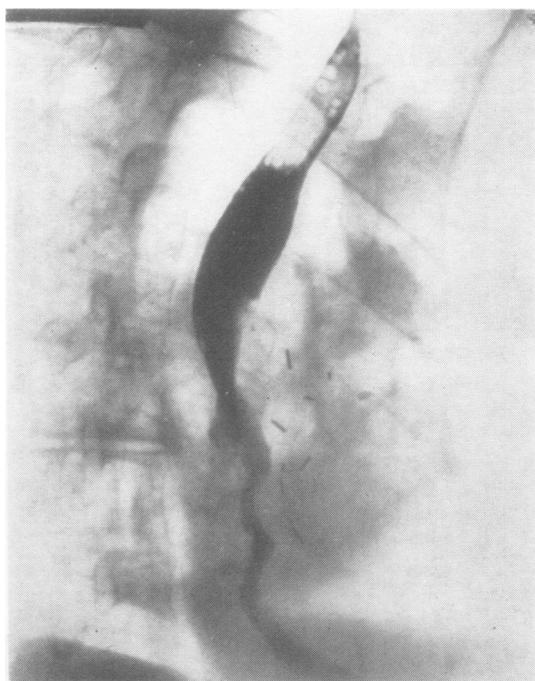


FIG. 4.—Man, aged 33, patient of Mr. R. C. B. Ledlie, with adenocarcinoma extending from the level of the aortic arch to the cardia.



FIG. 5

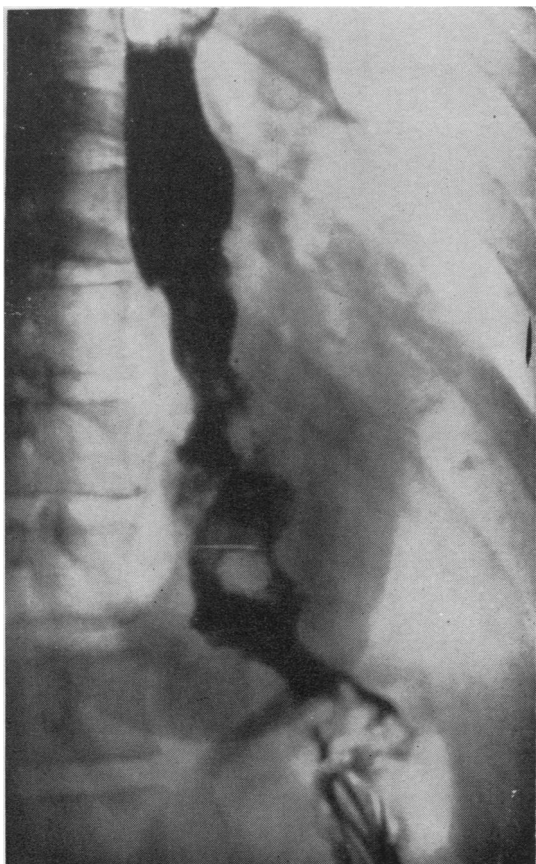


FIG. 6a

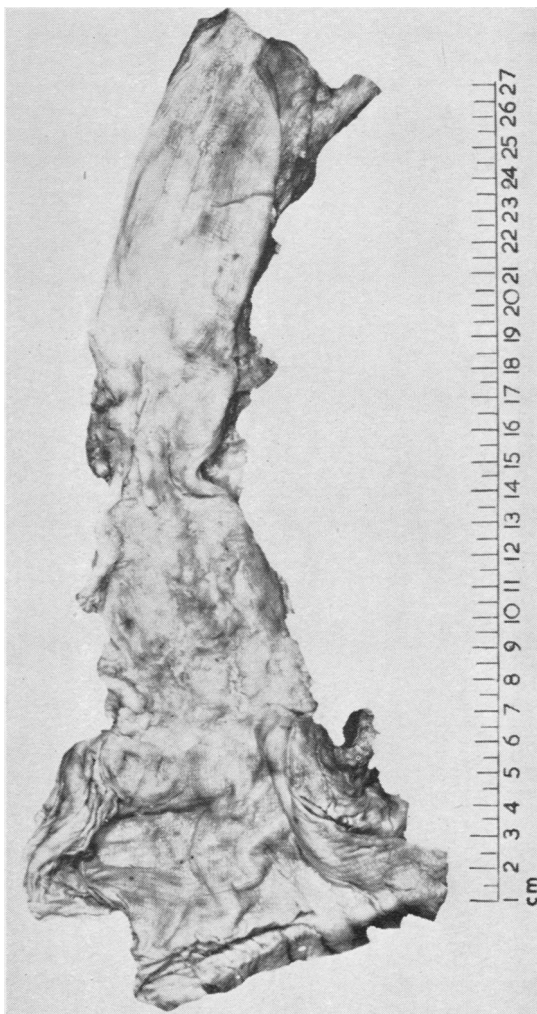


FIG. 6b

FIG. 5.—Man, aged 66, patient of Mr. R. W. Raven, with adenocarcinoma extending over the lower 10 cm. of the oesophagus.

FIG. 6a.—Woman, aged 38, operated on by Mr. R. W. Raven, with extensive adenocarcinoma of the lower oesophagus.

FIG. 6b.—Post-mortem specimen showing the extent of the tumour.

1937, M.G.) with a tumour just below the level of the aortic arch.

Eight patients had oesophageal adenocarcinomas extensively involving the lower oesophagus. One (012623, T.S.) extended to the cardia from the level of the aortic arch (Fig. 4) and another (011711, H.T.) over the lower 10 cm. of the oesophagus (Fig. 5). The post-mortem specimen and the radiograph of another are shown in Fig. 6 (003834, L.T.), and two others (911963, H.A., and 1938, W.C.) involved the whole of the lower third. One (903956, S.W.) started 25 cm. from the gum margin and showed a small portion of radiologically normal oesophagus between its lower limit and the cardia; this man was of special interest in that his brother had died from a somewhat similar growth one year before. This brother at laparotomy had been found to have an adenocarcinoma which was situated at the cardia and was said to have extended through the diaphragm; the body of the stomach was apparently normal, but the tumour was classified as gastric, the radiological appearances suggesting that the fundus of the stomach was involved. The seventh and eighth patients in this group (L.208/1936, F.C., and C.61/1936, C.N.) had lower oesophageal tumours 6 and 8 cm. long, both reaching to the cardia.

The remaining 11 of these 23 patients with adenocarcinomas had more localized tumours confined to the lower third of the oesophagus and so less obviously arising in it. In two of these (G.H.1941, I.M.L., and G.H.1943, A.H.-M.) portions of radiologically normal oesophageal mucous membrane could, however, be seen between the lower limits of the demonstrable tumour and the stomach. In five (005737, H.H., 904632, J.C., 005529, W.P., 009736, E.D., and 004113, T.M.) the lower oesophagus and part of the fundus of the stomach were removed and examination of these operation specimens showed oesophageal adenocarcinomas without any demonstrable stomach involvement; in one of them (009736) the tumour was 6 cm. in length. Post-mortem examinations were made on a further two cases (J.510/44, A.R., and A.638/44, M.B.), both of which showed adenocarcinomas immediately proximal to the cardia but without evidence of stomach invasion. One patient (014679, G.R.) was found, on thoracotomy, to have a hard adenocarcinomatous mass in the oesophageal hiatus. Still one more with an adenocarcinoma localized in the lower third of the oesophagus is described in more detail below (Case 4), because tumours at this site usually respond poorly to irradiation and

this exception may be of interest in relation to attempts to assess the prognosis in lower oesophageal adenocarcinomas.

CASE 4 (001139, W.N.).—A stoker aged 52, a patient of the late Mr. Lionel Colledge, had complained of dysphagia for four months. Oesophagoscopy showed a tumour at the lower end of the oesophagus. A piece was removed for biopsy and reported as "colloid or mucoid carcinoma derived from gastric glands." Radiological examination (Fig. 7) showed irregular tumour in the lower portion of the oesophagus without involvement of the stomach. The patient was treated with x rays during July and August, 1945, having refused operation. He was symptom-free for two months, but then developed pain and constriction of the lower end of the oesophagus. He was operated on in December, 1945, oesophago-gastrectomy being performed, and he died two days later. Serial sections of 7 cm. of lower oesophagus failed to demonstrate any residual tumour; post-mortem examination recorded no metastases. The cause of death was massive collapse of lung.

To summarize the 23 patients with adenocarcinomas of the oesophagus without hiatus hernias reported here: one tumour was in the upper third, three in the middle third, eight involved most of the lower half, and of the 11 confined

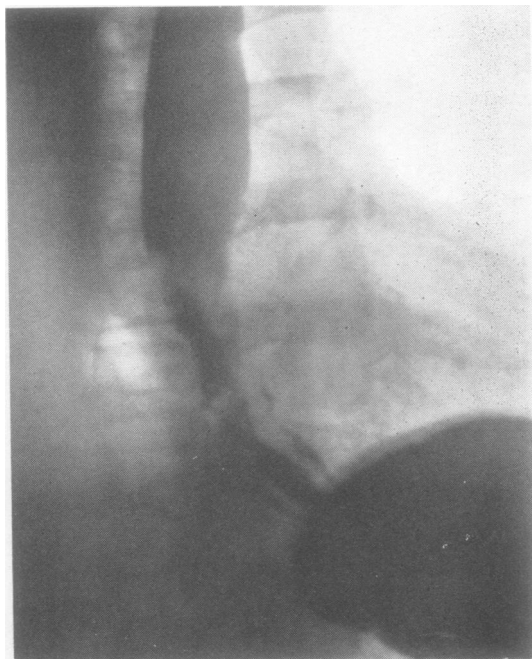


FIG. 7.—Man, aged 52, patient of the late Mr. Lionel Colledge, with adenocarcinoma in the lower third of the oesophagus.

to the lower third and accepted as oesophageal, two showed radiologically normal mucosa between them and the cardia, two showed no stomach involvement at necropsy, five showed no stomach involvement on examination of the specimen removed at oesophagectomy, one, on thoracotomy, was found to have a tumour confined within the oesophageal hiatus, and one (confined to the oesophagus radiologically) had been completely destroyed by radiation by the time the patient came to be operated on. The evidence that these were, in fact, primary oesophageal tumours is too strong to be easily explained away, although 15 seem to have reached to, though not to have extended beyond, the cardia. On this basis of assessment these 23 patients represent the minimum number with oesophageal adenocarcinomas seen, for in those where there was any doubt or too little information the tumours were classified as gastric.

CARCINOMAS ARISING AT THE CARDIA

It is extremely difficult to be sure of the precise site of origin of all adenocarcinomas reaching the lower oesophageal limit. Tumours localized to this region and extending over the junction of the two types of mucosa are quite common (Fig. 8) but are usually classified as arising in the stomach. Where the site of the change in mucous membrane in relation to the cardia is uncertain or the tumour extensive, real difficulties arise, both in classification and in determining the true incidence of oesophageal adenocarcinomas.

Morson (1956) analysed 190 gastrectomy specimens removed for carcinoma and found that the cardia was involved in 41 (21.6%); four (9.8%) of these 41 appeared to be arising from gastric mucosa lining the oesophagus.

The records of all new patients with carcinoma of the stomach seen at the Royal Marsden Hospital from 1936 to 1944 inclusive are incomplete. Only those admitted during that period can be listed in full; there were 232 of these. From 1945 onwards the records are complete, and 253 new patients with gastric cancer were seen during the years 1945 to 1951. The notes of these two groups have been examined, and in 94 out of a total of 485 (19.3%) there was evidence that the tumour directly involved the cardia or arose close to it in the fundus of the stomach. There is also evidence that 70 of these 485 (14.4%) extended further to involve the oesophagus. This group does not include either those extensive tumours involving so much of the stomach that their site

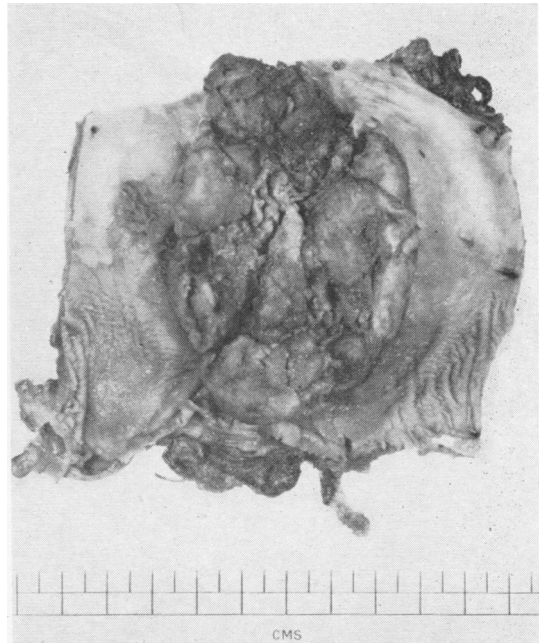


Fig. 8.—Operation specimen from a man aged 50, patient of Mr. A. Lawrence Abel, with a junctional adenocarcinoma at the normally placed cardia, lying astride the line of change from squamous to gastric mucosa.

of origin could not be determined, or those few in which the notes were inadequate for classification. With the 15 oesophageal tumours reaching to the cardia referred to above, this gives a total of 109 patients with adenocarcinomas involving the cardia in the hospital records during 16 years. A more detailed review of the patients with both oesophageal and gastric cancer is in preparation for a study of the results of treatment of carcinoma of the oesophagus, and the figures given above may possibly be found to require some minor adjustments. For the present purpose, which is merely to indicate the selection which has occurred within the hospital material in classifying tumours as oesophageal adenocarcinomas, they should be adequate.

Of the primary tumours arising in the region of the cardia, Tanner (1946) found that 73% (38 out of 52), Allison (1946) that 56% (53 out of 94) and Carey and Clagett (1955) that 73% (96 out of 131) were adenocarcinomas. Surgical reports do not usually attempt to distinguish between tumours arising immediately on the gastric or the oesophageal sides of the dividing line, since the mode of spread, treatment, and prognosis seem to be more dependent on the histology of the tumour than on minor variations in its external anatomical relations.

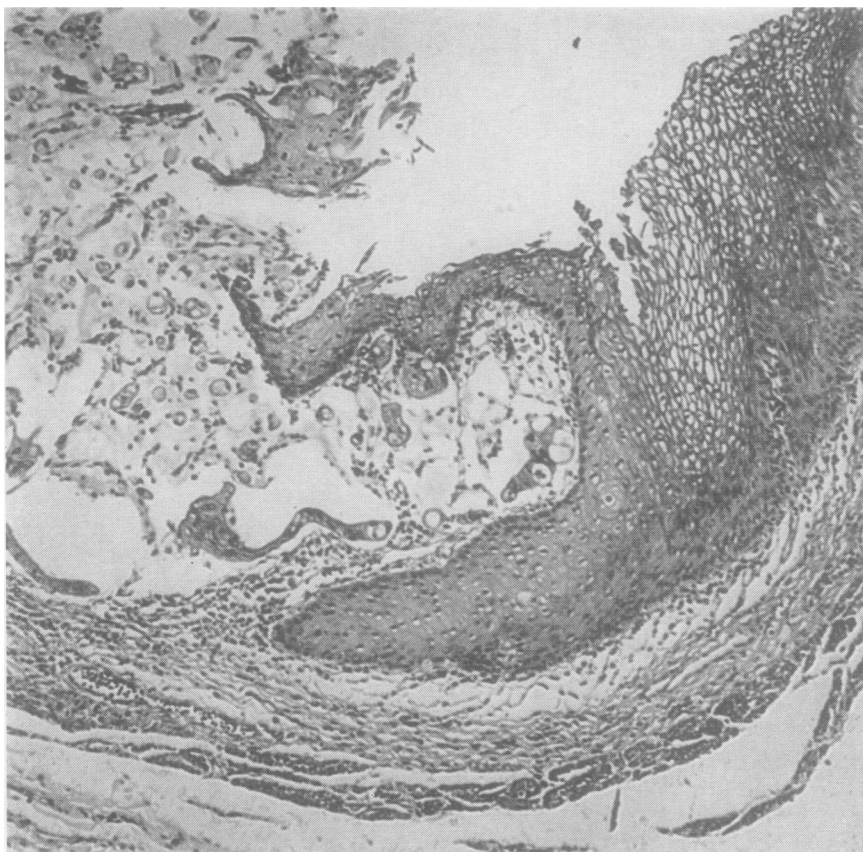


FIG. 9.—Photomicrograph of the margin of an ulcer of the oesophagus from a patient of Mr. R. C. B. Ledlie. This patchy ulceration extended above the level of the bifurcation of the trachea and was due to submucous infiltration from a mucus-secreting adenocarcinoma of the stomach.

The frequency with which oesophageal or stomach tumours arise in the region of the cardia cannot be gauged from most surgical series where the proportion of tumours near the pylorus tends to be unduly high for the stomach and of tumours near the cardia for the oesophagus. Post-mortem evidence suggests that the proportion of gastric tumours arising in the cardiac region is about 10% (Willis, 1953). At necropsy, as Willis again points out, many oesophageal tumours are so extensive that their level of origin is uncertain. The proportion of tumours reaching to the cardia is seldom given. The usual division of oesophageal tumours by site is into those arising in the upper, middle, and lower thirds, and the method of allocation to these sites is either by the third in which the greater part of the tumour is judged to be, or by that in which its upper limit was seen on oesophagoscopy or demonstrated radiologically. The range of difference of incidence by site of origin within the oesophagus in recorded groups is high. On such a rough basis of division—especially where the situation of the greater part of the

tumour is selected as a criterion—the middle third is likely to get more than its fair share. The widest range and the highest figures found are both in the lower third, however, where there is most difficulty in deciding whether the primary site is within the organ at all and where there is the greatest selection for admission to surgical wards.

So variable are the published figures that it is difficult at present to state clearly what proportion of oesophageal tumours occur in the region of the cardia, or to say with certainty that there is any very uneven distribution along its length of the squamous-cell tumours. The very different site distribution of adenocarcinomas, with their rarity in the upper oesophagus and their increasing frequency towards the cardia, may perhaps add a little weight to the possibility that a number of tumours arising at the oesophago-gastric junction may indeed be oesophageal in origin.

Much has been written about the invasion of the oesophagus by primary stomach tumours. There is no doubt that this commonly happens and

there is some evidence of a tendency for preferential spread of adenocarcinomas of the stomach arising near the cardia by way of the oesophageal submucous lymphatics. This spread may be so extensive that much of the oesophageal mucosa is undermined by tumour. In one patient (913767, T.F.B.) such infiltration was found at necropsy to reach a point above the level of the tracheal bifurcation with patchy infiltration through to the oesophageal mucosa which was in some places ulcerated (Fig. 9). This patient had an undoubted and extensive primary stomach tumour extending to within 3 cm. of the pylorus. In another (010323, E.M.), spread from a carcinoma of the fundus of the stomach was judged by the surgeon at operation to have reached by submucosal spread as far as 15 cm. up the oesophagus posteriorly, though this was never confirmed histologically. In one more (904616, T.K.), there was both undermining of the squamous epithelium of the oesophagus and patchy intra-epidermal malignant infiltration.

Rather less has been said recently about spread in the opposite direction from oesophagus to stomach. If the tumour is an adenocarcinoma it is usually assumed to have arisen in the stomach. It is rare for tumours arising in neighbouring organs to invade the stomach, so that invasion by continuity from the oesophagus, which is a very different matter, has perhaps been neglected. Willis (1952) pointed out that primary oesophageal tumours may give rise to secondary apparently discrete ulceration of the stomach, due to outcrops from permeated lymphatics, and quotes a number of examples reported in the past (Zahn, 1889; Bucher, 1893; Milner, 1904; Borrmann, 1907; Kaufmann, 1929). A patient seen at the Royal Marsden Hospital in 1951 (014478, T.W.) had a total gastrectomy performed which demonstrated a carcinoma on the anterior wall of the stomach, the upper margin being at the gastro-oesophageal junction; microscopically this was a squamous-cell carcinoma extending into the stomach wall. It is, therefore, possible that some adenocarcinomas classified as gastric in origin arise in the lower oesophagus and invade the stomach.

The difficulties of finding the real incidence of adenocarcinomas of the oesophagus are great and, though it may perhaps be true to say that a number of the adenocarcinomas in the region of the cardia arise primarily in the oesophagus, it is probably more important simply to recognize a group of junctional adenocarcinomas occurring

here, since they may perhaps have a comparatively good prognosis with surgery (Puestow and others, 1955).

DISCUSSION

Hewlett, who wrote a paper in 1901 on "The Superficial Glands of the Oesophagus," said that these glands in the upper part of the oesophagus were first described by Rudinger in 1879. Schmidt had been the first to describe the submucous mucus-secreting glands in 1805. Johnson (1910) stated that the superficial (or "cardiac") glands appear first as secretory epithelium at both the upper and lower ends of the oesophagus as early as the third month of intra-uterine life, later budding and branching to form glands which never extend through the muscularis mucosae. The deep (or "oesophageal") glands, on the other hand, appear first as excretory ducts which are outgrowths of stratified squamous epithelium and pierce the muscularis mucosae, later developing secreting cells which can be seen at the time of birth as a number of budding processes arising from the end pieces and lined with secretory epithelium. These deep oesophageal glands, he says, are found in adult life all along the oesophagus with the exception of the lower 2 to 4 mm. Schridde (1904) found "cardiac" glands in the upper part of the oesophagus in 70% of cases examined, but Rector and Connerley (1941), in 1,000 post-mortem examinations of children, found gastric mucosa in the upper two-thirds of the oesophagus in only 7.8%, though they did say that this aberrant type of mucosa might have been found more frequently if serial sections had been made. Nicholson (1950) gives an illustration (his Fig. 17) of a section of an upper cardiac gland, showing that these glands are all superficial to the muscularis mucosae and that they correspond exactly to those of the cardia. Many suggestions have been made that these glands might give rise to carcinomas, from the time of Schaffer (1897) and Hildebrand (1898), who described cases with such glands in the upper oesophagus and emphasized the possibility of tumour formation. Hewlett looked in the pre-1900 literature but could only find six reported cases of oesophageal adenocarcinomas where the site of origin was given, and none of these were higher than just above the mid-oesophagus.

If adenocarcinomas do arise in superficial glands, then some should be seen at the proximal end of the oesophagus and should be surrounded by squamous epithelium. Adequate reports of such cases are very hard to find. A most doubtful one was recorded by Feldman (1939), a rather

more satisfactory one by Carrie (1950), and one (Case 2) has been reported above, although even this tumour may, of course, have arisen in an oesophagus lined with gastric type mucosa throughout its entire length. Watson and Pool (1949) tabulate one adenocarcinoma of the cervical oesophagus in 77 tumours at this site, and Shedd, Crowley, and Lindskog (1955) one adenocarcinoma of the upper third of the oesophagus among 17 such tumours occurring in that organ, but no further reference is made to these cases in the texts. It does not seem at all probable, therefore, that the superficial glands of the oesophagus, at its upper limit at least, are a significant source of oesophageal adenocarcinomas, even though they may still be so at the lower limit. Since the deep oesophageal glands are evenly distributed along the length of the oesophagus, they also appear to be an improbable source of the majority of these tumours, the adenocarcinomas being most unevenly placed.

There is little evidence available to suggest that oesophageal tumours may arise in areas of glandular metaplasia following attrition and long-standing infection. This, however, is believed to occur at times in the urinary tract (Anderson, 1955), though Abeshouse (1943) found that adenocarcinoma of the bladder accounted for less than 2% of a series of reported bladder tumours. Morson (1955) has shown that metaplasia of the gastric mucosa to a type resembling intestinal mucosa is commonly related to stomach cancer. Should such metaplasia have occurred in those cases in which the lower oesophagus is lined by gastric mucosa, it might well both be associated with hiatus hernia and predominate at the lower end on account of the associated trauma and chronic inflammatory changes.

During the development of the human embryo the epithelium of the oesophagus is at first present in the simple columnar form common to the entodermal lining of the gut tract. It passes through a transient stage of ciliation before reaching its final stratified squamous form. Patten (1953) in his book on human embryology reproduces the University of Michigan's series of drawings of changes in the oesophageal lining showing the process in the embryo from the third week to the seventh month. Arey (1954) writes:

"The epithelium begins to acquire cilia at ten weeks and it is not until the fifth month that a stratified squamous epithelium starts replacing it. At birth the epithelium numbers ten layers, but may still include some ciliated patches. *Superficial glands* are developing in the fifth month, whereas the *deep glands* arise mostly after birth."

There is now some evidence that large portions of the lower adult oesophagus may at times be lined by gastric mucous membrane. Pattinson and others (1955) have reported another extremely interesting instance (Case 9) like that reported by Morson and Belcher (1952), in which this condition was present but where there were isolated patches of squamous epithelium within the columnar-celled mucosa just proximal to the cardia. It seems possible that the factors influencing squamous transformation of the oesophageal epithelium during development may have a physiological gradient of action from pharynx to stomach. Failure of this process to be completed during growth and descent of the stomach would then lead to a varying level of change from columnar to squamous epithelium, diminishing in frequency from distal to proximal ends of the oesophagus. Since the oesophagus is normally lined by squamous epithelium throughout its length, a fairly even distribution of squamous-cell carcinomas might be expected, but—if such a gradient of development is present—then the cases with partial failure of transformation of that lining would be likely to produce the observed incidence of adenocarcinomas which increases from pharynx to stomach. It is possible that columnar-celled epithelium is rather more liable to the development of malignant tumours than the squamous-celled; if so, the incidence of adenocarcinomas in the group in which a gastric type of mucous membrane persists may be higher than in that with a squamous. If some degree of such a graded failure of squamous transformation were not uncommon, if tumours arose frequently in gastric glands in the lower oesophagus, or if they arose in areas of glandular metaplasia following infection, then the number of squamous-cell carcinomas and of adenocarcinomas found at the lower end of the oesophagus might not be so very different. While there are several quite unsupported assumptions contained in the above suggestions, they do fit the facts so far observed—which the old, uncritical acceptance of all adenocarcinomas in the oesophagus as either spreading gastric cancers or as tumours arising in random placings of ectopic gastric glands did not.

Many patients with adenocarcinomas of the lower oesophagus have been seen in hospitals, but the belief that the change in mucous membrane was constantly located and fixed at the anatomical junction of oesophagus and stomach led to efforts to explain them away rather than to account for their presence. The knowledge that carcinomas of the gastric fundus readily spread to involve

the oesophagus was sufficient to maintain the commonly expressed view that true oesophageal adenocarcinomas either did not exist or were great rarities. The demonstration that the oesophagus is not uncommonly lined for part of its length by gastric mucosa, and the increasing number of adenocarcinomas in the oesophagus noted since interest in hiatus hernia was aroused, have changed this outlook. It is suggested here that oesophageal adenocarcinoma is not such a very uncommon disease, that it occurs predominantly in mucosa which has failed to undergo squamous transformation, that its incidence increases in frequency from pharynx to stomach, and that there is an important group of true junctional adenocarcinomas which cannot be reasonably allocated to stomach or oesophagus.

SUMMARY

Twenty-three adenocarcinomas of the oesophagus, not associated with hiatus hernia, are reported, in addition to seven with that association previously published and one further case recorded here. It is suggested that such tumours usually arise in lower oesophageal mucous membrane which has failed to undergo squamous transformation before birth.

I wish to thank my colleagues on the staff of the Royal Marsden Hospital for permission to publish the figures of all new cases of oesophageal and stomach cancer seen at the hospital from 1936 to 1951. Thirty-three individual cases are referred to in the text, mostly by hospital number. One of these was a patient of Mr. C. E. Shattock; six were patients of Mr. A. Lawrence Abel; seven of Mr. R. C. B. Ledlie; four of Mr. W. A. Mill; seven of Mr. R. W. Raven; and two of Dr. M. Lederman. I am indebted to Mr. N. R. Barrett for allowing me to report Case 2. I am most grateful to Dr. J. W. Whittick for the photographs of operation specimens and for reviewing the sections of all these patients for me, and to Dr. J. J. Stevenson for the radiographs published here and for screening and reporting on

most of these patients. Miss J. Hunt has most kindly prepared the illustrations, with the exception of Fig. 9 for which I am indebted to Mr. K. G. Moreman. Miss J. Thompson has done the hard work of collecting and sorting records of patients and in helping to prepare the text of this paper for publication, and I am most grateful to her for her invaluable help.

REFERENCES

- Abeshouse, B. S. (1943). *J. Urol.*, **49**, 259.
 Allison, P. R. (1946). *Proc. roy. Soc. Med.*, **39**, 415.
 — and Johnstone, A. S. (1953). *Thorax*, **8**, 87.
 Anderson, C. K. (1955). *Proc. roy. Soc. Med.*, **48**, 699.
 Arey, L. B. (1954). *Developmental Anatomy. A Textbook and Laboratory Manual of Embryology*, 6th ed., p. 241. W. B. Saunders Co., Philadelphia and London.
 Barrett, N. R. (1950). *Brit. J. Surg.*, **38**, 175.
 Borrmann, R. (1907). *Verh. dtsch. path. Ges.*, **11**, 108.
 Bosher, L. H., and Taylor, F. H. (1951). *J. thorac. Surg.*, **21**, 306.
 Bucher, R. (1893). *Beitr. path. Anat.*, **14**, 71.
 Carey, J. M., and Clagett, O. T. (1955). *Ann. Surg.*, **142**, 2.
 Carrie, A. (1950). *Brit. J. Surg.*, **37**, 474.
 Feldman, M. (1939). *Amer. J. dig. Dis.*, **6**, 453.
 Hewlett, A. W. (1901). *J. exp. Med.*, **5**, 319.
 Hildebrand, H. (1898). *Munch. med. Wschr.*, **45**, 1057.
 Johnson, F. P. (1910). *Amer. J. Anat.*, **10**, 521.
 Johnstone, A. S. (1951). *J. Fac. Radiol. (Lond.)*, **3**, 52.
 Kaufmann, E. (1929). *Pathology for Students and Practitioners*, vol. 1, pp. 647–8. Translated by S. P. Reimann. Lewis, London.
 Lederman, M. (1955). *Brit. J. Radiol.*, **28**, 173.
 Milner, R. (1904). *Arch. klin. Chir.*, **74**, 669, 1009.
 Morris, K. N. (1955). *Aust. N.Z. J. Surg.*, **25**, 24.
 Morson, B. C. (1955). *Brit. J. Cancer*, **9**, 365, 377.
 — (1956). Personal communication.
 — and Belcher, J. R. (1952). *Brit. J. Cancer*, **6**, 127.
 Nicholson, G. W. de P. (1950). *Studies on Tumour Formation*, p. 35. Butterworth, London.
 Palmer, E. D. (1953). *Radiology*, **60**, 825.
 Patten, B. M. (1953). *Human Embryology*, 2nd ed., pp. 469 and 472. Churchill, London.
 Pattinson, J. N., Osborne, G., and Morson, B. C. (1955). *J. Fac. Radiol. (Lond.)*, **7**, 90.
 Poppel, M. H., Zaino, C., and Lentino, W. (1955). *Radiology*, **64**, 690.
 Puestow, C. B., Gillesby, W. J., and Guynn, V. L. (1955). *Arch. Surg.*, **70**, 662.
 Raeburn, C. (1951). *J. Path. Bact.*, **63**, 157.
 Rector, L. E., and Connerley, M. L. (1941). *Arch. Path. (Chicago)*, **31**, 285.
 Schaffer, J. (1897). *S.B. Akad. Wiss. Wien*, **106**, abt. 3, p. 175.
 Schridde, H. (1904). *Virchows Arch. path. Anat.*, **175**, 1.
 Shedd, D. P., Crowley, L. G., and Lindskog, G. E. (1955). *Surg. Gynec. Obstet.*, **101**, 55.
 Smithers, D. W. (1945). *Brit. J. Radiol.*, **18**, 199.
 — (1950). *Ibid.*, **23**, 261.
 — (1955). *Ibid.*, **28**, 554.
 Tanner, N. C. (1946). *Proc. roy. Soc. Med.*, **39**, 411.
 Thomas, J. V., and Hay, L. J. (1954). *Surgery*, **35**, 635.
 Watson, W. L., and Pool, J. L. (1949). In *Cancer of the Esophagus and Gastric Cardia*, edited by G. T. Pack, p. 36. Mosby, St. Louis.
 Willis, R. A. (1952). *The Spread of Tumours in the Human Body*, 2nd ed., p. 63. Butterworth, London.
 — (1953). *Pathology of Tumours*, 2nd ed., p. 392. Butterworth, London.
 Wyndham, N. (1956). *Brit. J. Surg.*, **43**, 409.
 Zahn, F. W. (1889). *Virchows Arch. path. Anat.*, **117**, 30.