

CORRELATION OF CERTAIN BRONCHOGRAPHIC ABNORMALITIES SEEN IN CHRONIC BRONCHITIS WITH THE PATHOLOGICAL CHANGES

BY

LYNNE M. REID

From the Institute of Diseases of the Chest, Brompton Hospital, London

In their description of the changes seen in the bronchograms of patients with chronic bronchitis, Simon and Galbraith (1953) described the absence of peripheral filling as the most frequent change in the lung periphery and also the presence of "pools," the name applied to dense blobs of contrast medium, 3-5 mm. in diameter, which arise from the peripheral part of the bronchial tree. The present investigation is concerned with the significance of the lack of filling and the nature of the "pools" in patients with chronic bronchitis. The opportunity has also been taken to investigate another abnormal shadow with a spiked outline which is sometimes seen in patients with chronic bronchitis and emphysema.

METHOD AND MATERIAL

The method of injection of the bronchial tree with radio-opaque material and the selection of relevant blocks of tissue for microscopic examination have been described in the previous paper. Because of the small size of the structures in the secondary lobules serial sections are necessary to correlate the bronchographic and microscopic appearances. In this study, however, the distance between sections varied from 100 μ to 1 mm., since the histological changes had previously been examined in greater detail by serial section (Reid, 1954). Verhoeff-van Gieson and haematoxylin-eosin stains were used routinely, together with special stains to demonstrate mucus (Hotchkiss-McManus reaction) and iron (Prussian blue method) in certain cases.

Eleven lung specimens from patients with chronic bronchitis were investigated. Two were obtained at necropsy and nine from operation on patients with both chronic bronchitis and carcinoma of the lung.

CORRELATION OF THE BRONCHOGRAPHIC APPEARANCE WITH PATHOLOGICAL CHANGES

ABSENCE OF PERIPHERAL FILLING.—The first abnormality, lack of peripheral filling, can only be considered significant if there is sufficient radio-

opaque material in the appropriate bronchus, which should be demonstrated as a dense column and not as two rather ghostly parallel lines. Even where the amount of contrast medium seems adequate, the filling obtained may be patchy and uneven, as if it were affected by local changes in the lung. For example, a considerable part of a segment or of a subsegment may fail to fill beyond small bronchi, or may show filling of some bronchioles and not of others, while neighbouring subsegments show regular peripheral filling.

There are also certain appearances in the bronchogram which enable incomplete filling due to disease of an airway to be distinguished from that due to technique. If the radio-opaque material has not had time to flow or if filling has stopped because the air tube is blocked with secretion, the end of the contrast medium is truncated and has a rectilinear outline and the walls of the airway are still parallel even at the point where filling stops (Fig. 1). Microscopic examination confirms that in these instances the airway is patent beyond the part which has filled with radio-opaque material (Fig. 2). If this persists in a delayed film it is probably due to blockage by secretion. This, of course, does not preclude disease more peripherally, nor can secretion sufficient to cause this appearance be considered normal. When the wall is persistently irregular and the ending rounded or tapering histological study shows it is due to organic disease (Figs. 3 and 4). Because of their larger size this difference is more easily detected in the bronchi, but can often be seen even in the bronchioles (Figs. 1 and 3). In the interpretation of bronchograms in any disease of the lung the characteristic bronchographic appearances are useful in distinguishing the various causes of non-filling.

In studying an injected specimen, bronchioles with an irregular outline and rounded ending in the bronchograms, suggesting occlusion, were particularly selected for microscopic study. Of 16

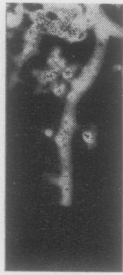

FIG. 1.—Part of a radiograph of a normal lung after injection with a radio-opaque suspension. This bronchial pathway was passing towards the diaphragm and shows a squared or truncated ending. $\times 2$.

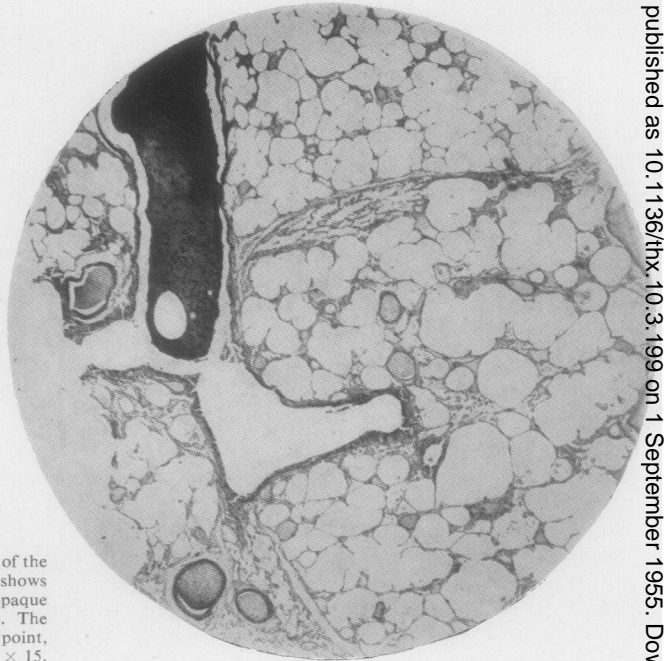


FIG. 2.—Longitudinal section through the end of the bronchial pathway illustrated in Fig. 1. It shows the rectilinear end of the column of radio-opaque solution (seen as black in this illustration). The bronchiole is patent and branches at this point, continuing distally to supply normal lung. $\times 15$.

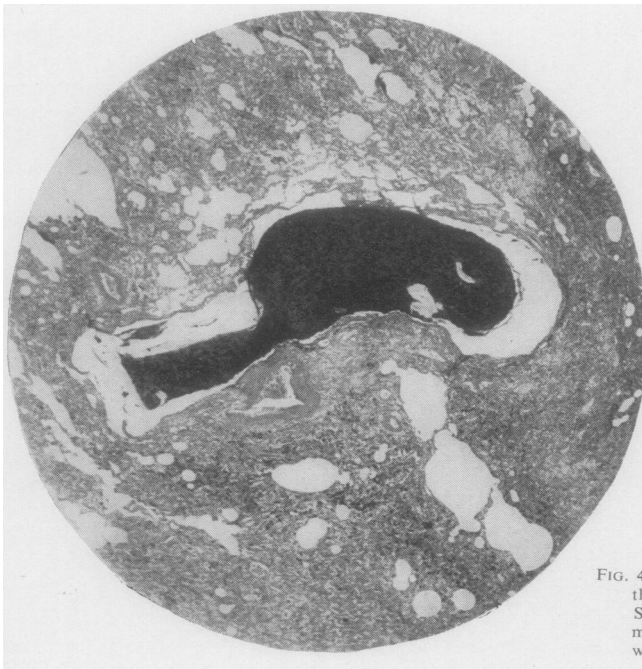

FIG. 4.—Longitudinal section through the lower of the two bronchial pathways seen in Fig. 3. Serial sections established that the opaque medium is outlining the blind end of a bronchiole which is surrounded by collapsed lung. $\times 15$.

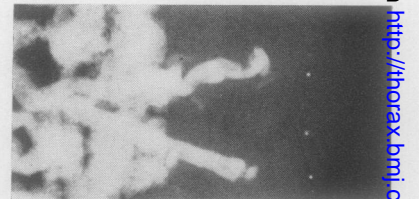


FIG. 3.—Part of a radiograph of the apical segment of the lower lobe (from a patient with chronic bronchitis) after the specimen had been injected with contrast medium. The two bronchial pathways illustrated are passing towards the pleural surface. The ending of each pathway is irregular and rounded. The lower one is illustrated in Fig. 4. $\times 2$.

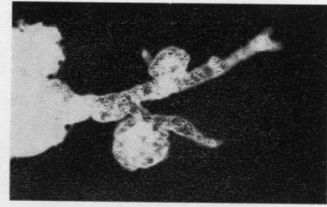
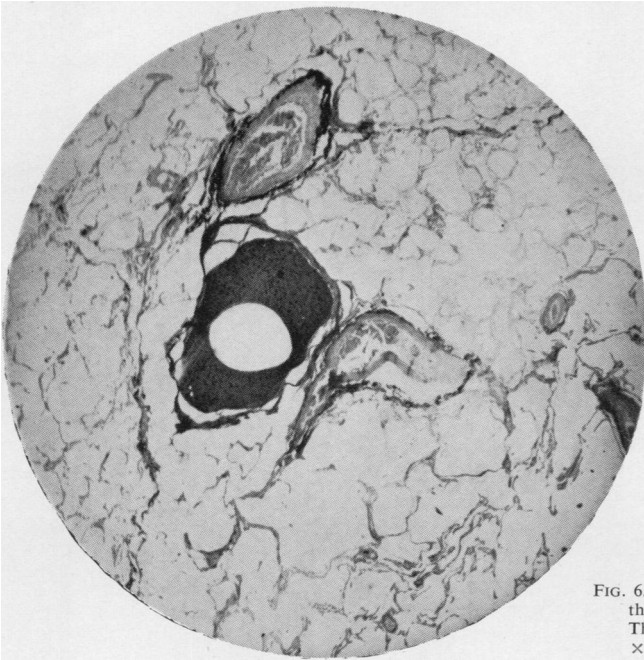


FIG. 5.—Magnified picture of part of the anterior segment of the upper lobe from a radiograph of a necropsy specimen injected with red lead suspension and from a patient with chronic bronchitis and carcinoma. The two bronchial pathways pass towards the pleura, and to each of them is attached a "pool" of opaque medium. The upper one is illustrated in Fig. 6. $\times 2$.

FIG. 6.—Section through the "pool" connected to the upper bronchial pathway seen in Fig. 5. The contrast medium is in a dilated bronchiole. $\times 15$.

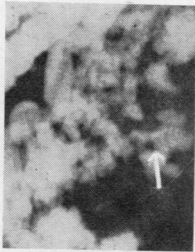

FIG. 7.—Magnification of a small area from the apical segment of the lower lobe from a radiograph of an operation specimen after injection with red lead. The patient had chronic bronchitis and carcinoma of the lung. The "spider" (indicated by arrow) is coarser and more irregular than the peripheral pattern seen in a normal bronchogram. Centrally, an airway is outlined and from it several lateral arms arise. Histological examination suggests that the lateral arms of this shadow represent approximately the same order of bronchioles as the two branches seen on the left side of the main pathway in Fig. 1. $\times 2$.

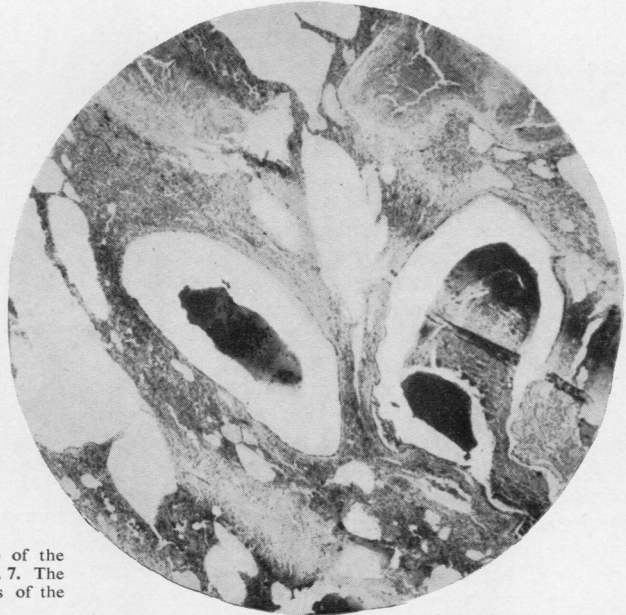

FIG. 8.—Shows radio-opaque medium in two of the lateral arms of the shadow illustrated in Fig. 7. The red lead is moulded by the blind endings of the terminal bronchioles. $\times 25$.

examples all showed that organic disease in the lung had prevented further filling. Stenosis is often complete, with obliteration of the lumen. The surrounding lung may be normal or it may show any of the various changes seen in the secondary lobules in chronic bronchitis, in particular, consolidation or collapse of the bronchiolar wall and lung beyond. These changes may be acute, but the presence of fibrosis frequently indicates that they are chronic.

PERIPHERAL "POOLING."—The second abnormality, "peripheral pooling," was seen in five of the injected specimens, and seven blocks of tissue which included bronchioles showing this change were examined.

The shadow in the bronchogram may be spherical, lobulated, or sausage-shaped and its edge is smooth (Fig. 5). Microscopic study of such areas shows that the radio-opaque material is "pooled" in a dilated bronchiole (Fig. 6), which is usually obliterated beyond the "pool." Although they may occasionally be larger, the usual diameter of such a shadow in the bronchogram is only 3–5 mm. It arises in a bronchiole whose normal diameter is less than 1 mm. When they arise near the end of an axial pathway, such "pools" can be shown in the specimen to be beyond the tenth generation of the bronchial tree.

The wall of these spaces is usually lined with respiratory epithelium and contains muscle and elastic fibres, confirming its origin from bronchioles, but sometimes the epithelium, in some areas at least, rests on fibrous tissue. This suggests that although distension is probably the most important factor ulceration also may play a part in the production of these deformities.

ABNORMAL PERIPHERAL SHADOWS WITH A "SPIKED" OUTLINE.—A third feature sometimes seen in the bronchograms of patients with chronic bronchitis and emphysema is an abnormal shadow with a spiked, irregular outline (Fig. 7) in marked contrast to the smooth outline of a "pool." On occasions such a shadow may resemble the pattern of peripheral filling in a normal bronchogram save that it is rather coarser. It then consists of a central line with a varying number of lateral spikes—usually four to six. Before its pathological structure was known, such a shadow was called for convenience a "spider," because of its resemblance to a body with legs, even if an inconstant number of legs. The overall length of the shadow in the bronchogram is usually between half and one centimetre and the lateral spikes are usually one to two millimetres in length, with tapering ends. The shadows are often obvious by contrast

with nearby areas which have not filled with radio-opaque material.

Microscopic examination of four examples shows that the radio-opaque material in the side arm (Fig. 8) is in terminal bronchioles, or an adjacent generation of the bronchial tree. (Miller (1947) has defined a terminal bronchiole as one which is immediately proximal to a respiratory bronchiole.) Filling with radio-opaque material has stopped because the lung between the spike is collapsed and fibrosed. The changes in the examined areas which showed this appearance were of a chronic nature.

VARIATIONS OF THE SHADOWS.—The "spider" may not show the regular pattern described above as the distortion from the normal pattern may be even greater. Sometimes, "spikes" are seen on only one side of a central line, or the central part may be of greater diameter and the shadow then resembles a "pool" with an occasional lateral spike. The "spikes" may taper at their end, but be so dilated at their origin that in the bronchogram they are triangular in shape. Such distortion reflects the changes of dilatation and obliteration in terminal and near terminal bronchioles with airlessness of the interjacent lung. This is similar to the pathological basis for a "pool," namely bronchiolectasis, but a "pool" is usually situated more proximally than a terminal bronchiole.

The similarity in the pathological changes in the two conditions explains the various shadows which are intermediate in appearance and combine some of the features of each.

DISCUSSION

Sparks and Wood (1932), O'Donoghue (1938), Drouet, Herbeuval, and Faivre (1949), and Scarinci (1950) in writing of the bronchographic appearances in emphysema have stressed the fact that peripheral filling occurs more slowly than in normal subjects and is less complete, although none of them demonstrated a pathological basis for this. The direct correlation described here between the bronchograms and specimens shows that under satisfactory conditions failure to fill usually the outcome of disease in the peripheral part of the lung, and that when filling ceases because of organic changes in the bronchial tree the bronchogram shows characteristic abnormalities. The pathological changes which impair bronchiolar filling include fibrosis and scarring which indicate chronic and permanent distortion although in necropsy specimens some acute and therefore possibly reversible changes are seen.

An abnormal peripheral pattern has also been mentioned by O'Donoghue (1938), who described the way "isolated clusters of normal alveoli" are filled. The diagrams published by Sparks and Wood (1932) show a similar appearance. Drouet and his colleagues (1949) describing a peculiar peripheral pattern compare it to lily of the valley ("brin de muguet" in French, which Scarinci (1950) also described, in Italian, as "mughetto"). It seems appropriate that abnormalities of the bronchial tree should be described in botanical terms. The "lily of the valley" appearance illustrated in these two papers is probably what has been described here as "pools." Although they discuss the possible pathological basis for this appearance these authors do not describe any direct pathological correlation. Drouet and his colleagues consider it due to "incomplete alveolar filling" which makes the localized areas of filling unduly obvious, while Scarinci attributes it to "lobular emphysema."

The presence of "pools" and "spiders" has a functional significance beyond the finding of a dilatation in an isolated bronchiole. It implies considerable local distortion and destruction, as there is usually associated obliteration of the bronchioles and at least one, if not more, secondary lobules are diseased. Moreover, not only is disease present in adjacent lobules, but, in all the specimens of chronic bronchitis in which these shadows were seen, more widespread disease was found in the lungs. This is in agreement with the observation of Simon and Galbraith (1953) that "pools" were found in 67% of bronchograms done on patients in whose standard radiographs emphysema had been diagnosed after the strict application of their criteria. In patients with chronic bronchitis "pooling" usually means there is serious and scattered disease in the secondary lobules of the lung.

The incidence of these bronchographic appearances in patients with chronic bronchitis, and their distribution within the lungs, can only be considered in general terms, since maximal peripheral filling was not always attempted. Thirty-six bronchograms selected at random from patients with chronic bronchitis were viewed, and in 24 of them one or more of the three abnormal bronchographic appearances just described were present. The remaining 12 included bronchograms in which, for technical reasons, peripheral filling could not be assessed, as well as several in which the peripheral pattern was normal. These figures are not designed to give the exact incidence of these bronchographic appearances, but only to show

that they are frequently encountered. When the disease is severe and of some years' duration a normal peripheral pattern throughout the lungs is rarely seen.

The incidence of the different appearances varies widely. A bronchogram may show only an occasional "pool" or "spider," or it may show all the abnormal features that have been considered here—"pools" and "spiders," and unfilled parts of the lung supplied by bronchioles with rounded endings. Sometimes one appearance may predominate, either throughout the lung or in one region, as in the right lower lobe of a particular bronchogram, in which there were 20 "pools" ranging from 2 to 4 mm. in diameter, although in the remainder of the lung only an occasional "spider" was found.

Since the pathological changes which account for the bronchographic appearances are not exclusive to chronic bronchitis, it is not surprising that similar appearances may be seen in other conditions. In most instances of bronchiectasis in which the pathological changes closely resemble those seen in chronic bronchitis, the tapering or rounded endings characteristic of organic obliteration occur in bronchi, usually large ones, while in chronic bronchitis, when it occurs, it is found in the bronchioles.

Because of the small size of scars or other changes associated with disease in the smaller bronchi and bronchioles, the plain radiograph may show no abnormality. The direct correlation of bronchographic and pathological changes makes it possible to interpret bronchographic appearances in the distal part of the bronchial tree, and bronchography can thus be used to investigate the smaller peripheral units of the lung which functionally are so vital.

SUMMARY

The bronchographic changes seen in the lung periphery in chronic bronchitis have been correlated with the pathological changes. The first abnormality is the incomplete peripheral filling. This may occur even when technique is adequate and the bronchioles are not plugged with secretion, and is due to stenosis and often obliteration of the bronchiolar lumen. The second abnormality is the presence of peripheral "pools." Here the radio-opaque material is "pooled" in a dilated bronchiole, usually immediately proximal to a point of obliteration. The third is a shadow with a spiked outline, which somewhat resembles the normal pattern save that it is coarser. The

“spikes” result from filling of terminal or near-terminal bronchioles which are dilated proximally to points of obliteration.

My thanks are due to the physicians and surgeons of the Brompton Hospital for the opportunity to study these patients and specimens, and particularly to Dr. G. Simon for his help in studying the bronchograms and to Dr. Neville Oswald for the opportunity to do so ; to Dr. J. W. Clegg, in whose department the work was started ; and to Mr. D. F. Kemp for the photographs.

This work was done during the tenure of a grant from the Research Fund of the Hospitals for Diseases of the Chest.

REFERENCES

- Drouet, P.-L., Herbeuval, R., and Faivre, G. (1949). *J. franç. Méd. Chir. thorac.*, **3**, 201.
 Miller, W. S. (1947). *The Lung*, 2nd ed., p. 41. Thomas, Springfield, Illinois.
 O'Donoghue, J. (1938). *Amer. J. Roentgenol.*, **40**, 863.
 Reid, L. M. (1954). *Lancet*, **1**, 275.
 Scarinci, C. (1950). *Arch. Tisiol. (seg. sci.)*, **5**, 659.
 Simon, G., and Galbraith, H.-J. B. (1953). *Lancet*, **2**, 850.
 Sparks, J. V., and Wood, F. G. (1932). *Ibid.*, **2**, 1419.