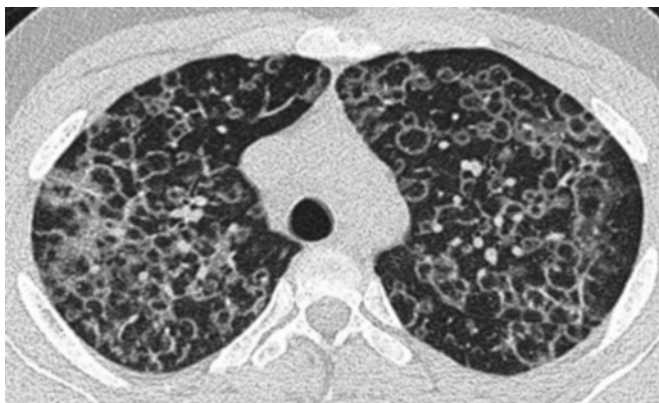

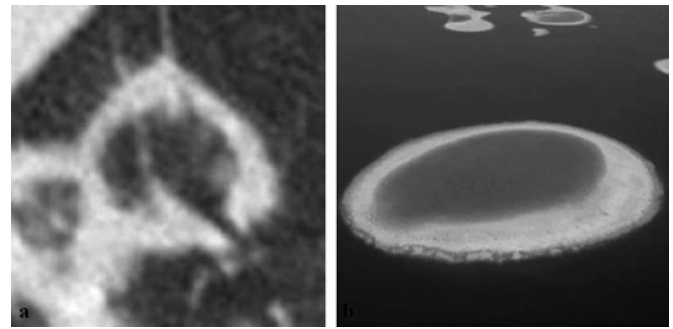
## The atoll sign

A man presented as an urgent referral to the interstitial lung disease outpatient clinic with a 5 week history of fever, night sweats, shortness of breath and malaise. His admission chest x-ray showed patchy consolidation within both lungs, and a subsequent CT demonstrated multiple parenchymal ring opacities (figure 1 and figure 2A). On the basis of the unusual CT appearances he subsequently proceeded to an open lung biopsy which demonstrated polypoid buds of intra-alveolar granulation tissue or Masson bodies, consistent with a histopathological diagnosis of organising pneumonia (figure 3). He was treated with intravenous methylprednisolone and hydroxychloroquine to which he initially responded. Over the next 5 years he had several relapses clinically and radiologically which required pulse doses of methylprednisolone. Once stable, his medication was tapered and eventually stopped. Repeat CT imaging at this time revealed no residual parenchymal abnormalities. No definite cause for his illness was found and, following a multidisciplinary evaluation of his case, a final diagnosis of cryptogenic organising pneumonia was made.

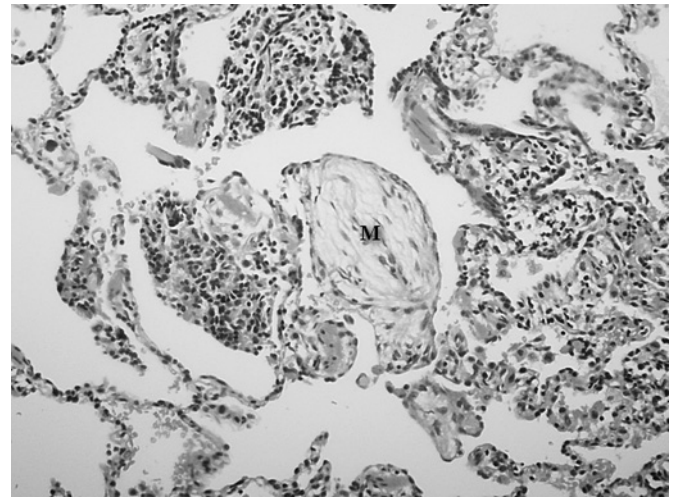
Crescentic or ring-shaped opacities surrounding an area of ground-glass opacification occasionally seen in the setting of organising pneumonia were first described by Voloudaki<sup>1</sup> and later coined the 'Atoll sign' by Zompatori.<sup>2</sup> Kim *et al.* documented it in 19% of cases of cryptogenic organising pneumonia.<sup>3</sup> The word Atoll is derived from the Maldivian word 'atholhu' meaning an island consisting of a circular coral reef surrounding a lagoon (figure 2B). Although originally thought to be specific for organising pneumonia, this CT appearance has been described in a variety of other diseases including sarcoidosis,<sup>4</sup> Wegener granulomatosis,<sup>5</sup> lymphomatoid granulomatosis,<sup>6</sup> pulmonary paracoccidiomycosis<sup>7</sup> and non-specific interstitial pneumonia,<sup>8</sup> and under different names including the 'reversed-halo' sign and the 'fairy-ring' sign. Histopathologically the ground-glass opacification centrally represents septal inflammation, and cellular debris within the airspaces and the peripheral crescentic or ring-shaped opacity represents organising pneumonia in the alveolar ducts.<sup>1</sup> From a learning perspective, although this striking CT appearance is well documented in organising pneumonia, it should alert the radiologist and physician to other possible diagnoses, of which Wegener granulomatosis is particularly important.



**Figure 1** Chest CT at presentation showed innumerable ring opacities, some of which surround a centre of ground-glass opacification, throughout the lung.



**Figure 2** (A) Magnified view of conjoined ring opacities. (B) Aerial view of a Maldivian 'atoll' from which this CT sign derives its name.



**Figure 3** Surgical lung biopsy material demonstrated intra-alveolar polypoid buds of granulation tissue also known as Masson bodies (M).

### Learning points

- ▶ The Atoll sign is a well recognised CT pattern associated with organising pneumonia.
- ▶ This sign has also been reported in a number of other important conditions which should be considered in the differential diagnosis when interpreting it. In particular, consideration should be given to Wegener granulomatosis.

### Simon L F Walsh, Benjamin J Robertson

Department of Radiology, Royal Brompton Hospital, UK

**Correspondence to** Simon L F Walsh, Department of Radiology, Royal Brompton Hospital, Sydney Street, London SW3 6NP, UK; [sfwalsh@gmail.com](mailto:sfwalsh@gmail.com)

**Competing interests** None.

**Provenance and peer review** Not commissioned; externally peer reviewed.

Accepted 9 June 2010

*Thorax* 2010; **65**:1–2. doi:10.1136/thx.2010.139360

### REFERENCES

1. Voloudaki AE, Bours DE, Froudarakis ME, *et al.* Crescentic and ring-shaped opacities. CT features in two cases of bronchiolitis obliterans organizing pneumonia (BOOP). *Acta Radiol* 1996;**37**:889–92.

## Images in Thorax

- Zompatori M**, Poletti V, Battista G, *et al*. Bronchiolitis obliterans with organizing pneumonia (BOOP), presenting as a ring-shaped opacity at HRCT (the atoll sign). A case report. *Radiol Med* 1999;**97**:308–10.
- Kim SJ**, Lee KS, Ryu YH, *et al*. Reversed halo sign on high-resolution CT of cryptogenic organizing pneumonia: diagnostic implications. *AJR Am J Roentgenol* 2003;**180**:1251–4.
- Marlow TJ**, Krapiva PI, Schabel SI, *et al*. The “fairy ring”: a new radiographic finding in sarcoidosis. *Chest* 1999;**115**:275–6.
- Agarwal R**, Aggarwal AN, Gupta D. Another cause of reverse halo sign: Wegener’s granulomatosis. *Br J Radiol* 2007;**80**:849–50.
- Benamore RE**, Weisbrod GL, Hwang DM, *et al*. Reversed halo sign in lymphomatoid granulomatosis. *Br J Radiol* 2007;**80**:e162–6.
- Gasparetto EL**, Escuissato DL, Davaus T, *et al*. Reversed halo sign in pulmonary paracoccidioidomycosis. *AJR Am J Roentgenol* 2005;**184**:1932–4.
- Ueda S**, Inoue R, Tanaka K, *et al*. A case of nonspecific interstitial pneumonia with reversed halo sign on chest HRCT. *Nihon Kogyoku Gakkai Zasshi* 2007;**45**:248–52.



## The atoll sign

Simon L F Walsh and Benjamin J Robertson

*Thorax* published online September 6, 2010  
doi: 10.1136/thx.2010.139360

---

Updated information and services can be found at:  
<http://thorax.bmj.com/content/early/2010/09/06/thx.2010.139360.full.html>

---

*These include:*

### References

This article cites 8 articles, 5 of which can be accessed free at:  
<http://thorax.bmj.com/content/early/2010/09/06/thx.2010.139360.full.html#ref-list-1>

Article cited in:

<http://thorax.bmj.com/content/early/2010/09/06/thx.2010.139360.full.html#related-urls>

### P<P

Published online September 6, 2010 in advance of the print journal.

### Email alerting service

Receive free email alerts when new articles cite this article. Sign up in the box at the top right corner of the online article.

---

### Notes

---

Advance online articles have been peer reviewed, accepted for publication, edited and typeset, but have not yet appeared in the paper journal. Advance online articles are citable and establish publication priority; they are indexed by PubMed from initial publication. Citations to Advance online articles must include the digital object identifier (DOIs) and date of initial publication.

---

To request permissions go to:  
<http://group.bmj.com/group/rights-licensing/permissions>

To order reprints go to:  
<http://journals.bmj.com/cgi/reprintform>

To subscribe to BMJ go to:  
<http://group.bmj.com/subscribe/>